

University of Groningen

## A single center analysis of nucleophosmin in acute myeloid leukemia

Woolthuis, Carolien M.; Mulder, Andre B.; Verkaik-Schakel, Rikst Nynke; Rosati, Stefano; Diepstra, Arjan; van den Berg, Eva; Schuringa, Jan Jacob; Vellenga, Edo; Kluin, Philip M.; Huls, Gerwin

*Published in:*  
Haematologica

*DOI:*  
[10.3324/haematol.2012.079806](https://doi.org/10.3324/haematol.2012.079806)

**IMPORTANT NOTE:** You are advised to consult the publisher's version (publisher's PDF) if you wish to cite from it. Please check the document version below.

*Document Version*  
Publisher's PDF, also known as Version of record

*Publication date:*  
2013

[Link to publication in University of Groningen/UMCG research database](#)

*Citation for published version (APA):*

Woolthuis, C. M., Mulder, A. B., Verkaik-Schakel, R. N., Rosati, S., Diepstra, A., van den Berg, E., Schuringa, J. J., Vellenga, E., Kluin, P. M., & Huls, G. (2013). A single center analysis of nucleophosmin in acute myeloid leukemia: value of combining immunohistochemistry with molecular mutation analysis. *Haematologica*, 98(10), 1532-1538. <https://doi.org/10.3324/haematol.2012.079806>

### Copyright

Other than for strictly personal use, it is not permitted to download or to forward/distribute the text or part of it without the consent of the author(s) and/or copyright holder(s), unless the work is under an open content license (like Creative Commons).

The publication may also be distributed here under the terms of Article 25fa of the Dutch Copyright Act, indicated by the "Taverne" license. More information can be found on the University of Groningen website: <https://www.rug.nl/library/open-access/self-archiving-pure/taverne-amendment>.

### Take-down policy

If you believe that this document breaches copyright please contact us providing details, and we will remove access to the work immediately and investigate your claim.

Downloaded from the University of Groningen/UMCG research database (Pure): <http://www.rug.nl/research/portal>. For technical reasons the number of authors shown on this cover page is limited to 10 maximum.

# A single center analysis of nucleophosmin in acute myeloid leukemia: value of combining immunohistochemistry with molecular mutation analysis

Carolien M. Woolthuis,<sup>1</sup> André B. Mulder,<sup>2</sup> Rikst Nynke Verkaik-Schakel,<sup>1</sup> Stefano Rosati,<sup>3</sup> Arjan Diepstra,<sup>3</sup> Eva van den Berg,<sup>4</sup> Jan Jacob Schuringa,<sup>1</sup> Edo Vellenga,<sup>1</sup> Philip M. Kluijn,<sup>3</sup> and Gerwin Huls<sup>1</sup>

<sup>1</sup>Department of Experimental Hematology, University Medical Center Groningen, University of Groningen, Groningen;

<sup>2</sup>Department of Laboratory Medicine, University Medical Center Groningen, University of Groningen, Groningen;

<sup>3</sup>Department of Pathology and Medical Biology, University Medical Center Groningen, University of Groningen,

Groningen; <sup>4</sup>Department of Genetics, University Medical Center Groningen, University of Groningen, Groningen, The Netherlands

## ABSTRACT

Mutations of nucleophosmin 1 are frequently found in acute myeloid leukemia and lead to aberrant cytoplasmic accumulation of nucleophosmin protein. Immunohistochemical staining is therefore recommended as the technique of choice in front-line screening. In this study, we assessed the sensitivity and specificity of immunohistochemistry on formalin-fixed bone marrow biopsies compared with gold standard molecular analysis to predict nucleophosmin 1 mutation status in 119 patients with acute myeloid leukemia. Discrepant cases were further characterized by gene expression analyses and fluorescence *in situ* hybridization. A large overlap between both methods was observed. Nevertheless, nine patients demonstrated discordant results at initial screening. Five cases demonstrated nuclear staining of nucleophosmin 1 by immunohistochemistry, but a nucleophosmin 1 mutation by molecular analysis. In two cases this could be attributed to technical issues and in three cases minor subpopulations of myeloblasts had not been discovered initially. All tested cases exhibited the characteristic nucleophosmin-mutated gene expression pattern. Four cases had cytoplasmic nucleophosmin 1 staining and a nucleophosmin-mutated gene expression pattern without a detectable nucleophosmin 1 mutation. In two of these cases we found the chromosomal translocation t(3;5)(q25;q35) encoding the NPM-MLF1 fusion protein. In the other discrepant cases the aberrant cytoplasmic nucleophosmin staining and gene expression could not be explained. In total six patients (5%) had true discordant results between immunohistochemistry and mutation analysis. We conclude that cytoplasmic nucleophosmin localization is not always caused by a conventional nucleophosmin 1 mutation and that in the screening for nucleophosmin 1 abnormalities, most information will be obtained by combining immunohistochemistry with molecular analysis.

## Introduction

Mutations in the nucleophosmin gene (*NPM1*) are found in 30% of patients with acute myeloid leukemia (AML) and lead to aberrant accumulation of nucleophosmin protein in the cytoplasm.<sup>1</sup> Distinctive biological and clinical features can be observed in *NPM1*-mutated AML, including a unique gene expression profile, a distinct microRNA signature, low expression of CD34 in more than 95% of cases, an increased incidence of *FLT3* internal tandem duplications (ITD) in about 40% of cases, and a good response to induction chemotherapy.<sup>2-5</sup> *NPM1*-mutated AML was included as a provisional entity in the 2008 World Health Organization classification of myeloid neoplasms.<sup>6</sup>

Currently more than 40 different mutations in the *NPM1* gene have been identified.<sup>4</sup> All these variants lead to common changes at the C-terminus of the gene and cause aberrant dislocation of the NPM1 protein into the cytoplasm of AML blast cells. This feature of *NPM1*-mutated AML can be used

for diagnostic purposes. Indeed, immunohistochemical staining of NPM1 on bone marrow biopsies has been described to be fully predictive of *NPM1* mutations by two independent research groups.<sup>1,7,8</sup> The low costs and relative simplicity are important advantages of immunohistochemistry in diagnostic screening, especially if more sophisticated molecular techniques are not available. On the other hand, compared to molecular analyses, immunohistochemistry is more prone to inter-observer variability and variability due to technical issues. Indeed, in the study by Konoplev *et al.*<sup>9</sup> immunohistochemical staining was not completely predictive for *NPM1* mutations. Still, immunohistochemical staining is recommended as the technique of choice in simple front-line screening, with a reported sensitivity and specificity of 100% on B5-fixed and EDTA-decalcified bone marrow biopsies, and for the diagnosis of AML patients presenting with a “dry tap” or myeloid sarcoma.<sup>10,11</sup>

In this study, we assessed the sensitivity and specificity of immunohistochemistry on formalin-fixed bone marrow

©2013 Ferrata Storti Foundation. This is an open-access paper. doi:10.3324/haematol.2012.079806

The online version of this article has a Supplementary Appendix.

Manuscript received on October 21, 2012. Manuscript accepted on May 21, 2013.

Correspondence: c.m.woolthuis@umcg.nl.

biopsies compared with gold standard molecular analysis to predict *NPM1* mutation status in a large cohort of AML patients from our institution. The cases that were found to have a discrepancy between the two methods were extensively evaluated.

## Methods

### Patients

Bone marrow biopsies for immunohistochemical analysis and either peripheral blood or bone marrow aspirates for RNA isolation were obtained from untreated patients diagnosed with AML after obtaining informed consent. The study protocol was approved by the Medical Ethical Committee of the University Medical Center in Groningen.

### Immunohistochemical staining for NPM1

The immunohistochemical stains were performed on bone marrow biopsies that were fixed in 10% neutral phosphate-buffered formalin (3.6% formaldehyde) for at least 12 h, and decalcified in a solution containing 10% (v/v) acetic acid and 10% formalin (v/v; 3.6% formaldehyde) for 1 or 2 days. Detection of NPM1 localization was routinely performed on paraffin-embedded 3  $\mu$ m (and also 1-2  $\mu$ m for discrepant cases) tissue sections by immunohistochemical staining using a Benchmark XT immunostainer (Ventana Medical Systems S.A., Tucson, AZ, USA). The NPM1 antigen was retrieved with TRIS EDTA buffer (pH 8.5). Endogenous peroxidase was blocked with H<sub>2</sub>O<sub>2</sub>. Slides were incubated with 1:50 diluted supernatant of the anti-NPM1 antibody (clone 376, 1G3) (kindly provided by Prof. Falini, Perugia, Italy). NPM1 was visualized using an ultraview universal DAB detection kit (Ventana). The nucleolin antigen was retrieved with a TRIS EDTA buffer (pH 9.0). Anti-nucleolin antibody (C23, Santa Cruz, Dallas, TX, USA) was used at a dilution of 1:50 and visualized using horse-radish peroxidase-labeled rabbit-anti-mouse and goat-anti-rabbit antibodies (Dako, Copenhagen, Denmark) and 3,3'-diaminobenzidine (Sigma Aldrich, St Louis, MO, USA). The NPM1 and nucleolin stains were initially scored as being either exclusively nuclear or combined nuclear and cytoplasmic by an experienced hematopathologist (SR, AD or PMK).

### Molecular analysis of NPM1

Molecular *NPM1* mutation analysis was performed using reverse transcriptase polymerase chain reaction (RT-PCR) of exon-12 harboring most *NPM1* mutations.<sup>4</sup> cDNA fragment analysis was performed with a fluorescein-labeled forward primer (CTTC-CGGATGACTGACCAAGAG) and a reverse primer (CCTGGA-CAACATTTATCAAACACG). The fragment analysis was validated by sequencing the RT-PCR product for the first 100 patients' samples analyzed with fragment analysis, revealing 100% accuracy for detecting either two wild-type alleles (non-mutated *NPM1*) or a wild-type and mutated allele (*NPM1*-mutated). For the cases with cytoplasmic NPM1 staining but no mutation by fragment analysis, a further analysis of exons 9 and 11 was performed by RT-PCR using the forward primer AGCGCCAGTGAAGAAATC and the reverse primer CACGGTAGGGAAAGTTCTC and sequencing the PCR product.

### Quantitative real-time polymerase chain reaction analyses

Total RNA was isolated using an RNeasy kit from Qiagen (Venlo, The Netherlands) according to the manufacturer's recommendations. The presence of *NUP98/NSD1* and the reciprocal *NSD1/NUP98* translocations was determined by quantitative RT-PCR. Primer sequences and cycle conditions have been described

previously.<sup>12</sup> Samples known to express the *NUP98/NSD1* and the reciprocal *NSD1/NUP98* translocations were kindly provided by Dr. PJM Valk (Erasmus MC, Rotterdam, The Netherlands) and used as positive controls.

The sequences of the primers used for the quantitative RT-PCR analysis of various *HOX* genes, *MEIS1*, *PBX3*, *BAALC* and *MN1* and the housekeeping genes *RPL27* and *HPRT* are presented in *Online Supplementary Table S1*. All quantitative RT-PCR analyses were performed in triplicate and the mean expression of these triplicate analyses is indicated in the results.

### Fluorescence in situ hybridization

Cytogenetic and fluorescence *in situ* hybridization (FISH) studies were performed according to standard methods. All discrepant samples were screened for the t(3;5) *NPM-MLF1* gene fusion using FISH. Both interphase nuclei and metaphases were analyzed with the TLX3 Breakapart probe (CytoCell, LPH050, Cambridge, UK) and with the bacterial artificial chromosome (BAC) (RP11-117L6 chr:170,746,923 - 170,922,033), kindly provided by Prof. M. Rocchi (Department of Genetics and Microbiology, University of Bari, Italy) to confirm the presence of a break within the *NPM1* gene suggestive of a translocation t(3;5).<sup>13,14</sup>

## Results

### No complete concordance for immunohistochemical analysis on formalin-fixed bone marrow biopsies and molecular analysis for the detection of NPM1 mutations

Both immunohistochemical and RT-PCR analyses for NPM1 mutations were performed in a total of 119 patients diagnosed with AML between 2005 and 2010 in the University Medical Center Groningen. Patients with a t(8;21), t(15;17), inv(16) or t(16;16) were excluded, since *NPM1* mutations have been reported to be mutually exclusive with these cytogenetic abnormalities.<sup>15</sup> The patients' characteristics are shown in Table 1.

Screening for *NPM1* mutations by fragment analysis revealed mutated *NPM1* in 34 out of the 119 patients (29%). In the subgroup of patients with normal karyotype AML (n=68), 28 (41%) had an *NPM1* mutation by fragment analysis. Screening for NPM1 dislocation by immunohistochemistry on formalin-fixed bone marrow biopsies revealed cytoplasmic NPM1 in 33 out of the 119 patients (28%). However, five cases had mutant *NPM1* by fragment analysis but did not have characteristic cytoplas-

**Table 1. Patients' characteristics.**

Age (years)		
Mean	57	
Range	17-81	
Sex		
Female	52%	
Cytogenetic characteristics		
Normal karyotype	68	57%
Unfavorable	28	24%
Other	23	19%
<i>FLT3</i> mutation status		
<i>FLT3</i> wt	92	77%
<i>FLT3</i> -ITD	27	23%

wt: wild type; ITD: internal tandem duplication.

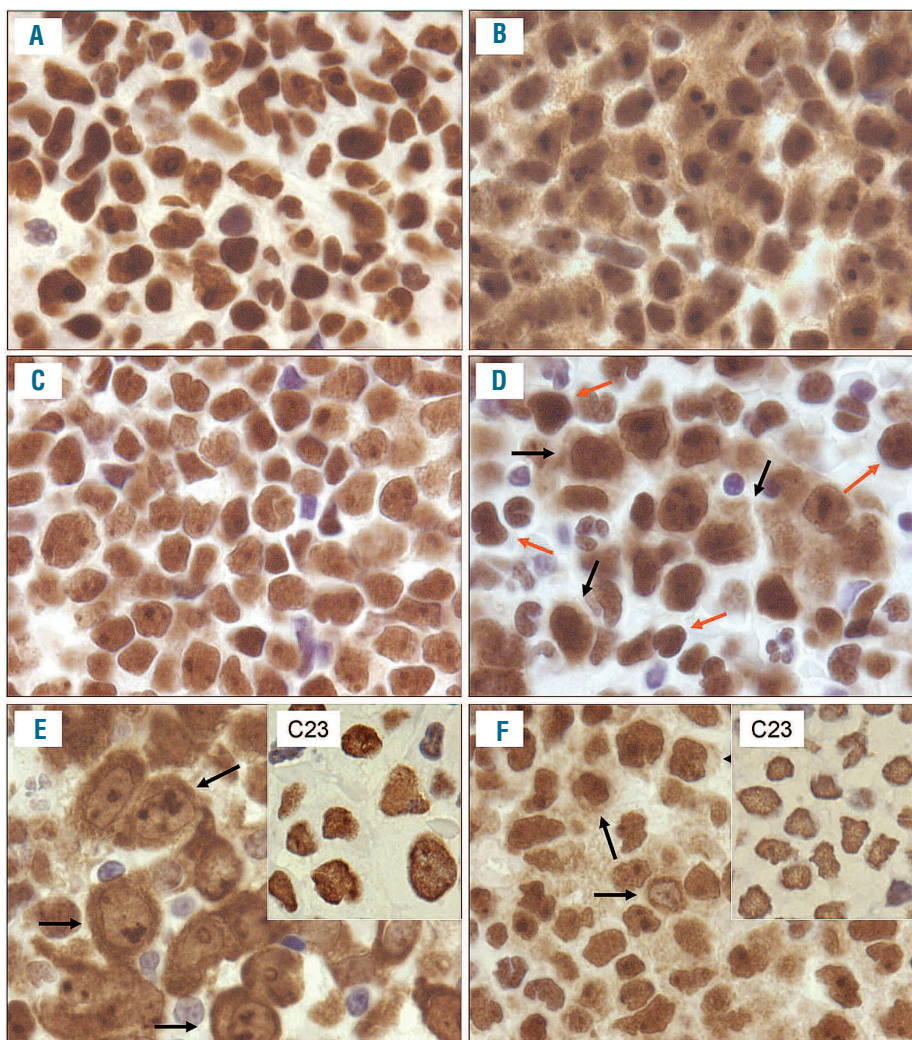
mic localization of NPM1 according to the initial immunohistochemistry studies used for diagnosis; conversely, in four cases, no *NPM1* mutation was detected by fragment analysis although immunohistochemistry showed cytoplasmic localization of NPM1 (Figure 1, *Online Supplementary Figure S1*, Table 2).

All cases with discordant results were analyzed in more depth. Since mutations of exons 9 and 11 of the *NPM1* gene have been described to occur in rare cases,<sup>15,16</sup> we performed additional sequencing analysis of exons 9, 11 and 12 for those four AML cases exhibiting cytoplasmic NPM1 by immunohistochemistry but no mutation by fragment analysis. This analysis did not reveal any mutations. Recently, a patient was reported with mutated *NPM1* detected by molecular analysis but predominant nuclear NPM1 by immunohistochemistry with faint localization in the cytoplasm.<sup>17</sup> It was suggested that the amino acids at position 270 and 272 could be important for proper sub-cellular localization of NPM1. The types of *NPM1* mutations found in our discrepant cases are shown in *Online Supplementary Table S2*. All these mutations were found in exon 12 of the *NPM1* gene and did not resemble the mutation described by Pianta and colleagues.

Further analysis of the five discrepant cases included re-cutting tissue sections at 1-2  $\mu\text{m}$  and microscopic analysis

at 100x magnification. In two discordant cases with a proven mutation, blast cells again showed exclusively nuclear staining (cases 1 and 4 in Table 2; Figure 1 and *Online Supplementary Figure S1*). In one case of AML with signs of differentiation (FAB M2), a minority of cells, probably the blasts, showed cytoplasmic staining (case 3), which had been overlooked in the original analysis of the thicker tissue sections. In an additional case with AML with multilineage dysplasia, previously classified as AML M6 (case 2), only small clusters of myeloblasts showed cytoplasmic staining. Finally as regards the fifth discrepant case, a patient with unclassifiable AML (dry tap due to extensive sclerosis) and very few circulating blasts, the biopsy used for the original analysis showed only nuclear staining. However, a biopsy taken one day earlier in the referring hospital, and only analyzed at the re-assessment, convincingly showed cytoplasmic staining in apparently more blastic cells with larger nuclei and bigger nucleoli (case 5, *Online Supplementary Figure S1*). Altogether, after re-analysis using 1-2  $\mu\text{m}$  sections of the five discrepant cases with detectable mutations of *NPM1* without cytoplasmic staining, only two cases remained discrepant.

In the group of four discordant cases with cytoplasmic staining of NPM1 but no detectable mutation (cases 6-9 in Table 2), cytoplasmic staining was very strong in one case



**Figure 1.** Immunohistochemistry for NPM1. Representative examples of immunohistochemical staining of AML cases are shown. (A) A case with strict nuclear staining of NPM1 and wild-type *NPM1* by fragment analysis; (B) a case with nuclear and cytoplasmic staining of NPM1 and an *NPM1* mutation by fragment analysis; (C) a discrepant case (case 1, Table 2) with strict nuclear staining but an *NPM1* mutation found by fragment analysis; (D) a discrepant case (case 2, Table 2) with a minor population of blasts with combined nuclear and cytoplasmic staining (black arrows) and many other cells with exclusively nuclear staining (orange arrows). The blasts with cytoplasmic expression had been overlooked at the initial screening; (E) a discrepant case (case 6, Table 2) with both nuclear and very strong cytoplasmic staining but no *NPM1* mutation found by molecular analysis; (F) a discrepant case (case 8, Table 2) with nuclear and cytoplasmic staining with a  $t(3;5)(q23;q3?3)$  likely involving *NPM1*. The inserts for cases 6 (E) and 8 (F) show exclusively nuclear staining for the nucleolin protein as detected with the C23 antibody. All photographs were taken with a 100x oil immersion lens.

(case 6) and fuzzy to granular in cases 8 and 9, whereas cytoplasmic staining of a very limited population of blasts was observed in case 7 (Figure 1). Immunohistochemistry studies for nucleolin were performed to exclude artifacts, i.e. abnormal general diffusion of nuclear proteins into the cytoplasm leading to false positive immunohistochemical results. Such artifacts were not observed (Figure 1).

To analyze the impact of the staining technique, all discrepant cases were re-analyzed using APAAP in the visualization of NPM1 in immunohistochemistry. The results are shown in *Online Supplementary Figure S1* and were in accordance with the results obtained by DAB visualization. After re-analysis of the four discrepant cases with cytoplasmic staining of NPM1 without detectable mutation all these cases remained discrepant.

### Cases of acute myeloid leukemia with discordant immunohistochemical and molecular results of NPM1 mutation analyses have high expression of HOXA and HOXB genes

Patients with *NPM1*-mutated AML are considered a specific subgroup based on distinct clinical as well as biological characteristics.<sup>1,4,5,18-20</sup> One of these features is a specific gene expression profile, characterized by strongly increased expression of *HOX* genes from both the A and B cluster, *MEIS1* and *PBX3* and down-regulation of *CD34* compared to the expression of these genes in AML samples with wild-type *NPM1*.<sup>2,5,21</sup> The (re)activation of a stem cell-like *HOX* gene signature in *NPM1*-mutated AML has been hypothesized to contribute to the leukemic transformation. We wondered whether the discordant AML cases had a specific expression profile for these genes and performed quantitative RT-PCR studies for the expression of several *HOXA/HOXB* genes, *MEIS1*, *PBX3*, *BAALC* and *MN1*. The tested cases (1-4 from Table 2) with nuclear staining of NPM1 by immunohistochemistry but an *NPM1* mutation by fragment analysis showed the gene expression profile expected for *NPM1*-mutated AML (Figure 2), suggesting that these cases were true false negative cases as assessed by immunohistochemistry. More interestingly, the gene expression patterns of three out of the four AML cases with cytoplasmic

*NPM1* by immunohistochemistry but no detectable *NPM1* mutation by fragment analysis also closely resembled those of *NPM1*-mutated AML with high *HOXA*, *HOXB* and *MEIS1* mRNA expression (Figure 2). The fourth case (case 7 in Table 2) demonstrated high expression of the *HOXA* genes and *MEIS1*, but low expression of *HOXB5*. Since the latter gene expression pattern is frequently observed in AML with *MLL* translocations,<sup>22</sup> we used FISH to test for abnormalities of chromosome 11 (q23.1) but these were not detected. Recently, Hollink *et al.*<sup>12</sup> described a group of AML with *NUP98/NSD1* translocations and a *HOX* gene expression pattern resembling the gene expression pattern of *NPM1*-mutated cases. We screened all discordant patients, including those with high *HOXA* and *HOXB* expression, for *NUP98/NSD1* by a specific RT-PCR. This revealed no *NUP98/NSD1* expression in these cases.

### NPM-MLF1 gene fusion detected in two out of four discrepant cases with cytoplasmic NPM1 but no detectable NPM1 mutation

Our analysis so far identified four AML cases (cases 6-9 in Table 2) with cytoplasmic NPM1 staining by immunohistochemistry, in the absence of an *NPM1* mutation detected by molecular analysis. It has been described that cytoplasmic NPM1 staining can be observed in cases without a conventional *NPM1* mutation, but in the presence of the rare chromosomal translocation t(3;5)(q25;q35).<sup>23</sup> This translocation generates the chimeric gene named NPM-myelodysplasia/myeloid leukemia factor 1 (*NPM-MLF1*) encoding the NPM-MLF1 fusion protein.<sup>24</sup> The mechanism explaining the cytoplasmic NPM1 dislocation in these cases remains to be clarified. We tested the discrepant cases in our study demonstrating cytoplasmic NPM1 staining, but no *NPM1* mutation for the *NPM-MLF1* gene translocation by FISH using the RP11-117L6 and the TLX3 Break apart probe. This analysis revealed the presence of a break within the *NPM1* gene highly suggestive of an *NPM-MLF1* gene translocation in two out of four discrepant cases (cases 8 and 9 in Table 2, Figure 3).

**Table 2.** Characteristics of the AML cases for which immunohistochemistry and fragment analysis for the detection of NPM1 mutations gave discrepant results.

N.	FA	Initial IHC	Revised IHC	Age	Karyotype	FLT3	WBC	FAB	WHO
1	mut	nuc	nuc	71	NK	ITD	23	M1	AML without maturation
2	mut	nuc	hetero*	70	+8	ITD	5	M6	AML with multilineage dysplasia
3	mut	nuc	hetero*	53	NK	wt	6	M2	AML with maturation
4	mut	nuc	nuc	64	NK	wt	5	dry tap	dry tap
5	mut	nuc	hetero**	41	NK	ITD	3	dry tap	dry tap
6	wt	nuc+cyt	nuc+cyt	64	NK	wt	13	M6	AML with multilineage dysplasia
7	wt	nuc+cyt	nuc+cyt	52	del 8p,del 9q,add 16p	wt	47	M5	therapy related AML
8	wt	nuc+cyt	nuc+cyt	60	t(3;5)(q23;q373), +8	ITD	190	M2	AML with maturation
9	wt	nuc+cyt	nuc+cyt	45	t(3;5)(q23;q373), +8	wt	66	M5	AML with multilineage dysplasia

FA: fragment analysis; mut: mutated; wt: wild-type; IHC: immunohistochemistry; nuc: nuclear staining; cyt: cytoplasmic staining; hetero: heterogeneous staining pattern; ITD: internal tandem duplication; WBC: white blood cell count ( $\times 10^9/L$ ); FAB: French-American-British classification; WHO: World Health Organization classification of myeloid neoplasms; NK: normal karyotype; D, no T: dead without treatment; D, D: died of progressive disease; D, TRM: treatment-related death; y, year. \*Heterogeneous pattern with only small clusters of myeloblasts showing cytoplasmic staining; \*\*Heterogeneous pattern with first biopsy showing nuclear and cytoplasmic staining, but a second biopsy showing only nuclear staining.

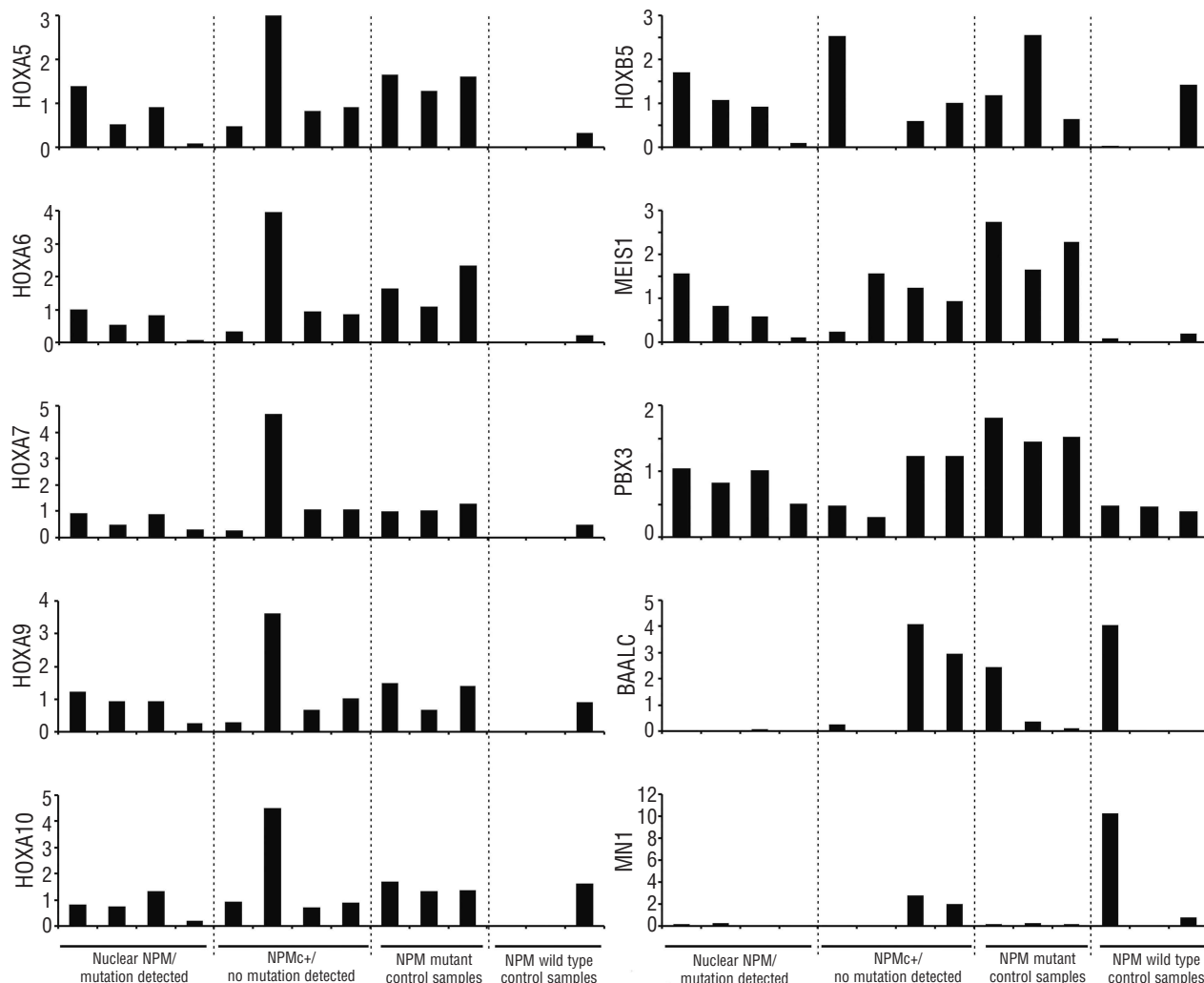
**Discussion**

The aim of this study was to evaluate the value of immunohistochemistry on formalin-fixed bone marrow biopsies and molecular analysis for the detection of *NPM1* mutations and further characterize the cases for which the two techniques gave discrepant results. We observed a high percentage of concordance between the two methods of mutation detection. Nevertheless, results were discordant in a small subgroup of patients (5% in the studied cohort).

To analyze the possible effects of inter-observer variability in the use of immunohistochemistry, a cohort of 50 patients, including all cases that showed discordant results by immunohistochemistry and fragment analysis, were re-scored blindly and independently by three hematopathologists and later discussed in a panel session. All nine cases remained discordant after this procedure (*data not shown*).

Previously, Falini and colleagues reported that immunohistochemical analysis had 100% specificity and sensitivi-

ty for the detection of mutated *NPM1*.<sup>7</sup> The superiority of their results might be explained by a difference in fixation technique, i.e. B5 fixation instead of formalin fixation. The B5 fixation technique used for hematopoietic tissues is well known for its superior morphological detail compared to formalin fixation. However, this technique has disadvantages, including difficulties with antigen retrieval for some antibodies (e.g. CD30, cyclin D1) and limitations to molecular studies. Moreover, the fixation can be problematic with respect to safety and disposal requirements in the laboratory, since B5 contains mercuric chloride. Consequently, most pathology laboratories currently use purely formalin-based fixation techniques, which provide a safe alternative.<sup>25</sup> In view of these considerations, all biopsies of the nine initially discordant cases were re-cut for thinner tissue sections and re-analyzed at higher magnification. Furthermore, an additional biopsy taken in the referring hospital was included for re-analysis. In three of the five cases with initially nuclear staining but proven *NPM1* mutations and a gene expression pattern characteristic of *NPM1*-mutated AML, we observed either a minor



**Figure 2.** Gene expression of discrepant cases. Results of quantitative RT-PCR of *HOX* genes, *MEIS1*, *PBX3*, *BAALC* and *MN1* for the AML cases with discordant finding between immunohistochemistry and fragment analysis for the detection of *NPM1* mutations. The graphs show relative mRNA expression of the indicated genes compared to the mean expression of the housekeeping genes *RPL27* and *HPRT*. The first eight bars from left to right in each graph represent the data from cases 1-4 and 6-9 according to Table 2.

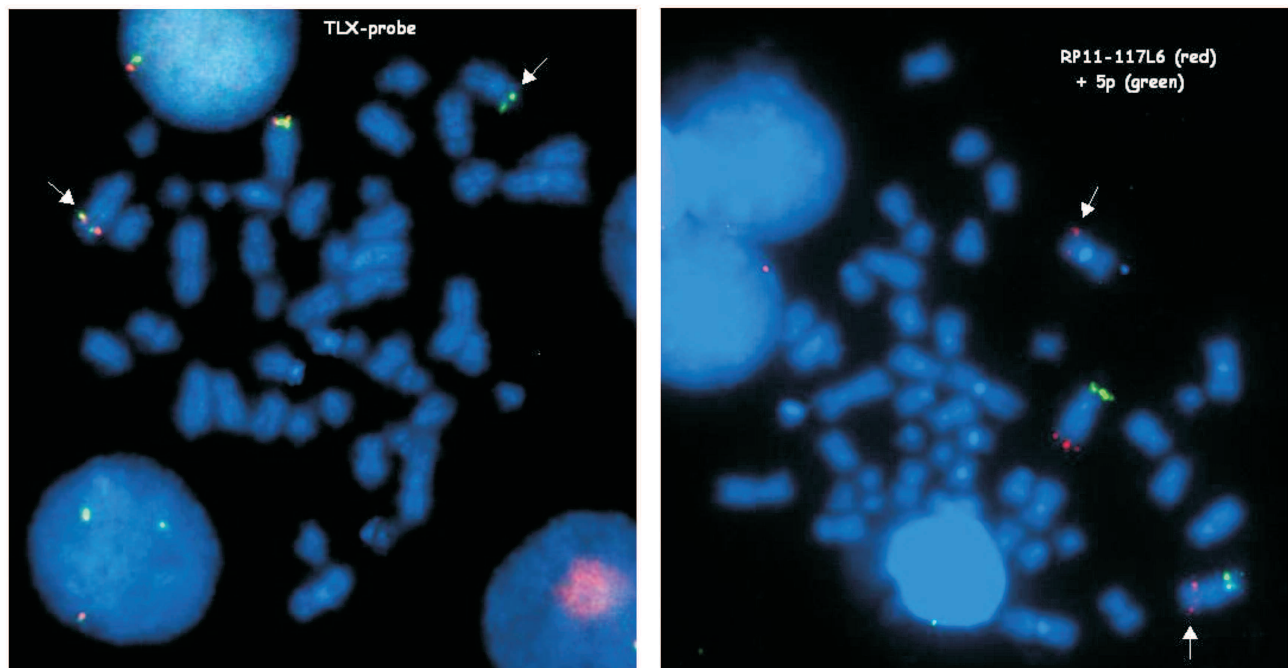
subpopulation with cytoplasmic staining or a discordance between two subsequent biopsies (Table 2). Only in two cases did the blasts again show exclusively nuclear NPM1 staining. This suggests that fixation and histotechnical factors may indeed contribute to the generation of false negative staining results. Differences in fixation, decalcification and staining procedures, leading to difficulties in microscopic evaluation, have also been addressed in previously published studies.<sup>1,7-9,11</sup> However, additional studies directly comparing different fixation techniques are necessary to assess the relevance of the fixation technique.

In addition to technical issues, characteristics of the AML blasts might also be important. We observed false negative results in a case of AML with myeloid maturation and one with a large component of erythroblasts. The cytoplasmic pattern of NPM1 is generally most prominent in myeloblasts and monoblasts as well as early erythroblasts. Indeed, cytoplasmic staining may be very weak or absent in more mature cells and might be below detection levels or more easily overlooked, especially in AML cases with M5b morphology.<sup>26</sup> Moreover, as is also illustrated by the results of this study, in rare cases only a very small population of blasts with cytoplasmic staining might be present.

The detection of mutant NPM1 could be improved by applying an antibody specific for mutant NPM1. An NPM1-mutant specific antibody has been generated for use in western blot analysis.<sup>27</sup> However, to the best of our knowledge, no such antibody is available for immunohistochemistry. Importantly, none of the cases with mutated NPM1 without overt cytoplasmic staining demonstrated the frameshift mutation, leading to a truncated protein, as was described by Pianta *et al.*<sup>17</sup> Nevertheless, the reported truncated protein illustrates that not all identified NPM1

mutants are necessarily associated with overt cytoplasmic localization of NPM1.

The four cases with cytoplasmic NPM1 without detectable *NPM1* mutation demonstrated the typical elevated expression of *HOX* and *MEIS1* genes, which has been shown to be associated with *NPM1*-mutated AML, suggesting that these cases do not reflect regular *NPM1* germline AML. It could, therefore, be argued that immunohistochemistry should be applied to identify these rare, but interesting cases. Rare mutations in exons 9 and 11 of the *NPM1* gene were excluded by sequencing. In two out of the four discrepant cases, analysis of the FISH results was highly suggestive of the rare chromosomal translocation t(3;5)(q25;q35) encoding the NPM-MLF1 fusion protein. This finding is in line with that of a previous study describing aberrant cytoplasmic NPM1 localization in AML cases carrying a t(3;5).<sup>23</sup> In this study AML with t(3;5) was reported to account for only 0.25% of all AML in adults aged between 15 and 60 years old. In our complete cohort of 119 cases, t(3;5) was found in 3% of all analyzed cases. Two out of these four cases demonstrated cytoplasmic NPM1. The exact breakpoints of the other two cases were not analyzed in detail. It is currently unknown how *NPM-MLF1* results in cytoplasmic expression. Apparently, not only the presence of a new NES motif in *NPM1* is required to cause cytoplasmic dislocation. For two out of four cases we could not find an explanation for the aberrant cytoplasmic NPM1 staining. This staining does not seem to represent an artifact because it could be reproduced; furthermore, one of the two cases had a gene expression pattern compatible with *NPM1*-mutated AML and the other demonstrated high expression of *HOXA* genes and *MEIS1* (albeit with low *HOXB5*



**Figure 3.** FISH analysis for *NPM-MLF1* translocation. On the left, results of metaphase FISH analysis of an AML case with a split in the *TLX3* gene on chromosome 5q35. Spectrum red and green *TLX3* breakapart probe (Cytocell, LPH, 050). On the right, metaphase FISH analysis of an AML case with a split in the *NPM1* gene on chromosome 5q35. Spectrum red *NPM1* specific BAC (RP11-117L6) and spectrum green specific BAC (RP11-600N9; control on 5p15.33). The pictures show results of the FISH analysis of case 8 from Table 2.

expression). Thus, it is very possible that there is a small subgroup of AML cases that present cytoplasmic NPM1 localization of (yet) unknown origin. Taken together these data illustrate that, when screening for *NPM1* abnormalities, most information can be obtained by combining immunohistochemistry with molecular analysis. Therefore, if possible, both techniques should be performed in parallel. Nevertheless, immunohistochemistry for NPM1 could still represent a reasonable screening procedure for laboratories in developing countries that are not equipped for molecular studies.

The terms *NPM1*-mutated and *NPMc*<sup>+</sup> are often used interchangeably. Our data and those of others<sup>9,23</sup> suggest that cytoplasmic NPM1 localization is not always caused by a conventional *NPM1* mutation, but can also be caused by t(3;5)(q25;q35) and possibly by other abnormalities. Moreover, cases with mutated *NPM1* do not always show overt cytoplasmic staining of NPM1 on formalin-fixed bone marrow biopsies. Nevertheless, even when performed on formalin-fixed bone marrow biopsies, immunohistochem-

istry has a high specificity and sensitivity for the detection of mutated *NPM1*. In view of the occasional discrepant results between immunohistochemistry and molecular analysis, we would recommend that the routine detection of *NPM1* mutations in newly diagnosed AML patients should optimally be based on both immunohistochemical and molecular analyses. When immunohistochemical methods on formalin-fixed bone marrow biopsies are used, 1-2  $\mu$ m tissue sections are preferred. Further studies are needed to elucidate the relevance of different factors that might contribute to discordant results between immunohistochemical and molecular analyses. In addition, the clinical relevance of the discrepancies between immunohistochemical and molecular detection of *NPM1* mutations will be an important issue for further research.

#### Authorship and Disclosures

Information on authorship, contributions, and financial & other disclosures was provided by the authors and is available with the online version of this article at [www.haematologica.org](http://www.haematologica.org).

#### References

- Falini B, Mecucci C, Tiacci E, Alcalay M, Rosati R, Pasqualucci L, et al. Cytoplasmic nucleophosmin in acute myelogenous leukemia with a normal karyotype. *N Engl J Med*. 2005;352(3):254-66.
- Alcalay M, Tiacci E, Bergomas R, Bigerna B, Venturini E, Minardi SP, et al. Acute myeloid leukemia bearing cytoplasmic nucleophosmin (NPMc<sup>+</sup> AML) shows a distinct gene expression profile characterized by up-regulation of genes involved in stem-cell maintenance. *Blood*. 2005;106(3):899-902.
- Dohner K, Schlenk RF, Habdank M, Scholl C, Rucker FG, Corbacioglu A, et al. Mutant nucleophosmin (NPM1) predicts favorable prognosis in younger adults with acute myeloid leukemia and normal cytogenetics: interaction with other gene mutations. *Blood*. 2005;106(12):3740-6.
- Falini B, Nicoletti I, Martelli MF, Mecucci C. Acute myeloid leukemia carrying cytoplasmic/mutated nucleophosmin (NPMc<sup>+</sup> AML): biologic and clinical features. *Blood*. 2007;109(3):874-85.
- Verhaak RG, Goudswaard CS, van Putten W, Bijl MA, Sanders MA, Hagens W, et al. Mutations in nucleophosmin (NPM1) in acute myeloid leukemia (AML): association with other gene abnormalities and previously established gene expression signatures and their favorable prognostic significance. *Blood*. 2005;106(12):3747-54.
- Vardiman JW, Thiele J, Arber DA, Brunning RD, Borowitz MJ, Porwit A, et al. The 2008 revision of the World Health Organization (WHO) classification of myeloid neoplasms and acute leukemia: rationale and important changes. *Blood*. 2009;114(5):937-51.
- Falini B, Martelli MF, Bolli N, Bonasso R, Ghia E, Pallotta MT, et al. Immunohistochemistry predicts nucleophosmin (NPM) mutations in acute myeloid leukemia. *Blood*. 2006;108(6):1999-2005.
- Luo J, Qi C, Xu W, Kamel-Reid S, Brandwein J, Chang H. Cytoplasmic expression of nucleophosmin accurately predicts mutation in the nucleophosmin gene in patients with acute myeloid leukemia and normal karyotype. *Am J Clin Pathol*. 2010;133(1):34-40.
- Konoplev S, Huang X, Drabkin HA, Koeppen H, Jones D, Kantarjian HM, et al. Cytoplasmic localization of nucleophosmin in bone marrow blasts of acute myeloid leukemia patients is not completely concordant with NPM1 mutation and is not predictive of prognosis. *Cancer*. 2009;115(20):4737-44.
- Falini B, Lenze D, Hasserjian R, Coupland S, Jaehne D, Soupir C, et al. Cytoplasmic mutated nucleophosmin (NPM) defines the molecular status of a significant fraction of myeloid sarcomas. *Leukemia*. 2007;21(7):1566-70.
- Falini B, Martelli MF, Pileri SA, Mecucci C. Molecular and alternative methods for diagnosis of acute myeloid leukemia with mutated NPM1: flexibility may help. *Haematologica*. 2010;95(4):529-34.
- Hollink IH, van den Heuvel-Eibrink MM, rensen-Peters ST, Pratorcorona M, Abbas S, Kuipers JE, et al. NUP98/NSD1 characterizes a novel poor prognostic group in acute myeloid leukemia with a distinct HOX gene expression pattern. *Blood*. 2011;118(13):3645-56.
- Ammatuna E, Panetta P, Agirre X, Ottone T, Lavorgna S, Calasanz MJ, et al. NPM1 gene deletions in myelodysplastic syndromes with 5q- and complex karyotype. *Haematologica*. 2011;96(5):784-5.
- Berger R, Busson M, Baranger L, Helias C, Lessard M, Dastugue N, et al. Loss of the NPM1 gene in myeloid disorders with chromosome 5 rearrangements. *Leukemia*. 2006;20(2):319-21.
- Albiero E, Madeo D, Bolli N, Giaretta I, Bona ED, Martelli MF, et al. Identification and functional characterization of a cytoplasmic nucleophosmin leukaemic mutant generated by a novel exon-11 NPM1 mutation. *Leukemia*. 2007;21(5):1099-103.
- Mariano AR, Colombo E, Luzi L, Martinelli P, Volorio S, Bernard L, et al. Cytoplasmic localization of NPM in myeloid leukemias is dictated by gain-of-function mutations that create a functional nuclear export signal. *Oncogene*. 2006;25(31):4376-80.
- Pianta A, Fabbro D, Damiani D, Tiribelli M, Fanin R, Franzoni A, et al. Unexpected phenotype of a typical NPM1 mutant. *Br J Haematol*. 2009;147(5):760-3.
- Garzon R, Garofalo M, Martelli MF, Briesewitz R, Wang L, Fernandez-Cymering C, et al. Distinctive microRNA signature of acute myeloid leukemia bearing cytoplasmic mutated nucleophosmin. *Proc Natl Acad Sci USA*. 2008;105(10):3945-50.
- Schnittger S, Schoch C, Kern W, Mecucci C, Tschulik C, Martelli MF, et al. Nucleophosmin gene mutations are predictors of favorable prognosis in acute myelogenous leukemia with a normal karyotype. *Blood*. 2005;106(12):3733-9.
- Thiede C, Koch S, Creutzig E, Steudel C, Illmer T, Schaich M, et al. Prevalence and prognostic impact of NPM1 mutations in 1485 adult patients with acute myeloid leukemia (AML). *Blood*. 2006;107(10):4011-20.
- Woolthuis CM, Han L, Verkaik-Schakel RN, van GD, Kluin PM, Vellenga E, et al. Downregulation of MEIS1 impairs long-term expansion of CD34<sup>+</sup> NPM1-mutated acute myeloid leukemia cells. *Leukemia*. 2012;26(4):848-53.
- Hess JL. MLL: a histone methyltransferase disrupted in leukemia. *Trends Mol Med*. 2004;10(10):500-7.
- Falini B, Bigerna B, Pucciarini A, Tiacci E, Mecucci C, Morris SW, et al. Aberrant subcellular expression of nucleophosmin and NPM-MLF1 fusion protein in acute myeloid leukaemia carrying t(3;5): a comparison with NPMc<sup>+</sup> AML. *Leukemia*. 2006;20(2):368-71.
- Yoneda-Kato N, Look AT, Kirstein MN, Valentine MB, Raimondi SC, Cohen KJ, et al. The t(3;5)(q25.1;q34) of myelodysplastic syndrome and acute myeloid leukemia produces a novel fusion gene, NPM-MLF1. *Oncogene*. 1996;12(2):265-75.
- Bonds LA, Barnes P, Foucar K, Sever CE. Acetic acid-zinc-formalin: a safe alternative to B-5 fixative. *Am J Clin Pathol*. 2005;124(2):205-11.
- Pasqualucci L, Liso A, Martelli MF, Bolli N, Pacini R, Tabarrini A, et al. Mutated nucleophosmin detects clonal multilineage involvement in acute myeloid leukemia: Impact on WHO classification. *Blood*. 2006;108(13):4146-55.
- Martelli MF, Manes N, Liso A, Pettirossi V, Verducci Galletti B, Bigerna B, et al. A western blot assay for detecting mutant nucleophosmin (NPM1) proteins in acute myeloid leukaemia. *Leukemia*. 2008;22(12):2285-8.