

University of Groningen

The use of a coded healing abutment as an impression coping to design and mill an individualized anatomic abutment

Telleman, Gerdien; Raghoobar, Gerry M.; Vissink, Arjan; Meijer, Henny J. A.

Published in:
Journal of Prosthetic Dentistry

IMPORTANT NOTE: You are advised to consult the publisher's version (publisher's PDF) if you wish to cite from it. Please check the document version below.

Document Version
Publisher's PDF, also known as Version of record

Publication date:
2011

[Link to publication in University of Groningen/UMCG research database](#)

Citation for published version (APA):

Telleman, G., Raghoobar, G. M., Vissink, A., & Meijer, H. J. A. (2011). The use of a coded healing abutment as an impression coping to design and mill an individualized anatomic abutment: a clinical report. *Journal of Prosthetic Dentistry*, 105(5), 282-285.

Copyright

Other than for strictly personal use, it is not permitted to download or to forward/distribute the text or part of it without the consent of the author(s) and/or copyright holder(s), unless the work is under an open content license (like Creative Commons).

The publication may also be distributed here under the terms of Article 25fa of the Dutch Copyright Act, indicated by the "Taverne" license. More information can be found on the University of Groningen website: <https://www.rug.nl/library/open-access/self-archiving-pure/taverne-amendment>.

Take-down policy

If you believe that this document breaches copyright please contact us providing details, and we will remove access to the work immediately and investigate your claim.

Downloaded from the University of Groningen/UMCG research database (Pure): <http://www.rug.nl/research/portal>. For technical reasons the number of authors shown on this cover page is limited to 10 maximum.



THE USE OF A CODED HEALING ABUTMENT AS AN IMPRESSION COPING TO DESIGN AND MILL AN INDIVIDUALIZED ANATOMIC ABUTMENT: A CLINICAL REPORT

Gerdien Telleman, DDS,^a Gerry M. Raghoebar, DMD, MD, PhD,^b Arjan Vissink DMD, MD, PhD,^c and Henny J. A. Meijer, DDS, PhD^d

University Medical Center Groningen, University of Groningen, Groningen, The Netherlands

A coded implant healing abutment makes an impression at the implant level no longer necessary. An impression is made of the healing abutment, which is placed onto the implant directly after implant placement. The codes embedded in the occlusal surface of the healing abutment provide essential information for the computer software to place the implant analog in the definitive cast and to design and mill the definitive abutment. (*J Prosthet Dent* 2011;105:181-185)

An implant impression is the negative copy of the dental implant platform and surrounding tissues needed to fabricate the prosthesis. Two different implant impression techniques are commonly applied, the open tray technique, using impression copings that have to be screwed on and off the implants, and the transfer or closed tray impression technique, in which the copings are placed back into the impression after removal. The authors of a systematic review indicated that, when an impression of 3 or fewer implants is made, there is no difference between the open and closed tray techniques; whereas for 4 or more implants, there is a higher accuracy with the open tray technique.¹

To combine the principles of the open and closed tray impression techniques, some implant manufacturers have developed snap-on plastic impression caps or press-fit metal copings.^{2,3} With this technique, a closed tray is used, but the copings are removed along with the impression. An advantage of the plastic impression copings is the opportunity to modify the copings when implants converge

or are placed too close together.⁴ However, several authors stated that metal impression copings are more accurate than plastic impression caps.^{2,4}

A disadvantage of all the previously described impression techniques is that the healing abutments have to be removed and the impression copings placed. All of this takes time and introduces the possibility of incorrectly placing the impression copings. To shorten chair time and to minimize the chance of impression coping-implant misfit, the coded healing abutment (Encode; Biomet 3i, Palm Beach Gardens, Fla) was designed. With this system, implant impressions can be made of the healing abutments when making implant-level impressions. The manufacturer states that special codes embedded in the occlusal surface of the healing abutment provide information (implant depth, hex orientation, implant angulation, platform diameter, and internal connection or external interface) that is essential to seat the implant analog in the definitive cast, as well as to design and mill the definitive individualized

abutment (Fig. 1). Preliminary clinical results of CAD/CAM-fabricated individualized abutments of this restorative system indicate better tissue response and reduced clinical chair time when compared to prefabricated abutments.⁴⁻⁸


Until recently, it was not possible to place the individualized abutment on the implant analog in the definitive cast. As a result, a second implant-level impression was necessary to place the implant analog in the definitive cast. Recently, a technique was developed using CAD to drill a hole in the definitive cast, and create a space into which the implant analog is placed. Figure 2 shows the device that drills the hole and places the implant analog (Robocats Technology; Biomet 3i). This technique makes it is no longer necessary to make a second implant-level impression. This article describes the treatment of a congenitally missing second mandibular premolar with an implant and a CAD/CAM-fabricated individualized abutment with an optimal emergence profile using a coded healing abutment.

^aAssistant professor, Department of Oral and Maxillofacial Surgery and Centre for Dentistry and Oral Hygiene.

^bProfessor, Department of Oral and Maxillofacial Surgery.

^cProfessor, Department of Oral and Maxillofacial Surgery.

^dProfessor, Department of Oral and Maxillofacial Surgery and Centre for Dentistry and Oral Hygiene.



1 Coded healing abutment consists of 2 pieces: screw and abutment (lateral view in upper figure). Special notches on occlusal surface are shown in lower part of figure. Reproduced with permission of Biomet 3i, Palm Beach Gardens, Florida.



2 Device that drills hole in definitive cast and places implant analog. Device is connected to computer, which has information from coded healing abutment. Reproduced with permission of Biomet 3i, Palm Beach Gardens, Florida.

CLINICAL REPORT

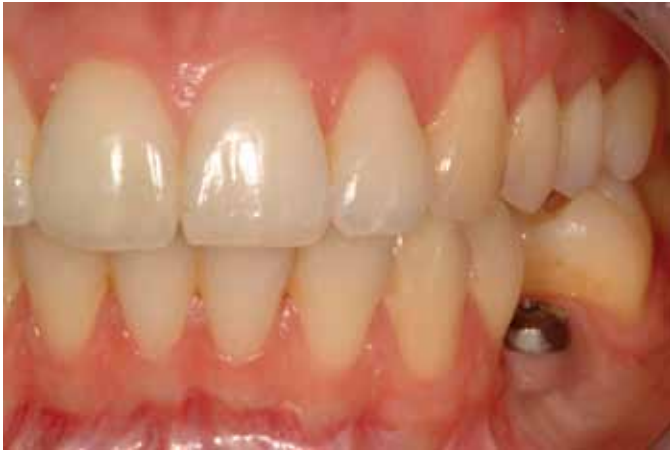A healthy, non-smoking 23-year-old woman presented for correction of the vertical overlap and crowding of the maxillary anterior teeth, as well as the replacement of a congenitally missing second mandibular premolar.

Extraoral examination revealed a mandibular retrognathia, profound plica mentalis, and a relatively prominent chin. Intraoral examination revealed a healthy, well-maintained den-

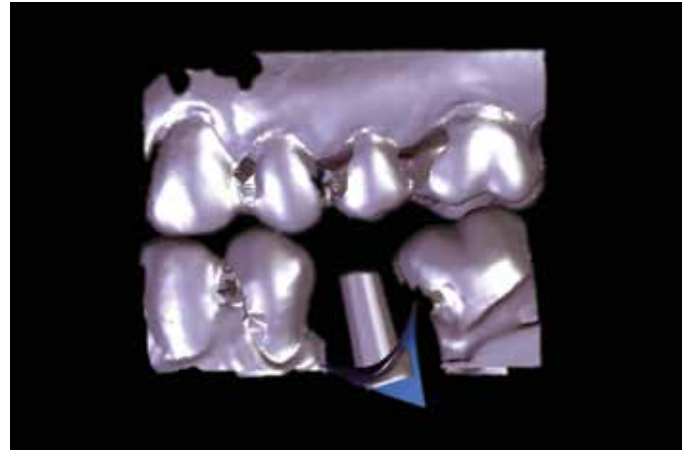
tition. Because of the missing second mandibular premolar, the molars had shifted mesially. Radiographically, no pathology of bone or teeth was noted.

As an adult, the patient's mandibular retrognathia and crowding could not be corrected by orthodontic treatment alone. Therefore, the patient was subjected to combination surgery (bilateral sagittal split osteotomy) and pre- and postorthodontic treatment. There remained several treatment options for the missing

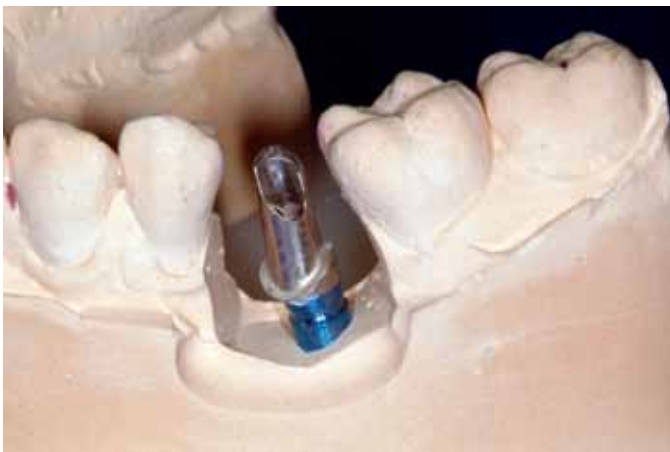second mandibular premolar. The first and second left molars could be orthodontically moved mesially into the diastema related to the missing premolar. Space could be created orthodontically to place an adhesive or conventional fixed partial dental prosthesis, or an endosseous implant could be placed in the left mandible to complete the treatment. For reasons of symmetry, tooth preservation, and predictable treatment, the option of an implant placement was chosen. The patient agreed with the suggested treatment and began orthodontic therapy. After one year of orthodontic treatment, the bilateral sagittal split osteotomy was performed. Meanwhile the left mandibular molars were distalized orthodontically, creating space for placement of a dental implant. As there was insufficient bone in the horizontal dimension to place an implant, the patient was scheduled for an augmentation procedure at the same time as the bilateral sagittal split osteotomy. The augmentation procedure was performed with bone from the left retromolar region.⁹ The autogenous bone graft was stabilized with a titanium screw (Gebrüder Martin GmbH & Co. KG, Tuttlingen, Germany). After a 3-month healing period, a diagnostic cast was made with a diagnostic waxing representing the future implant crown in ideal position. A transparent acrylic resin (Orthocryl; Dentaaurum GmbH & Co. KG, Ispringen, Germany) template of the diagnostic cast was fabricated for use as a surgical guide. One day before implant placement, the patient began the use of an aqueous 0.2% chlorhexidine mouth rinse (Corsodyl, Glaxo-SmithKline, Zeist, The Netherlands) (1 minute, 3 times daily for 2 weeks) for oral disinfection. One hour before surgery, the patient took antibiotics (amoxicillin 500 mg, 6 tablets). After the administration of local anesthesia (Ultracaine D-S Forte; Aventis Pharma Deutschland GmbH, Frankfurt, Germany) an incision was made crestally. A mucoperiosteal flap was elevated to expose the alveolar crest



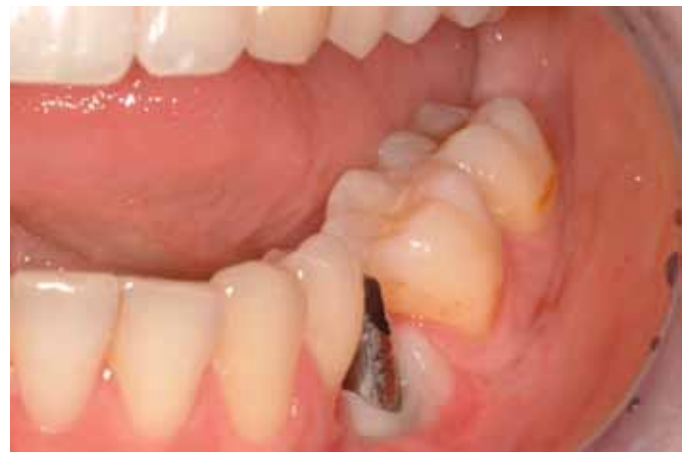3 Buccal view of healing abutment.



4 Computer-assisted design image of abutment to design in scanned casts. Anatomical shape with optimal emergence profile was designed using computer software.



5 Individualized abutment seated on implant analog.



6 Titanium individualized abutment placed.

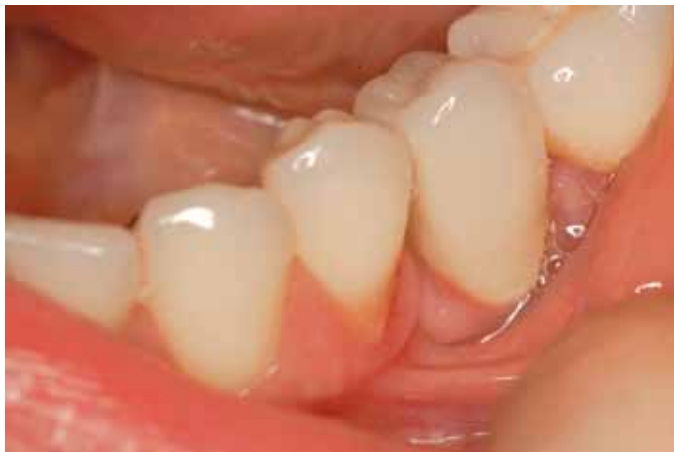and the fixation screw. The screw used to fixate the bone graft was removed and the implant (Osseotite, Certain Preval; Biomet 3i), diameter 4.1 mm/length 8.5 mm, was placed using the template, according to the procedure advocated by the manufacturer. The shoulder of the implant was placed at bone level. A coded healing abutment (Encode; Biomet 3i) with a height of 4 mm was placed to develop an emergence profile. The surgical site was closed with sutures (Vicryl 3-0; Johnson & Johnson, Brunswick, NJ). After 2 weeks the sutures were removed.

After 3 months, seating of the healing abutment was evaluated (Fig. 3). A closed tray impression of the healing abutment was made with a polyether impression material (Impregum Penta; 3M ESPE, St. Paul, Minn) and a custom acrylic resin impression

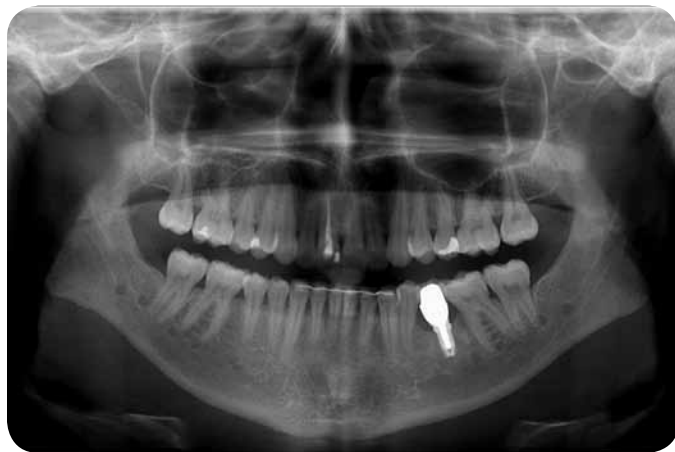tray (Lightplast base plates; Dreve Dentamid GmbH, Unna, Germany). An irreversible hydrocolloid impression (Cavex Holland BV, Haarlem, The Netherlands) was made of the opposing arch. The impressions were poured in die stone (GC Fujirock EP; GC Europe NV, Leuven, Belgium) and the casts were mounted in maximal intercuspal position in a semi-adjustable articulator (Ivoclar Stratos 100 articulator; Ivoclar Vivadent, Schaan, Liechtenstein). The casts were sent to the manufacturer (Biomet 3i) with a prescription indicating the design and contour. The healing abutment was scanned and an individualized abutment was designed (Fig. 4). The abutment was milled from a solid titanium alloy block and polished (Fig. 5). Using CAD, a hole was drilled in the definitive cast to create space for

the implant analog, followed by the placement of the implant analog (Fig. 2) (Robocats Technology; Biomet 3i). The individualized abutment with appropriate margin heights and natural emergence contours was placed on the implant analog and shipped back to the laboratory where the metal ceramic crown was made.

The healing abutment was removed and the titanium individualized abutment was placed with 20 Ncm using a torque device and a large hex driver tip (Biomet 3i) (Fig. 6). The screw access hole was filled with a cotton pellet and the metal (Estetic concorde; Cendres + Metaux, Biel, Switzerland) ceramic (DuceraGold Kiss, DeguDent, Hanau-Wolfgang, Germany) crown was cemented with a glass ionomer luting cement (GC Fuji 1; GC Europe NV). Because of



7 Restoration after service for 24 months.



8 Panoramic radiograph of definitive result. Note horizontal bone loss due to congenitally missing mandibular left premolar. Implant was placed at bone level

the precise fit between the individualized abutment and the metal ceramic crown, only a minimal amount of cement was needed to place the crown. To date, the restoration has been in service for 24 months without complications (Fig. 7, 8).

DISCUSSION

This report demonstrates a technical procedure in which an abutment level impression was used to fabricate an individualized abutment with an optimal emergence profile. This new restorative system, consisting of a coded healing abutment and a CAD/CAM titanium abutment, is purported to have numerous advantages: 1) it provides an anatomical emergence profile for the definitive abutment; 2) it provides the ability to correct an implant angle of up to 30 degrees; 3) it is available in titanium and zirconia; 4) there is no need to fabricate a cast or waxing, thereby reducing the laboratory time and costs; 5) it represents a simplified impression technique as there is no need to remove the healing abutment; 6) it is a convenient technique for the patient as it shortens chair time; and 7) it is easy to see the correct connection between the implant and the coded healing abutment when a mucoperiosteal flap is elevated during implant placement.

However, this system also has its disadvantages: 1) the use of the sys-

tem is limited to a specific implant system (Biomet 3i); 2) when using a titanium abutment, the crown has to be cemented; screw-retained implant crowns are only an option with zirconia abutments; 3) because of the precise fit between the crown and the titanium abutment, only a minimal amount of cement can be used or the crown may not be fully seated. In addition, the restorative system has some 3-dimensional limitations, such as a need for at least 6 mm of interarch space, 2 mm of space between the implants, and at least 1 mm soft tissue around the implant.⁵ However, these 3 disadvantages are encountered in almost all abutment systems. The restorative system described is one method to obtain an optimal implant suprastructure with an anatomical emergence profile.

SUMMARY

This clinical report describes a patient with a congenitally missing mandibular premolar, replaced with a dental implant and restored with an individualized abutment. With the restorative system described, an impression is made of the healing abutment, which has codes embedded in its occlusal surface. The codes provide essential information for the computer software to place the implant analog in the definitive cast, and to design and mill the definitive abutment.

REFERENCES

1. Lee H, So JS, Hochstedler JL, Ercoli C. The accuracy of implant impressions: a systematic review. *J Prosthet Dent* 2008;100:285-91.
2. Walker MP, Ries D, Borello B. Implant cast accuracy as a function of impression techniques and impression material viscosity. *Int J Oral maxillofac Implants* 2008;23:669-74.
3. Nissan J, Ghelfan O. The press-fit implant impression coping technique. *J Prosthet Dent* 2009;101:413-4.
4. Selecman AM, Wicks RA. Making an implant-level impression using solid plastic-press-fit, closed-tray impression copings: a clinical report. *J Prosthet Dent* 2009;101:158-9.
5. Priest G. Virtual-designed and computer-milled implant abutments. *J Oral Maxillofac Surg* 2005;63:22-32.
6. Grossmann Y, Pasciuta M, Finger IM. A novel technique using a coded healing abutment for the fabrication of a CAD/CAM titanium abutment for an implant-supported restoration. *J Prosthet Dent* 2006;95:258-61.
7. Drago CJ. Two new clinical/laboratory protocols for CAD/CAM implant restorations. *J Am Dent Assoc* 2006;137:794-800.
8. Fuster-Torres MA, Albalat-Estela S, Alcaniz-Ray M, Penarrocha-Diago M. CAD/CAM dental systems in implant dentistry: Update. *Med Oral Patol Oral Cir Bucal* 2009;14:E141-5.
9. Raghoebar GM, Meijndert L, Kalk WW, Vissink A. Morbidity of mandibular bone harvesting: a comparative study. *Int J Oral Maxillofac Implants* 2007;22:359-65.

Corresponding author:

Dr Gerdien Telleman
Department of Oral and Maxillofacial Surgery
University Medical Center Groningen
P.O. Box 30.001
9700 RB Groningen
THE NETHERLANDS
Fax: +31-50-3611161
E-mail: g.telleman@kchir.umcg.nl

Copyright © 2011 by the Editorial Council for
The Journal of Prosthetic Dentistry.