

University of Groningen

## Anti-neutrophil cytoplasmic antibodies

Kallenberg, Cees G.M.; Brouwer, Elisabeth; Weening, Jan J.; Cohen Tervaert, Jan W.

*Published in:*  
Kidney International

*DOI:*  
[10.1038/ki.1994.239](https://doi.org/10.1038/ki.1994.239)

**IMPORTANT NOTE: You are advised to consult the publisher's version (publisher's PDF) if you wish to cite from it. Please check the document version below.**

*Document Version*  
Publisher's PDF, also known as Version of record

*Publication date:*  
1994

[Link to publication in University of Groningen/UMCG research database](#)

*Citation for published version (APA):*

Kallenberg, C. G. M., Brouwer, E., Weening, J. J., & Cohen Tervaert, J. W. (1994). Anti-neutrophil cytoplasmic antibodies: Current diagnostic and pathophysiological potential. *Kidney International*, 46(1), 1-15. <https://doi.org/10.1038/ki.1994.239>

### Copyright

Other than for strictly personal use, it is not permitted to download or to forward/distribute the text or part of it without the consent of the author(s) and/or copyright holder(s), unless the work is under an open content license (like Creative Commons).

The publication may also be distributed here under the terms of Article 25fa of the Dutch Copyright Act, indicated by the "Taverne" license. More information can be found on the University of Groningen website: <https://www.rug.nl/library/open-access/self-archiving-pure/taverne-amendment>.

### Take-down policy

If you believe that this document breaches copyright please contact us providing details, and we will remove access to the work immediately and investigate your claim.

*Downloaded from the University of Groningen/UMCG research database (Pure): <http://www.rug.nl/research/portal>. For technical reasons the number of authors shown on this cover page is limited to 10 maximum.*

## Editor's Note:

*The scope of nephrology is, happily, continually expanding. Kidney International is acutely aware of its responsibility, as the official journal of the International Society of Nephrology, to serve the needs of the entire spectrum of renal clinicians and investigators.*

*For some years, the invited editorials appearing at the beginning of each month's issue of Kidney International, together with Nephrology Forum, have served the needs of our constituencies. But clinical nephrology has grown explosively. Moreover, the translation of laboratory information into clinically useful arguments is becoming increasingly short.*

*For that reason, beginning with this issue of Kidney International, we introduce a new series entitled Perspectives in Clinical Nephrology. Both PCN and Nephrology Forum will be directed primarily toward clinicians and/or clinical investigators whose major focus of inquiry is the patient. Like Nephrology Forum, PCN will attempt to translate, as rapidly as possible, advances made in the laboratory into constructs that help analyze the physiology and pathophysiology of disease. In turn, this construct will allow us to orient the Editorial Reviews, to an increasing degree, toward issues focused more on laboratory inquiry.*

*The Editors hope that this new series will, to an increasing degree, serve the needs of all of the readership of Kidney International.*

T. E. ANDREOLI  
FOR THE EDITORS

## PERSPECTIVES IN CLINICAL NEPHROLOGY

# Anti-neutrophil cytoplasmic antibodies: Current diagnostic and pathophysiological potential

Rapidly progressive glomerulonephritis (RPGN) is a clinical syndrome characterized by rapid deterioration of renal function occurring within days or weeks together with signs of glomerulonephritis, that is, proteinuria and hematuria with cellular casts. The syndrome is, in many cases, histopathologically manifested as fibrinoid necrosis of the capillary wall with extracapillary proliferation and crescent formation [1]. This so-called necrotizing crescentic glomerulonephritis (NCGN) is seen in 5 to 15% of renal biopsies in most series [1-3]. Although it is infrequent, the importance of the condition is illustrated by the fact that most cases of NCGN, if left untreated, develop renal failure within days or weeks [1]. Based on immunohistopathology NCGN can be subdivided into three distinct categories. The first one, occurring in 2 to 20% of the cases and characterized by linear staining of the glomerular capillary wall for immunoglobulin and complement, has classically been described as anti-glomerular basement membrane (GBM) disease. It is associated with autoantibodies to structural antigens of the GBM, in particular to the first globular noncollagen domain of collagen type IV [4]. The antibodies are considered of pathogenetic significance. The second category, comprising 15 to 50% of cases, is characterized by granular deposits of immunoglobulin and complement suggesting that immune complexes are pathogenetically involved. This type occurs in conjunction with systemic autoimmune diseases such as lupus erythematosus, in cases of post-infectious glomerulonephritis, IgA nephropathy or Henoch-Schönlein purpura, or as an idiopathic

variety. The third group of NCGN, occurring in 40 to 80%, demonstrates only a few or no immune deposits and is designated as pauci-immune NCGN [1-3, 5, 6]. Pauci-immune NCGN occurs as part of Wegener's granulomatosis (WG) or related conditions, or without systemic vasculitis (idiopathic NCGN). The pathophysiology of this pauci-immune type of NCGN has not been elucidated. Within the last decade, however, it has been recognized that the condition is associated with autoantibodies to cytoplasmic components of neutrophils (anti-neutrophil cytoplasmic antibodies or ANCA).

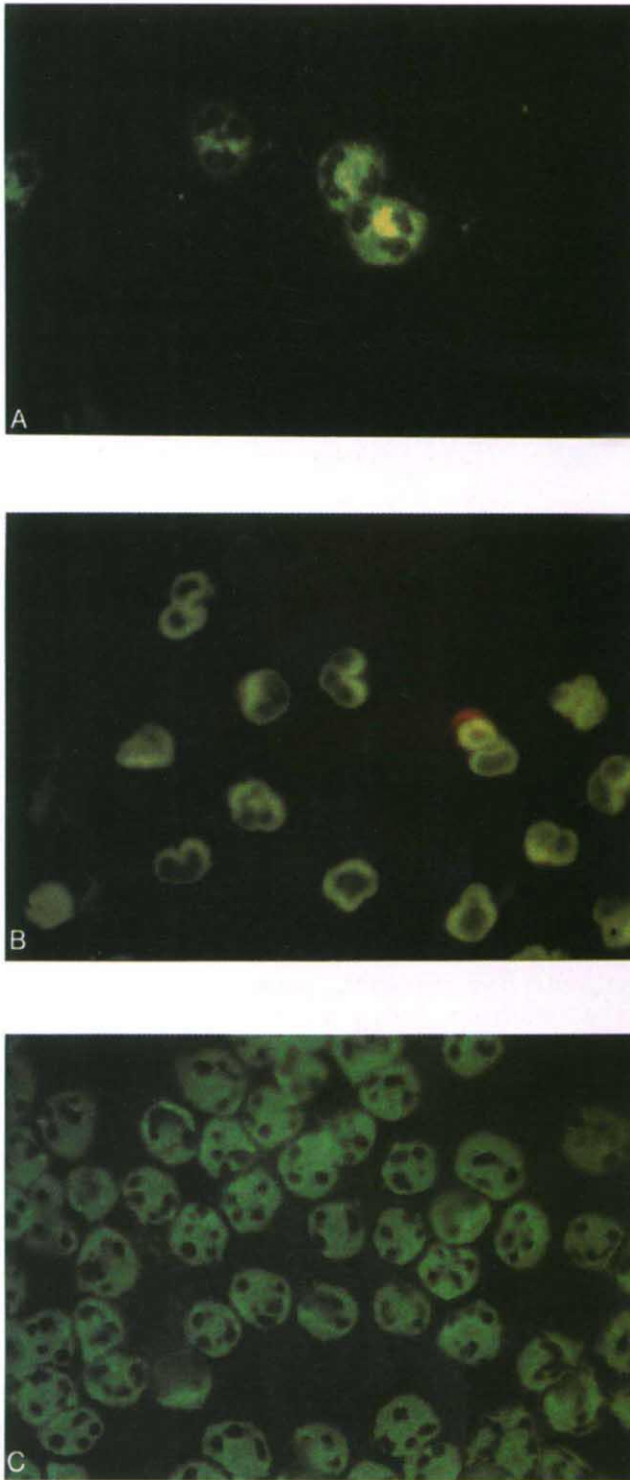
ANCA were first described in 1982 by Davies et al in a few patients with segmental necrotizing glomerulonephritis [7]. Only in 1985 did it become apparent that ANCA are a sensitive and specific marker for Wegener's granulomatosis (WG) [8]. Later on, ANCA were described in patients with microscopic polyarteritis [9]. Falk and Jennette, in 1988, showed that ANCA are also associated with the idiopathic form of pauci-immune NCGN [10]. These data have now been confirmed by many groups and support the view that ANCA-associated glomerulonephritis and vasculitis is, indeed, a distinct disease category. A number of studies, in addition, have suggested that ANCA are involved in the pathophysiology of the aforementioned disorders. As ANCA, however, have recently also been detected in a wide range of inflammatory and infectious conditions, a critical reappraisal of the diagnostic significance of ANCA-testing seems justified.

In this review we will evaluate the current state of ANCA-testing as well as elaborate on the pathophysiological role of the autoantibodies in necrotizing glomerulonephritis and vasculitis. Data presented recently at the Fifth International Workshop on ANCA, held in Cambridge, United Kingdom, will be included [11]. As such, it adds to previous reviews on ANCA that were published following the Second [12], Third [13], and Fourth [14] Workshops on ANCA.

---

Received for publication October 27, 1993  
and in revised form February 7, 1994  
Accepted for publication February 7, 1994

© 1994 by the International Society of Nephrology



**Fig. 1.** Staining of ethanol fixed neutrophils by indirect immunofluorescence by sera producing: (a) a characteristic cytoplasmic staining pattern with accentuation of the fluorescence intensity in the area within the nuclear lobes (c-ANCA, top); (b) a perinuclear staining pattern (p-ANCA, middle); (c) an atypical cytoplasmic staining pattern showing a more diffuse finely speckled fluorescence throughout the cytoplasm (bottom).

## ANCA: A class of different autoantibodies

### *ANCA as detected by indirect immunofluorescence*

ANCA are routinely detected by indirect immunofluorescence (IIF) on ethanol fixed neutrophils [15]. At least three different patterns of fluorescence can be distinguished (Fig. 1): a cytoplasmic pattern with accentuation of the fluorescence intensity in the area within the nuclear lobes (cytoplasmic or c-ANCA), a perinuclear pattern (p-ANCA), and a more diffuse cytoplasmic staining pattern (atypical ANCA). The first pattern has been recognized as a characteristic staining pattern produced by the sera of most patients with WG [8, 16], but also of some 50% of patients with microscopic polyangiitis/arteritis and a minority of patients with other necrotizing vasculitides or idiopathic NCGN [reviewed in 17]. P-ANCA were originally described by Falk and Jennette [10] in patients with idiopathic and/or vasculitis-associated NCGN. Further studies showed that the p-ANCA pattern can be produced also by sera from patients with vasculitis without renal involvement, and patients with inflammatory bowel diseases, autoimmune liver diseases, infectious diseases such as HIV infection, and rheumatic disorders as systemic lupus erythematosus (SLE) and rheumatoid arthritis [17, 18]. The perinuclear pattern cannot always be distinguished from a nuclear staining pattern. Thus, discrimination between antinuclear antibodies (ANA) and p-ANCA is not possible in most sera that are ANA-positive when isolated ethanol-fixed neutrophils are used as a substrate. In fact, antibodies reacting with nuclei of granulocytes only, and not with that of other substrates, have been detected in patients with rheumatoid arthritis long before ANCA had been described, and were named granulocyte-specific antinuclear antibodies (GS-ANA) [19, 20]. Recent studies, however, have shown that the p-ANCA pattern produced by sera from patients with NCGN is an artifact of ethanol fixation [21]. When neutrophils are fixed with a cross-linking fixative such as paraformaldehyde, those sera produce a cytoplasmic staining pattern [21, 22] whereas ANA-positive sera still display a nuclear staining. As will be discussed below, a number of antigens recognized by ANCA, such as myeloperoxidase, are highly cationic proteins. During ethanol fixation those cationic proteins move to the negatively charged nuclear membrane [22] which explains the perinuclear fluorescence pattern. The third pattern, an atypical cytoplasmic fluorescence staining, has not been linked to particular antigens nor to specific disease entities until now.

What do we learn from these data? First, detection of ANCA by IIF should be performed in a standardized way by highly skilled technicians in order to get reproducible results. Cytospins of the buffy coat are preferentially used as a substrate since the simultaneous presence of lymphocytes and neutrophils in the preparation allows the distinction between ANCA, which are myeloid specific, and ANA although the presence of ANCA cannot be excluded in ANA-positive sera. Besides ethanol fixation, paraformaldehyde-fixed preparations may be used since some sera are positive for ANCA on the latter substrate and negative on the former [23]. A recent collaborative European study has shown that ANCA-testing according to a standard protocol using ethanol-fixed leukocytes results in very low inter-laboratory variance [24]. Secondly, a positive



ANCA-test by IIF is in itself not diagnostic for a particular condition but should be followed by antigen-specific assays.

#### ANCA: Their target antigens

**Proteinase 3.** The antigen recognized by most c-ANCA positive sera has been identified as proteinase 3, a third serine protease from the azurophilic granules of neutrophils different from elastase and cathepsin G, the other two serine proteases from these granules [25–27].

Proteinase 3 has been cloned and was shown to be a 29 kD glycoprotein of 228 amino acids [28] that is identical to p29b, a recently described antibiotic protein from human neutrophils [29], and myeloblastin, a growth-promoting protein from myeloid cells [30]. The enzyme is slightly cationic, has proteolytic activity as measured on several substrates [31], and is physiologically inhibited by  $\alpha_1$ -antitrypsin [32]. Proteinase 3- $\alpha_1$ -antitrypsin complexes can, indeed, be detected in inflammatory fluids [32]. A 47 kD glycoprotein is also recognized by polyclonal and monoclonal antibodies that react with the 29 kD molecule as shown by Goldschmeding et al [25]. It has recently been demonstrated that this 47 kD moiety has serine protease activity and, probably, represents a post-transcriptional modification of the cDNA encoding for myeloblastin/proteinase 3 [33]. Human antibodies to proteinase 3 appear to recognize conformational determinants on the molecule [34]. The epitope(s) in question are localized at or near the catalytic domain of the molecule as human autoantibodies to proteinase 3 interfere with the inactivation of the enzyme by  $\alpha_1$ -antitrypsin [35]. In most cases binding of the antibody to proteinase 3 not only inhibits inactivation of the molecule by anti-proteases but also results in inactivation of proteinase 3 itself; in some instances, however, enzymatic activity is retained [35].

Proteinase 3 is localized in the azurophilic or  $\alpha$ -granules from myeloid cells. It is present both in monocytes and granulocytes and appears early in mono-myeloid differentiation [36, 37]. Proteinase 3 is released from activated neutrophils by a process involving fusion of the membrane of azurophilic granules with the plasmamembrane [38]. When neutrophils are primed, that is, pre-activated with a low dose of TNF $\alpha$  (100 pg/ml), proteinase 3 appears at the cell membrane being available for interaction with its cognate antibody [39]. *In vivo*, circulating neutrophils showing membrane expression of proteinase 3 have been detected in conditions as septic shock and also in patients with active WG [40]. Interestingly, recent studies by Mayet et al have shown that proteinase 3 can also be expressed in a renal carcinoma cell line [41] and, more importantly, in cultured human endothelial cells from umbilical veins [42]. In cytokine-treated endothelial cells proteinase 3 moves towards the cell membrane suggesting that the antigen may *in vivo* be a direct target for circulating autoantibodies [42]. Proteinase 3 can be purified from neutrophil granules by dye-ligand affinity and ion-exchange chromatography [43], by immunoaffinity chromatography [44], or by high pressure liquid chromatography [45]. Purified protein can be used in ELISA systems for quantitation of specific antibodies [24]. Anti-proteinase 3 antibodies can also be detected by a capture ELISA in which a monoclonal antibody selects the relevant antigen from a crude extract of  $\alpha$ -granules [3, 25].

**Myeloperoxidase (MPO).** Following the description of c-ANCA as a marker for WG several groups observed that a

**Table 1.** Neutrophil granule constituents

Class of constituent	Azurophilic granules	Specific granules
Microbial enzymes	myeloperoxidase lysozyme	lysozyme
Serine proteinases	elastase cathepsin G proteinase 3 azurocidin	
Metalloproteinases		collagenase gelatinase
Acid hydrolases	N-acetyl- $\beta$ -glucosaminidase cathepsin B cathepsin D $\beta$ -glucuronidase $\beta$ -glycerophosphatase $\alpha$ -mannosidase	
Other	defensins	lactoferrin vitamin B12-binding protein

number of sera from patients suspected of vasculitis produced a perinuclear fluorescence pattern on ethanol-fixed neutrophils. During the first international workshop on ANCA in 1988 Goldschmeding et al [46] reported that many of those sera contained antibodies to MPO and, incidentally, to elastase, and Falk and Jennette also mentioned MPO as the relevant antigen [47, 10]. Based on the latter data p-ANCA became almost synonymous for anti-MPO, which, as already has been discussed, is not true. In fact, many p-ANCA positive sera are directed against antigens different from MPO, whereas some sera with anti-MPO antibodies produce a cytoplasmic staining pattern on ethanol-fixed neutrophils [48, 49]. MPO is a highly cationic protein (pI 11.0) with a molecular wt of 146 kD, and consists of two chains. The enzyme plays a critical role in the generation of reactive oxygen species [50]. By immunoprecipitation at least two bands of approximately 60 and 42 kD, representing a complete and a partly degraded single chain, are recognized both by monoclonal and human polyclonal antibodies [25]. Western blotting studies demonstrate that human anti-MPO antibodies recognize native MPO but not denatured MPO suggesting that conformational epitopes are involved [51–53]. The human autoimmune response to MPO is directed against multiple epitopes as demonstrated by inhibition studies using anti-MPO positive sera and a set of different monoclonal antibodies [54]. The relevant epitopes have not yet been defined but most anti-MPO positive sera do not seem to inactivate the enzymatic activity of the molecule [51, 52]. Studies performed in mice have demonstrated the occurrence of natural anti-MPO antibodies of the IgM-isotype, some of which are polyreactive [55]. Autoantibodies to MPO have also been demonstrated in Brown Norway rats treated with mercuric chloride which induces a T-cell-dependent polyclonal B-cell activation [53]. These data suggest that also in humans low-affinity IgM-class antibodies are present at the germ line which may develop into high-affinity IgG-class anti-MPO by antigen-driven selection in the presence of their cognate T cells. In this respect, cross-reactivity or homology between MPO and other proteins may be relevant. As such, the homology demonstrated between MPO and heat shock proteins is of interest [56].

For the detection of anti-MPO antibodies commercially available MPO can be used in ELISA systems. Those preparations, however, may contain impurities, in particular lactoferrin [57]. Alternatively, a capture ELISA can be used [3, 25, 48].

**Other antigens.** Many sera that produce a perinuclear or atypical cytoplasmic staining pattern on ethanol fixed neutrophils do not contain antibodies to MPO or proteinase 3 as tested by antigen-specific assays. It has now been recognized that a number of these sera contain antibodies to defined granular constituents of neutrophils (Table 1). In particular, autoantibodies have been demonstrated to lactoferrin [23, 58–63] and lysozyme [64], which are constituents of the specific granules, to elastase [25, 65] and cathepsin G [66], the two other serine proteases that are present in the azurophilic granules, and to  $\beta$ -glucuronidase, another constituent of those granules [67]. In addition, autoantibodies have been detected that are directed against cytosolic components of neutrophils, in particular to alpha-enolase [68]. The presence of these autoantibodies have been demonstrated in most of the cases by ELISA, and not by additional Western blotting or immunoprecipitation. Detection by ELISA did not always parallel detection by IIF on ethanol- or formalin-fixed neutrophils. Their clinical associations will be discussed below.

#### ANCA: Diagnostic significance

Although ANCA were first described in a few patients with necrotizing glomerulonephritis [7], large interest in the autoantibodies arose from their presence in WG [8]. Numerous studies published in recent years, however, have shown that ANCA are far from specific for WG, and have challenged the diagnostic potential of the autoantibodies. These sometimes conflicting data ask for a critical reappraisal of the clinical value of ANCA testing.

#### *Wegener's granulomatosis*

Following the original description of ANCA in WG [8] many studies have confirmed the sensitivity of c-ANCA or anti-proteinase 3 for a diagnosis of WG. Three major studies comprising more than 200 patients have found a sensitivity of 90% for so-called extended WG characterized by the triad of granulomatous inflammation of the respiratory tract, systemic vasculitis, and necrotizing crescentic glomerulonephritis [16, 69, 70]. The sensitivity of anti-proteinase 3 for limited WG, that is, disease manifestations without obvious renal involvement, amounted to 75% [17]. It should be mentioned that these data concern patients with active disease only. During remission c-ANCA were detected in a far lower percentage of the patients. Generally, the presence of c-ANCA as detected by IIF corresponded with their presence as detected by proteinase 3-specific ELISA [3, 69]. Many other studies dealing with smaller numbers of patients have confirmed these findings [reviewed in 71]. The association between anti-proteinase 3 and WG is, however, not absolute: some patients with active (generalized) WG are ANCA-negative. Most of the patients who are negative for anti-proteinase 3 have, however, antibodies to MPO or leukocyte elastase [10, 48, 65, 71].

The specificity of anti-proteinase 3 for active WG has been found as high as 98% [16, 69, 71] when sera were studied from patients with a wide variety of renal, autoimmune, vasculitic, infectious, or lymphoproliferative disorders. It should, how-

**Table 2.** Traditional classification of systemic idiopathic vasculitides

I.	Affecting predominantly large- and medium-sized blood vessels
	1. Takayasu's arteritis
	2. Giant cell arteritis/temporal arteritis
II.	Affecting predominantly medium- and small-sized blood vessels
	1. Classic polyarteritis nodosa
	2. Churg-Strauss syndrome
	3. Wegener's granulomatosis
	4. Polyangiitis overlap syndrome
III.	Affecting predominantly small blood vessels
	1. Microscopic polyarteritis
	2. Henoch-Schönlein purpura

ever, be realized that anti-proteinase 3 antibodies are detected in patients with overlapping symptoms of WG and other forms of vasculitis, and in some patients with idiopathic necrotizing glomerulonephritis without systemic involvement [3, 48, 69, 72]. Some of these patients will evolve into definite (extended) WG as classified according to the ACR criteria [73] or according to the definition recently proposed by an international study group on vasculitis [74]. Very recently, anti-proteinase 3 antibodies have been described in patients with invasive amoebiasis [75] and in patients with thyroid disease treated with propylthiouracil [76]. The latter patients simultaneously developed antibodies to other myeloid enzymes such as MPO and elastase together with clinical signs of vasculitis. These findings may suggest that the thiol group of the drug is involved in the induction of this polyclonal autoimmune reaction.

As mentioned before, the prevalence of c-ANCA/anti-proteinase 3 in patients with active WG is far higher than that in inactive disease. Various longitudinal studies have shown that titers of ANCA rise prior to a relapse of WG [16, 77]. The rise proved very sensitive for an ensuing relapse and was detectable a mean of 49 days (range 9 to 106 days) before the moment of clinical relapse [16]. Based on these findings, a prospective study was undertaken on 58 patients with WG to test whether treatment based on changes in c-ANCA titer could prevent the occurrence of relapses [78]. In this study blood samples were tested every month for ANCA titer. Over an observation period of 24 months titers of ANCA rose in 20 patients. None of the nine patients who were randomized for treatment at the time ANCA titer had risen (without having major clinical signs at that moment) relapsed. In contrast, nine of the 11 patients who were not treated at that moment, finally developed a relapse. Those latter patients used more immunosuppressives and corticosteroids than the patients who were treated immediately at the time ANCA titer had risen. These data have been challenged by a recent report from the NIH group [79] demonstrating a rather poor correlation between changes in ANCA titer and disease activity of WG. A closer look at their data [80], however, shows that all 17 patients from the NIH study who were either in remission or had stable disease developed relapses that were preceded (24%) or paralleled (76%) by an increase of c-ANCA titer. Changing titers not corresponding to disease activity mainly occurred in patients with (persistently) active disease. Persistently or intermittently positive tests for ANCA in patients who come into remission have been shown to be a considerable risk factor for an ensuing relapse (RR 20 compared to patients who are persistently ANCA-negative after



**Table 3.** Classification of the idiopathic vasculitides as proposed by an international study group at the Chapel Hill Consensus Conference on the Nomenclature of Systemic Vasculitis (adapted from [74])

I. Large vessel vasculitis
1. Giant cell (temporal) arteritis
2. Takayasu arteritis
II. Medium-sized vessel vasculitis
1. Polyarteritis nodosa
2. Kawasaki disease
III. Small vessel vasculitis
1. Wegener's granulomatosis
2. Churg-Strauss syndrome
3. Microscopic polyangiitis
4. Henoch Schönlein purpura
5. Essential cryoglobulinemic vasculitis
6. Cutaneous leukocytoclastic angiitis

remission) [81]. Interestingly, persistence of ANCA is associated with certain HLA class II genes, in particular the DQw7, DR4 haplotype [82], suggesting that genetic factors are involved in the autoimmune response.

In conclusion, the presence of anti-proteinase 3 strongly suggests a diagnosis of WG although the association is not absolute. Increasing titers of the autoantibodies should alert the clinician to the possibility of an ensuing relapse.

#### *Other idiopathic necrotizing vasculitides including idiopathic pauci-immune NCGN*

The necrotizing vasculitides are traditionally grouped according to the size of the vessels involved and the histopathology of the inflammatory process (Table 2). Classification criteria based mainly on clinical signs and symptoms have been published by the American College of Rheumatologists (ACR) [83]. Although useful in clinical practice, these criteria do not strictly define the disease in question. Using these criteria, various degrees of sensitivity and specificity are obtained. As the criteria are not mutually exclusive one particular patient may be classified as having two or more disease entities. Recently, an international study group has newly defined the several vasculitides based, generally, on histopathologic findings (Table 3) [74]. The main difference with the traditional classification (Table 2) lies in the distinction between medium sized and small vessel vasculitis. In medium sized (and large) vessel vasculitis vessels smaller than arteries are not involved, whereas in small vessel vasculitis large vessels may be involved as well. A diagnosis of polyarteritis nodosa requires the presence of necrotizing arteritis but is excluded when arterioles, capillaries or venules are involved as well. In the latter situation the diagnosis probably will be microscopic polyangiitis according to the Chapel Hill conference [74]. Classification criteria based on both clinical and histopathologic findings still have to be established by this group. At present, one should realize that the same name may be used for different diseases and vice versa. In addition, in clinical practice many patients present with overlapping features of different vasculitides and cannot be classified within one category. Data on prevalences of ANCA in the various vasculitides should be valued with these considerations in mind.

**Table 4.** Disease associations of anti-proteinase 3 antibodies and anti-myeloperoxidase antibodies

Disease entity	Sensitivity of	
	Anti-proteinase 3 %	Anti-myeloperoxidase %
Wegener's granulomatosis	85	10
Microscopic polyangiitis	45	45
Idiopathic crescentic glomerulonephritis	25	65
Churg-Strauss syndrome	10	60
Polyarteritis nodosa	5	15

Data are derived from the references cited in the text.

*Microscopic polyarteritis or angiitis (MPA).* This is characterized by (pauci-immune) necrotizing vasculitis involving small sized vessels [84]. A pulmonary-renal syndrome consisting of NCGN in combination with pulmonary capillaritis is not uncommon. Most patients with MPA are ANCA-positive, either with specificity for proteinase 3 or for MPO [85]. There seems to be no clear distinction between patients positive for anti-proteinase 3 or anti-MPO, although a number of anti-proteinase 3 positive patients develop histologically confirmed WG during the course of their disease (own observations). The relation between titers of ANCA and disease activity has not been studied systematically in MPA.

*Idiopathic pauci-immune NCGN.* This can be considered as a renal limited form of MPA. Most patients with this latter disorder are positive for anti-MPO, the remaining generally being positive for anti-proteinase 3 [3, 10]. At a closer look, however, many patients with idiopathic NCGN have constitutional symptoms together with signs of systemic involvement such as arthralgias, purpura and/or otorhinolaryngologic symptoms. As such, the distinction between WG, MPA, and idiopathic NCGN is far from absolute.

*Anti-GBM disease.* Interestingly, anti-MPO antibodies also have been detected in 30 to 40% of patients with anti-GBM disease [86–88]. Patients having both anti-MPO and anti-GBM antibodies are considerably older than patients with anti-GBM antibodies only. In some of these patients clinical and pathological data suggest associated systemic vasculitis, and among these patients recovery of renal function has been reported despite their initial need for hemodialysis [87]. Whether ANCA in anti-GBM disease develop concomitantly with anti-GBM antibodies, possibly as a result of polyclonal activation, is presently not clear.

*Churg Strauss syndrome.* Characterized by (a history of) asthma and hypereosinophilia in conjunction with systemic vasculitis with or without renal involvement, Churg Strauss syndrome is associated with anti-MPO antibodies [89]. Combining data from several studies the prevalence of anti-MPO in this disorder may be estimated as 75% [72, 90]. *Classical polyarteritis nodosa (PAN)* defined as necrotizing arteritis involving medium sized arteries is ANCA-negative in the majority of the cases [72, 90]. In a large series from France [90] 20% of the patients with PAN without hepatitis B virus infection were positive for ANCA, whereas 11% of those with HBV infection were positive.

*Kawasaki disease.* The occurrence of ANCA in Kawasaki disease, a mucocutaneous lymph node syndrome with, in a

considerable number of cases, arteritis, in particular of the coronary arteries, has not been definitely established. Acute sera demonstrate positive homogeneous cytoplasmic staining in 23% of the patients possibly due to IgM-class antibodies directed to cathepsin G [91]. Large vessel vasculitides such as *Takayasu arteritis* [92] and *temporal arteritis* [65, 93] generally are ANCA-negative. Finally, the presence of ANCA, in particular of the IgA isotype, in *Henoch Schönlein purpura* needs consideration. Although these IgA-ANCA have been reported in earlier studies [94], these data have not been confirmed by other groups [95].

In summary, the presence of anti-proteinase 3 or anti-MPO appears to characterize pauci-immune small vessel vasculitis of different varieties frequently involving the kidney as well (Table 4).

#### *Connective tissue diseases*

*Systemic lupus erythematosus.* The prevalence of ANCA in systemic lupus erythematosus (SLE) still is a matter of debate. Antibodies to MPO [96, 97], elastase [97], and lactoferrin [61] have been reported in this disease. Their prevalences differ widely between several series, and their occurrence does not seem to be associated with any particular disease subset. Interestingly, anti-MPO have been detected in the sera of all six patients with hydralazine induced lupus, in five of them in combination with anti-elastase antibodies [98]. The simultaneous presence of specific ANCAs both in hydralazine induced lupus and propylthiouracil induced vasculitis suggests a more polyclonal immune activation in drug-induced autoimmunity comparable to experimental mercuric chloride induced autoimmune disease in which anti-MPO antibodies are also detected [53].

*Rheumatoid arthritis.* Granulocyte-specific ANA (GS-ANA) [20, see before] have been described in rheumatoid arthritis (RA) already in 1959 [99]. The detection of ANCA has evoked renewed interest in those antibodies in RA. It has been shown that, at least most of, GS-ANA are actually ANCA directed to different antigens [23]. Among these lactoferrin is most prominent. Anti-lactoferrin antibodies have been specifically associated with vasculitis in RA [58] and with Felty's syndrome [60], although these data have not been confirmed by others [23, 100]. The latter studies actually suggest that ANCA in RA are a secondary phenomenon related to disease duration.

#### *Inflammatory bowel disease (IBD) and autoimmune liver disease*

The occurrence of ANCA in IBD, in particular in *ulcerative colitis*, has raised interest in ANCA as a marker of ulcerative colitis useful in the work-up of patients with diarrhea [101]. The prevalence of ANCA in ulcerative colitis may be estimated as 50 to 80% compared to a 10 to 40% prevalence in *Crohn's disease* [59, 102–104]. Titers of ANCA possibly follow disease activity in ulcerative colitis but not in *Crohn's disease* [103–105]. There is still no agreement on the antigens involved. Cathepsin G as well as  $\beta$ -glucuronidase have been proposed [66, 67], but other studies suggest that the same antigens are involved as in RA including lactoferrin [59]. ANCA have also been described in a considerable number of patients with *primary sclerosing cholangitis*, a hepatic disease of possible

autoimmune origin associated with IBD [106]. ANCA, however, were also found in 60 to 70% of patients with *chronic active hepatitis*, and 35% of those with *primary biliary cirrhosis*. The antigens involved have only partly been characterized [107].

#### *Infectious diseases*

ANCA, generally of undefined specificity, have been described in HIV infection and mucoviscidosis with secondary infection [108, 109]. As mentioned before, a recent report described the occurrence of anti-proteinase 3 antibodies in patients with amoebiasis [75]. In addition, incidental case reports have mentioned the occurrence of ANCA in different infectious and neoplastic disorders. These findings, although unconfirmed, underscore that the detection of ANCA by IIF only has, at present, limited diagnostic value. The presence of anti-proteinase 3 or anti-MPO in the relevant clinical context, however, clearly points to one of the idiopathic forms of necrotizing vasculitis or glomerulonephritis.

#### **ANCA: Towards a role in the pathophysiology of NCGN/vasculitis**

The close association between anti-MPO and anti-proteinase 3 antibodies on the one hand and pauci-immune NCGN and necrotizing vasculitis on the other hand suggests a pathophysiological role for the autoantibodies. There are, indeed, experimental data that further substantiate a role for ANCA in the pathophysiology of the aforementioned diseases.

#### *Effect of ANCA on their target antigens*

As discussed before binding of anti-proteinase 3 to its target enzyme can inhibit the irreversible inactivation of the enzyme by  $\alpha_1$ -antitrypsin, its natural inhibitor [35]. The inhibitory activity differs between sera and is not directly related to the amount of specific antibody [110]. In a longitudinal study it has been shown that disease activity in patients with WG correlates with the amount of inhibitory activity of the serum rather than with the titer of the anti-proteinase 3 antibodies [110]. This suggests that escape of the enzyme from its inactivation may contribute to the inflammatory process. Although most anti-proteinase 3 positive sera not only inhibit inactivation of proteinase 3 but also its enzymatic activity [35], the reversible antigen-antibody binding may be dissolved at the site of inflammation allowing the enzyme to display its lytic activity.

The phenotypical expression of  $\alpha_1$ -antitrypsin is polymorphic: severely-, medium-, and non-deficient proteinase inhibitor phenotypes can be distinguished. Interestingly, among 14 anti-proteinase 3-positive patients with vasculitis, phenotypes deficient for proteinase inhibitor activity were increased compared to controls. Reversely, the prevalence of ANCA of diverse specificities was remarkable amongst a population with the severely deficient phenotype (20 out of 150) [111]. These data suggest that deficient  $\alpha_1$ -antitrypsin activity is involved in the induction of ANCA. Otherwise, this deficiency may contribute to the expression of the lesions in ANCA-associated vasculitis.

#### *Interaction between ANCA and endothelial cells*

The antigens recognized by anti-MPO and anti-proteinase 3 are constituents of granules from myeloid cells and are thought



to be specific for cells of the monomyeloid lineage. Recent studies from Mayet et al have demonstrated, however, that proteinase 3 can be expressed in other cell types as well, in particular in renal carcinoma cells [41] and in human endothelial cells [42]. In the latter cells cytokine treatment either with TNF $\alpha$ , IL-1, or IFN $\gamma$ , resulted in increased expression of proteinase 3 with translocation of the enzyme to the cell membrane. As such the antigen is available for interaction with the autoantibody at sites of cytokine production. MPO and proteinase 3 are cationic proteins with an isoelectric point of 11.0 and 7.8, respectively. These cationic proteins may bind to anionic structures such as the glomerular basement membrane (GBM) and the surface of endothelial cells. It has, indeed, been shown that ANCA can bind to endothelial cells incubated with MPO or proteinase 3 [112] although the interaction of proteinase 3 with endothelial cells has been disputed [113]. Under these conditions, anti-MPO can, *in vitro*, induce complement dependent endothelial cell lysis [112]. Although these *in vitro* studies have demonstrated that ANCA can interact, directly or indirectly, with endothelial cells, direct immunofluorescence studies from lesional tissue have failed to show significant deposition of IgG along the endothelium or the glomerular capillary wall. Thus, the *in vivo* relevance of those *in vitro* studies still has to be established.

#### Potential of ANCA to activate inflammatory cells

Falk et al were the first to demonstrate that ANCA can activate neutrophils that are pre-treated ("primed") with low dosage TNF $\alpha$  to the production of reactive oxygen species and the release of lysosomal enzymes [114]. The mechanisms underlying neutrophil activation by ANCA have only partly been elucidated. Priming of neutrophils by TNF $\alpha$  results in the expression of lysosomal enzymes such as MPO and proteinase 3 at the cell membrane [39]. Those pre-activated neutrophils showing surface expression of proteinase 3 can be detected in the peripheral blood in conditions as septic shock and at the time of active disease in WG [40]. Binding of anti-proteinase 3 to primed neutrophils results in further activation. Falk et al originally reported that activation can be induced by F(ab')<sub>2</sub>-fragments of the antibodies [114]. Recent studies, however, suggest that both F(ab)-binding and Fc-interaction are involved [115, 116]. Blocking of the FcII receptor on neutrophils inhibited activation [115]. The FcII receptor particularly interacts with IgG2 and IgG3 subclasses of antibodies. Interestingly, sera with relatively high levels of IgG3 subclass of ANCA preferentially activate neutrophils [115], and renal exacerbations of WG are associated with increases of the IgG3 subclass of ANCA [117] although IgG1 and IgG4 subclasses of ANCA are present as well [117]. The signal transduction pathway involved in ANCA-mediated activation of neutrophils is still a matter of debate [118–120]. Different pathways have been described suggesting that protein kinase C (PKC) as well as Ca<sup>2+</sup>-influx are involved. The translocation of PKC to the cell membrane as observed during ANCA-mediated activation [118] seems to be the initial step, further steps are dependent on intracellular calcium [120]. *In vitro* studies also have shown that primed neutrophils in the presence of ANCA can lyse endothelial cells in culture [121, 122]. In addition, it has been suggested that ANCA can induce adhesion of neutrophils to monolayers of cultured endothelial cells [123]. Considering these experiments

one should realize that isolation of neutrophils in itself may result in some degree of activation depending on the methods of isolation. This, apparently, may influence the results. Taken together, ANCA of defined specificity have been shown to activate primed neutrophils. The relevance of this phenomenon for the pathophysiology of the necrotizing vasculitides needs further study. In this respect, the capacity of ANCA to activate primed neutrophils did not correlate with the amount of *in situ* activated neutrophils present in renal biopsies from patients with active WG [124].

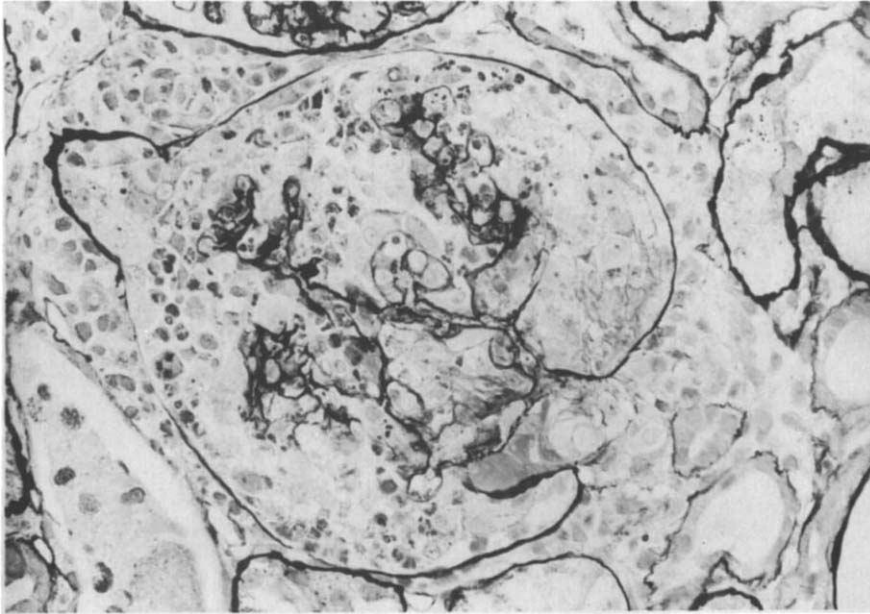
#### T cell reactivity to ANCA-associated antigens

Besides neutrophils, inflammatory lesions of lung and kidney in WG contain mononuclear infiltrates, frequently also in the form of granulomas, which consist of monocytes and T cells, the majority of which are CD4-positive [125, 126]. The presence of these large cellular infiltrates, contrasting with the scanty deposits of immunoglobulins [5, 6, 124], suggests that cell-mediated immunity is involved in the pathogenesis of the lesions as well. In agreement, elevated levels of soluble IL-2 receptors and increase in those levels preceding major relapses have been reported in patients with WG indicating the presence of activated T cells [127, 128]. The target antigens of those activated T cells are, however, not known. Microbial antigens, in particular Staphylococcal antigens, might be involved as chronic nasal carriage of *Staphylococcus aureus* has been shown to be an important risk factor for the development of relapses in patients with WG [81]. Otherwise, the target antigens of ANCA, that is, proteinase 3 and MPO, are released at the site of inflammation and could be targets for cell-mediated immunity. Preliminary data have shown that lymphocytes isolated from patients with WG proliferate in response to crude neutrophil extracts containing proteinase 3 [129, 130]. We recently demonstrated using *in vitro* lymphocyte proliferation assays, that patients with WG positive for anti-proteinase 3 antibodies responded more frequently and stronger to proteinase 3 than controls [131]. However, 33% of healthy controls also reacted *in vitro* to proteinase 3, whereas 35% of patients with anti-proteinase 3 antibodies did not show *in vitro* T cell reactivity to this autoantigen. Thus, the pathophysiological role of (autoreactive) T cells in systemic vasculitis awaits further studies.

#### The *in vivo* role of ANCA in NCGN

The *in vivo* potential of ANCA to aggravate the inflammatory response has recently been demonstrated by Kobayashi, Shibata and Sugisaki [132]. They injected rats with rabbit anti-rat MPO antibodies together with rabbit anti-rat GBM antibodies. Control rats were injected with either anti-rat GBM or anti-rat MPO antibodies. In the latter group no lesions were apparent. The most severe lesions were found in rats injected with both antibodies. In this group, MPO was found along the glomerular capillary wall and anti-MPO could be eluted from the kidneys. Thus, besides direct activation of rat neutrophils by anti-MPO, MPO released from activated neutrophils may have bound to the GBM due to charge interaction followed by *in situ* binding of anti-MPO. This local immune complex formation may have aggravated the passive anti-GBM nephritis. In line with these findings are the data of Brouwer et al [133]. They immunized





**Fig. 2.** Light microscopy of lesions found in Brown Norway rats immunized with myeloperoxidase and perfused with a lysosomal enzyme extract and  $H_2O_2$ . Crescent formation, tuft necrosis, and periglomerular infiltration ( $\times 560$ ).

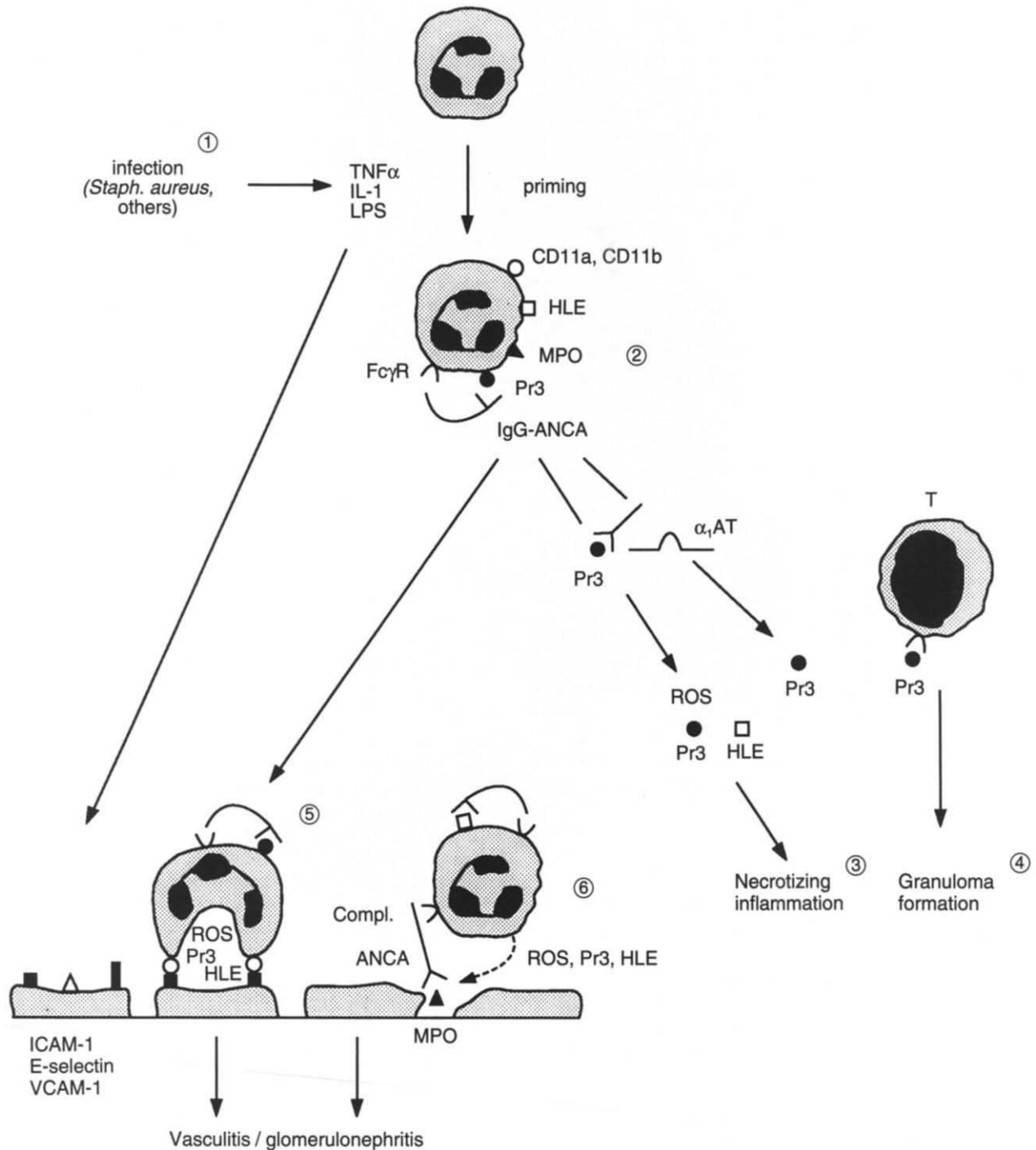
Brown Norway (BN) rats with human MPO. The rats developed anti-human MPO antibodies, which, in part, showed cross-reactivity with rat MPO, as well as delayed type hypersensitivity to human MPO. Five weeks after immunization the left kidney was perfused with products of activated neutrophils, that is, lytic enzymes, particularly proteinase 3 and elastase, MPO, and its substrate  $H_2O_2$ . The rats developed NCGN with interstitial infiltrate and vasculitis (Fig. 2). Whereas MPO, IgG, and C3 could be detected at 24 hours after perfusion along the GBM, immune deposits were generally absent at 4 and 10 days after perfusion, which illustrates the pauci-immune character of the lesions. In control immunized animals perfused with enzymes and  $H_2O_2$  no significant lesions occurred. When MPO-immunized rats were perfused with MPO and  $H_2O_2$  only, more or less comparable lesions developed, but those lesions were accompanied by immune deposits persisting for a longer time along the GBM. From these findings it is suggested that the initial step in the development of NCGN is (focal) immune complex formation. The presence of lytic enzymes, which were concomitantly perfused but may also have been released from neutrophils activated by ANCA, probably is responsible for the degradation of the immune deposits that were detected in the very early stage of the lesions. Yang et al very recently have tried to repeat the experiments of Brouwer et al in both BN rats and spontaneously hypertensive rats [134]. In the latter rats more severe lesions were found demonstrating the additive effects of hypertension. In contrast to Brouwer et al [133] they observed persistence, up to 10 days after perfusion, of immune deposits along the GBM in both rat strains. Differences both in the immunization procedure resulting in different qualities of the antibodies as well as in the composition of the perfusate may explain the discrepancies between both studies.

Anti-MPO antibodies have also been demonstrated in BN rats treated with mercuric chloride [53]. These rats develop a polyclonal autoimmune response comprising, among others, antibodies to MPO. Necrotizing vasculitis, particularly involving the gut, developed in some of the animals, possibly in

conjunction with a microbial infection [135]. The pathophysiological role of anti-MPO in the induction of the vasculitic process is, however, not clear in this particular model. A schematic representation of the possible pathophysiology of ANCA-associated necrotizing vasculitis/glomerulonephritis which summarizes the items discussed before is shown in Figure 3.

#### Impact of ANCA on treatment

Untreated, the outcome of the systemic necrotizing vasculitides is poor. High doses of corticosteroids have improved prognosis. Although treatment with steroids alone seems to be sufficient in less severe forms of polyarteritis nodosa and Churg Strauss syndrome, many cases of systemic vasculitis treated with corticosteroids alone still progress to renal failure or show a fatal outcome. In WG, for instance, corticosteroids have improved the average survival time from 5 to 12.5 months only. The introduction of cyclophosphamide [136, 137] has been a major advance in the treatment of the necrotizing vasculitides resulting in complete remission in 14 out of 17 patients with severe vasculitis [136] and 79 out of 85 patients with WG [137]. At present, the usual regimen consists of 2 mg/kg/day cyclophosphamide given orally in combination with 1 mg/kg/day prednisolone. Since a considerable number of patients relapse during tapering of immunosuppressives, long-term treatment (1 to 2 years of cyclophosphamide) has been advocated by the NIH group. Conversion to azathioprin after 8 to 12 weeks [138] might result in a higher relapse rate although comparative studies are not available. A major drawback of long-term cyclophosphamide treatment is the occurrence of severe adverse effects, in particular opportunistic infections [139] and bladder toxicity, that is, hemorrhagic cystitis and carcinoma [140]. In lupus nephritis, the frequency of adverse effects seems to be reduced without loss of efficacy by using intravenous pulse cyclophosphamide instead of oral cyclophosphamide



**Fig. 3.** Schematic representation of the possible pathophysiology of ANCA-associated necrotizing vasculitis/glomerulonephritis. 1. Neutrophils (PMN) are primed by low concentrations of cytokines resulting from (local) infection. 2. Primed PMN are further activated by IgG-ANCA to the production of reactive oxygen species (ROS) and the release of lytic enzymes such as proteinase 3 (Pr3) and elastase (HLE). 3. Products of activated PMN induce necrotizing inflammation which might be potentiated by the inhibition by ANCA of the  $\alpha_1$ -antitrypsin ( $\alpha_1$ AT) induced inactivation of Pr3. 4. CD4-positive T-cells, possibly autoreactive to Pr3, may contribute to granuloma formation. 5. Activated PMN may damage endothelial cells to which they adhere as a result of (focal) up-regulation of adhesion molecules. 6. Binding of cationic MPO to polyanionic (basement) membranes is followed by *in situ* immune complex formation; attracted PMN additionally activated by ANCA evoke the initial step of vasculitis/glomerulonephritis and degrade immune complexes.

[141]. In WG, the NIH group described a less favorable therapeutic effect of intravenous pulse compared to oral cyclophosphamide [142]. In ANCA-positive glomerulonephritis and

systemic vasculitis including WG, Falk et al [143], however, found no differences in renal or patient survival between both regimens. A controlled study from the UK also showed that

pulse and oral cyclophosphamide are equally effective in inducing remission in patients with systemic vasculitis [144].

Based on new insights, in part derived from the detection of ANCA, into the possible pathophysiology of the systemic vasculitides, different treatment modalities have been proposed for ANCA-associated glomerulonephritis and systemic vasculitis.

(a) A number of uncontrolled studies have described a favorable effect of trimethoprim/sulfamethoxazole (T/S) in the treatment of WG [145], particularly in limited WG. A prospective study in 17 patients with limited WG recently showed a response rate of 65% [146]. In generalized WG the use of T/S was accompanied by maintenance of remission in 14 out of 32 patients (44%) during a three year period [146]. Prospective controlled studies are, however, not available. The possibly positive effect of T/S might be explained by the observation that relapses of WG are frequently preceded by infections [147]. Our group recently found that chronic nasal carriage of *Staphylococcus aureus* is frequent in patients with WG, occurring in 36 out of 57 patients (63%), and identifies a subgroup more prone to relapses of the disease. During a 3½ year period 21 of the chronic carriers relapsed, compared to 2 out of 21 who were not considered chronic carriers [81]. Also, chronic nasal carriers had an increased risk of being persistently or intermittently positive for ANCA [81]. The inter-relationship between chronic nasal carriage of *Staphylococcus aureus* and prevention of relapses by T/S treatment has not been studied so far. Although the efficacy of T/S needs to be substantiated, this mode of treatment may be particularly useful in the management of chronic inflammation and superimposed infections of nose and sinuses in patients with WG.

(b) Several newly proposed treatment modalities in systemic vasculitis are based on the assumption that ANCA play a critical role in the pathophysiology of the disease. As stated before, rises of c-ANCA titers seem to precede the development of relapses of WG [16]. Based on these findings a controlled prospective study was performed in which patients were assigned to treatment or no treatment once a significant rise of ANCA had occurred [78]. Treatment based on rises of ANCA titer appeared to prevent relapses of WG in this study on a small number of patients. These data have to be confirmed by studies on larger groups of patients.

Plasma exchange (PE) has been proposed as a direct approach to remove pathogenic autoantibodies. A controlled study on the additional role of PE in the initial treatment of patients with necrotizing glomerulonephritis without anti-GBM antibodies was published in 1991 [148]. Included were patients with impaired renal function, crescentic necrotizing glomerulonephritis in the biopsy, and a clinical diagnosis of WG, MPA, or idiopathic rapidly progressive glomerulonephritis. Data on ANCA were not consistently available. Forty-eight cases could be analyzed of whom 23 were treated with immunosuppressives only and 25 with additional PE. Only in patients who were dialysis-dependent at presentation ( $N = 19$ ) was an additional benefit of PE observed: 10 out of 11 patients treated with additional PE recovered from renal failure, whereas only 3 patients recovered out of 8 patients treated with immunosuppressives alone. A comparable beneficial effect has been found for the additional use of pulse methylprednisolone in patients with rapidly progressive glomerulonephritis and crescentic glo-

merulonephritis who were dialysis-dependent at presentation [149]. Thus, either PE or pulse methylprednisolone can be added to the oral regimen described before in patients with ANCA-associated vasculitis/glomerulonephritis who present with acute renal failure.

Intravenous gammaglobulin (IVIg) therapy has been tried in an increasing number of autoimmune diseases. Originally used in autoimmune thrombocytopenia in order to block or saturate Fc-receptor mediated clearance of antibody-coated platelets, IVIg might also exert its effect by the presence in the preparation of anti-idiotypic antibodies which interact with the idiotypic network. Anti-idiotypic antibodies reactive to ANCA have, indeed, been detected in pooled human immunoglobulin and in the sera from patients with ANCA-positive vasculitis drawn during remission [150]. Preliminary data suggest that IVIg infused at 0.4 g/kg/day on five consecutive days may have a beneficial effect in patients with ANCA-positive vasculitis resulting not only in clinical improvement but also in some 50% reduction in levels of ANCA [151]. Controlled prospective studies are, however, needed to demonstrate the clinical usefulness of IVIg.

(c) Inflammatory lesions of lung and kidney in WG are characterized by large mononuclear infiltrates containing monocytes and T cells, with a majority of CD4-positive cells [125, 126]. The antigenic specificities of those T cells are not known, but peripheral blood lymphocytes reactive to ANCA-antigens such as proteinase 3 and MPO have been described [129–131]. In a patient with long-standing unclassified vasculitis treatment with the combination of two monoclonal antibodies, one directed against an antigen present on all mononuclear cells (CDw52) and the other against the CD4 molecule, resulted in long-lasting clinical remission whereas injection of the first antibody alone induced a short-lived remission only [152]. Recently, two additional patients with microscopic polyarteritis unresponsive to conventional treatment were treated with a comparable regimen [153]. Long-lasting remission was reached in one patient, the other developed antibodies to the humanized anti-CDw52 monoclonal antibody. These pilot studies await confirmation from a larger scale controlled study.

## Conclusion

The diagnostic potential of ANCA is now fairly well established for the target antigens proteinase 3 and MPO. The presence of anti-proteinase 3 strongly suggests a diagnosis of Wegener's granulomatosis (WG), either in its generalized or limited presentation, although the association is not absolute. Changes in levels of anti-proteinase 3 in WG generally reflect disease activity. Anti-MPO is associated with various forms of necrotizing vasculitis including idiopathic necrotizing and crescentic glomerulonephritis (NCGN). Anti-MPO also occurs, incidentally, in other diseases. The diagnostic significance of ANCA of other or still unknown specificities has not yet been definitely established.

The pathophysiological role of ANCA has been studied in *in vitro* and *in vivo* models. *In vitro* anti-proteinase 3 interferes with the inactivation of proteinase 3 by  $\alpha_1$ -antitrypsin. ANCA of diverse specificities are able to activate primed neutrophils to the production of reactive oxygen species and the release of



lysosomal enzymes. Both effects may contribute to the inflammatory process. With respect to vasculitis and glomerulonephritis the possible expression of proteinase 3 at the surface of (activated) endothelial cells and the binding of MPO on these cells might allow the respective antibodies to react to their targets *in vivo* and to injure the endothelium. In MPO-immunized animals perfusion of the kidney with the products of activated neutrophils results in the development of pauci-immune NCGN.

Although many questions still remain, the expanding knowledge on ANCA has greatly contributed to the diagnosis and the understanding of the pauci-immune necrotizing vasculitides.

CEES G.M. KALLENBERG, ELISABETH BROUWER, JAN J. WEENING, and JAN W. COHEN TERVAERT  
University Hospital, Groningen,  
and Academic Medical Center, Amsterdam,  
The Netherlands

Reprint requests to C.G.M. Kallenberg, M.D., Ph.D., Department of Clinical Immunology, University Hospital, Oostersingel 59, 9713 EZ Groningen, The Netherlands.

## References

- COUSER WG: Rapidly progressive glomerulonephritis: Classification, pathogenetic mechanisms, and therapy. *Am J Kidney Dis* 11:449-464, 1988
- JENNETTE JC, FALK RJ: Diagnosis and management of glomerulonephritis and vasculitis presenting as acute renal failure. *Med Clin North Am* 74:893-908, 1990
- COHEN TERVAERT JW, GOLDSCHMEDING R, ELEMA JD, VAN DER GIESSEN M, HUITEMA MG, VAN DER HEM GK, THE TH, VON DEM BORNE AEGKR, KALLENBERG CGM: Autoantibodies against myeloid lysosomal enzymes in crescentic glomerulonephritis. *Kidney Int* 37:799-806, 1990
- WIESLANDER J, BARR JF, BUTKOWSKI RJ, EDWARDS SJ, BYGREN P, HEINEGARD D, HUDSON BG: Goodpasture antigen of the glomerular basement membrane: Localization to noncollagenous regions of type IV collagen. *Proc Natl Acad Sci USA* 81:3838-3840, 1984
- STILMANT MM, BOLTON WK, STURGILL BC, SCHMITT GW, COUSER WG: Crescentic glomerulonephritis without immune deposits: Clinicopathologic features. *Kidney Int* 15:184-195, 1979
- JENNETTE JC, WILKMAN AS, FALK RJ: Anti-neutrophil cytoplasmic autoantibody-associated glomerulonephritis and vasculitis. *Am J Pathol* 135:921-930, 1989
- DAVIES DJ, MORAN JE, NIALL JF, RYAN GB: Segmental necrotizing glomerulonephritis with antineutrophil antibody: Possible arbovirus aetiology? *Br Med J* 285:606, 1982
- VAN DER WOUDE FJ, RASMUSSEN N, LOBATO S, WIJK A, PERMIN H, VAN ES LA, VAN DER GIESSEN M, VAN DER HEM GK, THE TH: Autoantibodies to neutrophils and monocytes: A new tool for diagnosis and a marker of disease activity in Wegener's Granulomatosis. *Lancet* ii:425-429, 1985
- SAVAGE COS, WINEARLS CG, JONES SJ, MARSHALL PD, LOCKWOOD CM: Prospective study of radioimmunoassay for antibodies against neutrophil cytoplasm in diagnosis of systemic vasculitis. *Lancet* 8:1389-1393, 1987
- FALK RJ, JENNETTE JC: Anti-neutrophil cytoplasmic autoantibodies with specificity for myeloperoxidase in patients with systemic vasculitis and idiopathic necrotizing and crescentic glomerulonephritis. *N Engl J Med* 318:1651-1657, 1988
- MATHIESON PW (editor): Proceedings of the 5th International ANCA Workshop. *Clin Exp Immunol* 93 (Suppl 1):S1-S47, 1993
- VAN DER WOUDE FJ, DAHA MR, VAN ES LA: The current status of neutrophil cytoplasmic antibodies. *Clin Exp Immunol* 78:143-148, 1989
- JENNETTE JC, FALK RJ: Antineutrophil cytoplasmic autoantibodies and associated diseases: A review. *Am J Kidney Dis* 15:517-529, 1990
- HAGEN EC, BALLIEUX BE, VAN ES LA, DAHA MR, VAN DER WOUDE FJ: Antineutrophil cytoplasmic autoantibodies: A review of the antigens involved, the assays and the clinical and possible pathogenetic consequences. *Blood* 81:1996-2002, 1993
- WIJK A: Delineation for a standard procedure for indirect immunofluorescence detection of ANCA. *APMIS* 97 (Suppl 6):S12-S13, 1989
- COHEN TERVAERT JW, VAN DER WOUDE FJ, FAUCI AS, AMBRUS JL, VELOSA J, KEANE WF, MEIJER S, VAN DER GIESSEN M, THE TH, VAN DER HEM GK, KALLENBERG CGM: Association between active Wegener's Granulomatosis and anticytoplasmic antibodies. *Arch Intern Med* 149:2461-2465, 1989
- KALLENBERG CGM, MULDER AHL, COHEN TERVAERT JW: Antineutrophil cytoplasmic antibodies: A still growing class of autoantibodies in inflammatory disorders. *Am J Med* 93:675-682, 1992
- PETER HH, METZGER D, RUMP A, RÖTHER E: ANCA in diseases other than systemic vasculitis. *Clin Exp Immunol* 91 (Suppl 1):S12-S14, 1993
- FABER V, ELLING P, NORUP G, MANS A, NISSEN NI: An antinuclear factor specific for leucocytes. *Lancet* ii:344-345, 1964
- WIJK A: Granulocyte-specific antinuclear antibodies. *Allergy* 35:263-289, 1980
- CHARLES LA, FALK RJ, JENNETTE JC: Reactivity of anti-neutrophil cytoplasmic autoantibodies with HL-60 cells. *Clin Immunol Immunopathol* 53:243-253, 1989
- PRYZWANSKY MB, MARTIN LE, SPITZNAGEL JK: Immunocytochemical localization of myeloperoxidase, lactoferrin, lysozyme, and neutral proteases in human monocytes and neutrophilic granulocytes. *J Reticuloendothel Soc* 24:295-310, 1978
- MULDER AHL, HORST G, VAN LEEUWEN MA, LIMBURG PC, KALLENBERG CGM: Antineutrophil cytoplasmic antibodies in rheumatoid arthritis: Characterization and clinical correlations. *Arthritis Rheum* 36:1054-1060, 1993
- HAGEN EC, ANDRASSY K, CSERNOK E, DAHA MR, GASKIN G, GROSS WL, LESAVRE PH, LÜDEMANN J, PUSEY CD, RASMUSSEN N, SAVAGE COS, SINICO A, WIJK A, VAN DER WOUDE FJ: The value of indirect immunofluorescence and solid phase techniques for ANCA detection. *J Immunol Meth* 159:1-16, 1993
- GOLDSCHMEDING R, VAN DER SCHOOT CE, TEN BOKKEL HUININK D, HACK CE, VAN DEN ENDE ME, KALLENBERG CGM, VON DEM BORNE AEGKR: Wegener's Granulomatosis autoantibodies identify a novel diisopropylfluorophosphate-binding protein in the lysosomes of normal human neutrophils. *J Clin Invest* 84:1577-1587, 1989
- NILES JL, McCLUSKEY RT, AHMAD MF, ARNAOUT MA: Wegener's Granulomatosis autoantigen is a novel serine proteinase. *Blood* 74:1888-1893, 1989
- LÜDEMANN J, UTECHT B, GROSS WL: Anti-neutrophil cytoplasmic antibodies in Wegener's Granulomatosis recognize an elastolytic enzyme. *J Exp Med* 171:357-362, 1990
- CAMPANELLI D, MELCHIOR M, FU Y, NAKATA N, SHUMAN H, NATHAN C, GABAY JE: Cloning of cDNA for proteinase 3: A serine protease, antibiotic, and autoantigen from human neutrophils. *J Exp Med* 172:1709-1715, 1990
- CAMPANELLI D, DETMERS PA, NATHAN CF, GABAY JE: Azurocidin and a homologous serine protease from neutrophils. Differential antimicrobial and proteolytic properties. *J Clin Invest* 85:904-915, 1990
- BORIES D, RAYNAL MC, SOLOMON DH, DARZYNKIEWICZ Z, CAYRE Y: Down-regulation of a serine protease, myeloblastin, causes growth arrest and differentiation of promyelocytic leukemia cells. *Cell* 59:959-968, 1989
- KAM CM, KERRIGAN JE, DOLMAN KM, GOLDSCHMEDING R, VON DEM BORNE AEGKR, POWERS JC: Substrate and inhibitor studies on Proteinase 3. *FEBS Lett* 297:119-123, 1992
- DOLMAN KM, VAN DE WIEL BA, KAM CM, ABBINK JJ, HACK CE, SONNENBERG A, POWERS JC, VON DEM BORNE AEGKR,

- GOLDSCHMEDING R: Determination of proteinase 3/ $\alpha_1$ -antitrypsin complexes in inflammatory fluids. *FEBS Lett* 314:117-121, 1992
33. DALPÉ G, BOIRE G, MÉNARD HA: The conformational determinants recognized by Wegener's c-ANCA are situated at or near the catalytic domain of myeloblastin. *Clin Exp Immunol* 93 (Suppl 1):S21, 1993
  34. BINI P, GABAY JE, TEITEL A, MELCHIOR M, ZHOU JL, ELKON KB: Antineutrophil cytoplasmic autoantibodies in Wegener's Granulomatosis recognize conformational epitope(s) on proteinase 3. *J Immunol* 149:1409-1415, 1992
  35. VAN DE WIEL A, DOLMAN KM, VAN DER MEER-GERRITSEN CH, HACK CE, VON DEM BORNE AEGKR, GOLDSCHMEDING R: Interference of Wegener's Granulomatosis autoantibodies with neutrophil proteinase 3 activity. *Clin Exp Immunol* 90:409-414, 1992
  36. GOLDSCHMEDING R, VAN DER SCHOOT CE, CALAFAT J, WYERMANS PW, VON DEM BORNE AEGKR: Differential expression of proteinase 3, leukocyte elastase and myeloperoxidase in myeloid leukaemia and cell line cells, in *Target Antigens of Antineutrophil Cytoplasmic Antibodies* (Thesis), edited by GOLDSCHMEDING R, Amsterdam, The Netherlands, 1992, pp 75-84
  37. CHARLES LA, FALK RJ, JENNETTE JC: Reactivity of neutrophil cytoplasmic autoantibodies with mononuclear phagocytes. *J Leuk Biol* 51:65-68, 1992
  38. CALAFAT J, GOLDSCHMEDING R, RINGELING PL, JANSSEN H, VAN DER SCHOOT CE: *In situ* localization by double-labeling immunoelectron microscopy of anti-neutrophil cytoplasmic autoantibodies in neutrophils and monocytes. *Blood* 75:242-250, 1990
  39. CHARLES LA, CALDAS MLR, FALK RJ, TERRELL RS, JENNETTE JC: Antibodies against granule proteins activate neutrophils *in vitro*. *J Leuk Biol* 50:539-546, 1991
  40. CSERNOK E, SCHMITT WH, BAINTON D, GROSS WL: Translocation of Pr-3 on the cell surface of neutrophils: Association with disease activity in Wegener's granulomatosis. (abstract) *Arthritis Rheum* 34:S79, 1991
  41. MAYET WJ, HERMANN E, CSERNOK E, KNUTH A, PORALLA T, GROSS WL, MEYER ZUM BÜSCHENFELDE KH: A human renal cancer line as a new antigen source for the detection of antibodies to cytoplasmic and nuclear antigens in sera of patients with Wegener's Granulomatosis. *J Immunol Meth* 143:57-64, 1991
  42. MAYET WJ, CSERNOK E, SZYMKOWIAK C, GROSS WL, MEYER ZUM BÜSCHENFELDE KH: Human endothelial cells express proteinase 3, the target antigen of anti-cytoplasmic antibodies in Wegener's Granulomatosis. *Blood* 82:1221-1229, 1993
  43. KAO RC, WEHNER NG, SKUBITZ KM, GRAY BH, HOIDAL JR: Proteinase 3: A distinct human polymorphonuclear leukocyte proteinase that produces emphysema in hamsters. *J Clin Invest* 82:1963-1973, 1988
  44. LÜDEMANN J, UTECHT B, GROSS WL: Detection and quantitation of anti-neutrophil cytoplasmic antibodies in Wegener's granulomatosis by ELISA using affinity-purified antigen. *J Immunol Meth* 114:167-174, 1988
  45. GASKIN G, TURNER AN, RYAN JJ, REES AJ, PUSEY CD: Purification of proteinase 3 and its reactivity with sera from patients with Wegener's granulomatosis and microscopic polyarteritis. (abstract) *J Am Soc Nephrol* 2:595, 1991
  46. GOLDSCHMEDING R, COHEN TERVAERT JW, VAN DER SCHOOT CE, VAN DER VEEN C, KALLENBERG CGM, VON DEM BORNE AEGKR: ANCA, anti-myeloperoxidase, and anti-elastase: Three members of a novel class of autoantibodies against myeloid lysosomal enzymes. *APMIS* 97(S6):48-49, 1989
  47. FALK RJ, JENNETTE JC: Immunofluorescence and ELISA determination of ANCA with description of a sub-class with anti-myeloperoxidase activity. *APMIS* 97(S6):45, 1989
  48. COHEN TERVAERT JW, GOLDSCHMEDING R, ELEMA JD, LIMBURG PC, VAN DER GIESSEN M, HUITEMA MG, KOOLEN MI, HENÉ RJ, THE TH, VAN DER HEM GK, VON DEM BORNE AEGKR, KALLENBERG CGM: Association of autoantibodies to myeloperoxidase with different forms of vasculitis. *Arthritis Rheum* 33:1264-1272, 1990
  49. SEGELMARK M, BASLUND B, WIESLANDER J: Some patients with c-ANCA pattern have antibodies to myeloperoxidase and not to proteinase 3. *Clin Exp Immunol* 93 (Suppl 1):S32, 1993
  50. WEISS SJ: Tissue destruction by neutrophils. *N Engl J Med* 320:365-376, 1989
  51. ROBERTS DE, PEEBLES C, CURD JG, TAN EM, RUBIN RL: Autoantibodies to native myeloperoxidase in patients with pulmonary hemorrhage and acute renal failure. *J Clin Immunol* 11:389-397, 1991
  52. FALK RJ, BECKER M, TERRELL R, JENNETTE JC: Anti-myeloperoxidase autoantibodies react with native but not denatured myeloperoxidase. *Clin Exp Immunol* 89:274-278, 1992
  53. ESNAULT VLM, MATHIESON PW, THIRU S, OLIVEIRA DBG, LOCKWOOD CM: Autoantibodies to myeloperoxidase in Brown Norway rats treated with mercuric chloride. *Lab Invest* 67:114-120, 1992
  54. CAMBRIDGE G, HALL TJ, LEAKER B: Heterogeneity of antibodies to myeloperoxidase in sera from patients with vasculitis. (abstract) *J Am Soc Nephrol* 2:590, 1991
  55. NACHMAN PH, TERRELL RS, JENNETTE JC, FALK RJ: Naturally occurring anti-myeloperoxidase antibodies. *Clin Exp Immunol* 93 (Suppl 1):S18, 1993
  56. JONES DB, COULSON AFW, DUFF GW: Sequence homologies between hsp60 and autoantigens. *Immunol Today* 14:115-118, 1993
  57. AUDRAIN MAP, BARANGER TAR, LOCKWOOD CM, ESNAULT VLM: Characterization of mice monoclonals directed against commercially purified myeloperoxidase. *Clin Exp Immunol* 93 (Suppl 1):S18, 1993
  58. COREMANS IEM, HAGEN EC, DAHA MR, VAN DER WOUDE FJ, VAN DER VOORT EAM, KLEIJBURG-VAN DER KEUR C, BREEDVELD FC: Antilactoferrin antibodies in patients with rheumatoid arthritis are associated with vasculitis. *Arthritis Rheum* 35:1466-1475, 1992
  59. MULDER AHL, BROEKROELOFS J, HORST G, LIMBURG PC, NELIS GF, KALLENBERG CGM: Anti-neutrophil cytoplasmic antibodies (ANCA) in inflammatory bowel disease: Characterization and clinical correlates. *Clin Exp Immunol* 95:490-497, 1994
  60. COREMANS IEM, HAGEN EC, DAHA MR, VAN DER WOUDE FJ, VAN DER VOORT EAM, BREEDVELD FC: Anti-lactoferrin antibodies in patients with Felty's syndrome. *Clin Exp Immunol* 93 (Suppl 1):S33, 1993
  61. LEE SS, LAWTON JWM, CHAN CE: Antilactoferrin antibody in systemic lupus erythematosus. *Br J Rheumatol* 31:669-673, 1992
  62. PEEN E, ALMER S, BODEMAR G, RYDER BO, SROLIN C, TEJLE K, SKOGH T: Anti-lactoferrin antibodies and other types of ANCA in ulcerative colitis, primary sclerosing cholangitis and Crohn's disease. *Gut* 34:56-62, 1993
  63. SINICO RA, POZZI C, RADICE A, TINCANI A, LI VECCHI M, ROTA S, COMOTTI C, FERRARIO F, D'AMICO G: Clinical significance of antineutrophil cytoplasmic autoantibodies with specificity for lactoferrin in renal diseases. *Am J Kidney Dis* 22:253-260, 1993
  64. GROSS WL, SCHMITT WH, CSERNOK E: ANCA and associated diseases: Immunodiagnostic and pathogenetic aspects. *Clin Exp Immunol* 91:1-12, 1993
  65. COHEN TERVAERT JW, MULDER AHL, STEGEMAN CA, ELEMA JD, HUITEMA MG, THE TH, KALLENBERG CGM: The occurrence of autoantibodies to human leukocyte elastase in Wegener's Granulomatosis and other inflammatory disorders. *Ann Rheum Dis* 52:115-120, 1993
  66. HALBWACHS-MECARELLI LH, NUSBAUM LH, NOËL LH, REUMAUX D, ERLINGER S, GRÜNFELD JP, LESAVRE P: Antineutrophil cytoplasmic antibodies (ANCA) directed against Cathepsin G in ulcerative colitis, Crohn's disease and primary sclerosing cholangitis. *Clin Exp Immunol* 90:79-84, 1992
  67. KANEKO K, SUZUKI Y, YAMASHIRO Y, YABUTA S: Is p-ANCA in ulcerative colitis directed against glucuronidase? *Lancet* 341:320, 1993
  68. MOODIE FDL, LEAKER B, CAMBRIDGE G, TOTTY NF, SEGAL AW: Alpha-enolase: A novel cytosolic autoantigen in ANCA positive vasculitis. *Kidney Int* 43:675-681, 1993
  69. NÖLLE B, SPECKS U, LÜDEMANN J, ROHRBACH MS, DEREMEE



- RA, GROSS WL: Anticytoplasmic antibodies: Their immunodiagnostic value in Wegener's Granulomatosis. *Ann Intern Med* 111: 28-40, 1989
70. WEBER MFA, ANDRASSY K, PULLIG O, KODERISCH J, NETZER K: Antineutrophil cytoplasmic antibodies and antiglomerular basement membrane antibodies in Goodpasture's syndrome and in Wegener's granulomatosis. *J Am Soc Nephrol* 2:1227-1234, 1992
  71. KALLENBERG CGM, COHEN TERVAERT JW: Anti-neutrophilic cytoplasmic antibodies: New tools in the diagnosis and follow-up of necrotizing glomerulonephritis, in *International Yearbook of Nephrology 1992*, edited by ANDREUCCI VE, FINE LG, 1992, pp. 313-336
  72. COHEN TERVAERT JW, LIMBURG PC, ELEMA JD, HUITEMA MG, HORST G, THE TH, KALLENBERG CGM: Detection of autoantibodies against myeloid lysosomal enzymes: A useful adjunct to classification of patients with biopsy-proven necrotizing arteritis. *Am J Med* 91:59-66, 1991
  73. LEAVITT RY, FAUCI AS, BLOCH DA, MICHEL BA, HUNDER GG, AREND WP, CALABRESE LH, FRIES JF, LIE JT, LIGHTFOOT RW, MASI AT, MCSHANE DJ, MILLS JA, STEVENS MB, WALLACE SL, ZVAIFLER NJ: The American College of Rheumatology 1990 criteria for the classification of Wegener's Granulomatosis. *Arthritis Rheum* 33:1101-1107, 1990
  74. JENNETTE JC, FALK RJ, ANDRASSY K, BACON BA, CHURG J, GROSS WL, HAGEN EC, HOFFMANN GS, HUNDER GG, KALLENBERG CGM, McCLUSKEY RT, SINICO RA, REES AJ, VAN ES LA, WALDHERR R, WIIK A: Nomenclature of systemic vasculitides: The proposal of an international consensus conference. *Arthritis Rheum* 37:187-192, 1994
  75. PUDIFIN DJ, DUURSMA J, GATHIRAM V, JACKSON TFGH: Serum from patients with invasive amoebiasis has anti-neutrophil cytoplasmic antibody activity. *Clin Exp Immunol* 93 (Suppl 1):S33, 1993
  76. DOLMAN KM, GANS ROB, VERVAART THJ, ZEVENBERGEN G, MAINGAY D, NIKKELS RE, DONKER AJM, VON DEM BORNE AEGKR, GOLDSCHMEDING R: Vasculitic disorders and anti-neutrophil cytoplasmic autoantibodies associated with propylthiouracil therapy. *Lancet* 342:651-652, 1993
  77. EGNER W, CHAPEL HM: Titration of antibodies against neutrophil cytoplasmic antigens is useful in monitoring disease activity in systemic vasculitides. *Clin Exp Immunol* 82:244-249, 1990
  78. COHEN TERVAERT JW, HUITEMA MG, HENÉ RJ, SLUITER WJ, THE TH, VAN DER HEM GK, KALLENBERG CGM: Prevention of relapses in Wegener's granulomatosis by treatment based on antineutrophil cytoplasmic antibody titre. *Lancet* 336:709-711, 1990
  79. KERR GR, FLEISCHER THA, HALLAHAN CW, LEAVITT RY, FAUCI AS, HOFFMAN GS: Limited prognostic value of changes in antineutrophil cytoplasmic antibody titer in patients with Wegener's granulomatosis. *Arthritis Rheum* 36:365-371, 1993
  80. COHEN TERVAERT JW, STEGEMAN CA, HUITEMA MG, KALLENBERG CGM: Comments on article by Kerr et al. *Arthritis Rheum* (in press)
  81. STEGEMAN CA, COHEN TERVAERT JW, MANSON WL, KALLENBERG CGM: Chronic nasal carriage of *Staphylococcus aureus* in Wegener's Granulomatosis: Identification of a subgroup more prone to relapses. *Ann Intern Med* 120:12-17, 1994
  82. SPENCER SJW, BURNS A, GASKIN G, PUSEY CD, REES AJ: HLA class II specificities in vasculitis with antibodies to neutrophil cytoplasmic antigens. *Kidney Int* 41:1059-1063, 1992
  83. HUNDER GG, AREND WP, BLOCH DA, CALABRESE LH, FAUCI AS, FRIES JF, LEAVITT RY, LIE JT, LIGHTFOOT RW JR, MASI AT, MCSHANE DJ, MICHEL BA, MILLS JA, STEVENS MB, WALLACE SC, ZVAIFLER NJ: The American College of Rheumatology 1990 criteria for the classification of vasculitis. *Arthritis Rheum* 33:1065-1067, 1990
  84. SAVAGE COS, WINEARLS CG, EVANS DJ, REES AJ, LOCKWOOD CM: Microscopic polyarteritis: Presentation, pathology and prognosis. *Q J Med* 56:467-483, 1985
  85. GASKIN G, SAVAGE COS, RYAN JJ, JONES S, LOCKWOOD CM, REES AJ, PUSEY CD: Anti-neutrophil cytoplasmic antibodies and disease activity during long-term follow-up of 70 patients with systemic vasculitis. *Nephrol Dial Transplant* 6:689-694, 1991
  86. JAYNE DRW, MARSHALL PD, JONES SJ, LOCKWOOD CM: Autoantibodies to GBM and neutrophil cytoplasm in rapidly progressive glomerulonephritis. *Kidney Int* 37:965-970, 1990
  87. BOSCH X, MIRAPEIX E, FONT J, BORRELLAS X, RODRIGUEZ R, LOPES-SOTO A, INGELMO M, REVERT L: Prognostic implication of anti-neutrophil cytoplasmic autoantibodies with myeloperoxidase specificity in anti-glomerular basement membrane disease. *Clin Nephrol* 36:107-113, 1991
  88. NILES JL, PAN G, COLLINS AB, SHANNON T, SKATES S, FIENBERG R, ARNAOUT MA, McCLUSKEY RT: Antigen-specific radioimmunoassay for anti-neutrophil cytoplasmic antibodies in the diagnosis of rapidly progressive glomerulonephritis. *J Am Soc Nephrol* 2:27-36, 1991
  89. COHEN TERVAERT JW, GOLDSCHMEDING R, VON DEM BORNE AEGKR, KALLENBERG CGM: Anti-myeloperoxidase antibodies in the Churg Strauss Syndrome. *Thorax* 46:70-71, 1991
  90. GUILLEVIN L, VISSER H, NOËL LH, POURRAT J, VERNIER I, GAYRAUD M, OKSMAN F, LESAVRE P: Antineutrophil cytoplasm antibodies in systemic polyarteritis nodosa with and without Hepatitis B Virus infection and Churg-Strauss syndrome. *J Rheumatol* 20:1345-1349, 1993
  91. GILBERT RD, SHAH V, READER J, DILLON MJ: Cathepsin G specific IgM anti-neutrophil cytoplasmic antibodies (ANCA) and anti-endothelial cell antibodies (AECA) in acute Kawasaki disease. *Clin Exp Immunol* 93 (Suppl 1):S30, 1993
  92. DAGENAIS P, DALPÉ G, FERNANDES MF, BOIRE G, KEYSTONE EC, GROSS WL, WEYAND MC, MÉNARD HA: ANCAs in patients with Takayasu's arteritis. *Clin Exp Immunol* 93 (Suppl 1):S34, 1993
  93. McHUGH NJ, JAMES IE, PLANT G: Anticardiolipin and antineutrophil antibodies in giant cell arteritis. *J Rheumatol* 17:916-922, 1990
  94. VAN DER WALL BAKE AWL, LOBATO S, JONGES L, DAHA MR, VAN ES LA: IgA antibodies directed against cytoplasmic antigens of polymorphonuclear leukocytes in patients with Henoch-Schönlein purpura. *Adv Exp Med Biol* 216:1593-1598, 1987
  95. SAULSBURY T, KIRKPATRICK PR, BOLTON WK: IgA antineutrophil cytoplasmic antibody in Henoch-Schönlein purpura. *Am J Nephrol* 11:295-300, 1991
  96. GUEIRARD P, DELPECH A, GILBERT D, GODIN M, LE LOET X, TRON F: Anti-myeloperoxidase antibodies: Immunological characteristics and clinical associations. *J Autoimmun* 4:517-527, 1991
  97. GALLICHO MC, SAVIGE JA: Detection of anti-myeloperoxidase and anti-elastase antibodies in vasculitis and infections. *Clin Exp Immunol* 84:232-237, 1991
  98. NÄSSBERGER L, SJÖHOLM AG, JONSSON H, STURFELT G, ÅKESSEN A: Autoantibodies against neutrophil cytoplasm components in systemic lupus erythematosus and in hydralazine-induced lupus. *Clin Exp Immunol* 81:380-383, 1990
  99. CALABRESE P, EDWARDS EA, SCHILLING RF: Fluorescent antiglobulin studies in leukopenic and related disorders. *J Clin Invest* 38:2091-2100, 1959
  100. PETER HH, METZGER D, RUMP A, RÖTHER E: ANCA in diseases other than systemic vasculitis. *Clin Exp Immunol* 93 (Suppl 1):S12-S14, 1993
  101. DUERR RH, TARGAN SR, LANDERS CJ, SUTHERLAND LR, SHANAHAN F: Anti-neutrophil cytoplasmic antibodies in ulcerative colitis. Comparison with other colitides/diarrheal illnesses. *Gastroenterology* 100:1590-1596, 1991
  102. SAXON A, SHARAHAN F, LANDERS C, GANZ T, TARGAN S: A distinct subset of antineutrophil cytoplasmic antibodies is associated with inflammatory bowel disease. *J Allergy Clin Immunol* 86:202-210, 1990
  103. RUMP JA, SCHÖLMERICH J, GROSS V, ROTH M, HELFESRIEDER R, RAUTMANN A, LÜDEMANN J, GROSS WL: A new type of perinuclear anti-neutrophil cytoplasmic antibody (p-ANCA) in active ulcerative colitis but not in Crohn's disease. *Immunobiology* 181:406-413, 1991
  104. CAMBRIDGE G, RAMPTON DS, STEVENS TRJ, MCCARTHY DA, KAMM M, LEAKER B: Anti-neutrophil antibodies in inflammatory bowel diseases: Prevalence and diagnostic role. *Gut* 33:668-674, 1992
  105. BROEKROELOFS J, MULDER AHL, NELIS GF, WESTERVELD BD,



- COHEN TERVAERT JW, KALLENBERG CGM: Anti-neutrophil cytoplasmic antibodies (ANCA) in sera from patients with inflammatory bowel disease: Relation to disease pattern and disease activity. *Dig Dis Sci* (in press)
106. DUERR RH, TARGAN SR, LANDERS CJ, LARUSSO NF, LINDSAY KL, WIESNER RH, SHANAHAN F: Neutrophil cytoplasmic antibodies: A link between primary sclerosing cholangitis and ulcerative colitis. *Gastroenterology* 100:1385-1391, 1991
  107. MULDER AHL, HORST G, HAAGSMA EB, LIMBURG PC, KLEIBEU-KER JH, KALLENBERG CGM: Prevalence and characterization of anti-neutrophil cytoplasmic antibodies in autoimmune liver diseases. *Hepatology* 17:411-417, 1993
  108. KLAASSEN RJJ, GOLDSCHMEDING R, DOLMAN KM, VLEKKE ABJ, WEIGEL HM, EEF TINCK SCHATTE NKERK JKM, MULDER JW, WESTEDT ML, VON DEM BORNE AEGKR: Anti-neutrophil cytoplasmic autoantibodies in patients with symptomatic HIV infection. *Clin Exp Immunol* 87:24-30, 1992
  109. EFTHINIOU J, SPICKETT G, LANE D, THOMPSON A: Anti-neutrophil cytoplasmic antibodies, cystic fibrosis and infection. *Lancet* 337:1037-1038, 1991
  110. DOLMAN KM, STEGEMAN CA, VAN DE WIEL BA, HACK CE, VON DEM BORNE AEGKR, KALLENBERG CGM, GOLDSCHMEDING R: Relevance of classic anti-neutrophil cytoplasmic autoantibody (c-ANCA)-mediated inhibition of proteinase 3- $\alpha$ -antitrypsin complexation to disease activity in Wegener's Granulomatosis. *Clin Exp Immunol* 93:405-410, 1993
  111. TESTA A, AUDRAIN M, BARANGER T, SESBOUÉ R, MARTIN JP, ESNAULT VLM: Anti-neutrophil cytoplasm antibodies and alpha-1-antitrypsin phenotype. *Clin Exp Immunol* 93 (Suppl 1):S16, 1993
  112. SAVAGE COS, GASKIN G, PUSEY CD: Anti-neutrophil cytoplasm antibodies (ANCA) can recognize vascular endothelial cell-bound ANCA-associated autoantigens. *J Exp Nephrol* 1:190-195, 1993
  113. BALLIEUX BEPB, ZONDERVAN K, HAGEN EC, VAN DER WOUDE FJ, VAN ES LA, DAHA MR: Differential binding of MPO and Pr3 to monolayers of endothelial cells. *Clin Exp Immunol* 93 (Suppl 1):S17, 1993
  114. FALK RJ, TERRELL RS, CHARLES LA, JENNETTE JC: Anti-neutrophil cytoplasmic autoantibodies induce neutrophils to degranulate and produce oxygen radicals in vitro. *Proc Natl Acad Sci USA* 87:4115-4119, 1990
  115. MULDER AHL, HORST G, LIMBURG PC, KALLENBERG CGM: Activation of neutrophils by anti-neutrophil cytoplasmic antibodies is FcR-dependent. *Clin Exp Immunol* 93 (Suppl 1):S16, 1993
  116. PORGES AJ, REDECHA PB, CSERNOK E, GROSS WL, KIMBERLY RP: Monoclonal ANCA (anti-MPO and anti-Pr3) engage and activate neutrophils via Fc $\gamma$  Receptor IIA. *Clin Exp Immunol* 93 (Suppl 1):S18, 1993
  117. BROUWER E, COHEN TERVAERT JW, HORST G, HUITEMA MG, VAN DER GIESSEN M, LIMBURG PC, KALLENBERG CGM: Predominance of IgG1 and IgG4 subclasses of anti-neutrophil cytoplasmic autoantibodies (ANCA) in patients with Wegener's granulomatosis and related disorders. *Clin Exp Immunol* 83:379-386, 1991
  118. FUJIMOTO T, LOCKWOOD CM: Antineutrophil cytoplasm antibodies (ANCA) activate protein kinase C in human neutrophils and HL-60 cells. (abstract) *Am J Kidney Dis* 18:204, 1991
  119. LAI KN, LOCKWOOD CM: The effect of anti-neutrophil cytoplasm antibodies on the signal transduction in human neutrophils. *Clin Exp Immunol* 85:396-401, 1991
  120. JENNETTE JC, EWERT BH, FALK RJ: Do antineutrophil cytoplasmic autoantibodies cause Wegener's granulomatosis and other forms of necrotizing vasculitis? *Rheum Dis Clin N Am* 19:1-28, 1993
  121. SAVAGE COS, POTTINGER BE, GASKIN G, PUSEY CD, PEARSON JD: Autoantibodies developing to myeloperoxidase and proteinase 3 in systemic vasculitis stimulate neutrophil cytotoxicity towards cultured endothelial cells. *Am J Pathol* 141:335-342, 1992
  122. EWERT BH, JENNETTE JC, FALK RJ: Anti-myeloperoxidase antibodies stimulate neutrophils to damage human endothelial cells. *Kidney Int* 41:375-383, 1992
  123. KEOGAN MT, RIFKIN I, RONDA N, LOCKWOOD CM, BROWN DL: Antineutrophil cytoplasm antibodies increase neutrophil adhesion to cultured human endothelium. *Adv Exp Med Biol* 336:115-119, 1993
  124. BROUWER E, HUITEMA MG, MULDER AHL, HEERINGA P, VAN GOOR H, COHEN TERVAERT JW, WEENING JJ, KALLENBERG CGM: Neutrophil activation *in vitro* and *in vivo* in Wegener's granulomatosis. *Kidney Int* 45:1121-1131, 1994
  125. GEPHARDT GN, AHMED M, TUBBS RR: Pulmonary vasculitis (Wegener's granulomatosis). Immunohistochemical study of T and B cell markers. *Am J Med* 74:700-704, 1983
  126. TEN BERGE RJM, WILMINK JM, MEYER CHRJLM, SURACHNO J, TEN VEEN KH, BALK TG, SCHELLEKENS PT: Clinical and immunological follow-up in patients with severe renal disease in Wegener's granulomatosis. *Am J Nephrol* 5:21-29, 1985
  127. SCHMITT WH, HEESSEN C, CSERNOK E, GROSS WL: Elevated serum levels of soluble interleukin-2-receptor (sIL-2R) in Wegener's granulomatosis: Association with disease activity. *Arthritis Rheum* 35:108-112, 1992
  128. STEGEMAN CA, COHEN TERVAERT JW, HUITEMA MG, KALLENBERG CGM: Serum markers of T-cell activation in relapses of Wegener's Granulomatosis. *Clin Exp Immunol* 91:415-420, 1993
  129. VAN DER WOUDE FJ, VAN ES LA, DAHA MR: The role of the c-ANCA antigen in the pathogenesis of Wegener's granulomatosis. A hypothesis based on both humoral and cellular mechanisms. *Neth J Med* 36:169-171, 1990
  130. PETERSEN J, RASMUSSEN N, SZPIAT W, HERMANN E, MAYET W: T lymphocyte proliferation to neutrophil cytoplasmic antigen(s) in Wegener's granulomatosis. *Am J Kidney Dis* 18:205, 1991
  131. BROUWER E, STEGEMAN CA, HUITEMA MG, LIMBURG PC, KALLENBERG CGM: T-cell reactivity to proteinase 3 and myeloperoxidase in patients with Wegener's granulomatosis. (submitted for publication)
  132. KOBAYASHI K, SHIBATA T, SUGISAKI T: Aggravation of rat Masugi nephritis by heterologous anti-rat myeloperoxidase antibody. *Clin Exp Immunol* 93 (Suppl 1):S20, 1993
  133. BROUWER E, HUITEMA MG, KLOK PA, WEERD H DE, COHEN TERVAERT JW, WEENING JJ, KALLENBERG CGM: Anti-myeloperoxidase-associated proliferative glomerulonephritis: An animal model. *J Exp Med* 177:905-914, 1993
  134. YANG JJ, TUTTLE R, JENNETTE JC, FALK RJ: Glomerulonephritis in rats immunized with myeloperoxidase. *Clin Exp Immunol* 93 (Suppl 1):S22, 1993
  135. MATHIESON PW, THIRU S, OLIVEIRA DBG: Mercuric chloride-treated Brown Norway rats develop widespread tissue injury including necrotizing vasculitis. *Lab Invest* 67:121-129, 1992
  136. FAUCI AS, KATZ P, HAYNES BF, WOLFF SM: Cyclophosphamide therapy of severe systemic necrotizing vasculitis. *N Engl J Med* 301:235-238, 1979
  137. FAUCI AS, HAYNES BF, KATZ P, WOLFF SM: Wegener's Granulomatosis: prospective clinical and therapeutic experience with 85 patients for 21 years. *Ann Intern Med* 98:76-85, 1983
  138. SERRA A, CAMERON JS, TURNER DR, HARTLEY B, OGG CS, NIELD GH, WILLIAMS DG, TAUBE D, BROWN CB, HICKS JA: Vasculitis affecting the kidney. Presentation, histopathology and long-term outcome. *Q J Med* 53:181-207, 1984
  139. BRADLEY JD, BRANDT KD, KATZ BP: Infectious complications of cyclophosphamide treatment for vasculitis. *Arthritis Rheum* 32:45-53, 1989
  140. STILLWALL TJ, BENSON RC, DEREMEE RA, McDONALD TJ, WEILAND LH: Cyclophosphamide-induced bladder toxicity in Wegener's Granulomatosis. *Arthritis Rheum* 31:465-470, 1988
  141. BALOW JE, AUSTIN HA, TSOKOS CG, ANTONOVYCH TT, STEINBERG AD, KLIPPEL JH: Lupus nephritis. *Ann Intern Med* 106:79-94, 1987
  142. HOFFMAN GS, LEAVITT RY, FLEISHER THA, MINOR JR, FAUCI AS: Treatment of Wegener's Granulomatosis with intermittent high-dose intravenous cyclophosphamide. *Am J Med* 89:403-410, 1990
  143. FALK JR, HOGAN S, CAREY TS, JENNETTE JC: Clinical course of anti-neutrophil cytoplasmic autoantibody-associated glomerulonephritis and systemic vasculitis. *Ann Intern Med* 113:656-663, 1990

144. ADU D, PALL A, LUGMANI RA, RICHARDS N, HOWIE AJ, EMERY P, MICHAEL J, BACON PA: Controlled trial of treatment of vasculitis. *Clin Exp Immunol* 93 (Suppl 1):38, 1993
145. DEREMEE RA: The treatment of Wegener's Granulomatosis with trimethoprim/sulfamethoxazole: Illusion or vision? *Arthritis Rheum* 31:1068-1072, 1988
146. REINHOLD-KELLER E, BEIGEL A, DUNCKER G, HELLER M, GROSS WL: Trimethoprim/sulfamethoxazole in the long-term treatment of Wegener's granulomatosis. *Clin Exp Immunol* 93 (Suppl 1):38, 1993
147. PINCHING AJ, REES AJ, PUSSELL BA, LOCKWOOD CM, MITCHISON RS, PETERS DK: Relapses in Wegener's granulomatosis: The role of infection. *Br Med J* 281:836-838, 1980
148. PUSEY CD, REES AJ, EVANS DJ, PETERS DK, LOCKWOOD CM: Plasma exchange in focal necrotizing glomerulonephritis without anti-GBM antibodies. *Kidney Int* 40:757-763, 1991
149. BOLTON WK, STURGILL BC: Methylprednisolone therapy for acute crescentic rapidly progressive nephritis. *Am J Nephrol* 9:368-375, 1989
150. ROSSI F, JAYNE DRW, LOCKWOOD CM, KAZATCHKINE MD: Anti-idiotypes against anti-neutrophil cytoplasmic antigen autoantibodies in normal human polyspecific IgG for therapeutic use and in the remission sera of patients with systemic vasculitis. *Clin Exp Immunol* 83:298-303, 1991
151. JAYNE DRW, DAVIES MJ, FOX CJV, BLACK CM, LOCKWOOD CM: Treatment of systemic vasculitis with pooled intravenous immunoglobulin. *Lancet* 337:1137-1139, 1991
152. MATHIESON PW, COBBOLD SP, HALE G, CLARK MR, OLIVEIRA DBG, LOCKWOOD CM, WALDMANN H: Monoclonal-antibody therapy in systemic vasculitis. *N Engl J Med* 323:250-254, 1990
153. LOCKWOOD CM, THIRU S, ISAACS JD, HALE G, WALDMANN H: Long-term remission of intractable systemic vasculitis with monoclonal antibody therapy. *Lancet* 341:1620-1622, 1993