

University of Groningen

Incorporation of anterior iliac crest or calvarial bone grafts in reconstructed atrophied maxillae

Wortmann, Dagmar E; Klein-Nulend, Jenneke; van Ruijven, Leo J; Schortinghuis, Jurjen; Vissink, Arjan; Raghoobar, Gerry M

Published in:
Clinical Implant Dentistry and Related Research

DOI:
[10.1111/cid.13012](https://doi.org/10.1111/cid.13012)

IMPORTANT NOTE: You are advised to consult the publisher's version (publisher's PDF) if you wish to cite from it. Please check the document version below.

Document Version
Publisher's PDF, also known as Version of record

Publication date:
2021

[Link to publication in University of Groningen/UMCG research database](#)

Citation for published version (APA):

Wortmann, D. E., Klein-Nulend, J., van Ruijven, L. J., Schortinghuis, J., Vissink, A., & Raghoobar, G. M. (2021). Incorporation of anterior iliac crest or calvarial bone grafts in reconstructed atrophied maxillae: A randomized clinical trial with histomorphometric and micro-CT analyses. *Clinical Implant Dentistry and Related Research*, 23(3), 492-502. <https://doi.org/10.1111/cid.13012>

Copyright

Other than for strictly personal use, it is not permitted to download or to forward/distribute the text or part of it without the consent of the author(s) and/or copyright holder(s), unless the work is under an open content license (like Creative Commons).

The publication may also be distributed here under the terms of Article 25fa of the Dutch Copyright Act, indicated by the "Taverne" license. More information can be found on the University of Groningen website: <https://www.rug.nl/library/open-access/self-archiving-pure/taverne-amendment>.

Take-down policy

If you believe that this document breaches copyright please contact us providing details, and we will remove access to the work immediately and investigate your claim.

Downloaded from the University of Groningen/UMCG research database (Pure): <http://www.rug.nl/research/portal>. For technical reasons the number of authors shown on this cover page is limited to 10 maximum.

ORIGINAL ARTICLE

WILEY

Incorporation of anterior iliac crest or calvarial bone grafts in reconstructed atrophied maxillae: A randomized clinical trial with histomorphometric and micro-CT analyses

Dagmar E. Wortmann MD, PhD¹  | Jenneke Klein-Nulend PhD² |
 Leo J. van Ruijven PhD³ | Jurjen Schortinghuis DDS, MD, PhD^{1,4} |
 Arjan Vissink DDS, MD, PhD¹ | Gerry M. Raghoebar DDS, MD, PhD¹

¹Department of Oral and Maxillofacial Surgery, University of Groningen, University Medical Center Groningen, Groningen, The Netherlands

²Department of Oral Cell Biology, University of Amsterdam and Vrije Universiteit Amsterdam Academic Center for Dentistry Amsterdam, Amsterdam, The Netherlands

³Department of Functional Anatomy, University of Amsterdam and Vrije Universiteit Amsterdam Academic Center for Dentistry Amsterdam, Amsterdam, The Netherlands

⁴Department of Oral and Maxillofacial Surgery, Treant Scheper Ziekenhuis Emmen, Emmen, The Netherlands

Correspondence

Dagmar E. Wortmann, Department of Oral and Maxillofacial Surgery, University Medical Center Groningen, University of Groningen, PO Box 30.001, 9700 RB Groningen, The Netherlands.

Email: d.e.wortmann@umcg.nl

Abstract

Background: Autologous bone grafts have been applied successfully to severely atrophied maxilla via a preimplant procedure. Differences in graft incorporation at the microscopic level can be the decisive factor in the choice between anterior iliac crest and calvarial bone.

Purpose: To compare conversion of anterior iliac crest bone and calvarial bone 4 months after grafting of the edentulous maxilla.

Materials and methods: Twenty consecutive patients were randomly assigned to either anterior iliac crest (n = 10) or calvarial (n = 10) bone harvesting to reconstruct their atrophied maxillae. Biopsies were taken from both fresh bone grafts and reconstructed maxillae after 4 months healing, at time of implant placement. Micro-CT, histomorphometric and histological analyses were performed.

Results: Micro-CT analysis revealed that both the anterior iliac crest and calvarial bone grafts retained their volume and bone mass after being incorporated in the maxilla, but with a favor for calvarial bone grafts: calvarial bone grafts had a higher mineral density before and after incorporation. Both bone grafts types were well incorporated after 4 months of healing with preservation of bone volume and mineral density. Although the fresh bone biopsies were similar histomorphometrically, after 4 months of graft incorporation, the osteoid percentage and osteocyte count remained higher in the anterior iliac crest bone whereas the percentage of bone was higher in the calvarial bone grafts compared to the anterior iliac crest bone grafts.

Conclusions: Both donor sites, that is, anterior iliac crest and calvarial bone, are well suited to provide a reliable and stable basis for implant placement 4 months after grafting with mineral density, porosity, and resorption rate in favor of calvarial bone grafts.

KEYWORDS

alveolar ridge reconstruction, atrophic maxilla, autogenous bone graft, bone, bone density, bone grafting, calvaria, histological analysis, maxillary reconstruction, micro-CT

This is an open access article under the terms of the Creative Commons Attribution-NonCommercial-NoDerivs License, which permits use and distribution in any medium, provided the original work is properly cited, the use is non-commercial and no modifications or adaptations are made.

© 2021 The Authors. *Clinical Implant Dentistry and Related Research* Published by Wiley Periodicals LLC

1 | INTRODUCTION

Due to their unique osteogenic, osteoinductive and osteoconductive properties, autologous bone grafts are still the preferred grafting material for craniofacial reconstructions prior to placement of dental implants.^{1–3} Although several sites are used to harvest autologous bone, the properties of the grafts derived from these sites differ such as long-term structural integrity and tissue quality.

The donor sites can be classified according to their embryological origin, that is, endochondral or intramembranous. The iliac crest, tibia and ribs are endochondral in origin, while the maxilla, mandible and skull (calvaria) are intramembranous in origin.^{1,4} A major difference between the two embryological origins is that the resorption rate of intramembranous bone is less than that of endochondral bone.^{4,5} As a result, intramembranous bone is presumed to have better long-term results with regard to three-dimensional reconstructions of severely atrophied ridges of the maxilla or mandible.

Intra-oral sites are frequently used as graft donor sites for bony reconstructive procedures prior to implant placement, but the amount of bone that can be harvested from the chin, mandibular ramus and maxillary tuberosity is limited. The anterior iliac crest is traditionally the most frequently used donor site for harvesting autologous bone when large volumes are needed. The major drawbacks of iliac crest bone harvesting are post-operative pain and gait problems, as perceived by the patients.⁶ The calvarium is an alternative donor site when there is a demand of copious amounts of bone.^{1,5} Although calvarial bone grafting bears the hazard of inducing severe complications, technique improvements have made its harvesting to a safe and straightforward procedure.^{7–11}

The success of a bone graft is mostly assessed indirectly based on implant survival and macroscopic volumetric changes.¹² Unfortunately, qualitative and quantitative factors, such as relative volumetric changes, mineral density, and maturation of the graft, are not within the scope of these approaches, even though these parameters provide insight into the long-term outcomes of the reconstruction. Current advancements in imaging technology, however, have led to a significant improvement in the resolution of the skeletal structural architecture *in vivo* and *ex vivo*, thus enabling a more in-depth analysis of bony reconstructions. Utilizing a combination of micro-CT scanning and histomorphometric analysis facilitates the evaluation of the mineral and bioactive properties of bone.¹³ Therefore, the aim of this study was to compare the material properties and incorporation of anterior iliac crest and calvarial bone grafts when applied to reconstruct atrophied maxillae by means of micro-CT and histomorphometric analyses.

2 | MATERIALS AND METHODS

2.1 | Patient selection

Twenty consecutive eligible patients who were referred to the department of Oral and Maxillofacial Surgery of the University Medical Center Groningen (UMCG), the Netherlands, and who suffered from problems with wearing an upper denture due to severe resorption of

What is known:

- Autologous bone grafts are the gold standard for reconstructing severely resorbed maxillae prior to implant placement.
- Enchondral bones such as the anterior iliac crest and mesenchymal bones such as calvarial bone are frequently used for augmentation.
- Clinically, anterior iliac crest bone grafts seem to have a higher resorption rate than calvarial bone grafts.

What this study adds:

- Anterior iliac crest and calvarial bone are both well suited to provide a reliable basis for implant placement 4 months after augmentation.
- At a microscopical level, mineral density, porosity, and resorption rate are in favor of calvarial bone grafts.

the edentulous maxilla, were asked to join this study. Inclusion took place between November 2014 and March 2016. Inclusion criteria were an insufficient bone volume for reliable placement of dental implants as assessed on a cone beam computed tomography (CBCT) scan, that is, <3 mm bone height in the maxillary sinus area and <2 mm bone width in the anterior and posterior maxilla. The patients were randomly assigned to either the anterior iliac crest group ($n = 10$) or calvarial bone group ($n = 10$) using computer-generated random numbers. Also, in order to be able to harvest the calvarial bone, the patients' parietal bone in the skull had to be at least 5 mm thick in the area between the articular tubercle and the end of the mastoid bone on the CBCT scan. Exclusion criteria were patients with an American Society of Anaesthesiologists (ASA) score of III or higher,¹⁴ a history of radiotherapy in the head and neck region, former or current use of intravenous bisphosphonates, and previous surgery at one of the two donor sites (iliac crest or cranium).

The anticipated effect size of bone volume reduction in the calvarium group compared to the anterior iliac crest group was 1.6, which is in agreement with other studies.^{5,13,15–17} Using an *a-priori* sample size calculator for Students *t* test with the anticipated effect size (Cohens *d*) of 1.6 with a two-sided 5% significance level and a power of 80%, a sample size of eight patients per group was necessary. To compensate for error, it is reasonable to include 10 per group.

2.2 | Study approval

The study was approved by the Medical Ethical Committee (REF NL48614.042.14) of the University Medical Center Groningen, the Netherlands.

2.3 | Surgical procedure

A monocortical iliac crest bone graft was taken from the medial surface of the anterior ilium using a technique that was based on the procedure described by Kalk et al.⁶ The incision began 1 cm behind the anterior superior iliac spine and continued posteriorly, following the iliac crest. It was carried down sharply to the mid crest, dividing the musculotendinous aponeurosis of the tensor muscle of the fascia lata and the oblique abdominal muscles, without transecting any muscle fibers. The bony ilium was exposed directly by reflecting the iliac muscle subperiosteally, and the donor site was exposed with a retractor. The corticocancellous bone blocks were harvested by making two horizontal and five vertical cuts. The superior horizontal cut was made mid-crestal with a reciprocating saw. The inferior horizontal cut was made 4 cm inferior in the inner table with a curved osteotome. The horizontal cuts were connected by vertical cuts using a reciprocating saw. After removing the corticocancellous bone blocks, piece by piece from the inner table, additional cancellous bone was harvested with gouges and curettes. Care was taken not to perforate the lateral cortex.

The technique described by Schortinghuis et al.⁷ was used to harvest the calvarial bone grafts. In short, after raising a full-thickness flap from the parietal skull, the outer table graft was marked with a burr until the diploe was encountered. A bevel was created with a bone scraper around the calvarial outer table graft area to harvest cancellous bone and to facilitate piece-by-piece removal of the cortical bone grafts with a reciprocating saw. The defect in the skull was reconstructed with bone cement (Palacos, Zimmer Biomet, Warsaw, Indiana).

All the operations were performed at the UMCG by an experienced oral and maxillofacial surgeon (GMR). After harvesting the iliac crest or calvarial bone, maxillary sinus elevation surgery was performed with the cancellous bone on both sinuses. The cortical bone grafts were positioned on the exposed maxillary alveolar process as buccal onlay grafts. The cancellous portion of the graft was placed facing the recipient maxilla. A maxillary sinus augmentation and buccal plating was performed in all patients on both sides. If necessary, a double plating with both a buccal and a palatal graft was performed or bone particles were added to gain enough bone volume. In all patients, a minimum crest width of the alveolar process of 6 mm was strived for. The grafts were fixed with 1.3 mm osteosynthesis screws (Synthes, Wolhusen, Switzerland). The sharp bone edges were rounded to allow for smooth coverage of the grafted area with the overlying mucosa. Primary wound closure was accomplished with resorbable 4-0 polyglactine sutures (Ethicon, Somerville, New Jersey). After a 4-month healing period, dental implants (Straumann Standard SLA implants; Ø 4.1 mm, Institut Straumann AG, Basel, Switzerland) were placed in the reconstructed maxilla in a one-stage procedure. The wound was closed with resorbable 4-0 polyglactine sutures (Ethicon, Somerville, New Jersey).

2.4 | Bone biopsies

Bone biopsies were obtained from the donor bone area immediately after harvesting the fresh grafts as well as 4 months later from the

native and grafted bone in the reconstructed maxilla, whereby a small bone wedge of the reconstructed alveolar process was taken between two adjacent implants. The biopsies were preserved in 4% phosphate-buffered formaldehyde solution (Klinipath BV, Duiven, the Netherlands) for 24 h and then stored in 70% ethanol until used for micro-CT and histomorphometric analyses. The analysis were performed by DEW, JS, LvR, and MAD and they were blinded for the allocation sequence until all outcomes were assessed.

2.5 | Micro-computed tomography evaluation

All the biopsies were scanned with a high-resolution micro-CT (μ CT 40, Scanco Medical AG, Brüttisellen, Switzerland). This system was calibrated every 2 weeks using phantoms with densities of 0, 100, 200, 400, and 800 mg HA/cm³. Before scanning, the biopsies were fixed with synthetic foam in a polyetherimide tube (inner diameter, 28.5 mm; length, 75 mm). Then the tube was filled with 70% ethanol and covered with Parafilm M (SPI Supplies, West Chester, Pennsylvania) to prevent evaporation during scanning. The scanner settings were: voltage, 70 kV; intensity, 113 μ A; integration time, 1000 ms; isometric resolution, 0.015 mm. A cone-beam reconstruction algorithm was used to make 3D reconstructions. All the reconstructions were smoothed with a Gauss filter (0.8/1) and segmented with a visually determined threshold of 559.2 mg hydroxyapatite (HA)/cm³ (Figure 1). This threshold visualizes bone in the same way as it appears on histological sections. The biopsy and transition zone orientations were identified for each bone biopsy using per operatively obtained photographs and schematic drawings of the biopsies.

The volumes of interest (VOIs) evaluations were performed by manually tracing the contours of the entire freshly biopsied fragments of bone. Then, three VOIs were drawn for each of the biopsies taken from the grafted bone and native bone after 4 months: a VOI including the entire biopsy and VOIs including only grafted and only native bone. The tissue mineral density (TMD, mg HA/cm³), defined as the mean mineral density of the whole volume of interest, was calculated for each VOI. TMD can be used as a qualitative measure of the mineral density of compact bone. The bone mineral density (BMD, mg HA/cm³), defined as the mean mineral density of the segmented bone volume in the VOI, was also calculated.¹⁸ Finally, the bone volume fraction (BVF), which is a quantitative measure defined as the ratio of the segmented bone volume to the total volume of the VOI (%), was assessed. In other words, BVF represents the percentage of biopsy volume, or tissue volume, that is occupied by bone volume.

2.6 | Histology and histomorphometric analysis

After micro-CT scanning and dehydrating in ascending alcohol series, the bone biopsies were embedded without prior decalcification in low-temperature polymerizing methyl methacrylate (MMA, Merck Schuchardt OHG, Hohenbrunn, Germany). The biopsies 3D-orientations were assessed using the micro-CT reconstructions. Longitudinal 5 μ m thick sections were cut with a Jung K microtome




FIGURE 1 Micro-CT scans of fresh bone biopsies and bone biopsies obtained from edentulous maxillary alveolar processes 4 months after being reconstructed with an anterior iliac crest or calvarial bone graft. Only bone with a mineral density of >559.2 mg HA/cm³ is visible. (A) Fresh anterior iliac crest biopsy consisting of a thin, dense cortical layer and a major spongy part. The thin trabeculae are numerous and form a dense network. (B) Biopsy obtained after 4 months of anterior iliac crest bone graft healing. The right side consists of grafted bone. The compact cortex of the anterior iliac crest can be identified based on morphology and bone density. The native maxillary bone is more porous, contains more trabeculae, and the cortical wall is thinner compared to the bone in the grafted area. In this biopsy, the palatal cortical wall is hard to identify from this perspective. (C) A fresh calvarial bone biopsy consisting mainly of cortical bone. The diploic bone is the more porous part of the piece. (D) Biopsy after 4 months of healing seen from the mesial perspective. The left side consists of grafted bone. The compact cortex of the calvarium can be identified based on morphology and bone density. The native maxillary bone is more porous, contains more trabeculae, and the cortical wall is thinner compared to the bone in the grafted area. Magnification: A and C, $\times 40$; B and D, $\times 20$; Arrow heads: border between grafted and native bone; GB.Ct: cortical part of grafted iliac crest or calvarial bone

(Reichert Jung, Heidelberg, Germany). Midsagittal histological sections of each biopsy were stained with Goldner's trichrome to distinguish mineralized bone (green) and unmineralized osteoid tissue (red).¹⁹ Digital images of the $\times 100$ magnified sections were acquired.

First, a qualitative histological analysis was performed. The 2D-orientation, completeness, and outstanding features, such as signs of inflammation, were identified for each section. The orientation was determined from the notes and photographs taken during the surgery as well as the 3D-reconstructions made by the micro-CT-software. The cortical bone percentage was determined for the fresh biopsies. Regarding the biopsies taken after 4 months, the native maxillary bone and grafted bone were identified visually. The presence and 2D distribution of bone, osteoid, and osteocytes was measured per section (presence and location). Bone is defined here as mineralized bone matrix without any osteoid.²⁰ Osteoid is bone matrix that is not mineralized yet.²⁰[Dempster, 2013 #11] The presence of osteoid indicates new bone formation. Osteocytes are mature osteoblasts located with their cell bodies in lacunae and with their cellular processes running through the canaliculi. They are encased by a mineral matrix and

are normally supplied by vessels lying in the bone's canal system. Osteocytes are the mechanosensors of bone and, as such, they have an important regulatory function in bone resorption and bone formation. The presence of vital osteocytes in the grafted bone indicates that the canalicular system is viable and functional.²¹

The histomorphometry was performed by dividing the sections into three pre-defined zones, that is, (1) the cortical zone of the graft, which is the cortical outer side of the graft just underneath the periosteum; (2) the cancellous zone of the graft, which is the side of the graft towards the alveolar process; and (3) the transitional zone, which is the contact zone between the calvarial graft and the alveolar process onto which the graft is fixed. Three regions of interest (ROIs) were determined for each biopsy zone following a pre-defined pattern. The mean result of each zone was used to compare the biopsies.

Histomorphometrical measurements were manually performed for each ROI using a computer with an electronic stage table and a Leica DC 200 digital camera. The computer software used was Leica QWin (Leica Microsystems Image Solutions, Rijswijk, the Netherlands). The primary variables, in terms of the bone area, osteoid area, and osteocyte number were determined. The percentage of bone area, percentage of osteoid, and osteocyte number per mm² of tissue area were derived from these primary variables.²⁰⁻²²

2.7 | Statistical analysis

Data management and analysis were performed using SPSS 23.0 (IBM SPSS Statistics for Windows, Version 23.0. Armonk, NY: IBM Corp., New York). The data were tested for normal distribution with a Shapiro Wilk-test and checked visually using a histogram with a distribution curve. The data are presented as mean \pm SD, or in case of non-normal distribution, as median and interquartile range. A dependent Student's *t* test, or the non-parametric paired Wilcoxon-Signed Rank test, was used to determine differences in the micro-CT parameters (tissue mineral density, bone mineral density, and bone volume fraction) and the histomorphometric parameters (bone percentage, osteoid percentage, osteocyte number per volume of bone) between the fresh iliac crest and calvarial bone biopsies and between the grafted iliac crest and calvarial bone biopsies obtained after 4 months healing from the same patient. Also, the differences between the grafted and native bone within each biopsy obtained after 4 months of healing, were determined as were the differences between the fresh and 4 months grafts. An independent *t*-test, or in case of non-parametric data, a Mann-Whitney *U* test, was used to determine the differences between both groups. A significance level of .05 was chosen for all tests.

3 | RESULTS

3.1 | Study population characteristics

The 20 participating patients were either male (9) or female (11), with an equal distribution between the groups (Table 1). No patients were

TABLE 1 Characteristics of the calvarial and anterior iliac crest groups

	Anterior iliac crest bone		Calvarial bone		Students t test	
	n = 10		n = 10		t	P
Gender						
Female	6		5		-0.43	.673
Male	4		5			
	Mean	SD	Mean	SD		
Age at implant placement (years)	63.5	7.0	65.9	8.7	-0.67	.509
BMI (kg/m ²)	28.5	6.13	30.6	7.9	0.64	.532
Time between augmentation and placement of implants (years)	0.4	0.1	0.5	0.2	-1.63	.120
Number of implants placed	44		44			

Abbreviations: BMI, body mass index; SD, standard deviation of the mean.

lost to follow-up. There were no smokers. The mean body mass index was comparable in both groups.

3.2 | Clinical results

In all cases, the augmentation procedure resulted in sufficient bone volume for implant placement at the prosthodontically preferred sites. In each group, 44 implants were placed. One patient in each group lost an implant because of mobility during the osseointegration phase resulting in a 1-year implant survival rate of 97.8%.

3.3 | Biopsies

A total of 40 bone biopsies was obtained. Twenty biopsies came from the freshly harvested bone grafts (10 per group) and 20 were taken from the reconstructed maxillary alveolar wall of the grafted bone after 4 months of healing (10 per group).

3.4 | Micro-CT

The original orientation and the transition zone were identified on the 3D-reconstructions of the CT scans by the same investigator (DW). Figure 1 shows a 3D-reconstruction of fresh blocks from anterior iliac crest and calvarial bone grafts and of a specimen harvested during implant placement after a 4-month graft healing period.

The fresh anterior iliac crest biopsies contained a thin layer of very dense, compact cortical bone. This compact layer merged into the cancellous bone with a small transition zone. The numerous trabeculae of the cancellous bone were thin and round, extending in all directions. The original anatomy of the anterior iliac crest was reflected in the form of the grafts since the cortical layer was slightly concave. In the biopsies obtained after 4 months of anterior iliac crest bone graft healing, the transition from the grafted bone towards the native bone could be identified by the small impression in the cortical

layer of the biopsies. Furthermore, the cancellous bone was less dense at the junction. The grafted bone still appeared as a dense, thin cortical layer at the grafted site. The cancellous bone was less dense compared to the fresh anterior iliac crest bone and the orientation of the trabeculae appeared slightly disorganized.

The fresh calvarial bone grafts demonstrated a smooth transition from dense cortical bone towards more cancellous diploic bone. The trabecula of the diploic part were thick and short. In the biopsies obtained after 4 months, the grafted bone could be identified easily based on the compact cortical bone and the morphology of the graft, and since they looked as dense as the fresh biopsies. A more in-depth observation of the biopsies revealed that the transition towards cancellous bone started similar to the fresh biopsies, but the trabeculae had become longer and thinner towards the native maxillary bone. Both bone types' transition area demonstrated more space between the trabeculae, which were irregular in form and thickness indicating remodeling of the grafted bone. Further towards the native bone, the trabeculae remained long and thin but were more packed together. The cortical zone of the native bone was thinner compared to the calvarial bone.

All the biopsies underwent micro-CT analysis and the results are depicted in Table 2. When the fresh bone graft outcomes regarding tissue mineral density of the grafted bone (TMD), inorganic bone mass (BMD) and volume fraction occupied by bone (BVF) were compared with the outcomes in grafted bone obtained from the same participants after 4 months of bone graft healing, a slight decrease was seen for TMD and BVF and an increase for BMD in the anterior iliac crest group. However, these inter-group differences were not statistically significant (TMD: anterior iliac crest group: $Z = -1.572$, $P = .116$, calvarium group: $Z = -0.76$, $P = .445$; BMD: anterior iliac crest group: $Z = -1.07$, $P = .285$, calvarium group: $Z = -1.78$, $P = .074$; BVF: anterior iliac crest group: $Z = -.15$, $P = .878$, calvarium group: $Z = -0.15$, $P = .878$) (Wilcoxon-Signed Ranks test). Thus, both the anterior iliac crest and calvarial bone grafts keep their volume and bone mass after being incorporated in the maxilla.

A comparison of both groups' micro-CT parameter outcomes showed that fresh calvarial bone had a higher tissue density value

TABLE 2 Microcomputed tomography analysis of tissue mineral density (TMD), bone mineral density (BMD) and bone volume fraction (BVF) in biopsies taken from fresh anterior iliac crest and calvarial bone grafts and from reconstructed maxillary alveolar ridges with either of these bone grafts 4 months after reconstruction and prior to implant placement

	Fresh bone biopsies (n = 20)				Healed reconstructed alveolar process biopsies (n = 20)			
	Anterior iliac crest	Calvarium	Mann-Whitney U test		Anterior iliac crest	Calvarium	Mann-Whitney U test	
	Median (IQR)	Median (IQR)	U	P	Median (IQR)	Median (IQR)	U	P
TMD (mgHA/cm ³)	399.3 (341.2–814.4)	743.6 (500.1–889.6)	22.0	.329 ^a	365.2 (264.5–530.6)	509.9 (372.4–621.9)	14.5	.007
BMD (mgHA/cm ³)	860.8 (819.2–887.9)	1028.4 (987.7–1112.1)	11.0	.002 ^a	892.9 (832.8–943.0)	929.6 (877.7–956.9)	22.0	.035 ^b
BVF (%)	39.3 (13.7–61.6)	69.4 (69.4–79.1)	25.0	.049 ^a	38.7 (21.3–52.0)	47.5 (33.2–60.6)	7.0	.01 ^b

Abbreviation: IQR, interquartile range.

^aSignificant difference between freshly harvested calvarium and anterior iliac crest bone obtained at bone graft harvesting surgery, $P < .05$, Mann-Whitney U test.

^bSignificant difference between calvarium and anterior iliac crest bone grafts obtained after 4 months of healing, $P < .05$, Mann-Whitney U test.

(BMD, Mann-Whitney U test, $U = 11.00$, $P = .002$) and a higher fraction of the volume that is occupied by bone (BVF, Mann-Whitney U test, $U = 25.00$, $P = .049$) than the anterior iliac crest bone. After 4 months of graft healing, the tissue mineral density, the inorganic mass and the bone volume fraction had higher values in calvarial bone (TMD, Mann-Whitney U test, $U = 14.50$, $P = .007$; BMD, Mann-Whitney U test, $U = 22.00$, $P = .035$; BVF, Mann-Whitney U test, $U = 7.00$, $P = .001$). In other words, inorganic tissue density was higher in calvarial bone before and after graft incorporation.

The two groups' native maxillary bone TMD, BMD, and BVF outcomes did not differ (Mann-Whitney U test, TMD: $U = 35.00$, $P = .414$; BMD: $U = 35.50$, $P = .438$; BVF: $U = 32.00$, $P = .288$). Furthermore, irrespective of the type of graft, the native bone's TMD, BMD, and BVF values were lower compared to those measured in the grafted bone. It seems that since the TMD, BMD, and BVF had decreased after 4 months of graft incorporation, the grafted bone had adapted to the maxillary bone.

3.5 | Histology

The sections with fresh anterior iliac crest consisted of highly mineralized bony tissue, appearing dark green in the histological sections (Figure 2). The sections contained a dense cortical layer and an adjacent network of numerous thin trabeculae surrounding fatty tissue. The transition area from the compact cortex towards the spongy bone was irregular and abrupt. Osteoid, appearing as clear red lines adjacent to green, mineralized bone, was present throughout the sections, as were osteocytes, which were visible as dark dots within the white lacunae in the mineralized bone.

The fresh calvaria sections appeared dark green as well. The sections mostly contained mostly dense cortical bone, but several sections showed both cortical and diploic bone, with a smooth transition from one to the other bone type. The diploic bone consisted of short, thick trabeculae. Numerous osteocyte lacunae were visible

throughout the sections (Figure 2). In the sections obtained from biopsies taken after 4 months of healing, the original alveolar process, transition zone and grafted bone could still be identified from the bone morphology, irrespective of bone maturation. Several trabeculae were present at the transition zone between the grafted and native bone. These trabeculae connected the two bony parts, thus representing new bone formation. The trabeculae at the transition zone were thin and irregular, and appeared more like maxillary bone. Next to these trabeculae, soft, mostly fat tissue was seen between the graft and the native bone, and sometimes signs of inflammation were observed. Moreover, poorly mineralized bony tissue was observed, possibly the result of adding cancellous bone particles to fill the gaps between the grafted and native bone. Apart from mineralized bone tissue, osteoid was highly present in the transition zones (Figure 2B, F). Osteocytes were seen throughout the biopsies, but they were more concentrated in the transition zone and cancellous parts of the grafted bone than in the cortical part of the graft. In the biopsies taken at later time points, the osteocytes were more evenly distributed throughout the grafts indicating further maturation of the bone.

3.6 | Histomorphometry

Histomorphometry was used to measure the cortical part and the cancellous zone of the graft, and the transition zone between the graft and the alveolar process. It was possible to set the nine ROIs following the pre-defined pattern in 16 out of the 20 biopsies taken after 4 months. In two biopsies, one per group, only two ROIs per zone could be set. Another two biopsies, again one per group, could not be measured due to inadequate orientation of the sectioning.

There were no significant differences between the bone percentage, osteoid percentage, or osteocyte number over bone area of the fresh bone graft biopsies (Table 3). Then, the median bone percentage in the anterior iliac crest group sections decreased significantly from 51.5% (IQR 46.3–56.7%) in the fresh biopsies to 27.5% (IQR 25.1–

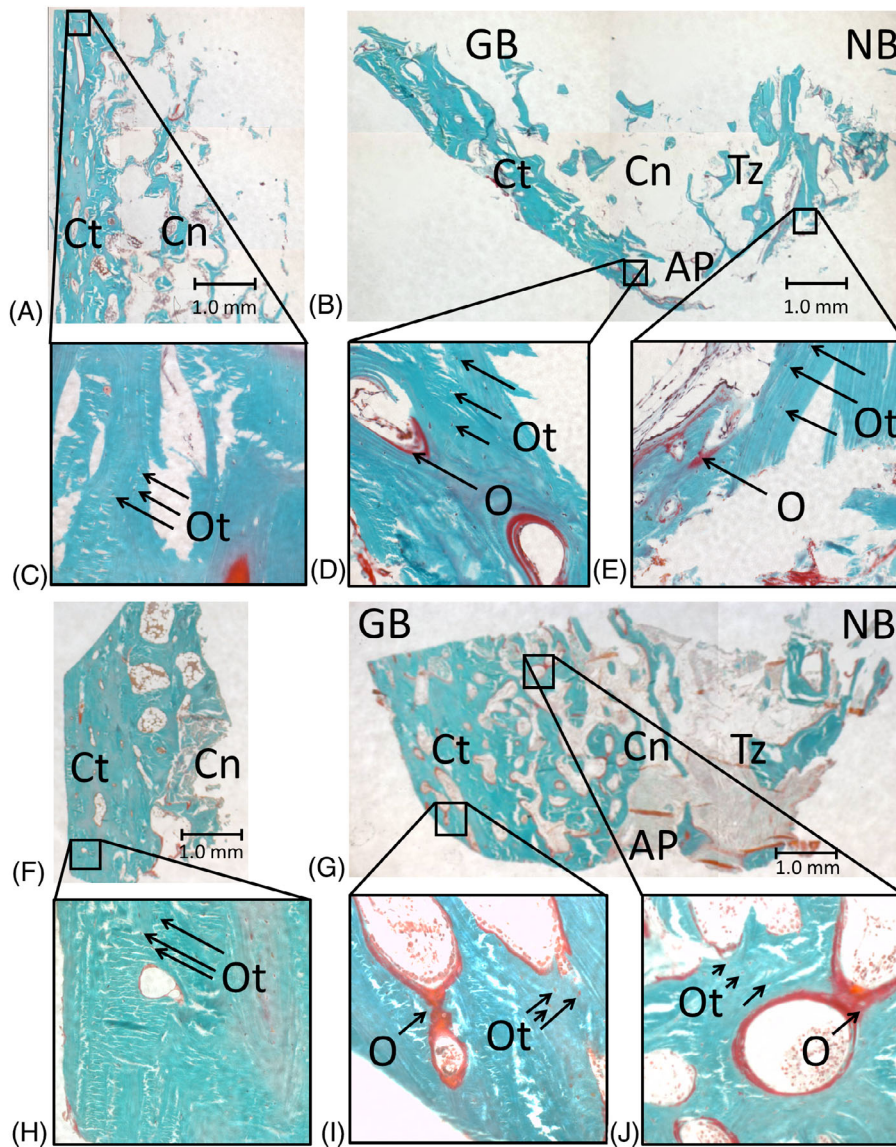


FIGURE 2 Histologic sections of biopsies obtained from edentulous patients whose maxilla were reconstructed with either anterior iliac crest or calvarial bone grafts: fresh anterior iliac crest and calvarial bone biopsies and biopsies from the maxillary alveolar ridge, 4 months post reconstruction surgery. (A) Fresh anterior iliac crest bone showing dense cortical bone (Ct) and several thick trabeculae (Tb) on the right where the copious amount of cancellous trabecular bone (Cn) starts. (B) Biopsy 4 months after grafting the native maxillary bone (NB; right) with anterior iliac crest bone (GB; left). The cortical part of the anterior iliac crest bone is denser compared to the native bone. Crossing trabeculae are scarce between the native and grafted bones and non-mineralized connective tissue is present. (C) Detail of (A), containing cortical bone with osteocytes (Ot). (D) Detail of (B), taken from the border between the grafted and native bones, including osteoid (O) and osteocytes (Ot). (E) Detail of (B), taken from the cortical part of the grafted bone, including osteoid (O) and osteocytes (Ot). (F) A fresh calvarial bone graft biopsy demonstrating a thick and dense cortical layer (Ct) with a smooth transition towards cancellous diploic bone months after grafting. The border between the grafted and native bone has disappeared, and there is more homogenous mineralized, hard bone tissue visible throughout the section compared to the section obtained after 4 months of graft healing. (G) Biopsy 4 months after grafting the native maxillary bone (NB; right) with anterior iliac crest bone (GB; left). The cortical part of the calvarial bone is denser compared to the native bone. Several crossing trabeculae are present between the native bone and grafted bone and non-mineralized connective tissue is present. (H), (I), and (J): Details of, respectively, (F) and (G). Staining: Goldner's trichrome to distinguish mineralized bone tissue (green) and unmineralized osteoid (red). All the bone biopsies are from one patient, showing the progression from fresh calvarial bone towards a healed, reconstructed alveolar process. Magnification: A and B $\times 20$, C and D $\times 100$. AP: alveolar process; Cn: cancellous zone of grafted bone; Ct: cortical zone of grafted bone; GB: grafted (anterior iliac crest or calvarial) bone; NB: native (maxillary) bone; O: osteoid; Ot: osteocyte; Tb: trabecula; Tz: transition zone between grafted and native bone

38.5%) in the biopsies taken 4 months later (Wilcoxon-Signed Rank test, $Z = -2.24$, $P = .025$). The median osteoid percentage increased significantly from 0.3% (IQR 0.1–0.6%) to 1.1% (IQR 0.6–1.5%)

(Wilcoxon-Signed Rank test, $Z = -2.38$, $P = .017$) and the median number of osteocytes over bone volume increased significantly from 114 (IQR 90–190) to 369 (IQR 284–402) (Wilcoxon-Signed Rank test,

TABLE 3 Histomorphometric analysis of bone percentage (Bp), osteoid percentage (Op), and osteocyte number per volume (OcN/Ba) in biopsies from fresh harvested bone grafts and from the grafted sites after 4 months in the patients undergoing reconstruction of the edentulous maxilla prior to implant placement

		<u>Anterior iliac crest bone</u>		<u>Calvarium</u>		<u>Mann-Whitney U test^a</u>	
		<u>Median (IQR)</u>		<u>Median (IQR)</u>		<u>U</u>	<u>P</u>
Fresh bone graft		N = 10		N = 10			
All regions combined	Bp (%)	51.5 (46.3–56.7)		51.2 (46.0–69.5)		37.0	.790
	Op (%)	0.3 (0.1–0.6)		0.44 (0.1–0.8)		34.0	.594
	OcN/Ba (1/mm ²)	114 (90–190)		215 (64–273)		30.0	.374
Cortical bone	Bp (%)	68.3 (58.3–79.7)		59.9 (37.4–79.7)		29.0	.328
	Op (%)	0.1 (0.2–0.5)		0.2 (0.3–1.0)		31.0	.423
	OcN/Ba (1/mm ²)	98 (107–117)		126 (57–201)		34.0	.594
Trabecular bone	Bp (%)	33.7 (24.0–55.8)		37.4 (28.6–59.6)		33.5	.563
	Op (%)	0.1 (0.0–0.6)		0.15 (0.35–1.0)		35.0	.651
	OcN/Ba (1/mm ²)	101.9 (80.4–164.3)		127 (57–201)		32.0	.477
Grafted bone after 4 months of healing		N = 8		N = 8			
All regions combined	Bp (%)	27.5 (25.1–38.5)		49.7 (42.1–57.7)		5.0	.005 ^b
	Op (%)	1.1 (0.6–1.5)		1.3 (0.5–1.9)		27.0	.600
	OcN/Ba (1/mm ²)	369 (284–402)		278 (239–370)		22.0	.293
Cortical bone of graft	Bp (%)	45.6 (22.6–54.3)		51.9 (49.2–59.2)		16.0	.093
	Op (%)	1.0 (0.5–1.7)		1.7 (0.4–2.3)		30.0	.834
	OcN/Ba (1/mm ²)	399 (223–437)		302 (231–438)		27.0	.599
Cancellous bone of graft	Bp (%)	34.8 (15.8–45.7)		50.2 (28.8–61.7)		15.0	.074
	Op (%)	0.5 (0.1–1.7)		1.7 (0.4–2.3)		26.0	.528
	OcN/Ba (1/mm ²)	318 (116–427)		234 (195–405)		34.0	.847
Transition zone	Bp (%)	36.5 (25.2–38.0)		45.5 (40.2–50.5)		4.0	.003 ^b
	Op (%)	1.0% (0.8–1.3%)		0.6% (0.4–2.4%)		26.0	.528
	OcN/Ba (1/mm ²)	284 (93–410)		258 (90–190)		14.0	.065

Abbreviation: IQR, interquartile range.

^aEquality of the median between the anterior iliac crest and calvarial bone grafts after 4 months of healing using a Mann-Whitney U test.

^bSignificant difference between Bp, Op, or OcN/Ba measured in the cortical bone, cancellous bone, or transition zone between of grafted bone and native maxillary bone, in sections obtained from participants' from the anterior iliac crest group and calvarial bone graft group.

$Z = -2.24$, $P = .025$.) In the calvarium group, the median bone percentage decreased from 51.2% (IQR 46.0–69.5%) in fresh biopsies to 49.7% (IQR 42.1–57.7%) in biopsies taken at 4 months (Wilcoxon-Signed Rank test, $Z = -1.15$, $P = .249$), the median osteoid percentage increased from 0.44% (IQR 0.1–0.84%) to 1.3% (IQR 0.5–1.9%) (Wilcoxon-Signed Rank test, $Z = 1.57$, $P = .116$ and the number of osteocytes over bone volume also increased somewhat, from 215 (IQR 64–273) to 278 (IQR 239–370) (Wilcoxon-Signed Rank test, $Z = -1.78$, $P = .075$).

There were no significant differences between the bone percentage, osteoid percentage or osteocyte number over bone area in the fresh bone graft biopsies. On comparing the two groups' sections obtained 4 months post reconstruction, the bone percentage in the transition zones was significantly higher in the calvarium bone graft group (median (IQR) bone percentages in the transition zone: 45.5 (IQR 40.2–50.5)% for the calvarium group and 25.2 (IQR 25.2–38.0)% for the anterior iliac crest group; Mann-Whitney U test: $U = 4.50$,

$P = .004$). There were no significant differences between the other histomorphometry outcomes, but what stood out was that the osteocyte number over bone volume was clearly higher in all the anterior iliac crest group's section zones (median OcN/Ba in entire sections: 302 (IQR 231–428) per mm² for the calvarium group and 399 (223–437) per mm² for the anterior iliac crest group; Mann-Whitney U test, $U = 22.00$, $P = .293$; Table 3).

Thus, all the fresh bone biopsies' histomorphometric outcome values were similar. During the 4-month healing period, the median bone percentage decreased, whereas the median osteoid percentage and number of osteocytes increased in both groups and the changes were of statistical significance in the anterior iliac crest group (bone percentage, anterior iliac crest group: $Z = 2.24$, $P = .025$ and calvarium group: $Z = -1.15$, $P = .25$; osteoid percentage, anterior iliac crest group: $Z = -2.38$, $P = .116$; number of osteocytes per bone area: anterior iliac crest group: $Z = 2.24$, $P = .025$; $Z = -0.73$, $P = .463$). After 4 months of graft incorporation, the amount of bone per graft

volume was higher, and the number of osteocytes per volume of bone was lower, in the calvarial bone graft compared to the anterior iliac crest bone graft group (Table 3).

4 | DISCUSSION

This study revealed that the histomorphological and radiographic characteristics make both graft types very suitable for pre-implant graft procedures, showing that (i) both bone graft types become well incorporated after 4 months of healing. The bone volume and mineral density are well preserved, the grafted bone is well connected to the native bone and the grafts are vital and showed signs of new bone formation; (ii) calvarial bone grafts are less porous, have a higher volume of mineralized tissue, and showed less resorption over time compared to anterior iliac crest bone grafts; (iii) anterior iliac crest bone grafts show a higher percentage of an osteoid and higher number of osteocytes per bone volume compared to calvarial bone grafts.

The major differences between both donor sites lie in the mineral density, bone percentage, osteoid percentage and osteocyte number of the grafts. The calvarial grafts show a higher mineral density measured with micro-CT and a higher percentage of bone per tissue surface as shown by histomorphometry, which corresponds with the thick cortical layer and overall dense structure calvarial bone is known for. Anterior iliac crest bone contained more osteoid and a higher number of osteocytes after 4 months healing. This reflects a high metabolic activity in anterior iliac crest bone grafts. These outcomes suggest that the number of osteocytes per volume in anterior iliac crest does not add to bone mass preservation when compared to calvarial bone, since the calvarial bone grafts showed less decrease in bone percentage without an increase in osteoid or osteocyte number. It is therefore hypothesized that on the long term, calvarial bone grafts show less resorption compared to anterior iliac crest grafts.

This hypothesis is supported by previous clinical studies which have shown more bone resorption in anterior iliac crest bone grafts compared to calvarial bone grafts.^{5,23} The three-dimensional volume reduction after reconstructions with iliac crest bone ranges from 24%²⁴ after 6 months to 60%¹² after 1 year. When calvarial bone grafts are used, the resorption is reported to be 0–15%,¹² viz., 8.44% after 6 months,²⁴ and 10%²⁵ to 19.2%² after 1 year. These observations are in line with differences we found between both graft types at baseline and 4 months after grafting in terms of mineral density, bone percentage and metabolic activity. Higher volume preservation of the alveolar bone after augmentation using calvarial grafts compared to using anterior iliac crest grafts should be taken into account in clinical decision making, as it might benefit the prosthetic outcomes of the procedure.

The higher number of osteocytes in combination with lower bone mass and mineral density in anterior iliac crest bone compared to calvarial bone matches with previously described differences in flat bone and long bone osteocyte networks that arise from adapting to different physiological loading patterns, which suggest different networks activities.²⁶ In other words, the bone percentage of bone after

4 months of graft incorporation might result from the specific features of the osteocytes instead of the number of these cells per volume of bone. Osteocytes are mechanosensitive cells that play a key role in bone remodeling, facilitating an increase or decrease in bone resorption and formation depending on the prevailing loading conditions.^{27,28} Previous studies have suggested that differences in the fate of the endochondral and intramembranous bone grafts are caused by differences in osteocyte function whereby the to specific mechanosensitive features of the local osteocytes in the parietal skull bone means it has efficient physiological load bearing and volume maintenance properties despite its relative mechanical disuse.^{27,28} Possibly, calvarial osteocytes have the ability to successfully orchestrate bone apposition and resorption even after transplantation,^{27,28} resulting in proper incorporation of a viable graft in combination with the preservation of its material properties. This theory seems to fit the findings in our study since the morphology of the grafted calvarial bone had only changed slightly during the healing period. In other words, the previously described higher metabolic activity of anterior iliac crest compared to calvarial bone,^{5,12,23} is likely to result from differences in osteocyte functioning rather than osteocyte number. This theory explains the previously described clinical findings supporting the hypothesized long term volume preservation seen in calvarial bone grafts. Furthermore, as osteocytes seem to play a key role in the fate of reconstructed alveolar ridges, future research on these procedures should focus on the optimal use of osteocytes.

The current micro-CT analyses demonstrated that both types of bone graft adapt to the native maxillary bone, as their features in terms of mineral density and porosity changed towards values measured in native bone. However, both graft types continued to show favorable features in terms of strength when compared to native maxillary bone. Previous research suggests that after a longer healing period, calvarial bone grafts still show favorable features that are at least as favorable as native bone when it comes to bone density, bone mass and bone volume.²⁹ Long-term studies on a larger scale are needed to further analyze the functioning of bone grafts compared to native maxillary bone, in terms of bone volume and bone strength as this has consequences for the placement of implants for prosthodontic rehabilitation.

In the quest to an ideal bone graft, the current study is of great value due to its randomized controlled design. This design allows for thorough comparison of both bone grafts despite their differences in anatomical location and subsequent burdens the bone was exposed to before harvesting. Both groups were equal in age distribution, male/female ratio and presence of known comorbidities.

The current study analyzed effects after 4 months of healing in terms of bone mineral density and microscopic bone volume. In clinical decision making, long term evaluations on macroscopic alveolar crest volume, implant survival and prosthetic outcomes should be included. Medium term studies on bone volume resorption report that, in line with the current results, anterior iliac crest shows a higher resorption rate than calvarial bone.^{5,12,17,25,30–33} However, it the outcomes might converse to some extent with time as anterior iliac crest has a steep initial resorption curve which flattens after several months

whereas calvarial bone shows a more gradual resorption pattern.¹⁷ To answer questions on differences in clinical outcomes, an analysis on macroscopic bone volume, for example by means of CBCT imaging, is needed.

In conclusion, the results of this study show that both donor sites, that is, anterior iliac crest and calvarial bone, are both well suited to provide a reliable and stable basis for implant placement 4 months after grafting with mineral density, porosity, and resorption rate being in favor of calvarial bone grafts. Future studies with a longer follow-up period are needed to test the hypothesis that calvarial bone grafts will show less resorption on the long term, therefore providing a more favorable and more durable outcome from a prosthodontic point of view.

CONFLICT OF INTEREST

The authors declare no conflict of interest.

AUTHOR CONTRIBUTIONS

Concept/design: Dagmar E. Wortmann, Jenneke Klein-Nulend, Leo J. van Ruijven, Jurjen Schortinghuis, Arjan Vissink, Gerry M. Raghoobar; Data analysis/interpretation: Dagmar E. Wortmann, Jenneke Klein-Nulend, Leo J. van Ruijven, Arjan Vissink, Gerry M. Raghoobar; Drafting of article: Dagmar E. Wortmann, Jenneke Klein-Nulend, Leo J. van Ruijven, Arjan Vissink, Gerry M. Raghoobar; Critical revision of article: Dagmar E. Wortmann, Jenneke Klein-Nulend, Leo J. van Ruijven, Jurjen Schortinghuis, Arjan Vissink, Gerry M. Raghoobar; Approval of Article: Dagmar E. Wortmann, Jenneke Klein-Nulend, Leo J. van Ruijven, Jurjen Schortinghuis, Arjan Vissink, Gerry M. Raghoobar; Statistics: Dagmar E. Wortmann; Funding secured by: Jurjen Schortinghuis, Gerry M. Raghoobar; Data collection: Dagmar E. Wortmann, Leo J. van Ruijven; Accountable for all aspects of the work including investigating and resolving appropriately any questions related to accuracy or integrity: Dagmar E. Wortmann, Jenneke Klein-Nulend, Leo J. van Ruijven, Jurjen Schortinghuis, Arjan Vissink, Gerry M. Raghoobar. Ing. Marion van Duin's assistance with the processing and histomorphometrical analysis was greatly appreciated.

DATA AVAILABILITY STATEMENT

Data available on request from the authors

ORCID

Dagmar E. Wortmann  <https://orcid.org/0000-0002-9625-7614>

REFERENCES

- Zouhary KJ. Bone graft harvesting from distant sites: concepts and techniques. *Oral Maxillofac Surg Clin North Am.* 2010;22(3):301-316. <https://doi.org/10.1016/j.coms.2010.04.007>.
- Sakkas A, Wilde F, Heufelder M, Winter K, Schramm A. Autogenous bone grafts in oral implantology-is it still a "gold standard"? A consecutive review of 279 patients with 456 clinical procedures. *Int J Implant Dent.* 2017;3(1):23. <https://doi.org/10.1186/s40729-017-0084-4>.
- Nkenke E, Weisbach V, Winckler E, et al. Morbidity of harvesting of bone grafts from the iliac crest for preprosthetic augmentation procedures: a prospective study. *Int J Oral Maxillofac Surg.* 2004;33(2):157-163. <https://doi.org/10.1054/ijom.2003.0465>.
- Zins JE, Whitaker LA. Membranous versus endochondral bone: implications for craniofacial reconstruction. *Plast Reconstr Surg.* 1983;72(6):778-785. <https://doi.org/10.1097/00006534-198312000-00005>.
- Mertens C, Decker C, Seeberger R, Hoffmann J, Sander A, Freier K. Early bone resorption after vertical bone augmentation: a comparison of calvarial and iliac grafts. *Clin Oral Implants Res.* 2013;24(7):820-825. <https://doi.org/10.1111/j.1600-0501.2012.02463.x>.
- Kalk WW, Raghoobar GM, Jansma J, Boering G. Morbidity from iliac crest bone harvesting. *J Oral Maxillofac Surg.* 1996;54(12):1424-1429. [https://doi.org/10.1016/s0278-2391\(96\)90257-8](https://doi.org/10.1016/s0278-2391(96)90257-8).
- Schortinghuis J, Putters TF, Raghoobar GM. Safe harvesting of outer table parietal bone grafts using an oscillating saw and a bone scraper: a refinement of technique for harvesting cortical and "cancellous"-like calvarial bone. *J Oral Maxillofac Surg.* 2012;70(4):963-965. <https://doi.org/10.1016/j.joms.2011.02.077>.
- Kuik K, Putters TF, Schortinghuis J, van Minnen B, Vissink A, Raghoobar GM. Donor site morbidity of anterior iliac crest and calvarium bone grafts: a comparative case-control study. *J Craniomaxillofac Surg.* 2016;44(4):364-368. <https://doi.org/10.1016/j.jcms.2015.12.019>.
- Putters TF, Raghoobar GM, Klein-Nulend J, Vissink A, Schortinghuis J. Immediate dental implant placement in calvarial bone grafts to rehabilitate the severely resorbed edentulous maxilla: a prospective pilot study. *J Craniomaxillofac Surg.* 2019;47(1):23-28. <https://doi.org/10.1016/j.jcms.2018.11.007>.
- Putters TF, Schortinghuis J, Vissink A, Raghoobar GM. A prospective study on the morbidity resulting from calvarial bone harvesting for intraoral reconstruction. *Int J Oral Maxillofac Surg.* 2015;44(4):513-517. <https://doi.org/10.1016/j.ijom.2014.12.007>.
- Putters TF, Wortmann DE, Schortinghuis J, et al. Morbidity of anterior iliac crest and calvarial bone donor graft sites: a 1-year randomized controlled trial. *Int J Oral Maxillofac Surg.* 2018;47(11):1474-1480. <https://doi.org/10.1016/j.ijom.2018.06.002>.
- Chiapasco M, Zaniboni M, Boisco M. Augmentation procedures for the rehabilitation of deficient edentulous ridges with oral implants. *Clin Oral Implants Res.* 2006;17(Suppl 2):136-159. <https://doi.org/10.1111/j.1600-0501.2006.01357.x>.
- Kamal M, Gremse F, Rosenhain S, et al. Comparison of bone grafts from various donor sites in human bone specimens. *J Craniofac Surg.* 2018;29(6):1661-1665. <https://doi.org/10.1097/SCS.00000000000004586>.
- Smeets EC, de Jong KJ, Abraham-Inpijn L. Detecting the medically compromised patient in dentistry by means of the medical risk-related history. A survey of 29,424 dental patients in The Netherlands. *Prev Med.* 1998;27(4):530-535. <https://doi.org/10.1006/pmed.1998.0285>.
- Crespi R, Vinci R, Capparè P, Gherlone E, Romanos GE. Calvarial versus iliac crest for autologous bone graft material for a sinus lift procedure: a histomorphometric study. *Int J Oral Maxillofac Implants.* 2007;22(4):527-532.
- Monje A, Monje F, Chan HL, et al. Comparison of microstructures between block grafts from the mandibular ramus and calvarium for horizontal bone augmentation of the maxilla: a case series study. *Int J Periodontics Restorative Dent.* 2013;33(6):e153-e161.
- Carinci F, Farina A, Zanetti U, et al. Alveolar ridge augmentation: a comparative longitudinal study between calvaria and iliac crest bone grafts. *J Oral Implantol.* 2005;31(1):39-45.
- Bouxein ML, Boyd SK, Christiansen BA, Guldborg RE, Jepsen KJ, Muller R. Guidelines for assessment of bone microstructure in rodents using micro-computed tomography. *J Bone Miner Res.* 2010;25(7):1468-1486. <https://doi.org/10.1002/jbmr.141>.
- Plenk H. Bone tissue and teeth. In: Böck P, ed. *Romeis Microscopic Technique.* 17. Munich, Germany: Urban & Schwarzenberg; 1989.

20. Dempster DW, Compston JE, Drezner MK, et al. Standardized nomenclature, symbols, and units for bone histomorphometry: a 2012 update of the report of the ASBMR Histomorphometry Nomenclature Committee. *J Bone Miner Res.* 2013;28(1):2-17. <https://doi.org/10.1002/jbmr.1805>.
21. Burchardt H. The biology of bone graft repair. *Clin Orthop Relat Res.* 1983;174:28-42.
22. Parfitt AM, Drezner MK, Glorieux FH, et al. Bone histomorphometry: standardization of nomenclature, symbols, and units. Report of the ASBMR Histomorphometry Nomenclature Committee. *J Bone Miner Res.* 1987;2(6):595-610.
23. Sbordone C, Toti P, Guidetti F, Califano L, Santoro A, Sbordone L. Volume changes of iliac crest autogenous bone grafts after vertical and horizontal alveolar ridge augmentation of atrophic maxillas and mandibles: a 6-year computerized tomographic follow-up. *J Oral Maxillofac Surg.* 2012;70(11):2559-2565.
24. Mertens C, Steveling HG, Seeberger R, Hoffmann J, Freier K. Reconstruction of severely atrophied alveolar ridges with calvarial onlay bone grafts and dental implants. *Clin Implant Dent Relat Res.* 2013;15(5):673-683. <https://doi.org/10.1111/j.1708-8208.2011.00390.x>.
25. Lenzen C, Meiss A, Bull HG. Augmentation of the extremely atrophied maxilla and mandible by autologous calvarial bone transplantation. *Mund Kiefer Gesichtschir.* 1999;3(Suppl 1):S40-S42.
26. Himeno-Ando AIY, Yamaguchi A, Imura T. Structural differences in the osteocyte network between the calvaria and long bone revealed by three-dimensional fluorescence morphometry, possibly reflecting distinct mechano-adaptations and sensitivities. *Biochem Biophys Res Commun.* 2012;417(2):765-770. <https://doi.org/10.1016/j.bbrc.2011.12.031>.
27. Vatsa A, Breuls RG, Semeins CM, Salmon PL, Smit TH, Klein-Nulend J. Osteocyte morphology in fibula and calvaria: is there a role for mechanosensing? *Bone.* 2008;43(3):452-458. <https://doi.org/10.1016/j.bone.2008.01.030>.
28. Santos A, Bakker AD, Klein-Nulend J. The role of osteocytes in bone mechanotransduction. *Osteoporos Int.* 2009;20(6):1027-1031. <https://doi.org/10.1007/s00198-009-0858-5>.
29. Wortmann DE, Klein-Nulend J, van Ruijven LJ, Vissink A, Raghoobar GM. Histomorphometric and micro-CT analyses of calvarial bone grafts used to reconstruct the extremely atrophied maxilla. *Clin Implant Dent Relat Res.* 2020;22(5):593-601. <https://doi.org/10.1111/cid.12936>.
30. Smolka W, Eggensperger N, Carollo V, Ozdoba C, Iizuka T. Changes in the volume and density of calvarial split bone grafts after alveolar ridge augmentation. *Clin Oral Implants Res.* 2006;17(2):149-155. <https://doi.org/10.1111/j.1600-0501.2005.01182.x>.
31. Mertens C, Freier K, Engel M, Krisam J, Hoffmann J, Freudlsperger C. Reconstruction of the severely atrophic edentulous maxillae with calvarial bone grafts. *Clin Oral Implants Res.* 2017;28(6):749-756. <https://doi.org/10.1111/clr.12873>.
32. Cansiz E, Haq J, Manisali M, Cakarer S, Alper GB. Long-term evaluation of three-dimensional volumetric changes of augmented severely atrophic maxilla by anterior iliac crest bone grafting. *J Stomatol Oral Maxillofac Surg.* 2020;121(6):665-671. <https://doi.org/10.1016/j.jormas.2019.11.004>.
33. Chiapasco M, Tommasato G, Palombo D, Scarnò D, Zaniboni M, del Fabbro M. Dental implants placed in severely atrophic jaws reconstructed with autogenous calvarium, bovine bone mineral, and collagen membranes: a 3- to 19-year retrospective follow-up study. *Clin Oral Implants Res.* 2018;29(7):725-740. <https://doi.org/10.1111/clr.13281>.

How to cite this article: Wortmann DE, Klein-Nulend J, van Ruijven LJ, Schortinghuis J, Vissink A, Raghoobar GM. Incorporation of anterior iliac crest or calvarial bone grafts in reconstructed atrophied maxillae: A randomized clinical trial with histomorphometric and micro-CT analyses. *Clin Implant Dent Relat Res.* 2021;1-11. <https://doi.org/10.1111/cid.13012>