

## Journal of the Hellenic Veterinary Medical Society

Vol 71, No 2 (2020)



### Occurrence of black spot disease induced by *Posthodiplostomum cuticola* (Nordmann, 1832) (Digenea: Diplostomatidae) in endemic and native fish of Turkey: seven new host records

D. INNAL, F. ÖZDEMİR, M.M. STAVRESCU-BEDIVAN, O. OZMEN, M.O. ÖZTURK

doi: [10.12681/jhvms.23636](https://doi.org/10.12681/jhvms.23636)

Copyright © 2020, D. INNAL, F. ÖZDEMİR, M.M. STAVRESCU-BEDIVAN, O. OZMEN, M.O. ÖZTURK



This work is licensed under a [Creative Commons Attribution-NonCommercial 4.0](https://creativecommons.org/licenses/by-nc/4.0/).

### To cite this article:

INNAL, D., ÖZDEMİR, F., STAVRESCU-BEDIVAN, M., OZMEN, O., & ÖZTURK, M. (2020). Occurrence of black spot disease induced by *Posthodiplostomum cuticola* (Nordmann, 1832) (Digenea: Diplostomatidae) in endemic and native fish of Turkey: seven new host records. *Journal of the Hellenic Veterinary Medical Society*, 71(2), 2120–2126. <https://doi.org/10.12681/jhvms.23636>

## Occurrence of black spot disease induced by *Posthodiplostomum cuticola* (Nordmann, 1832) (Digenea: Diplostomatidae) in endemic and native fish of Turkey: seven new host records

D. Innal<sup>1</sup>, F. Özdemir<sup>2</sup>, M. M. Stavrescu-Bedivan<sup>3</sup>, O. Ozmen<sup>4</sup>, M. O. Öztürk<sup>5</sup>

<sup>1</sup>Mehmet Akif Ersoy University, Department of Biology, Burdur, Turkey

<sup>2</sup>Hacettepe University, Department of Biology, Ankara, Turkey

<sup>3</sup>University of Agronomic Sciences and Veterinary Medicine of Bucharest, Faculty of Agriculture, Romania

<sup>4</sup>Mehmet Akif Ersoy University, Faculty of Veterinary Medicine, Department of Pathology, Burdur, Turkey

<sup>5</sup>Afyon Kocatepe University, Department of Molecular Biology and Genetics, Afyon, Turkey

**ABSTRACT:** This study was conducted to determine parasite infection with *Posthodiplostomum cuticola* in eight fish species collected from five Rivers Basins of Turkey (Aras, Çoruh, Sakarya, Marmara and Susurluk River Basins). Five of eight fish species are endemic to Turkey. The highest values of prevalence and mean intensity (60.87%; 4.86) of cysts with metacercaria of *P. cuticola* were recorded in *Alburnus filippii*, a native fish species in Ağıl Creek. At the gross examination numerous black lesions were observed at the skin of the fishes. Microscopically black-spot disease was revealed by melanin pigmentation and atrophy of fish muscles in lesioned areas. Parasites were covered by thin connective tissue capsule. *Alburnus escherichii*, *Alburnus filippii*, *Capoeta tinca*, *Chondrostoma angorense*, *Chondrostoma colchicum*, *Squalius pursakensis* and *Squalius turcicus* were found as new host records for *P. cuticola*.

**Keywords:** black-spot disease, cyprinid, histopathology, *Posthodiplostomum cuticola*, Turkey

*Corresponding Author:*  
D. Innal, Mehmet Akif Ersoy University, Department of Biology, Burdur, Turkey  
E-mail address: innald@yahoo.com

*Date of initial submission:* 29-04-2019  
*Date of revised submission:* 13-03-2020  
*Date of acceptance:* 15-03-2020

## INTRODUCTION

*Posthodiplostomum cuticola* (Nordmann, 1832) is a digenean parasitic fluke, responsible for black-spot disease, a pathological condition manifested by an intensive pigmentation of the cyst wall located in the skin, muscle tissue and fins of freshwater fish hosts throughout the world (Ondračková et al., 2004; Zrnčić et al., 2009; Kvach et al., 2017).

In the complex life-cycle of *P. cuticola* involving piscivorous birds as definitive hosts and planorbid snails as first intermediate host, various fishes belonging mainly to Cyprinidae and Cobitidae families play the role of the second intermediate host (Ondračková et al., 2004; Markovic and Krsmanovic, 2008; Zrnčić et al., 2009). Members of Escoidae, Percidae and Salmonidae could also represent hosts for *P. cuticola* (Mierzejewska et al., 2004).

Fish reaction to the parasite presence consists in dark pigment produced by decomposition of hemoglobin and chromatophores disposed around metacercaria, the penultimate development stage of *P. cuticola* (Markovic and Krsmanovic, 2008; Markovic et al., 2012). Although the black-spot disease is not deadly to fish hosts in general, symptoms such as body deformation, muscle fibers necrosis, kidney and liver dystrophy may occur and could be harmful to fry (Rolbiecki, 2004; Markovic and Krsmanovic, 2008; Iqbal et al., 2014).

To date, occurrence of *P. cuticola* infection was reported only in six cyprinid species from ichthyofauna of Turkey: *Alburnus chalcoides*, *Blicca bjoerkna*, *Cobitis cf. turcica*, *Cyprinus carpio*, *Scardinius erythrophthalmus* and *Vimba vimba* (Öztürk, 2005; Kırankaya and Ekmekçi, 2011; Öktener, 2014; Altan and Soylu, 2018). Therefore, the aim of this paper was to assess new host-parasite relationships in native and endemic fish species from Turkish inland waters in which the causal agent of black-spot disease is spread.

## MATERIALS AND METHODS

Overall, 153 individuals from eight fish species belong to 2 families (Cyprinidae and Cobitidae) and 5 genera were analysed: *Alburnus escherichii* Steindachner, 1897 (Caucasian bleak); *Alburnus filippii* Kessler, 1877 (Kura bleak); *Capoeta tinca* Heckel, 1843 (Anatolian khramulya); *Chondrostoma angorense* Elvira, 1987 (Ankara nase); *Chondrostoma colchicum* Derjugin, 1899 (Colchic nase); *Cobitis taenia* Linnaeus 1758 (Spined loach); *Squalius pursakensis* Hankó, 1925 (Sakarya chub) and *Squalius turcicus* De Filippi, 1865 (Transcaucasian chub). The study was carried out during 2010-2018 years. Fishes were collected from seven different locations (Seydisuyu Creek, Pasinler Creek, Süvari Creek, Düzköy Creek, Çerpeş Creek, Karaçaltı Creek, Ağıl Creek) (Figure 1) capturing five different river basins of Turkey: Aras, Çoruh, Sakarya, Marmara and Susurluk.

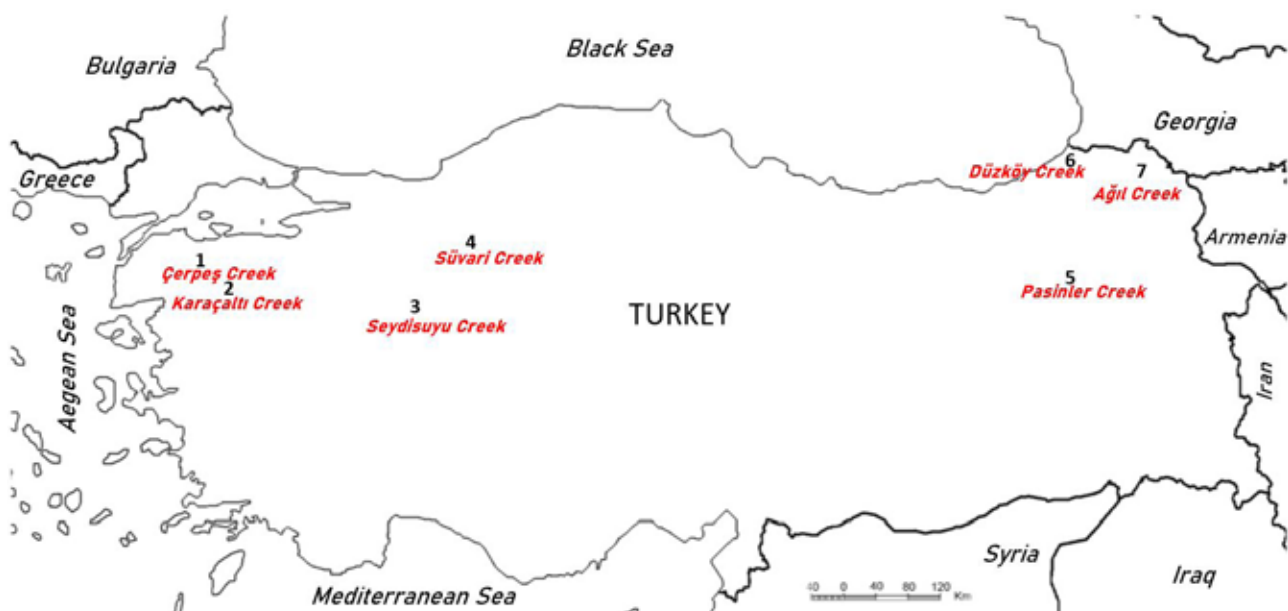

Figure 1. Map of sampling localities

For parasitic isolation, the skin and fins of the host fish specimens were taken into Petri dishes with physiological water. The parasites were separated by a scalpel. Subsequently, the parasites were fixed in 70% ethyl alcohol medium between the lamella for 24 hours. The parasite samples were then stained with hematoxylin (Pritchard & Kruse, 1982) and species identified, according to Bykhovskaya et al (1962).

During the necropsy, clinically lesioned and abnormal pigmented samples of analyzed fish species were collected and fixed in 10% neutral formalin solution for histopathological examination. After fixation tissue samples were routinely prepared by automatic tissue processing equipment (Leica ASP300S; Leica Microsystem, Nussloch, Germany). The samples were embedded in paraffin, and 5 µm serial sections taken from sections were prepared using a Leica RM 2155 rotary microtome (Leica Microsystem, Nussloch, Germany). Then sections were stained with hematoxylin and eosin (HE) and examined under the 40X a light microscope. Morphometric evaluation and microphotography were performed using the Database Manual cellSens Life Science Imaging Software System (Olympus Corporation, Tokyo, Japan).

Prevalence (Pr %), as the percentage of hosts infected with a particular parasite species or taxonomic group and intensity (Int), as the number of individuals of a parasite species in/on a single infected host were calculated following Bush et al. (1997).

## RESULTS

Among eight host species (Table 1) examined for infestation with *Posthodiplostomum cuticola* (Nordmann, 1832), the highest prevalences (60.87%) of infection were reached in *Alburnus filippii*, a native fish from Ağıl Creek, followed by *A. escherichii* (57.14%) and *Squalius pursakensis*, endemic fish in Seydisuyu Creek (55%) (Table 2). With respect of mean intensity, the highest values were recorded in *A. filippii* (Ağıl Creek), *A. escherichii* (Seydisuyu Creek) and *Capoeta tinca* (Süvari Creek) (4.86; 4.75; 3.75 parasites/fish, respectively).

At the histopathological analysis, most of the black spots were composed of parasites surrounding by thick fibrous capsule around the encysted parasite developmental stages with periphery of the capsule containing numerous melanocytes. Most of the lesions contained one or more metacercariae of the parasites.

**Table 1.** Host fish species and their status

Fish Species	Family	Locality	River Basin	Status	Length (cm) (Min-Max)
<i>Squalius pursakensis</i>	Cyprinidae	Seydisuyu Creek	Sakarya	Endemic	8.7-19.4
<i>Alburnus escherichii</i>	Cyprinidae	Seydisuyu Creek	Sakarya	Endemic	5.2-15.1
<i>Chondrostoma angorense</i>	Cyprinidae	Seydisuyu Creek	Sakarya	Endemic	8.2-11.5
<i>Squalius turcicus</i>	Cyprinidae	Pasinler Creek	Aras	Endemic	10.2-14.9
<i>Alburnus filippii</i>	Cyprinidae	Pasinler Creek	Aras	Native	8.9-12.3
<i>Capoeta tinca</i>	Cyprinidae	Süvari creek	Sakarya	Endemic	16.2-24.0
<i>Chondrostoma colchicum</i>	Cyprinidae	Düzköy Creek	Çoruh	Native	7.6-13.4
<i>Cobitis taenia</i>	Cobitidae	Çerpeş Creek	Marmara	Native	7.0-9.4
<i>Capoeta tinca</i>	Cyprinidae	Karaçaltı Creek	Susurluk	Endemic	10.4-18.6
<i>Alburnus filippii</i>	Cyprinidae	Ağıl Creek	Aras	Native	8.2-11.6

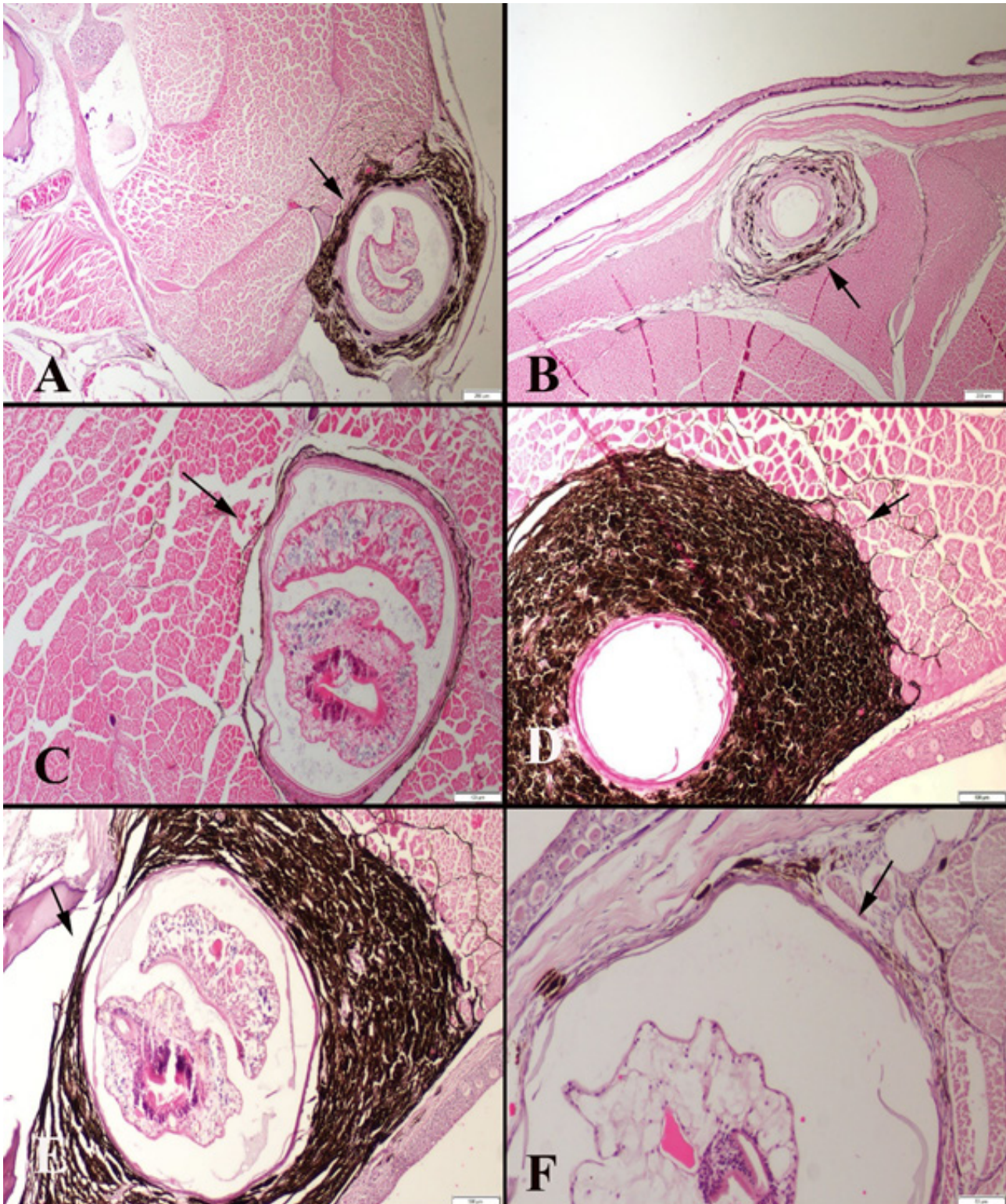
**Table 2.** Occurrence of *Posthodiplostomum cuticola* infestation in fish community of study area (N = total number of hosts examined; N' = number of infected fishes; Pr = prevalence)

Fish Species	Locality	N	N'	Pr%	Total parasite	Mean Intensity
<i>Squalius pursakensis</i>	Seydisuyu Creek	20	11	55	15	1.36
<i>Alburnus escherichii</i>	Seydisuyu Creek	14	8	57.14	38	4.75
<i>Chondrostoma angorense</i>	Seydisuyu Creek	11	4	36.36	7	1.75
<i>Squalius turcicus</i>	Pasinler Creek	11	4	36.36	11	2.75
<i>Alburnus filippii</i>	Pasinler Creek	12	4	33.33	9	2.25
<i>Capoeta tinca</i>	Süvari creek	9	4	44.44	15	3.75
<i>Chondrostoma colchicum</i>	Düzköy Creek	16	1	6.25	2	2.00
<i>Cobitis taenia</i>	Çerpeş Creek	22	10	45.45	32	3.20
<i>Capoeta tinca</i>	Karaçaltı Creek	15	3	20	7	2.33
<i>Alburnus filippii</i>	Ağıl Creek	23	14	60.87	68	4.86



The melanin capsules often presented an opening on the surface of cuticle layer. Amount of the melanocytes was different in each nodule. Either not observed at all or slight inflammatory reaction was observed near the lesions (Figure 2). The lesions were

usually associated with migration of developmental stages of the parasite within the host tissues. Atrophy of the muscle near the parasitic lesion was commonly noticed. Melanocytes were also observed between the muscles near the cysts.



**Figure 2.** Histopathology of the black spot lesions in fish muscle related to parasite developmental stages, with different severity of melanocytic reaction. HE, Bars=200 $\mu$ m (A, B), 100  $\mu$ m (C, D, E) and 50  $\mu$ m (F).





**Figure 3.** Black spot disease found in selected fishes in the present study

Grossly affected fishes exhibit multifocal black spots in the skin which were different in shape and diameter. Black spots were localized in all skin regions from mouth to caudal fin (Figure 3). In some fish hyperemia was observed around the lesions.

## DISCUSSION

Black-spot disease induced by *P. cuticola* was reported before in freshwater fish of Turkey, however there was no histopathological information available up to date. Worldwide, there is still a paucity of data concerning histological examination of fish diagnosed with posthodiplostomiasis. Nevertheless, few observations similar to ours on melanin deposits were made on: *Ctenopharyngodon idella* from a fishpond in Serbia (Markovic et al., 2012) and *Blicca bjoerkna*, *Rutilus rutilus*, *Scardinius erythrophthalmus* from a freshwater lake from Romania (Negrea et al., 2015). Parasitological data have been reported just for four species including *Alburnus escherichii*, *Capoeta tin-*

*ca*, *Squalius pursakensis* and *Cobitis taenia* (Öktener, 2014; Innal et al., 2016). On the other hand, *P. cuticola* was reported only in *Cobitis taenia* of eight host species. The prevalence and intensity levels of infection among host species differed by host and area. The prevalence of *P. cuticola* infection in all host species ranged from 6.25% to 60.87%. The difference in the prevalence is likely due to abiotic parameters of systems and also biotic factors such as host health status, age and size and fish community structure.

Bykhovskaya-Pavlovskaya et al (1962) stated that this parasite is found in the most common cyprinids, rarely seen in sturgeon, catfish and freshwater perch. Fish specimens which were examined in this study and recorded with *P. cuticola* infection support this view. Öztürk (2005) which recorded *P. cuticola* infection in skin and fins of *Cyprinus carpio* stated that the occurrence of parasite decreases in autumn and winter reaching its highest level during the summer period. The same research determined that *P. cuticola*

infection was found in carp fishes of 15-20 cm in size, but it was not found in fishes of 13 cm and smaller. In contrast to Öztürk (2005), in the present study small sized fish individuals were found infected by *P. cuticola*.

There is a little knowledge about pathology of the black spot disease in fishes. Histopathological observations revealed that the black spots on the fishes are melanized nodules formed against metacercaria of *P. cuticola*. In addition, inflammatory cell infiltration and atrophy of the skeletal muscle around the metacercaria of the parasite were common findings indicating inflammatory reaction. The parasites were penetrated under the skin of the fish and formed encysted metacercaria and covered by a thick fibrous capsule these findings being in agreement with classical knowledge

(Lane and Morris, 2000; Bush et al., 2001).

As a result, in this study, *P. cuticola* was determined to be a parasite species found in various fish species in different regions of Turkey. In addition, histopathological effects of this parasite species on host fish tissues were identified. In future studies, water birds in the study areas where parasitized fish live may be investigated whether they are infected with *P. cuticola*.

#### ACKNOWLEDGEMENT

The authors would like to thank Prof. Dr. Füsün Erkakan for her contributions to this study.

#### CONFLICT OF INTEREST

None declared

### REFERENCES

- Altan A, Soylu E (2018) Composition and structure of parasite communities in white bream *Blicca bjoerkna* from Lake Büyük Akgöl, Sakarya-Turkey. *Ege Journal of Fisheries and Aquatic Sciences* 35(2): 199-206.
- Bush AO, Lafferty KD, Lotz JM, Shostak AW (1997) Parasitology meets ecology on its own terms: Margolis et al. revisited. *Journal of Parasitology* 83: 575-583.
- Bush AO, Fernandez JC, Esch GW, Seed JR (2001) Parasitism: the diversity and ecology of animal parasites. Cambridge: Cambridge University Press. 312 p.
- Bykhovskaya-Pavlovskaya IE (1962) Key to the Parasites of the Freshwater Fishes of the U.S.S.R. Transl. Birrow A. ve Cale, Z.S. 1964 Israel Prog. for Scientific Trans. Jerusalem, p. 919.
- Kırankaya ŞG, Ekmekçi FG (2011) Frequency of black spot disease in *Cobitis cf. turcica* from Pınarbaşı Springs (Haymana, Turkey). *Folia Zoology* 60 (4): 350-354.
- Kvach Y, Jurajda P, Bryjová A, Trichkova T, Ribeiro F, Přikrylová I, Ondračková M (2017) European distribution for metacercaria of the North American digenean *Posthodiplostomum cf. minimum centrarchi* (Strigeiformes: Diplostomidae). *Parasitology International* 66(5): 635-642.
- Innal D, Aydoğdu A, Güçlü SS (2016) Invasion of *Schyzocotyle acheilognathi* (Yamaguti, 1934) (Cestoda: Bothriocephalidea) in Turkey. *Acta Biologica Turcica* 29(1): 20-25.
- Iqbal Z, Shukerova SA, Minhas IK (2014) Occurrence of black spot disease in *Labeo rohita* (Hamilton) fry in carp fish hatchery Lahore, Pakistan. *Canadian Journal of Pure and Applied Sciences* 8 (1): 2727-2731.
- Lane RL, Morris JE (2000) Biology, prevention and effects of common grubs (digenetic trematodes) in freshwater fish. Ames: Department of Animal Ecology/Iowa State University. Technical Bulletin Series, 115.
- Markovic G, Krsmanovic M (2008) The influence of *Posthodiplostomum cuticola* (Digenea, Trematodes) metacercaria infestation on the growth rate of *Leuciscus cephalus* L. (Cyprinidae, Pisces). *Acta Agriculturae Serbica* XIII, 26: 73-76.
- Marković M, Čirković M, Aleksić N, Milošević N, Olivera BČ, Dragana L, Aksentijević K, Radojičić M (2012) Posthodiplostomosis in a fishpond in Serbia. *Acta Veterinaria (Beograd)*, 62(1): 101-109.
- Mierzejewska K, Wlasow T, Kapusta A, Szymanczyk K (2004) Fish digeneans from the Seven Islands Ornithological Reserve at Oswin Lake Poland. Part I. *Posthodiplostomum cuticola* von Nordmann, 1832. *Acta Ichthyologica et Piscatoria* 34(1): 73-84.
- Negrea O, Mireşan V, Răducu C, Onaciu G, Negrea O, Laţiu C, Cocan D (2015) Some Investigations on incidence and infestation level in cyprinid posthodiplostomosis. *Bulletin of the University of Agricultural Sciences & Veterinary Medicine Cluj-Napoca. Animal Science & Biotechnologies* 72(2): 203-206.
- Ondračková M, Šimková A, Gelnar M, Jurajda P (2004) *Posthodiplostomum cuticola* (Digenea: Diplostomidae) in intermediate fish hosts: factors contributing to the parasite infection and prey selection by the definitive bird host. *Parasitology* 129: 761-770.
- Öktemer A (2014) Revision of parasitic helminths reported in freshwater fish from Turkey with new records. *Transylv. Rev. Syst. Ecol. Res.* 16(1): 1-56.
- Öztürk OM (2005) An investigation of metazoan parasites of common carp (*Cyprinus carpio* L.) in Lake Eber, Afyon, Turkey. *Acta Parasitologica Turcica* 29 (3): 204-210
- Pritchard MH, Kruse GOW (1982) The Collection and Preservation of Animal Parasites. Univ. of Nebraska Press, Lincoln, U.S.A., p.141.
- Rolbiecki L (2004) Distribution of *Posthodiplostomum cuticola* (Nordmann, 1832) (Digenea; Diplostomidae) metacercariae in Cyprinids of the Vistula Lagoon, Poland. *Archives of Polish Fisheries* 12 (1): 93-98.
- Zrnčić S, Oraić D, Mihaljević Ž, Čaleta M, Zanella D, Jelić D, Jelić M (2009) First observation of *Posthodiplostomum cuticola* (Nordmann, 1832) metacercariae in cypriniformes from Croatia. *Helminthologia*, 46 (2): 112-116.