

Journal of the Hellenic Veterinary Medical Society

Vol 70, No 4 (2019)



Conjoined Twins in Red Sokoto Goat

i. AHMAD, U.M. CHAFE, A.A. UMAR, M.D. SALISU

doi: [10.12681/jhvms.22245](https://doi.org/10.12681/jhvms.22245)

Copyright © 2020, i. AHMAD, U.M. CHAFE, A.A. UMAR, M.D. SALISU



This work is licensed under a [Creative Commons Attribution-NonCommercial 4.0](https://creativecommons.org/licenses/by-nc/4.0/).

To cite this article:

AHMAD, i., CHAFE, U., UMAR, A., & SALISU, M. (2020). Conjoined Twins in Red Sokoto Goat. *Journal of the Hellenic Veterinary Medical Society*, 70(4), 1919–1924. <https://doi.org/10.12681/jhvms.22245>

Conjoined Twins in Red Sokoto Goat

I. Ahmad^{1,*}, U.M. Chafe², A.A. Umar², M.D. Salisu³

¹*Directorate of Animal Health and Livestock Development, Gusau, Zamfara Nigeria*

²*Faculty of Veterinary Medicine, Usmanu Danfodiyo University Sokoto, Nigeria*

³*National Animal Production Research Institute, Ahmadu Bello University Zaria, Nigeria*

Abstract. A case of female conjoined twins was found in Red Sokoto goat, delivered alive along with a free male kid without obstetrical assistance. The abnormal twins were examined clinically and at postmortem. Based on morphological features, they could be classified as thoraco-omphalopagus symmetrical conjoined twins. Autopsy showed that fusion occurred at ventral-midline from the cranial region of the thorax to abdomen caudal to the umbilicus; thus, only head, neck and pelvis were separated. Genetic factors could be suspected in this case. This is the first report of thoraco-omphalopagus symmetrical twinned goat in Nigeria.

Keywords: Conjoined twins; Red Sokoto goat; Nigeria

Corresponding Author:
Ibrahim Ahmad, Directorate of Animal Health and Livestock Development,
Gusau, Zamfara Nigeria
Email address: ibrahimahmaad22@gmail.com

Date of initial submission: 14-04-2019
Date of revised submission: 09-10-2019
Date of acceptance: 10-10-2019

INTRODUCTION

Conjoined twins represent rare congenital malformations of monozygotic twins, thus abnormalities in their anatomy arise during prenatal development (Kulawik *et al.*, 2017). The term duplication, often used regarding conjoined twins, does not intrinsically imply either fission or fusion process, but it describes the formation of double structures regardless of their origin (Schneevoigt *et al.*, 2014). Congenital duplication etiopathogenesis is considered to be a complex of processes with various influencing factors at different time-points (Elnady and Sora, 2009). Previous report has attributed the development of conjoined twins to either environmental or genetic factors, or both (Kulawik *et al.*, 2017).

Although there is paucity of information regarding the definitive cause(s) of embryonic duplications, the separation of fused twins only becomes feasible when the two components do not share any vital parts or organs. Given the developmental disorders that may affect function of systems or organs in the malformed twins, surgical separation often leads to poor prognoses and is not always an option (Kulawik *et al.*, 2017). Conjoined dysmorphologies can affect several systems not only limited to the fused parts, which usually have syndromic manifestations (Binanti and Riccaboni, 2012). Organ dysfunction, failure, and even death are the implications often associated with abnormalities arising during prenatal development (Kulawik *et al.*, 2017). The occurrence of conjoined twins is sporadic and very rare, thus most of its aspects remain hypothetical; however, the description of its cases benefits both veterinary and medical sciences (Schneevoigt *et al.*, 2014). In domestic animals, such aberrations are rare and remain under-reported (Samuel *et al.*, 2014). The present article describes

a case of thoraco-omphalopagus symmetrical conjoined female twins in Red Sokoto goat.

CASE HISTORY

On March 4, 2018, female conjoined kids weighing approximately 2.8 kg were delivered alive and without obstetrical assistance by a multiparus doe in Tsafe town, Zamfara State, Northwest Nigeria. They were delivered along with a normal male kid (1.3 kg) (Figure 1). The normal weight at birth for kids of Red Sokoto goat is about 1.5-2.0 kg. One of the conjoined kids died at the flock a day after the delivery, although it remained attached to the living twin and were referred to the Zonal Veterinary Clinic Gusau, Zamfara State (Figure 2). The 4 years old doe was managed on free range system with three other goats and a buck and had two sets of normal twin kids in the previous parturitions. Flock history revealed no evidence of use of drugs known to cause congenital defects, occurrence of teratogenic infections, or previous record of malformation.

The conjoined kids was attached from thorax to the caudal umbilicus (Figure 3). Clinical examination revealed the following: (a) two components referring to the left and right twins, named kid A and kid B (Figure 2), (b) an increased respiration rate and mild dehydration in kid B that was alive, (c) complete duplication of the head and neck down to the thorax, (d) complete duplication of the vertebral column (thoracic, lumbar and sacral vertebrae), anus, vulva, and tail (e) two forelimbs attached on each kid in normal spatial orientation, (f) shared umbilical cord, and (g) two unattached pelvis with two hind limbs on each twin at normal positions. The length of the body parts for each kid was recorded (Table 1). The alive twin died during surgical separation.

Table 1: Body measurements of normal kid and thoraco-omphalopagus conjoined twins in Red Sokoto goat.

	Normal kid	Left twin (A)	Right twin (B)
Head-tail length (cm)	37.5	37.5	37.5
Neck length (cm)	2	2	2
Tail length (cm)	2	2	2
Fore-and-hind limbs length (cm)	18	18	18



Figure 1. Normal male kid.



Figure 3. Lateral view of the conjoined twins showing fusion of thoraxes and abdomen to point of umbilicus.

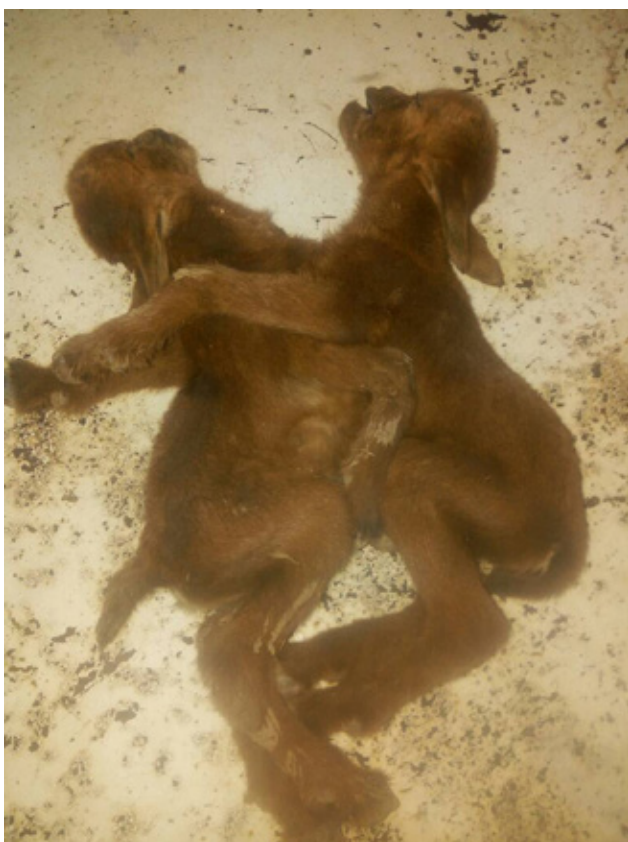

Figure 2. Conjoined kids, showing two components referring to the left and right twin, named kid A and kid B.

Autopsy revealed complete fusion of the thoraxes and abdomen to the caudal umbilicus at ventral mid-line, two pairs of normal rib cages ventrally joined by 2 sterna, two completely divided but attached thoracic cavities containing only one hypertrophic heart (located only in kid B with two branched aorta emanating from the left ventricle; each branch supplies the organs of the individual twin component), and complete bilateral duplication of the well aerated lungs (Figure 4). The ribs formed the lateral walls of the two thoraxes, articulated with the facets of thoracic vertebrae on the median plane and ventrally to the sternum. The attached thoraxes were separated from the abdomen by a single diaphragm. In the abdominal cavity of each twin, the gastrointestinal tract was duplicated containing esophagus, four compartment stomachs (rumen, reticulum, omasum and abomasum), spleen, pancreas and intestines (duodenum, jejunum, ileum, caecum, colon and rectum); however, a single enlarged liver and a gall bladder were found only in kid B. Each twin contained a normal urogenital system in the characteristic anatomical positions (Figure 5). There were uterus, two kidneys, ureters and bladder that discharged into a urethra, duplicates of anus and vulva on each component.

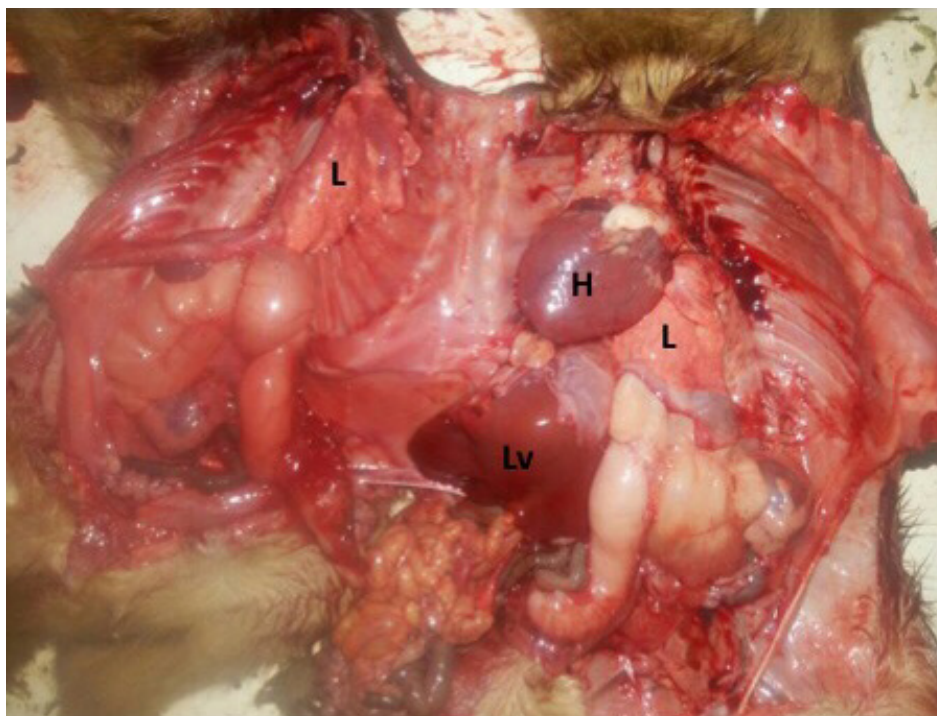


Figure 4. Cut opened conjoined twins showing single enlarged heart (H) and liver (Lv) found only in kid B, and bilateral duplication of the well aerated lungs (L).



Figure 5. Photograph showing a comparison of the internal organs recovered from each twin. 1. Uterus 2. Single heart 3. Inflated lungs 4. Kidneys 5. Intestines

DISCUSSION

Identification of the conjoined twins is often made based on the morphological appearance of the duplication anomaly. Classifications can be based on site of the union, embryological development, anatomy, and symmetry level of the twins (Chen, 2012). Although the ventrally fused twins in this case were of equal size, they were conjoined at the thoracic cavity and cranial one third of the abdominal cavity. Kid A (parasite) has all internal organs except heart, liver, and gallbladder which makes it dependent on kid B (autosite). These kids are completely well developed and symmetrical, each exhibiting a set of structures that is an imitation of its counterpart; thus they are called diplopagus. Classification into either conjoined symmetrical (complete) or conjoined asymmetrical (incomplete) is based on the normal-length duplication of vertebral column; duplicated partially in asymmetrical and fully in symmetrical congenital twins. The externally visible point of attachment is also commonly used to classify conjoined twins. In the study subjects, this duplication occurred across the entire body parts but fused at the ventral-midline between thoraces (thoracopagus) and caudal umbilicus (omphalopagus), leading to a classification as thoraco-omphalopagus. The conjoined twins documented

in this report were similar to that previously found in goats by Binanti and Riccaboni (2012); however, this occurrence is rare (Elnady and Sora, 2009). The present case is unique because all structures are nearly doubled except heart, liver, gallbladder, and umbilicus; thus it is different from the previous report (Binanti and Riccaboni, 2012) which described additional uncommon malformations such as persistent right aortic arc, foramen ovale, and patent ductus arteriosus. Conjoined twins was female, as in previous reports (Binanti and Riccaboni, 2012; Mazaheri *et al.*, 2014; Schneevoigt *et al.*, 2014).

The fusion of the thorax and abdomen represents an abnormal articulation at the ventral midline, presenting morphological alterations of the sternum and abdominal wall. No obvious abnormality associated with the respiratory organs in both the thoraces was observed, as reported previously (Binanti and Riccaboni, 2012; Schneevoigt *et al.*, 2014). A common liver and umbilical cord shared between the twins found in this case is similar to the report of Binanti and Riccaboni (2012). Abdominal structures such as esophagus, four chambered stomachs, intestines, pancreas and spleen were entirely duplicated without any fusion. This observation varies with the findings in the literature (Binanti and Riccaboni, 2012; Schneevoigt *et al.*, 2014). The entire gastrointestinal tract is rarely doubled in siamese twins (Spencer, 2000). The urogenital organs found in this case were doubled (four kidneys, two bladders, four ovaries, and oviducts, as well as two bicornuate uterus and vagina), as widely confirmed previously in conjoined twins (Spencer, 2000). As concern the cardiovascular system defect involved there was a single functioning heart for both kids, which is similar to heart defects previously described in congenital twinning (Binanti and Riccaboni, 2012; Schneevoigt *et al.*, 2014; Kulawik *et al.*, 2017). The enlarged heart and branched aorta found in the right kid B, reflected the right twin heart being the pumping donor to the left twin A. Thus, in this form of defect Twin-Twin Transfusion Syndrome (TTTS) might be a conceivable consequence of arteriovenous anastomoses (Bahlmann, 2009). Cells are not split equally in monozygotic twinning process, resulting in a larger number of cells in one twin leading to a delay in cardiac development of the twin that had received fewer cells (Benirschke, 2009).

Information about the cause(s) of congenital duplication anomalies is rarely available (Shojaei *et al.*, 2012). Two hypotheses such as fusion and fission

have been proposed regarding conjoined twins, but the mechanism of its development is incompletely understood (Binanti and Riccaboni, 2012). Thus, diplopagus could arise either due to incomplete separation of a single fertilized ovum as in monozygotic twins or by secondary fusion between two different embryonic axes. Mis-expression of gene and secreted protein signals may be implicated in congenital duplication, affecting the regulation of right-left asymmetry or left-right axis formation (Mazaheri *et al.*, 2014; Kulawik *et al.*, 2017). In Nigeria, the predominant free-range management system favors exposure of pregnant animals to toxic plants, drinking water, and forages contaminated by various chemicals (e.g. pesticides, herbicides and inorganic fertilizers) being applied without caution. Furthermore, the practices of unregulated mining activities could lead to enhanced exposure of animals to hazardous heavy metals and radiation-induced hyperthermia. Exposure to some of these factors or their combination can serve as exogenous disruptors, thereby acting as substrate in allometric growth impairments leading to in-utero developmental errors. In addition, lack of dietary supplements and frequent use of hormone treatment are in part linked to the higher incidence of conjoined twins in animals (Schneevoigt *et al.*, 2014; Kulawik *et al.*, 2017). Previous report described the above mentioned as probable causes of congenital abnormalities in animals (Kulawik *et al.*, 2017). Moreover, a genetic mutation was speculated as the probable cause of a similar malformation described by Binanti and Riccaboni (2012).

This is the first report of thoraco-omphalopagus symmetrical conjoined twins in animals in Nigeria. The article presented the anatomical findings of conjoined twins born alive, after clinical and postmortem examinations. Malformations of skeletal, cardiovascular, and digestive systems were revealed. Prompt reporting of such cases is encouraged to aid in the epidemiological surveys of malformations in animals and accurate identification of the probable cause(s) and compounding factors.

ACKNOWLEDGEMENTS

Authors gratefully acknowledge Nura Aminu Tsafe for referring the case and Dr Junaidu Ibrahim of the zonal veterinary clinic, Gusau Zamfara State for his technical support.

CONFLICT OF INTEREST

None declared.

REFERENCES

- Bahlmann F (2009) Monochorionic twin pregnancy and the following problems. *Z. Geburtshilfe Neonatol* 6: 234-237.
- Benirschke K (2009) The monozygotic twinning process, the twin-twin transfusion syndrome and acardiac twins. *Placenta* 11: 923-928.
- Binanti D, Riccaboni P. (2012) Thoraco-Omphalopagus conjoined twins in chamois-coloured domestic goat kids. *Anatomia Histologia Embryologia* 3: 159-162.
- Chen H (2012) Atlas of genetic diagnosis and counselling. Springer-Verlag, New York: pp 495-505.
- Elnady F, Sora M-C (2009) Anatomical exploration of dicephalous goat kid using sheet plastination. *Congenit Anom* 49: 66-70.
- Kulawik M, Pluta K, Wojnowska M, Bartyzel B, Nabzdyk M, Bukowska D (2017) Cephalothoracopagus (monocephalic dithoracic) conjoined twins in a pig (*Sus scrofa f. domestica*): a case report. *Veterinari Medicina* 62(08): 470-477.
- Mazaheri Y, Nourinezhad J, Ranjbar R, Mahabady MK, Ghadiri AR, Lombeshkon H (2014) A case of conjoined twins (thoraco-omphalopygopagus tribrachius tetrapus) in lamb. *Veterinary Research Forum* 5(1): 73-76.
- Samuel MO, Wachida N, Abenga JH, Kisani AI, Adamu SS, Hambesha P, Gyang E, Oyedipe EO (2014) A case of omphalo-ischiopagus (dicephalic dithoracic abdominopagus tetrascelus tetrabrachius) in lambs. *Anatomia Histologia Embryologia* 43(4):320-323.
- Schneevoigt J, Bahramsoltani M, Gerlach K, Gericke A, Fersterra M, Brehm W, Seeger J (2014) Parapagus conjoined twin calf: a case study-focused on CT and cardiac abnormalities. *Anatomia Histologia Embryologia* 43: 64-70.
- Shojaei B, Mohebbi E, Hashemnia S (2012) Caudal duplication (*monocephalus tripus dibrachius*) in a kid goat. *Eur J Anat* 16(3): 206-211.
- Spencer R (2000) Theoretical and analytical embryology of conjoined twins: Part II: adjustments to union. *Clin Anat* 13: 97-120.