

Journal of the Hellenic Veterinary Medical Society

Vol 70, No 4 (2019)



Arthrectomy for traumatic proximal interphalangeal arthritis in the lateral digit in a heifer

A. GOTO, N. TSUZUKI, A. tsuzuki@obihiro.ac.jp
KAJIHARA, T. MORIYAMA, Y. SASAKI, N. ZUSHI, K.
HATATE, K. IINO, N. YAMAGISHI

doi: [10.12681/jhvms.22244](https://doi.org/10.12681/jhvms.22244)

Copyright © 2020, A. GOTO, N. TSUZUKI, A. tsuzuki@obihiro.ac.jp
KAJIHARA, T. MORIYAMA, Y. SASAKI, N. ZUSHI, K. HATATE, K.
IINO, N. YAMAGISHI



This work is licensed under a [Creative Commons Attribution-NonCommercial 4.0](https://creativecommons.org/licenses/by-nc/4.0/).

To cite this article:

GOTO, A., TSUZUKI, N., KAJIHARA, A. tsuzuki@obihiro.ac.jp, MORIYAMA, T., SASAKI, Y., ZUSHI, N., HATATE, K., IINO, K., & YAMAGISHI, N. (2020). Arthrectomy for traumatic proximal interphalangeal arthritis in the lateral digit in a heifer. *Journal of the Hellenic Veterinary Medical Society*, 70(4), 1911–1918. <https://doi.org/10.12681/jhvms.22244>

Arthrectomy for traumatic proximal interphalangeal arthritis in the lateral digit in a heifer

A. Goto¹, N. Tsuzuki², A. Kajihara¹, T. Moriyama¹, Y. Sasaki¹, N. Zushi¹, K. Hatate³,
K. Iino², N. Yamagishi^{2,3}

¹ *Veterinary Medical Center, Obihiro University of Agriculture and Veterinary Medicine, Japan*

² *Section of Large Animal Clinical Sciences Department of Veterinary Medicine, Obihiro University of Agriculture and Veterinary Medicine, Japan*

³ *The United Graduate School of Veterinary Sciences, Gifu University, Japan*

ABSTRACT. Instructive information on the treatment for chronic deep infections of digital joints in a 9-month-old Holstein heifer is described in this report. Preoperative ultrasonographic and radiographic examinations revealed soft tissue swelling and subchondral bone lysis at the distal part of the proximal phalanx in the lateral digit. Arthrectomy was performed under xylazine sedation to remove infectious articular cartilage tissues. Immature callus formation was observed via radiography at the surgical site by the 28th postoperative day. On the 48th postoperative day, callus fell into disrepair on the radiographs along with aggravation of the locomotion score. After the application of a half-limb cast, the immature callus formed again by the 62nd postoperative day (11 months), and bony callus formation was observed by the 74th postoperative day. Thereafter, the heifer could walk well with marked improvement in the locomotion score. The withers height of the heifer at 13 months (136 cm) was within the range of that in control heifers of the same age on this farm (133 ± 3 cm); however, the body weight (BW) of this heifer (322 kg) was lower than the BW of controls (384 ± 26 kg). The BW gain from 11 to 13 months of age seemed to be higher in the present heifer (+76 kg) than in controls (+55±20 kg), suggesting that BW of the present heifer was returning to the original BW. Based on these observations, we suggested that arthrectomy was an effective treatment option for the present case of digital joint arthritis.

Keywords: arthrectomy, arthritis, cow, external fixation, productivity

Corresponding Author:

Nao Tsuzuki, 2-11 Inada, Nishi, Obihiro, Hokkaido 080-8555, Japan
E-mail address: tsuzuki@obihiro.ac.jp

Date of initial submission: 07-02-2019

Date of revised submission: 14-05-2019

Date of acceptance: 27-05-2019

CASE HISTORY

A 9-month-old Holstein heifer (228 kg body weight; BW) was referred to the Obihiro University Veterinary Medical Center owing to a traumatic lesion on the proximal interphalangeal joint of the left hind limb that was injured 12 days prior. Before arriving to the medical center, the heifer underwent treatment with antibiotics and non-steroidal anti-inflammatory drugs by the referring veterinarians. Physical examination at the day of admission revealed a rectal temperature of 39.1°C, heart rate of 144 bpm, and respiratory rate of 72 bpm. The heifer had a non-weight-bearing left hind limb and marked pain and swelling around the proximal interphalangeal joint. A locomotion scoring system scored on a scale of 1 to 5 (Sprecher et al., 1997) gave a score of 5 that declared the most severe lameness. Several abrasions were observed on the skin around the proximal interpha-

langeal joint; one of those formed a 5-cm-deep open wound with suppurative exudate at the cranial side of the lateral proximal interphalangeal joint (Figure 1A). Preoperative radiographs confirmed soft tissue swelling and subchondral bone lysis at the distal part of the proximal phalanx in the lateral digit of the affected limb, suggesting proximal interphalangeal arthritis (Figure 1B). Ultrasonography of the lateral digit of the left hind limb revealed that the open wound was connected to the lateral proximal interphalangeal joint while conserving the superficial and deep digital flexor tendon structures (Figure 2).

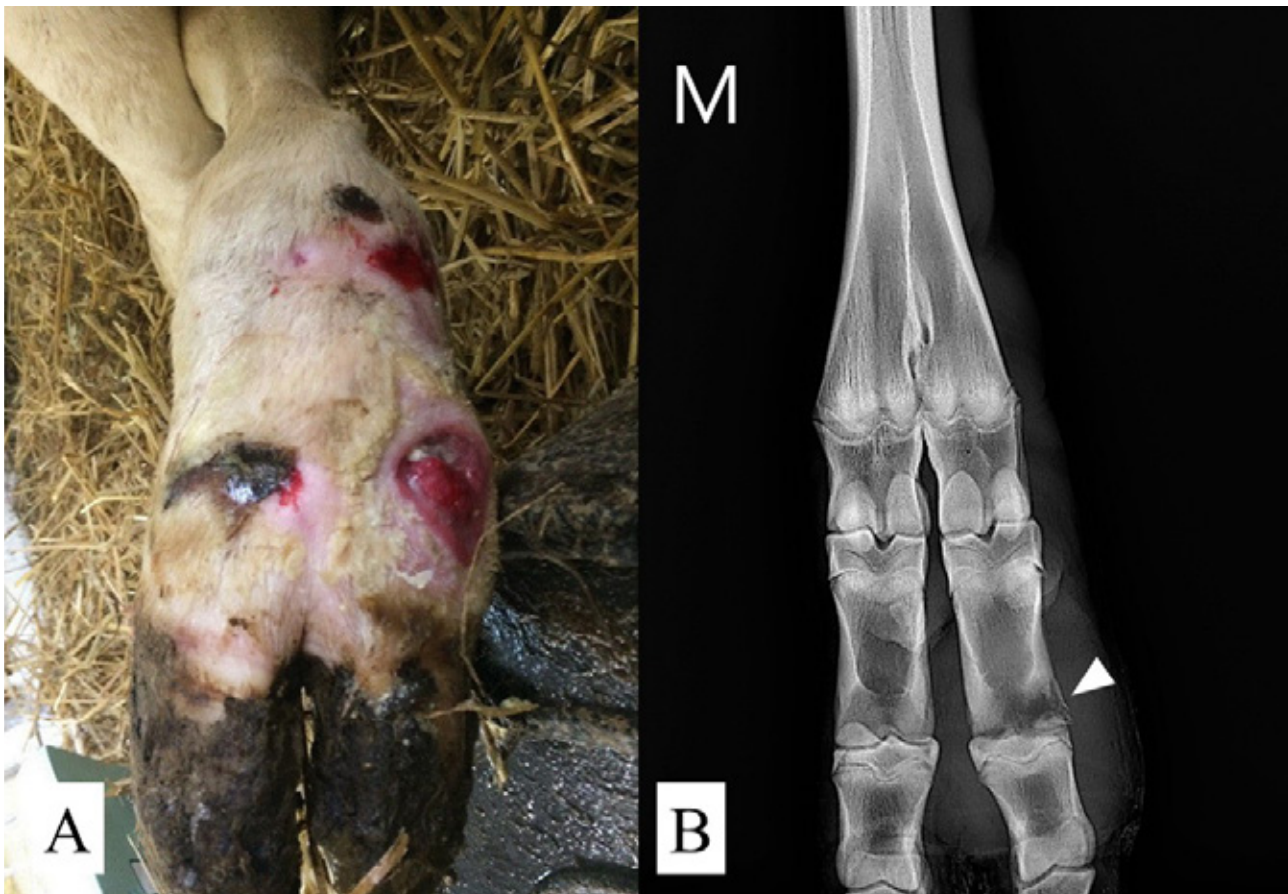


Fig 1. Pre-surgical photograph and radiograph (Dorsal-Plantar view) of the distal left hind limb. (A) Site of trauma around the proximal interphalangeal joint. (B) Subchondral bone lysis at the proximal interphalangeal joint in the lateral digit of the affected limb (white arrow). Swelling of soft tissue is recognized at the circumference of joint.

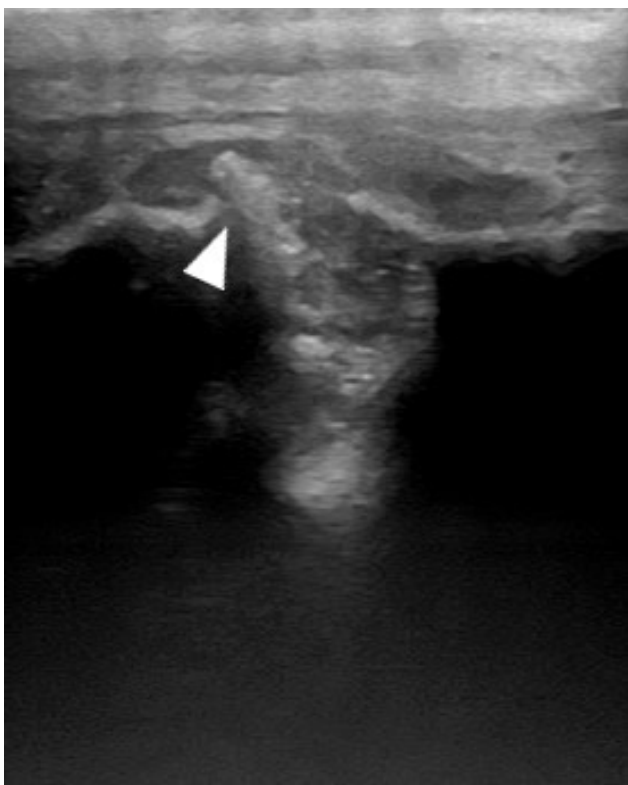


Fig 2. Ultrasonography image of the lateral digit of the left hind limb. Open wound was connected to the lateral proximal interphalangeal joint (white arrow).

The heifer was sedated with 0.1 mg/kg BW of xylazine (Seractal; Bayer, Osaka, Japan) intravenously and ceftiofur (Excenel; Zoetis, Tokyo, Japan; 2 mg/kg BW) was administered intramuscularly. The animal was positioned in the right lateral recumbency with the left hind limb upward. The skin around the proximal interphalangeal joint was aseptically prepared, the sciatic nerve blockade under ultrasound-guidance (Re., et al 2014) and local infiltration anesthesia around the open wound at the lateral proximal interphalangeal joint were induced by injecting of 2% lidocaine solution (Xylocaine; AstraZeneca, Osaka, Japan).

First, the degenerative cutaneous and subcutaneous tissues were debrided from the open wound using a surgical scalpel, and communication into the proximal interphalangeal joint was confirmed. Next, artherectomy was performed using a bone rongeur and an osteotrite to remove infectious articular cartilage tissues. The surgical wound, including the crevice of artherectomy, was then irrigated with 3 liters of sterile saline using an infusion tube that was 2.1 mm in diameter. Finally, the surgical wound was bandaged to cover the lateral digit, and hoof block was applied

on the heel of the medial digit of the affected limb for relieve a load applied to a lateral digit. The surgery was completed in 40 minutes after xylazine administration, and intravenous atipamezole (0.01 mg/kg BW; atipame-chu; Kyoritsu Pharmaceutical, Tokyo, Japan) was administered to the heifer to reverse the effect of sedation.

After complete recovery from sedation, the heifer returned to the farm. Ceftiofur (2 mg/kg BW, intramuscularly, SID) was administered for 5 days postoperatively, and the bandage was changed after lavage was performed at intervals of 2 days. Hoof block was removed 14 days after surgery.

On the 28th postoperative day, radiographic examination was conducted, which revealed an immature callus at the distal part of the proximal phalanx of the lateral digit with reduced adjacent soft tissue swelling in the affected limb (Figure 3). Results of ultrasonography confirmed that the swelling of the soft tissues around the surgical wound subsided. The locomotion score improved (a score of 3) on that day.

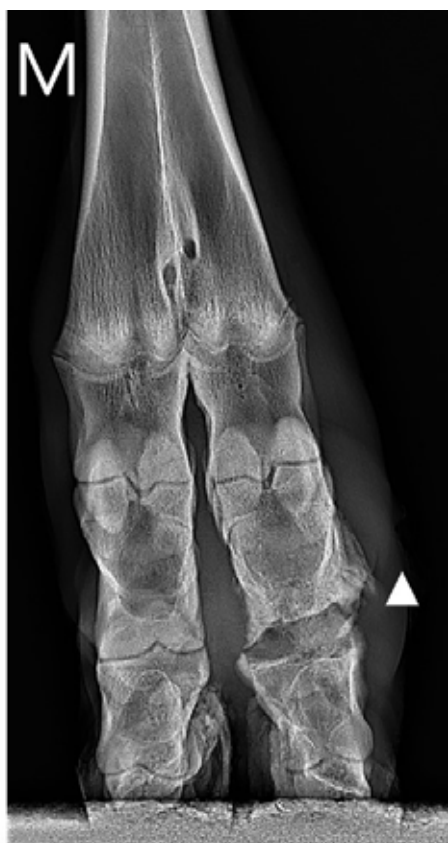

Fig 3. Post-surgical radiograph (Dorsal-Plantar view) of the distal left hind limb obtained on the 28th postoperative day. An immature callus was observed on the lateral side of proximal phalanx (white arrow). Soft tissue swelling was still recognized at the circumference of joint.

On the 48th postoperative day, the locomotion score aggravated (a score of 4) although the surgical wound was closed without swelling (Figure 4A). Radiography confirmed disrepair of the immature callus at the distal part of the proximal phalanx in the later-

al digit of the affected limb (Figure 4B). An external coaptation with a half-limb cast was applied from the sole of the hoof to the mid-metacarpus proximally (Figure 4C).

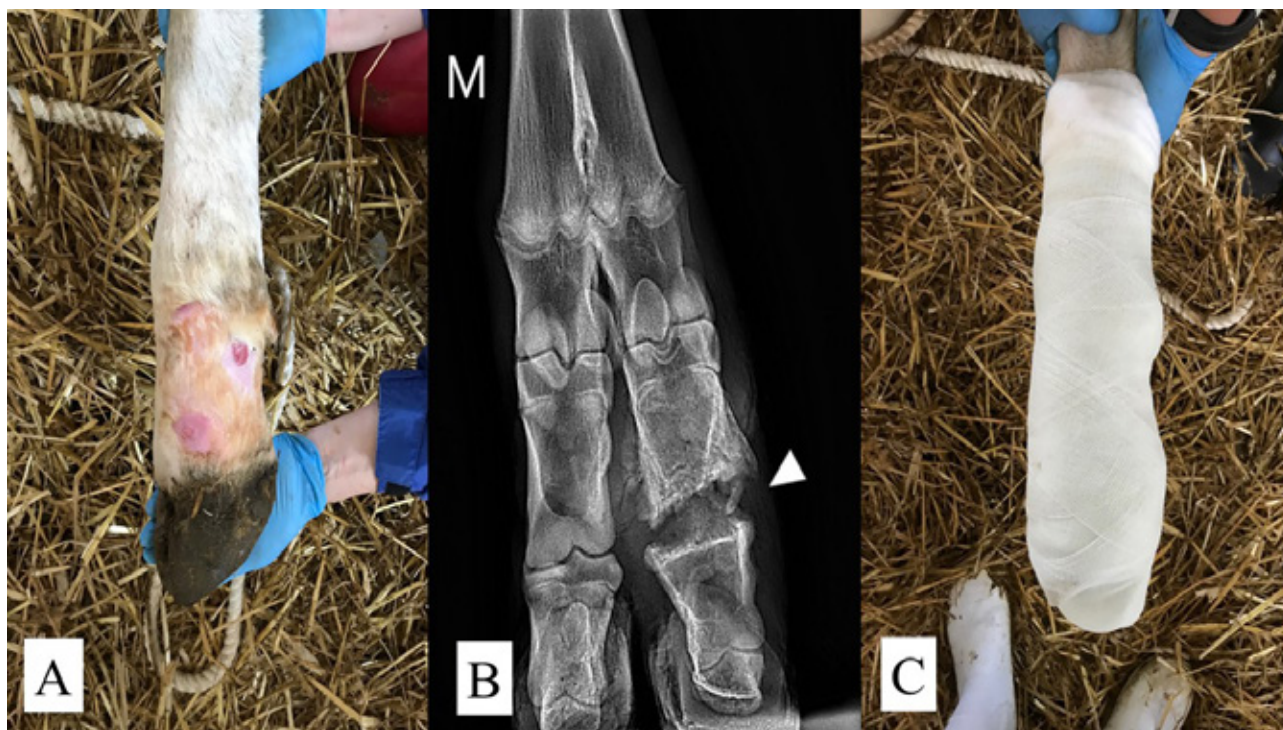

Fig 4. Post-surgical photograph and radiograph (Dorsal-Plantar view) of the distal left hind limb on the 48th postoperative day. (A) Well-healed wound. (B) Disrepair of immature callus at the distal part of the proximal phalanx in the lateral digit of the affected limb (white arrow). Reduced soft tissue irritation recognized at the circumference of joint. (C) An external coaptation with a half-limb fiberglass cast.

On the 62nd postoperative day, the immature callus was observed again at the distal part of the proximal phalanx on the radiographs (Figure 5A), and the locomotion score had improved (a score of 3). The half-limb cast was exchanged on that day.

On the 74th postoperative day, radiography was performed, which revealed bony callus formation at the distal part of the proximal phalanx (Figure 5B). The heifer was able to walk better with improvement in the locomotion score (a score of 2); the half-limb cast was then removed.

On the 88th postoperative day, the gait of the heifer seemed to be normal; the locomotion score was 1.

At 6 months post-surgery, there were no abnormalities in the stride and weight shift of the gait, although the heifer showed a cowhocked posture when standing (Figure 6A and B). Radiography was performed, which revealed adequate bony callus at the

distal part of the proximal phalanx in the lateral digit of the affected limb (Figure 6C). The withers height of the heifer was 136 cm (age: 13 months), which was comparable to that of the control (25 heifers of the same age in this herd) heifers (average: 133 ± 3 cm). Figure 7 shows the change in BW of the present heifer and those of control from 1 to 13 months based on the records from this farm. BW of the heifer was 266 kg approximately 2 weeks before the injury occurred, which reduced to 228 kg (-38 kg) prior to arrival to our hospital (age: 9 months). After arthroctomy was performed, BW of the heifer was 246 kg at 11 months, which was increased to 322 kg ($+76$ kg) at 13 months. The mean BW of the control was 329 kg at 11 months and increased to 384 kg ($+55$ kg) at 13 months.

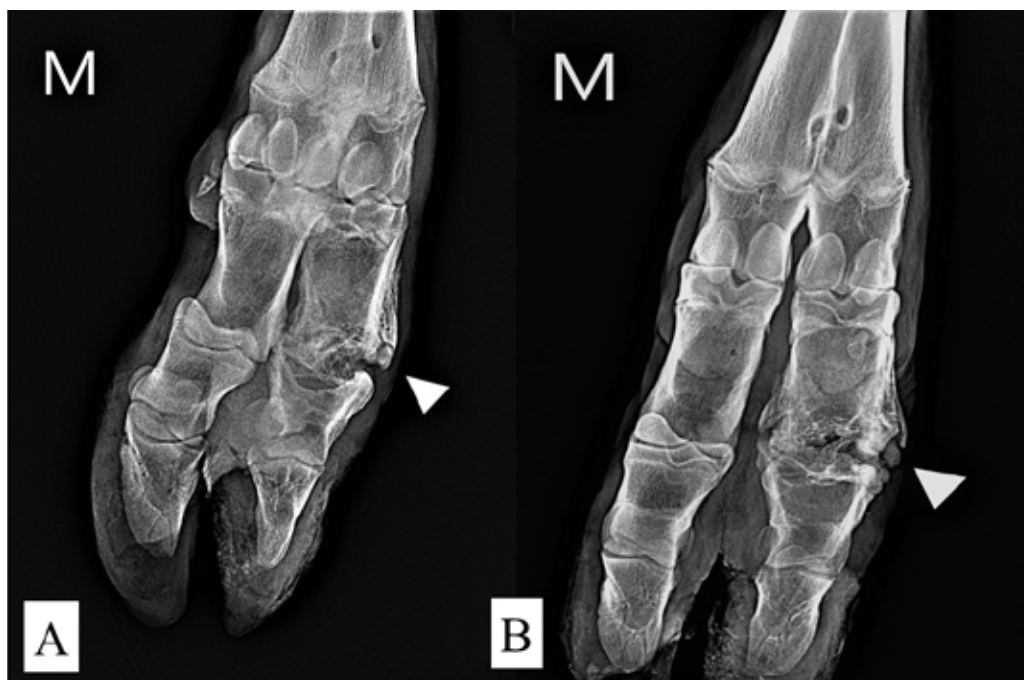

Fig 5. Post-surgical radiograph (Dorsal-Plantar view). An immature callus was observed on the lateral side of proximal phalanx again (white arrow) on (A) the 62th and (B) the 74th postoperative days.

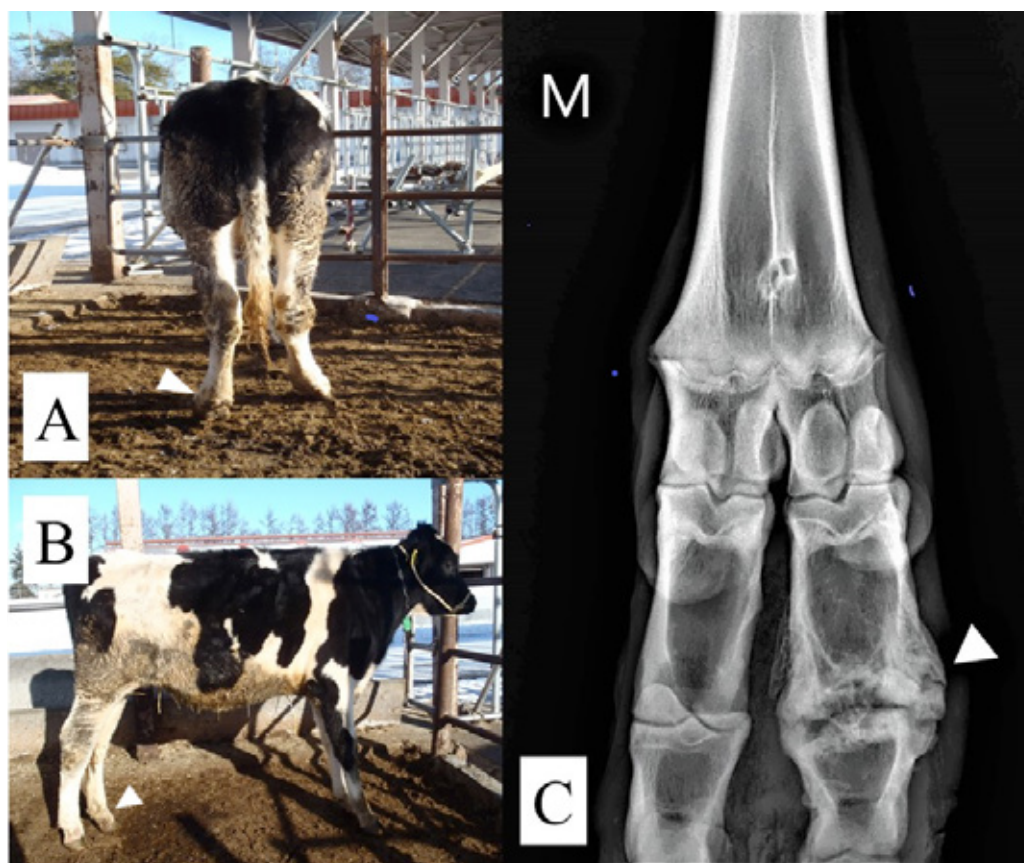


Fig 6. Post-surgical photograph (Dorsal-Plantar view) and radiograph in the 6th postoperative month. (A) Sufficient weight-bearing on the affected limb of dorsal view (white arrow). (B) Sufficient weight-bearing on the affected limb of lateral view (white arrow). (C) Radiographs confirmed an adequate bony callus at the distal part of the proximal phalanx in the lateral digit of the affected limb (white arrow).

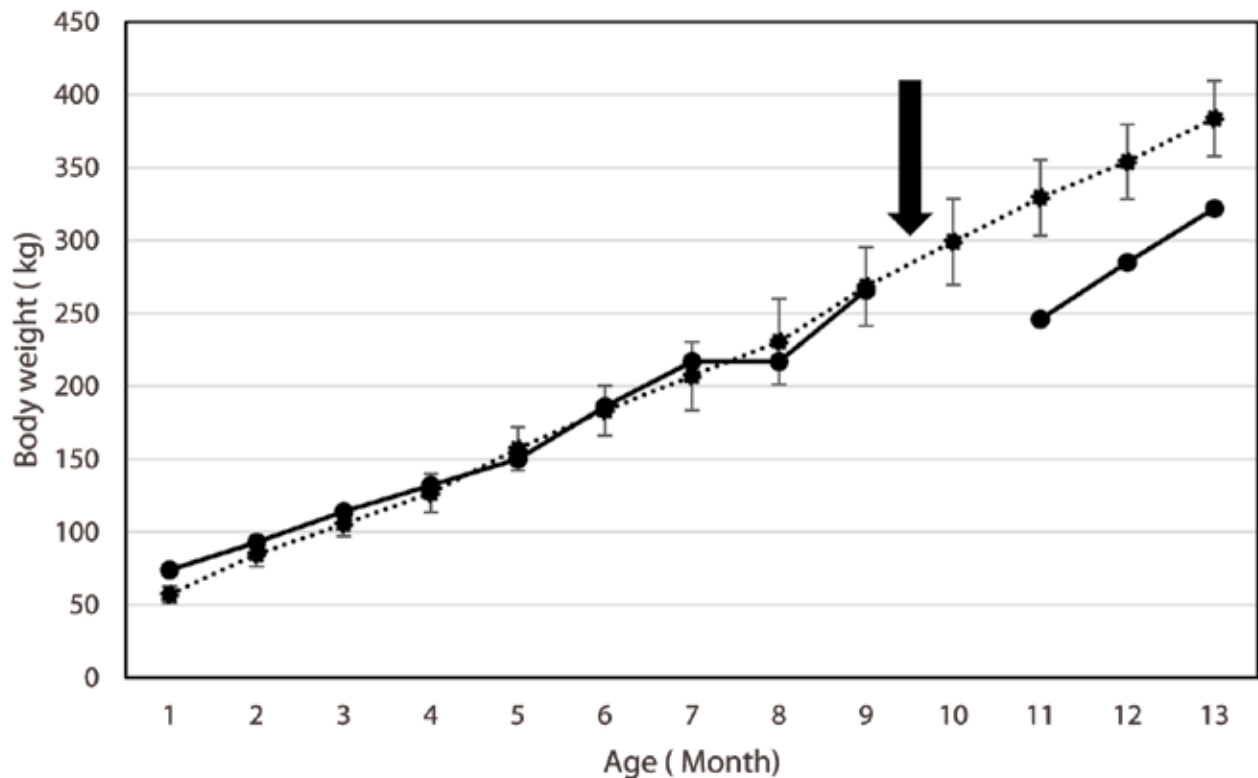


Fig 7. Change in the body weight of the present heifer (solid line) and control heifers (n=25) in this herd (dotted line; mean \pm standard deviation) from 1 to 13 months of age. The black arrow indicates the time of injury in the heifer.

DISCUSSION

For 12 days prior to arrival, the present heifer had a non-weight-bearing left hind limb with marked pain and swelling around its proximal interphalangeal joint, despite receiving treatment with antibiotics and non-steroidal anti-inflammatory drugs by the referring veterinarians. We decided to perform arthrectomy, followed by synarthrosis. The heifer had a favorable clinical and radiographic outcome with good wound healing; however, repeated surgical wound lavage followed by external coaptation was needed up to the 74th postoperative day.

Septic arthritis is the most common condition affecting joints of cattle. It can be caused by direct trauma, an adjacent infection, or systemic infection (Desrochers, 2004). Once pus accumulates in the joint cavity and invades the peri-articular soft tissues, needle lavage and arthrotomy with open drainage are insufficient to resolve the infection (Van Huffel et al., 1989; Starke et al., 2006). When bones are infected, surgical debridement of the devitalized or irreparably damaged bone is especially critical (Orsini, 2017). For interphalangeal joint septic arthritis, reported therapeutic options include conservative manage-

ment, digit amputation, facilitated arthrodesis, and fenestration of the wound (Lewis et al., 2009). In this case, we decided that conservative management was inadequate to control the infection owing to extension of deep infection into the bones and/or periarticular soft tissues in the radiographs. In addition, preoperative radiography revealed subchondral bone lysis, suggesting the presence of a chronic bone infection. Chronic osteomyelitis with persistent drainage and sequestrum formation is resistant to eradication by long-term antibiotics alone; therefore, surgical intervention is the only effective method to eliminate such an infection and promote healing (Johnson and Buckley, 2007).

Digit amputation and digit arthrodesis surgery have been performed to successfully treat deep infections to the digits in cattle (Pesja et al., 1993; Desrochers et al., 1995). Digit arthrodesis surgery was superior to digit amputation with regards to longevity and productivity of cattle during the postoperative days (Jean and Desrochers, 2004; Bicalho et al., 2006). Conversely, disadvantages of arthrodesis of the interphalangeal joint in comparison to digit amputation are that it is more expensive, technically demanding,

and requires more postoperative care. Cattle also have a slower return to previous production following arthrodesis owing to the length of the procedure and the pain it causes (St-Jean and Desrochers., 2004). Based on this comparison, we opted for arthrectomy to treat digital joint arthritis of the heifer.

On the 48th postoperative day, the surgical wound seemed to be healing, but the locomotion score remained aggravated. Then, external coaptation with a half-limb cast was applied because disrepair of immature callus at the lateral proximal interphalangeal joint was observed on radiography. Excessive interfragmentary instability will impede cartilage replacement, diminishes angiogenesis, and prevents bone from bridging the fracture gap (Einhorn and Gerstenfeld, 2015). In this case, improvement of the postoperative condition at the surgical site during the first month was likely to allow weight bearing of the left hind limb, resulting in an excessive interfragmentary instability and injury of the immature callus at that joint. Half-limb casts can be used for immobilization of phalangeal fractures (Anderson and Jean 2008) and can provide substantial stability to induce bone union (El-Shafaey et al., 2014). Therefore, a cast with a fenestration on the surgical site should have been applied from the beginning of the postoperative treatment in this heifer. Alternatively, it has been reported that stabilisation of the joint and the removal of the load on it by means of a steel-reinforced synthetic resin is important for the healing process (Starke et al., 2006). Moreover, it has been reported that use of the screw system in cattle is an excellent treatment option for distal interphalangeal joint arthrodesis with minimal postoperative morbidity and excellent return to function (Lewis et al., 2009).

Although the withers height of the present heifer was within the average of that of control heifers on this farm, BW of the heifers at 13 months (322 kg) was still lower than the BW of the control heifers (384 ± 26 kg). However, the BW gain for 2 months (between 11 to 13 months) seemed to be higher in the present heifer (+76 kg) than in control ($+55 \pm 20$ kg), suggesting that BW of the present heifer was returning to the original BW. Satisfactory functioning of the reproductive organs (ovary and uterus) was observed in this heifer; the owner is planning to breed the animal. Based on these observations, we suggested that arthrectomy was an effective treatment option for digital joint arthritis in the present case for better expected recovery of productivity.

In the early infection stage of arthritis, the accuracy of the diagnosis may be reduced because radiographic abnormalities are often difficult to detect (Kofler, 2009). Ultrasound examination can be useful for detecting soft tissue damage around distal limbs (*esp.*, tendinitis and abscess) of cattle (Kofler and Edinger, 1995). Therefore, in this case, it will be possible to diagnose degrees of inflammation and bone infection by combined use of radiographic and ultrasonographic examinations, resulting in the possibility of shortening the duration of postoperative treatments. Furthermore, use of half-limb cast with fenestration or a screw system were likely to shorten the duration of postoperative treatment. Hence, the current case report provides instructive information on the treatment for chronic deep infections of bovine digital joints. Improved strategies for diagnosis and surgical wound management are required for similar cases of digital joint arthritis.

REFERENCES

- Anderson DE, Jean GS (2008) Management of Fractures in Field Settings. *Vet Clin Food Anim* 24:567-582.
- Bicalho RC, Cheong SH, Warnick LD, Nydam DV, Guard CL (2006) The effect of digit amputation or arthrodesis surgery on culling and milk production in holstein dairy cows. *J Dairy Sci* 89:2596-2602.
- Desrochers A (2004) Septic arthritis. In: (Fubini SL, Ducharme NG eds) *Farm Animal Surgery*. Saunders, Philadelphia: pp 330-336.
- Desrochers A, Jean GS, Anderson DE (1995) Use of facilitated ankylosis in the treatment of septic arthritis of the distal interphalangeal joint in cattle: 12 cases (1987-1992). *J Am Vet Med Assoc* 206:1923-1927.
- Desrochers A, Francoz D (2014) Clinical Management of Septic Arthritis in Cattle. *Vet Clin Food Anim* 30:177-203.
- Einhorn TA and Gerstenfeld LC (2015) Fracture healing: mechanisms and interventions. *Nat Rev Rheumatol* 11:45-54.
- El-Shafaey EA, Aoki T, Ishii M, Yamada K (2014) Conservative management with external coaptation technique for treatment of a severely comminuted fracture of the proximal phalanx in a Holstein-Friesian cow. *Iran J Vet Res* 15:300-303.
- Jean GS, Desrochers A (2004) Treatment of Pathological Diseases Foot and Digits. In: (Fubini SL, Ducharme NG eds) *Farm Animal Surgery*. Saunders, Philadelphia: pp 323- 330.
- Johnson EE, Buckley RE (2007) Chronic infection and infected nonunion. In: (Rüedi TP, Buckley RE, Moran CG eds) *AO Principles of Fracture Management*. 2nd ed, AO publishing, New York: pp 543-554.
- Kofler J (2009) Ultrasonography as a diagnostic aid in bovine musculoskeletal disorders. *Vet Clin Food Anim* 25:687-731.
- Kofler J, Edinger HK (1995) Diagnostic ultrasound imaging of soft tissues in the bovine distal limb. *Vet Radiol Ultrasound* 36:246-252.
- Lewis AJ, Sod GA, Gill MS, Mitchell CF (2009) Distal interphalangeal joint arthrodesis in seven cattle using the Acutrak Plus screw. *Vet Surg* 38:659-63.
- Orsini JA (2017) Update on Managing Serious Wound Infections in Horses: Wounds Involving Bone. *J Equine Vet Sci* 55:123-138.
- Pesja TG, Jean GS, Hoffsis GF, Musser JMB (1993) Digit amputation in cattle: 85 cases (1971-1990). *J Am Vet Med Assoc* 202:981-984.
- Re M, Blanco-Murcia J, Villaescusa Fernández A, De Gaspar Simón I, Gómez de Segura IA (2014) Ultrasound-guided anaesthetic blockade of the pelvic limb in calves. *Vet J* 200: 434-439.
- Sprecher DJ, Hostetler DE, Kaneene JB (1997) A lameness scoring system that uses posture and gait to predict dairy cattle reproductive performance. *Theriogenology* 47:1179-87.
- Starke A, Kehler W, Rehage J (2006) Arthrotomy and arthrodesis in the treatment of complicated arthritis of the fetlock joint in adult cattle. *Vet Rec* 159: 772-777.
- Van Huffel X, Steenhaut M, Imschoot J, Verschooten F, Gasthuys F, Desmet P, De Moor A (1989) Carpal joint arthrodesis as a treatment for chronic septic carpalitis in calves and cattle. *Vet Surg* 18:304-11.