


Journal of the Hellenic Veterinary Medical Society

Vol 70, No 3 (2019)



Caudal cruciate ligament avulsion at its origin in a dog

A.A. KRYSTALLI, N.N. PRASSINOS, P. MANTIS

doi: [10.12681/jhvms.21803](https://doi.org/10.12681/jhvms.21803)

Copyright © 2019, A.A. KRYSTALLI, N.N. PRASSINOS, P. MANTIS



This work is licensed under a [Creative Commons Attribution-NonCommercial 4.0](https://creativecommons.org/licenses/by-nc/4.0/).

To cite this article:

KRYSTALLI, A., PRASSINOS, N., & MANTIS, P. (2019). Caudal cruciate ligament avulsion at its origin in a dog. *Journal of the Hellenic Veterinary Medical Society*, 70(3), 1733–1736. <https://doi.org/10.12681/jhvms.21803>

Caudal cruciate ligament avulsion at its origin in a dog

A.A. Krystalli¹, N.N. Prassinos¹, P. Mantis²

¹ School of Veterinary Medicine, Faculty of Health Sciences, Aristotle University, Thessaloniki, Greece

² Dick White Referrals, Station Farm, Six Mile Bottom, Suffolk, CB8 0UH, United Kingdom

Απόσπαση της έκφυσης του οπίσθιου χιαστού συνδέσμου σε σκύλο

A.A. Κρυστάλλη¹, N.N. Πράσιнос¹, Π. Μάντης²

¹ Κλινική Ζώων Συντροφιάς, Τμήμα Κτηνιατρικής, Σχολή Επιστημών Υγείας, Αριστοτέλειο Πανεπιστήμιο Θεσσαλονίκης, Θεσσαλονίκη

² Dick White Referrals, Station Farm, Six Mile Bottom, Suffolk, CB8 0UH, United Kingdom

ABSTRACT. Caudal cruciate ligament (CaCL) rupture is uncommon in dogs and usually occurs with a concurrent rupture of the cranial cruciate ligament (CrCL). A 10-month-old cross-bred dog was presented with left hind limb lameness. Orthopaedic examination revealed positive craniocaudal drawer sign in the left stifle. Arthrotomy confirmed CrCL rupture, and showed CaCL avulsion fracture at its origin. The stifle was stabilized using extracapsular lateral fabellotibial suture. Eight months postoperatively the dog was free of obvious lameness and remained sound until the last re-evaluation (3 years). This case raises the possibility that restoration of the CaCL function is not always essential for animals' successful outcome.

Keywords: Caudal cruciate ligament, cranial cruciate ligament, dog, lameness

Corresponding Author:

Androniki Krystalli, Companion Animal Clinic, School of Veterinary Medicine, 11, Stavrou Voutira str., 54627 Thessaloniki, Greece
E-mail address: andronikikr@yahoo.gr

Αλληλογραφία:

Androniki Krystalli, Companion Animal Clinic, School of Veterinary Medicine, 11, Stavrou Voutira str., 54627 Thessaloniki, Greece
E-mail address: andronikikr@yahoo.gr

Date of initial submission: 06-10-2018

Date of revised submission: 8-11-2018

Date of acceptance: 03-12-2018

ΠΕΡΙΛΗΨΗ. Η ρήξη του οπίσθιου χιαστού συνδέσμου είναι σπάνια στον σκύλο και συνήθως συνυπάρχει με ταυτόχρονη ρήξη του πρόσθιου χιαστού συνδέσμου. Ένας ημίαιμος σκύλος ηλικίας 10 μηνών προσκομίστηκε με χωλότητα του οπίσθιου δεξιού άκρου. Η ορθοπαιδική εξέταση αποκάλυψε θετική προσθιοπίσθια συρταρωτή κίνηση στο δεξίο γόνατο. Η αρθροτομή επιβεβαίωσε τη ρήξη του πρόσθιου χιαστού συνδέσμου και έδειξε και απόσπαση του οπίσθιου χιαστού συνδέσμου στην πρόσφυσή του. Το γόνατο σταθεροποιήθηκε με τη χρήση εξωαρθρικής τεχνικής (νάιλον ράμμα μεταξύ έξω σησαμοειδούς και κνημιαίου κυρτώματος). Οκτώ μήνες μετεγχειρητικά ο σκύλος δεν παρουσίαζε εμφανή χωλότητα και παραμένει έτσι μέχρι και την τελευταία επανεξέταση (3 χρόνια). Το περιστατικό αυτό εγείρει την πιθανότητα ότι η αποκατάσταση της λειτουργίας του οπίσθιου χιαστού συνδέσμου δεν είναι πάντα απαραίτητη για την επιτυχή έκβαση των ζώων.

Λέξεις ευρητηρίασης: Οπίσθιος χιαστός σύνδεσμος, πρόσθιος χιαστός σύνδεσμος, σκύλος, χωλότητα

INTRODUCTION

The caudal cruciate ligament (CaCL) is the primary stabilizer against caudal tibial subluxation. In combination with the cranial cruciate ligament (CrCL), limits internal rotation of the tibia and hyperextension of the stifle (Arnoczky et al., 1977). Isolated rupture of the canine CaCL is very rare and in many cases coexists with rupture of the CrCL and/or medial collateral ligament of the stifle (Kowaleski et al., 2012). A rare case of CaCL avulsion fracture at its origin, which was treated successfully, is presented.

CASE HISTORY

A male, 10-month-old, 30 kg, cross-bred was referred due to sudden onset left hind limb lameness of 1 month duration. There was no history of trauma. Lameness was observed after the dog had run unattended in a grassland. Orthopaedic examination revealed mild to moderate lameness in the left hindlimb with severe pain, medial thickening and craniocaudal drawer movement in the left stifle. Tibial thrust was also present. Moderate joint effusion with reduced visibility of the infrapatellar fat pad was visible radiographically, while the popliteal sesamoid was caudodistally displaced. At least three bone opacities were visible superimposed on the lateral surface of the medial femoral condyle suggestive of possible avulsion fracture of the caudal cruciate ligament. Slight new bone formation was visible on the patellar apex and on the distal aspect of the medial gastrocnemius sesamoid bone is also visible (Figure 1a,b). Diagnosis of left stifle osteoarthritis compatible with CrCL rupture was established, but differential diagnosis included CaCL rupture, too.

Lateral arthrotomy of the affected stifle was performed and initial diagnosis of CrCL rupture was confirmed (Johnson, 2014). Also, CaCL avulsion fracture at its origin and an articular cartilage defect in the

middle of the medial trochlear ridge were observed (Figure 2). The medial meniscus was not intact and partial meniscectomy was performed. An attempt was made to osteosynthesize the avulsed bone fragment, however, it was impossible to be reduced and it was removed. The stifle was stabilized using double extracapsular lateral fabellotibial suture 100 lb and both cranial and caudal drawer movements of the stifle were ceased.

Two months after surgery the lameness of the operated limb was very mild, while after 8 months the gait seemed to be normal on observation. Pain and crepitus were not clinically identified in the stifle. Osteoarthritic lesions were mainly restricted on the intercondyloid eminence and the lateral fabella. Two years postoperatively, the clinical view of the dog was unchanged, while signs of mildly worsened left stifle osteoarthritis were identified radiographically (Figure 3).

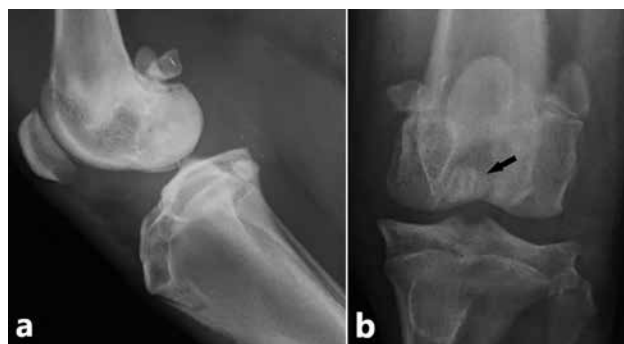

Figure 1. Mediolateral (a) and caudocranial (b) radiographs of the left stifle one month after both CLs rupture. Moderate joint effusion with reduced visibility of the infrapatellar fat pad. The popliteal sesamoid appears caudodistally displaced. At least three bone opacities are visible superimposed on the lateral surface of the medial femoral condyle (arrow) that likely reflect the multiple fragments of an avulsion fracture at the origin of the caudal cruciate ligament in the intercondylar fossa identified surgically. Slight new bone formation is visible on the patellar apex and on the distal aspect of the medial gastrocnemius sesamoid bone is also visible+

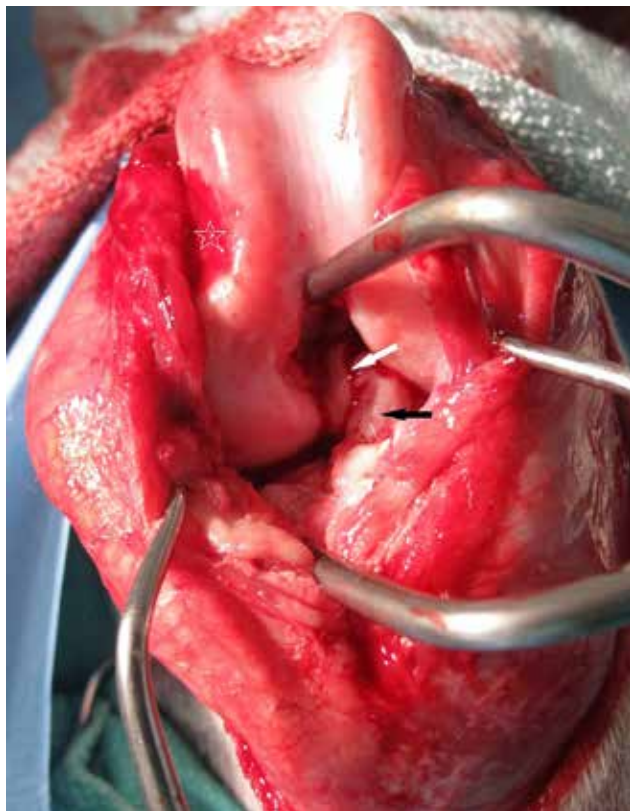


Figure 2. Lateral arthrotomy of the left stifle: Avulsion fracture of the femoral attachment of the CaCL (white arrow), CrCL rupture (black arrow) and articular cartilage defect in the middle of the medial trochlear ridge (white star)

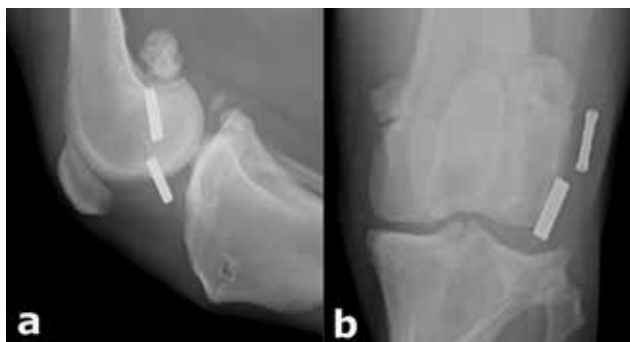

Figure 3. Mediolateral (a) and caudocranial (b) radiographic views of the left stifle taken 2 years after extracapsular stabilization. There is mild increased new bone formation, most notably on the intercondyloid eminence and the lateral gastrocnemius sesamoid bone. Small osseous opacities are superimposed medially and caudally on the joint. The lucent area visible in the tibial tuberosity seen on the lateral view represents a hole drilled to pass the suture material in connection with the extracapsular stabilization procedure. Crimps are noted on the lateral aspect of the stifle. Moderate joint effusion is still visible, mildly less than preoperatively. Mild thickening of the patellar ligament is also visible

DISCUSSION

Avulsion fracture of the attachments of the CaCL is uncommon. Indeed, few cases of CaCL fracture at its insertion (Wong 1994; Soderstrom et al., 1998), and only one at its origin (Monotti et al., 2015) have

been published. Our case was treated successfully using extracapsular lateral fabellotibial suture only for the management of CrCL instability.

The cause of CaCL rupture is usually traumatic (Fossum et al., 2013). Although, in this case, the owner was not aware of any accident, perhaps the defect in the femoral trochlear ridge is the evidence of a violent percussion.

Differentiation of caudal from cranial drawer movement of the stifle is difficult. In a retrospective study of 14 dogs of single CaCL rupture, half of the cases were misdiagnosed as having CrCL rupture, and also in 9/14 dogs with CaCL rupture, this was not included in the differential diagnoses list (Johnson and Olmstead 1987). Accurate diagnosis of CaCL avulsion fracture requires a high index of suspicion for this disorder; in addition, an understanding of the neutral position of the tibia and of the direction of displacement is necessary for correct diagnosis of caudal drawer (Kowaleski et al., 2012). In this animal, orthopaedic examination revealed only the CrCL rupture, while the CaCL one was suspected radiographically and confirmed with arthrotomy.

Radiographs are important in CaCL injuries because of their frequent association with other traumatic injuries and because of a higher percentage of avulsion injuries than with the CrCL. This probably results from the CaCL being larger and stronger than the CrCL and therefore resisting rupture but predisposing to avulsion (DeCamp et al., 2016). Computer tomography (CT) scan best demonstrated the CaCL avulsion fracture at its origin in a dog, while radiography and magnetic resonance imaging failed (Monotti et al., 2015). Unfortunately, in our case, CT was not performed due to financial constraints.

Stifles with CaCL injury could be treated with resection of the remnants of the ligament and stabilization by one of several extracapsular reconstruction techniques, e.g. suture stabilization, redirection of the medial collateral ligament, or popliteal tendon tenodesis (Fossum et al., 2013). Also, in case of avulsion fracture of the attachments of the CaCL various techniques have been proposed (DeCamp et al., 2016).

However, there must be some doubt about the necessity of stabilizing the stifle following CaCL injury, based on experimental transection in seven dogs. In a study, six months after transection and partial excision of the ligament, none of the dogs was lame al-

though there was still a positive caudal drawer movement present. It is interesting that none of the dogs developed osteoarthritis (Harari et al., 1987). Indeed, surgical stabilization of an isolated rupture of the CaCL is only suggested in working and sporting dogs or when it occurs with another ligamentous injury of the stifle (DeCamp et al., 2016). Monotti et al (2015) treated their case conservatively, due to minimally displaced avulsion, with strict rest and a non-steroid anti-inflammatory drug. Although their follow-up is short, the dog regained excellent use of the limb after 6 weeks (Monotti et al., 2015). In our case, the attempt to reduce the avulsed femoral attachment of the CaCL was failed due to the ligament contraction, which related to the chronicity. The use of extracapsular lateral fabellotibial suture to restore CrCL function stabilized the stifle enough to cease the craniocaudal drawer movement. So, additional stabilization for the

CaCL rupture did not use. It is interesting that the dog seemed to be lameness free on re-examinations, even 3 years postoperatively, although osteoarthritis was worsened radiographically. This assessment was made during observation, which is a subjective method of estimating the movement of the animal, but if the equipment for gait analysis was available, mild disturbances could be detected. At any rate, it is well known that osteoarthritic clinical findings do not always correspond with radiographic ones.

In conclusion, rupture of the CaCL, with or without concurrent CrCL one, is difficult to diagnose clinically. Based on the clinical outcome from our study, restoration of the CaCL function is not always essential for animals' successful outcome.

CONFLICT OF INTEREST

The authors declare no conflict of interest.

REFERENCES

- Arnoczky SP, Torzilli PA, Marshall JL (1977) Biomechanical evaluation of anterior cruciate ligament repair in the dog: an analysis of the instant center of motion. *J Am Anim Hosp Assoc* 13: 553-558.
- DeCamp CE, Johnston SA, Dejardin LM, et al. (2016) The stifle joint. In: *Handbook of Small Animal Orthopedics and Fracture Repair*. 5th ed, Elsevier, St. Louis: pp 597-669.
- Fossum TW, Dewey CD, Horn CV, et al. (2013) Diseases of the joints. In: *Small Animal Surgery*. 4th ed, Elsevier Mosby, St. Louis: pp 1215-1374.
- Harari J, Johnson AL, Stein LE, et al. (1987) Evaluation of experimental transection and partial excision of the caudal cruciate ligament in dogs. *Vet Surgery* 16: 151-154.
- Johnson AL, Olmstead ML (1987) Caudal cruciate ligament rupture: a retrospective analysis of 14 dogs. *Vet Surg* 16: 202-206.
- Johnson KA (2014) Approach to the stifle joint through a lateral incision. In: *Piermattei's atlas of surgical approaches to the bones and joints of the dog and cat*. 5th ed, Elsevier Saunders, St Louis: pp 392-395.
- Kowaleski MP, Boudrieau RJ, Pozzi A (2012) Stifle joint. In: Tobias KM, Johnston SA, editors: *Veterinary Surgery - Small Animal*. Elsevier Saunders, St. Louis: pp 906-998.
- Monotti IC, Davies SE, Lidbetter DA (2015) What is your diagnosis? *JAVMA* 246: 507-509.
- Soderstrom MJ, Rochat MC, Drost T (1998) Radiographic diagnosis: Avulsion fracture of the caudal cruciate ligament. *Vet Radiol Ultrasound* 39: 536-538.
- Wong WT (1994) Caudal cruciate ligament avulsion fracture in a dog. *Austr Vet J* 71: 82-83.