

Journal of the Hellenic Veterinary Medical Society

Vol 35, No 1 (1984)

ΕΛΛΗΝΙΚΗ ΚΤΗΝΙΑΤΡΙΚΗ ΕΤΑΙΡΕΙΑ
Επιστημονικό Σωματείο Αναγνωρισμέ-
νο, Απόφ. Πρωτ. Αθηνών 1021/83
Διοικητικό Συμβούλιο:
Πρόεδρος: Σπ. Κ. Κυριάκης
Αντιδρος: Λουκ. Ευσταθίου
Γ. Γραμ.: Θεοδ. Ανανιάδης
Ειδ. Γραμ.: Ευαγ. Σίμιος
Ταμίας: Αγγ. Παπαδόπουλος
Μέλη: Απ. Ράντσιος
Αλ. Καρδούλης

ΕΚΔΟΤΗΣ: Λουκάς Ευσταθίου
Ζαλοκώστα 30, Χαλάνδρι
Τηλ.: 6823459

ΣΥΝΤΑΚΤΙΚΗ ΕΠΙΤΡΟΠΗ:
Πρόεδρος: Αριστ. Σειμένης
Μέλη: Χρ. Παππούς
Γιαν. Δημητριάδης
Στεφ. Κολάγγης
Ειρ. Οικονομίδου

ΦΩΤΟΣΤΟΙΧΕΙΟΘΕΣΙΑ
ΕΠΙΜΕΛΕΙΑ ΕΚΔΟΣΗΣ:
Σ. Μπέλλου, Ελ. Βενιζέλου 98,
Χολαργός, Τηλ.: 6529604

Ημερομηνία έκδοσης: ΜΑΪΟΣ

TAX. ΔΙΕΥΘΥΝΣΗ:
Ταχ. Θυρίδα 3546
10210 Αθήνα

Συνδρομές για Ελλάδα και Κύπρο:

Ετήσια μελών	δρχ. 1.000
Ετήσια μη μελών	» 1500
Ετήσια φοιτητών	» 500
Ετήσια Υπηρεσ., Οργαν. ΑΕΙ	» 1500
Τιμή κάθε τεύχους	» 500



ΔΕΛΤΙΟΝ
ΤΗΣ ΕΛΛΗΝΙΚΗΣ
ΚΤΗΝΙΑΤΡΙΚΗΣ ΕΤΑΙΡΕΙΑΣ

ΤΡΙΜΗΝΙΑΙΑ ΕΚΔΟΣΗ
ΠΕΡΙΟΔΟΣ Β
ΤΟΜΟΣ 35
ΤΕΥΧΟΣ 1

ΙΑΝΟΥΑΡΙΟΣ - ΜΑΡΤΙΟΣ
1984

Bulletin
OF THE HELLENIC
VETERINARY MEDICAL SOCIETY

QUARTERLY
SECOND PERIOD
VOLUME 35
No 1

JANUARY - MARCH
1984

Επιταγές και εμβάσματα αποστέλλονται επ' ονό-
ματι κ. Αγγ. Παπαδόπουλου Κτην. Ινστ. Υγιεινής και
Τεχνολογίας Τροφίμων, Ιερά οδός 75, 118 55 Αθή-
να. Μελέτες, επιστολές κ.λπ. αποστέλλονται στον κ.
Α. Ευσταθίου, Κτηνιατρικό Ινστιτούτο Φυσιοπαθο-
λογίας, Αναπαραγωγής και Διατροφής Ζώων, Νεα-
πόλεως 9-25, Αγία Παρασκευή Αττικής.

A rare case of multiple congenital malformations in a piglet

J. Menegatos, E. Stoforos, S. Deligiorgis, E. Xylouri

doi: [10.12681/jhvms.21626](https://doi.org/10.12681/jhvms.21626)

Copyright © 2019, J. Menegatos, E. Stoforos, S. Deligiorgis, E. Xylouri



This work is licensed under a [Creative Commons Attribution-NonCommercial 4.0](https://creativecommons.org/licenses/by-nc/4.0/).

To cite this article:

Menegatos, J., Stoforos, E., Deligiorgis, S., & Xylouri, E. (2019). A rare case of multiple congenital malformations in a piglet. *Journal of the Hellenic Veterinary Medical Society*, 35(1), 12–18. <https://doi.org/10.12681/jhvms.21626>

ΣΠΑΝΙΑ ΠΕΡΙΠΤΩΣΗ ΠΟΛΛΑΠΛΗΣ ΣΥΓΓΕΝΟΥΣ ΔΙΑΜΑΡΤΙΑΣ ΣΕ ΧΟΙΡΙΔΙΟ

I. ΜΕΝΕΓΑΤΟΣ*, Ε. ΣΤΟΦΟΡΟΣ*, Δ. ΔΕΛΗΓΙΩΡΓΗΣ*, Ε. ΞΥΛΟΥΡΗ*

A RARE CASE OF MULTIPLE CONGENITAL MALFORMATIONS IN A PIGLET

J. MENEGATOS*, E. STOFOROS*, S. DELIGIORGIS*, E. XYLOURI*

Summary

It is described a case of multiple congenital malformations in a Landrace male piglet which lived for 50 days. It showed brachygnathia superior, arthrogryposis of hind limbs, malformations of the lumbar vertebrae and the sacrum, aplasia of the left ilium and of the muscles of the left thigh and femur. Also all the bones of the left hind limb were shorter than the right ones. Malformations of the sternum and the ribs were present. The left ribs were shorter than the right ones. The left lung, kidney and testicle were much shorter than the right ones. The causative agent was unknown.

Περίληψη

Περιγράφεται η περίπτωση ενός αρσενικού χοιριδίου φυλής Landrace που παρουσίασε συγγενή πολλαπλή διαμαρτία διάπλασης.

Οι συγγενείς διαμαρτίες διάπλασης περιγράφονται πιο συχνά στο χοίρο από τα άλλα κατοικίδια ζώα.

Το χοιρίδιο γεννήθηκε από μια χοιρομητέρα ηλικίας 17 μηνών, μαζί με άλλα 5 χοιρίδια. Στη χοιρομητέρα κατά τη διάρκεια της εγκυμοσύνης δεν είχε δοθεί κανένα φάρμακο ή ορμόνη. Η διατροφή της επίσης ήταν ισορροπημένη.

Κλινικά το χοιρίδιο παρουσίαζε αρθρογρύπωση των οπισθίων άκρων. Οι μύες του αριστερού οπίσθιου άκρου ήταν ατροφικοί. Παρουσίαζε επίσης βραχυγναθία άνω γνάθου. Σταδιακά άρχισε να μειώνεται η όρεξη και να καθυστερεί η ανάπτυξη του μέχρι της ηλικίας των 50 ημερών που ψόφησε.

Παρουσίαζε έλκη κατάκλισης στο πρόσωπο και στον αριστερό καρπό, ενώ η ουρά είχε νεκρωθεί.

Σε ακτινογραφία των οπισθίων

* Ανωτάτη Γεωπονική Σχολή Αθηνών, Εργαστήριο Ανατομίας και Φυσιολογίας Αγροτικών Ζώων. Ιερά Οδός 75, Αθήνα (301).

Agricultural College of Athens, (Laboratory of Anatomy and Physiology of Farm Animals), Department of Animal Production. 75, Iera Odos, Athens (301).

άκρων παρατηρήθηκε απλασία του αριστερού λαγονίου ενώ το αριστερό ισχιακό και το ηβικό ήταν πολύ μικρότερα από του δεξιού ημιμορίου. Επίσης το αριστερό μηριαίο και η κνήμη ήταν μικρότερα από τα αντίστοιχα δεξιά.

Στη νέκρωση τα εσωτερικά μονοφυή όργανα ήταν φυσιολογικά ενώ τα διφυή ήταν ανισομεγέθη.

Οι θηλές αριστερά ήταν 7 και δεξιά 9. Τα ευρήματα από το σκελετό ήταν: Στο κεφάλι παρατηρήθηκε μόνο βραχυγναθία άνω γνάθου. Οι αυχενικοί σπόνδυλοι ήταν 7, οι θωρακικοί 16. Ο 11ος θωρακικός είχε δύο εγκάρσια τρήματα αριστερά. Ο 16ος θωρακικός δεν είχε εγκάρσιο τρήμα δεξιά. Οι οσφυϊκοί ήταν 6. Οι αριστερές εγκάρσιες αποφύσεις ήταν μικρότερες από τις δεξιές.

Ο 5ος και 6ος οσφυϊκός δεν είχαν εγκάρσιες αποφύσεις.

Το Ιερό οστού αποτελείτο από 4 σπονδύλους. Οι κοκκυγικοί ήταν μόνο 6 γιατί οι υπόλοιποι είχαν νεκρωθεί. Το στέρνο αποτελείτο από 10 τμήματα. Οι πλευρές ήταν 8 ζεύγη αληθείς και 8 ζεύγη ψευδείς. Οι αριστερές πλευρές ήταν κοντότερες από τις δεξιές. Όλα τα οστά του αριστερού οπισθίου άκρου ήταν μικρότερα από του δεξιού.

Ο βαθμός αρθρογρύπωσης του αριστερού οπισθίου άκρου ήταν μεγαλύτερος από του δεξιού άκρου.

Τα δεδομένα μας δεν είναι αρκετά για να διερευνηθεί αν το αίτιο που προκάλεσε αυτή την πολλαπλή δυσπλασία είναι κληρονομικό ή αποτέλεσμα περιβαλλοντικών παραγόντων.

Introduction

Congenital malformations are reported more frequently in swine than in other domestic animals (Neal et al., 1970). The frequency of malformations was found to vary

from 0.48 to 1.37 per cent of pigs born (Anonymus, 1959; Nielsen and Bendixen, 1969; Selby et al., 1971; Nielsen et al., 1974., and Bille and Nielsen, 1977).

Case history

An abnormal male Landrace piglet was born in December 1979 with four normal females and another normal male. Its mother, a Landrace sow 17 months old, had a previous litter size (last July) of 8 normal piglets, two males and six females. During last pregnancy the sow had not treated with any drugs or hormones. The sow lived in a close piggery and its feed consisted of cereals, soyabeanmeal, fishmeal, minerals and vitamins. The ration did not contain medicines. It had never been fed by grass.

The abnormal piglet was examined clinically. It showed arthrogryposis of the hind limbs, the left one was much more contracted than the right one. The muscles of the left hip, thigh and leg were aplastic. Also there was brachygnaathia superior. Its growth was not retarded and its appetite was good. However as the time was passing its growth was retarded in comparison with other piglets of the same litter size, especially after weaning. The piglet died when it was 50 days old. There were decubital ulcers on the skin of the face and on the carpus while the tail had been necrotized. We examined the hind limbs radiologically and we found aplasia of the left ilium while the left ischium and pubic were much smaller than the right ones. Also the left femur and tibia were smaller than the right ones. In necropsy the internal impaired organs were normal but the paired ones were dissimilar in size (Table 1). The left testicle was in sublumbar region and the right was abnormally enlarged Vd (Fig.1). The teats on the left side were 7 in number while

on the right side were 9.

Skeleton findings

On the head no other malformation occurred except brachygnathia superior. The cervical vertebrae were 7 in number and normal. The thoracic vertebrae were 16. The 11th thoracic vertebra had two transverse foramen on the right. The lumbar vertebrae were 6 in number. The left transverse processes were much smaller than the right ones. The 5th and 6th lumbar vertebrae had no left transverse process. The sacrum consisted of four vertebrae and it was twisted from left to right. The right wing was well developed but the left one was aplastic. The caudal vertebrae were only 6, because the rest of the tail had been necrotized and fallen. The sternum consisted of ten segments, six of which were in pairs and irregular in shape. The ribs were 16 pairs of which 8 true and 8 false. The left ribs were shorter than the right ones (Table 2). The costal cartilages of the left ribs were also shorter than the right ones. The free ends of the 11th and 12th costal cartilages were double. The bones of the thoracic limbs scapula, humerus, radius and ulna has significant differences (Table 3). The left ilium was aplastic and the other bones of the left os coxae were much smaller than the right ones.

The left femur had not the greater trochanter and was smaller than the right. Also the left tibia, fibula, calcaneus and talus were significant smaller than the right ones. There was arthrogryposis of the rear legs. The contracture of the left hind limb was much severe than the right one.

Discussion

The distribution of congenital abnormalities in pigs has been reported to be 60.5%

Table 1. The weights of paired internal organs in gr.

Organ	Left	Right
Lung	19.8	30.4
Kidney	0.7	29.6
Testicle	1.1	53.4

Table 2. The length of ribs in mm.

Rib	Length in mm	
	Left	Right
I	35	—*
II	45	61
III	59	72
IV	73	82
V	83	94
VI	95	98
VII	97	102
VIII	99	105
IX	95	104
X	93	102
XI	92	94
XII	91	92
XIII	77	86
XIV	65	68
XV	59	64
XVI	10	32

* The first right rib was broken.

nervous system, 15.0% alimentary tract, 11.0% bone, muscle and skin, 8.5% circulatory system, 1.1% genitalia, 3.9% not classified (Anon., 1960); alimentary and respiratory system 27.3%, bones and joints 23.0%, central nervous system 16.7%, special sense organs 11.5%, other unspecified defects 9.0%, abdominal cavity 5%, and genitourinary system 5% (Selby et al., 1971); digestive system 25.9%, abdominal cavity 6.8%, face, oral and nasal area 6.1%, urogenital system 1.7% and skin 0.2% (Bille and Nielsen, 1977).

In our case there were malformations of the skeleton and the internal organs. Skeletal anomalies principally of the axial skeleton occurred with a frequency of 0.28% in a population of 10,683 pigs produced over an 8-year period (Fredeen and Jarmoluk, 1963). Bille and Nielsen (1977) found that malformations of locomotor system occurred by a frequency of 0.32% in a population of 29,886 pigs. The most fre-

quently occurring anomaly have been found to be the contracture of the hind limbs which comprised more than half of the skeletal malformations. In half of them the anomaly was observed to be combined with malformation of the lumbar vertebrae (Bille and Nielsen, 1977). This was like our case. This condition has been described as hereditary in Danish Landrace (Ludvigsen et al., 1963). Basse and Jonsson (1965) have

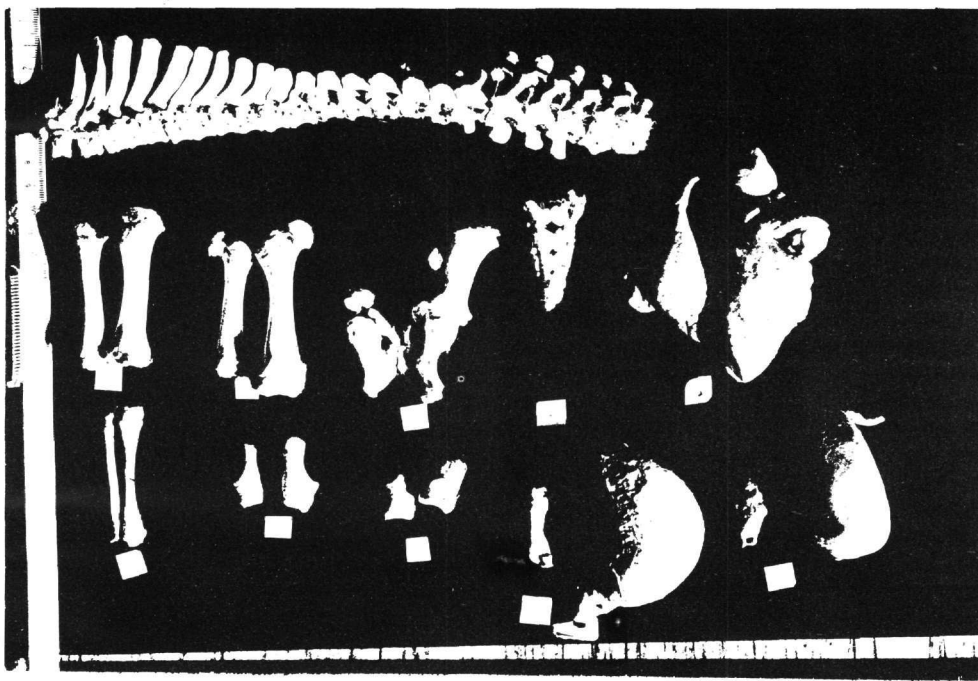


Fig. 1. – Top: Thoracic and lumbar vertebrae.

Middle: From left to right: tibia left and right, femur left and right, bony pelvis, sacrum and lungs.

Bottom: From left to right: fibula left and right, calcaneus left and right, talus left and right, testicle left and right, kidney left and right.

Εικ. 1. – Επάνω: Θωρακικοί και οσφυϊκοί σπόνδυλοι.

Κέντρο: Από αριστερά προς τα δεξιά: κνήμη αριστερή και δεξιά, μηριαίο αριστερό και δεξιό, οστά πυέλου, ιερό και πνεύμονες.

Κάτω: Από αριστερά προς τα δεξιά: περόνη αριστερή και δεξιά, πτέρνα αριστερή και δεξιά, αστράγαλος αριστερός και δεξιός, όρχις αριστερός και δεξιός, νεφρός αριστερός και δεξιός.

revealed a simple rescessive inheritance. Ely and Leipold (1979) described hereditary arthrogryposis in purebred Yorkshire piglets caused by homozygosity of a simple autosomal recessive gene. The primary lesion in their study appeared to be multiple random formation of dystrophic axons (neuroaxonal dystrophy) in white matter of the central nervous system, and in peripheral nervous system tissue. In our case there were malformations of the left os coxae and all the other bones of the left limbs were smaller than the right ones. We believe that the aplasia of the muscles of the thigh and femur, had not any relation with Assymmetric hindquarter syndrome (AHQS) reported by Done and Wijeratne (1972) and Done et al., (1975), because AHQS is less severe and it has been observed in older pigs.

The thoracic vertebrae were 16 in number and little damaged. This number is normal according to Fredeen and Newman (1962), who found 13.5.-17 thoracic vertebrae and 20-30 thoracic and lumbar

ones. This last number in our case was 22. Arhrogryposis is caused from teratogenic effect of methallibure (Barker, 1970; King, 1969; Yente et al., 1972; Wrathall, 1973) of **Conium maculatum** (Dyson and Wrathall, 1977; Edmonds et al., 1972) and of **Nicotiana tabacum** (Crowe, 1969; Crowe, 1973; Leipold et al., 1973; Crowe and Swerczek, 1974). But in our case piglet's mother had never been provided by any hormones or teratogenic substances.

Lungs, smaller than normal, unilateral or bilateral have been reported in relation to maternal lack of vitamin A (Goodwin, 1958). Multiple defects of internal organs as retarded growth of the kidneys, large lungs and testicles have been reported as result of material intake of methallibure (Vente et al., 1972; Wrathall, 1973).

Out data are not enough to detect the causative agent either this case was hereditary or a result of some environmental disorders.

Table 3. Weight of bones of limbs in gr.

Bone	Weight in gr	
	Left	Right
Scapula	10,8	11.0
Humerus	19.0	20.3
Radius and Ulna	14.0	14.3
Ilium	0.8	4.0
Pubis	0.5	0.8
Ischium	2.0	3.1
Femur	10.2	21.7
Tibia	5.8	12.0
Fibula	0.7	1.6
Calcaneus	1.5	2.4
Talus	1.8	3.6

References

- Anonymus (1959). A survey of the incidence and causes of mortality in pigs. *Vet. Rec.* 71:771-786.
- Anonymus (1960). Les malformations congenitales chez les animaux. *Inform. Vet.* 2:5, ref. by Neal et al., (1970) Malformations. In: Dunne, H.W. (ed), «Diseases of swine» 3rd ed., The Iowa State Un. Press. pp. 942-955.
- Barker, C.A.V. (1970). Anti-gestation and teratogenic effects of AIMAX (methallibure) in gilts. *Can. Vet. J.* 11:39-40. *The Vet. Bull.* 1970 40(8):661, §4131.
- Basse, A. and P. Jonsson (1965). Congenital lameness of the hindquarters of pigs. *Landok. Forsogslab. Abrog.* pp. 133-135. by Bille and Nielsen (1977).
- Bille, N. and Nielsen, N.C. (1977). Congenital malformations in pigs in a post mortem material. *Nord. Vet. Med.* 29(3): 128-136.
- Crowe, M.W. (1969). Skeletal anomalies in pigs associated with tobacco. *Mod. Vet. Pract.* 50(12):54-55.
- Crowe, M.W. and H.T. Pike (1973). Congenital arthrogyrosis associated with ingestion of tobacco stalks by pregnant sows. *J. Am. Vet. Med. Ass.* 162:453-455.
- Crowe, M.W. and T.W. Swerczek (1974). Congenital arthrogyrosis in offspring of sows fed tobacco (**Nicotiana tabacum**). *Am. J. Vet. Res.* 35:1071-1073.
- Done, J.T., W.A. Allen, J. Bailley, P.H. De Gruchy and M.K. Curran (1975). Asymetric hindquarter syndrome (AHQS) in the pig. *Vet. Rec.* 96(22):482-488.
- Done, J.T. and W.V. Wijeratne (1972). Genetic diseases in pigs in «Pig Production». Edit. by D. J.A. Cole. Butterworths.
- Dyson, D.A. and A.E. Wrathall (1977). Congenital deformities in pigs possibly associated with exposure to hemlock (**Coinium maculatum**) *Vet. Rec.* 100(12):241-246.
- Edmonds, L.D., L.A. Selby and A.A. Case (1972). Poisoning and congenital malformations associated with consumption of poison hemlock by sows. *J. Am. Vet. Ass.* 160:1319-1324.
- Ely, R.H.W. Leipold (1979). Arthrogyrosis in Yorkshire piglets. *Z. Tierzüchtg Züchtgsbiol.* 96:241-252.
- Fredeen, H.T. and L. Jarmoluk (1963). Skeletal anomalies in swine. *Canad. J. Anim. Sci.* 43:143-149. *An. Breed. Abst.* 31(4):502, §3025.
- Fredeen, H.T. and J.A. Newman (1962). Rid and cerebral numbers in swine. *Canad. J. Anim. Sci.* 42:232-239, 240-251. *An. Breed. Abst.* 31(2):234, §1360.
- Goodwin, R.F.W. and A.R. Jennings (1958). Mortality of newborn pigs associated with a maternal deficiency of vitamin A. *J. Com. Path.* 68:82-95.
- King, G.J. (1969). Deformities in piglets following administration of methallibure during specific stages of gestation. *J. Peprod. Fert.* 20:551-553.
- Leipold, H.W., W.F. Oehme and J.E. Cook (1973). Congenital arthrogyrosis associated with ingestion of Jimsonweed by pregnant sows. *J. Am. Vet. Med. Ass.* 162:1059-1060.
- Ludvigsen J., A. Basse, Hj. Clausen and P. Jonsson (1963). Congenital lameness of the hindquarters of pigs. *Landok. Forsogslab. Arbog.* pp. 414-416. Report. by Bille and Nielsen (197).
- Neal, F.C., F.K. Ramsey and K.S. Preston (1970). Malformations. In: Dunne, H.W. (ed.), «Diseases of swine», 3rd ed., The Iowa State University Press. U.S.A. pp. 942-955.
- Nielsen, H.E. and H.J. Bendixen (1969). Foetal death in pigs. *Landok. Forsogslab. Arbog.* p.p. 23-32.
- Nielsen, N.C., K. Christensen, N. Bille and J.L. Larsen (1974). Prewaning mortality in pigs. *Nord. Vet. Med.* 26:137-150.

Selby, L.A., H.C. Hopps and L.D. Endmonds (1971). Comparative aspects of conjoined malformations in man and swine. *J. Am. Vet. Med. Ass.* 159:1485-1490.

Selby, L.A., C.J. Marienfield, W. Heidlage, H.T. Wright and V.E. Young (1971b). Evaluation of a method to estimate the prevalence of congenital malformations in swine, using a mailed questionnaire. *Cornell Vet.* 61:203-213.

Vente, J.P., A.E. Wrathall, J.T. Done

(1971). Teratogenic effects of methallibure in the pig. *Teratology* 4:502-503. *The Vet. Bull.* 42(9):5557.

Vente, P.J., A.E. Wrathall and N. Herbert (1972). Quantitative anatomical study of methallibure induced malformations in piglets. *Res. Veter. Science.* 13(2): 169-179. *The Vet. Bull.* 42(8):553, §4880.

Wrathall, A.E. (1973). Methallibure induced congenital abnormalities in the pig. *Vet. Rec.* 92:15-16.