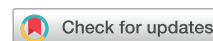

# Brief Report: Heterogeneity of Acquired Resistance Mechanisms to Osimertinib and Savolitinib



Sun Min Lim, MD, PhD,<sup>a</sup> San-Duk Yang, PhD,<sup>b</sup> Sangbin Lim, PhD,<sup>b</sup>  
Hyo Sup Shim, MD, PhD,<sup>c</sup> Byoung Chul Cho, MD, PhD<sup>a,\*</sup>

<sup>a</sup>Division of Medical Oncology, Department of Internal Medicine, Yonsei Cancer Center, Yonsei University College of Medicine, Seoul, Republic of Korea

<sup>b</sup>Yonsei Cancer Research Institute, Yonsei University College of Medicine, Seoul, Republic of Korea

<sup>c</sup>Department of Pathology, Yonsei University College of Medicine, Seoul, Republic of Korea

Received 21 April 2021; accepted 22 April 2021

Available online - 30 April 2021

## ABSTRACT

**Introduction:** *MET* amplification is a frequently observed mechanism of resistance to osimertinib, and coinhibition strategy of *MET* and *EGFR* revealed promising results in recent clinical trials. Nevertheless, acquired resistance mechanisms to combined *EGFR* and *MET* inhibition are poorly understood. In this study, we investigated the mechanisms of acquired resistance to osimertinib and savolitinib by using pretreatment and post-treatment tissue analysis.

**Methods:** Whole-exome sequencing was performed in *EGFR*-mutant, *MET*-amplified patients who received osimertinib and savolitinib using tissues obtained both before and after therapy. All patients achieved partial response or durable stable disease to osimertinib and savolitinib before developing acquired resistance.

**Results:** After progression on osimertinib and savolitinib, whole-exome analysis revealed *MET*-dependent mechanisms of resistance, such as acquired *MET* p.D1246H mutation, *MET* p.Y1230C mutation, and *MET* copy number gain. As for *MET*-independent mechanisms, development of *ERBB2* mutation and amplification and copy number gains in amplifications in *CCNE*, *CCND1*, *CDK6*, and *EGFR* were observed. Patient 2 harbored an acquired *PIK3CA* p.H1047R mutation in which resistance could be overcome with combination of PI3K inhibitor and osimertinib in the patient-derived xenograft model.

**Conclusions:** Our study reveals that acquired resistance to savolitinib plus osimertinib can occur from both *MET*-dependent and *MET*-independent mechanisms.

© 2021 The Authors. Published by Elsevier Inc. on behalf of the International Association for the Study of Lung Cancer. This is an open access article under the CC BY-NC-ND license (<http://creativecommons.org/licenses/by-nc-nd/4.0/>).

**Keywords:** *MET*; Osimertinib; Resistance; Savolitinib

## Introduction

*EGFR* tyrosine kinase inhibitors (TKIs) are the standard first-line treatment for patients with locally advanced or metastatic *EGFR*-mutant NSCLC.<sup>1</sup> Nevertheless, patients ultimately develop resistance to *EGFR* TKIs through heterogeneous mechanisms, and *MET* amplification is a common bypass track activation, occurring in up to 10% to 25% of patients with *EGFR* TKI-resistant NSCLC.<sup>2-4</sup> Preclinical data suggest that *EGFR* TKI plus *MET* TKI is a possible treatment option for *EGFR* mutation-positive lung cancers with *MET*-driven acquired resistance. Recently, a phase 1 safety data of savolitinib (also known as AZD6094, HMPL-504,

\*Corresponding author.

**Disclosure:** The authors declare no conflict of interest.

Drs. Lim and Yang contributed equally to this work.

This work was supported by Basic Science Research Program through the NRF funded by the Ministry of Science and ICT (2016R1A2B3016282) to CBC, a faculty research grant of Yonsei University College of Medicine (6-2020-0132) to SML, and 7th AstraZeneca-KHIDI (Korea health industry development institute) oncology research program to SML.

Address for correspondence: Byoung Chul Cho, MD, PhD, Division of Medical Oncology, Department of Internal Medicine, Yonsei Cancer Center, Yonsei University College of Medicine, Seoul, Republic of Korea. E-mail: [cbc1971@yuhs.ac](mailto:cbc1971@yuhs.ac)

Cite this article as: Lim SM, et al. Brief Report: Heterogeneity of Acquired Resistance Mechanisms to Osimertinib and Savolitinib. *JTO Clin Res Rep* 2021;2:100180

© 2021 The Authors. Published by Elsevier Inc. on behalf of the International Association for the Study of Lung Cancer. This is an open access article under the CC BY-NC-ND license (<http://creativecommons.org/licenses/by-nc-nd/4.0/>).

ISSN: 2666-3643

<https://doi.org/10.1016/j.jtccr.2021.100180>

and volitinib), a potent, selective MET TKI, plus osimertinib have been reported from the global expansion cohorts of the TATTON study.<sup>5</sup> These results suggested the potential of osimertinib and savolitinib as a new therapeutic option for patients with *EGFR*-mutant NSCLC with acquired *MET* amplification. The SAVANNAH study (NCT03778229) is further ongoing to evaluate the combination of osimertinib and savolitinib in patients with *MET*-driven resistance to osimertinib. Nevertheless, osimertinib and savolitinib treatment also faces acquired resistance with the median progression-free survival of 5.4 months, but studies on the mechanisms of acquired resistance have been scarce.<sup>6</sup>

In this study, we report comprehensive analyses of acquired resistance in patients who progressed on combination of osimertinib and savolitinib. These patients received the combination of osimertinib and savolitinib in the global expansion cohorts of the TATTON study.<sup>5</sup>

## Materials and Methods

### Patients

We report three consecutive patients with *EGFR*-mutant NSCLC who were treated with osimertinib and savolitinib and achieved tumor shrinkage followed by disease progression. The clinical characteristics of the patients are summarized in [Supplementary Table 1](#). The study was done in accordance with the Declaration of Helsinki Good Clinical Practice guidelines, and all patients provided written, informed consent before participating in this study.

### Whole-exome sequencing and analysis

Patient samples were captured using the SureSelect Human All Exon V6 (5190-8881, Agilent Technologies, Santa Clara, CA). Sequencing libraries were constructed for the NovaSeq 6000 system (Illumina, San Diego, CA) and sequenced using the 110-base pair paired-end mode of the NovaSeq 6000 Reagent Kit (20039236, Illumina). Exome sequencing reads were aligned to the hg38 reference genome using BWA-0.7.17. Putative duplications were marked by Picard (version picard-tools-2.18.2-SNAPSHOT). Sites harboring small insertions or deletions were realigned and recalibrated using GATK (v4.0.5.1) modules with known variant sites identified from the 1000 Genomes Project and dbSNP-151. GATK4 Mutect2 was used to call somatic mutations. The coverage for whole-exome sequencing (WES) was  $\times 150$ . To identify copy number (CN) variant (CNV) alterations, CNVkit was used to call CNV gain or loss for each gene from WES data in patient samples. All variants with minor allele frequency (MAF) greater than 0.01 in gnomAD were filtered. Visualization of CNV was performed using R4.0.2 and IGV2.8.13. To investigate pathogenic

variants, we performed SIFT and Polymorphism Phenotyping-2 in silico predictions for functional effect of protein-coding mutations. The following cutoff values were used: SIFT (deleterious: sift score  $\leq 0.05$ ) and Polymorphism Phenotyping-2 (probably damaging [D]: HumDiv score  $\geq 0.957$ ).

### *MET* in situ hybridization

*MET* amplification was confirmed by *MET* in situ hybridization (SISH) method by an expert pathologist (HSS). *MET* gene CN greater than or equal to 5 or *MET*-to-CEP7 ratio greater than or equal to 2 was required for positivity.

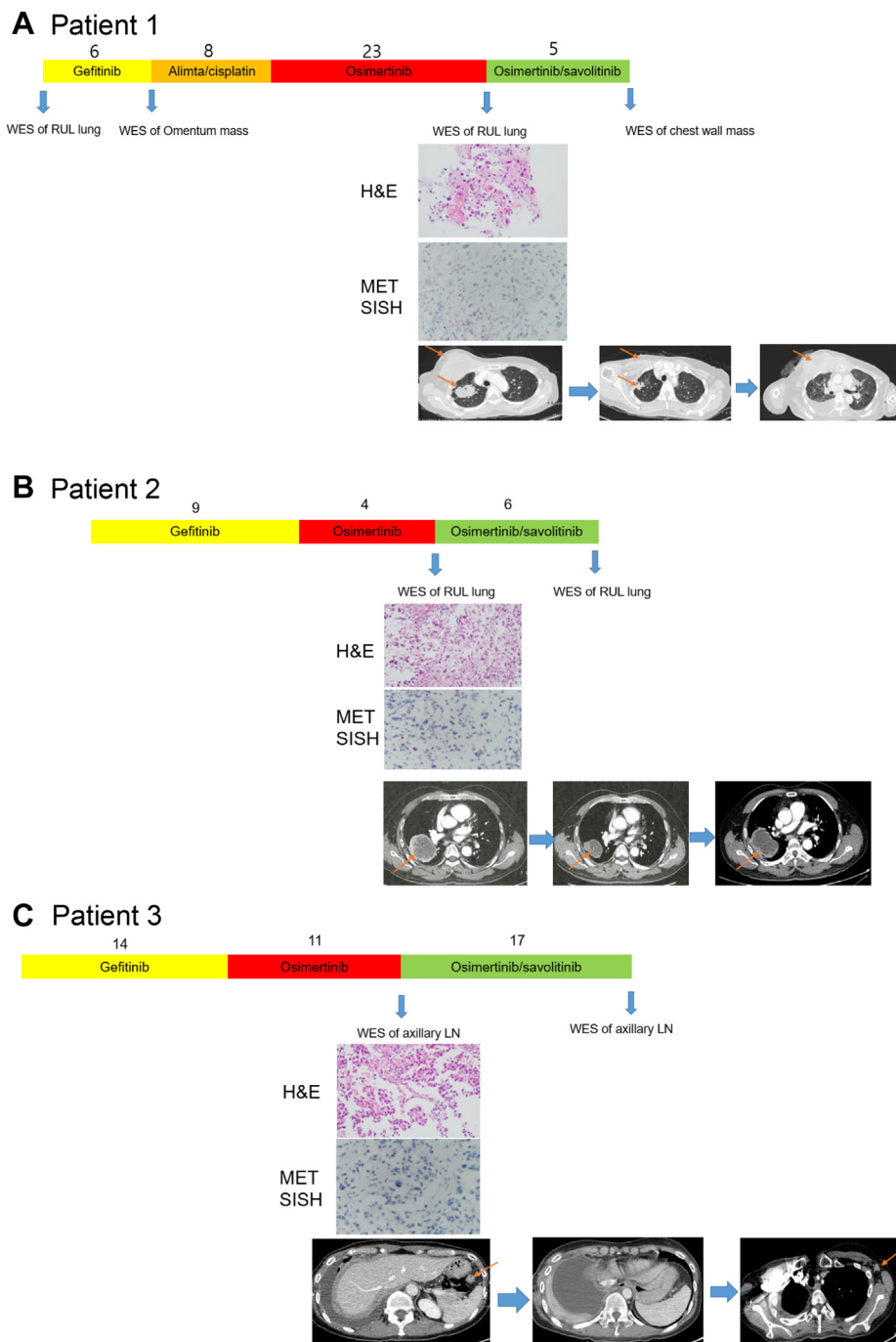
## Results

### Patient 1

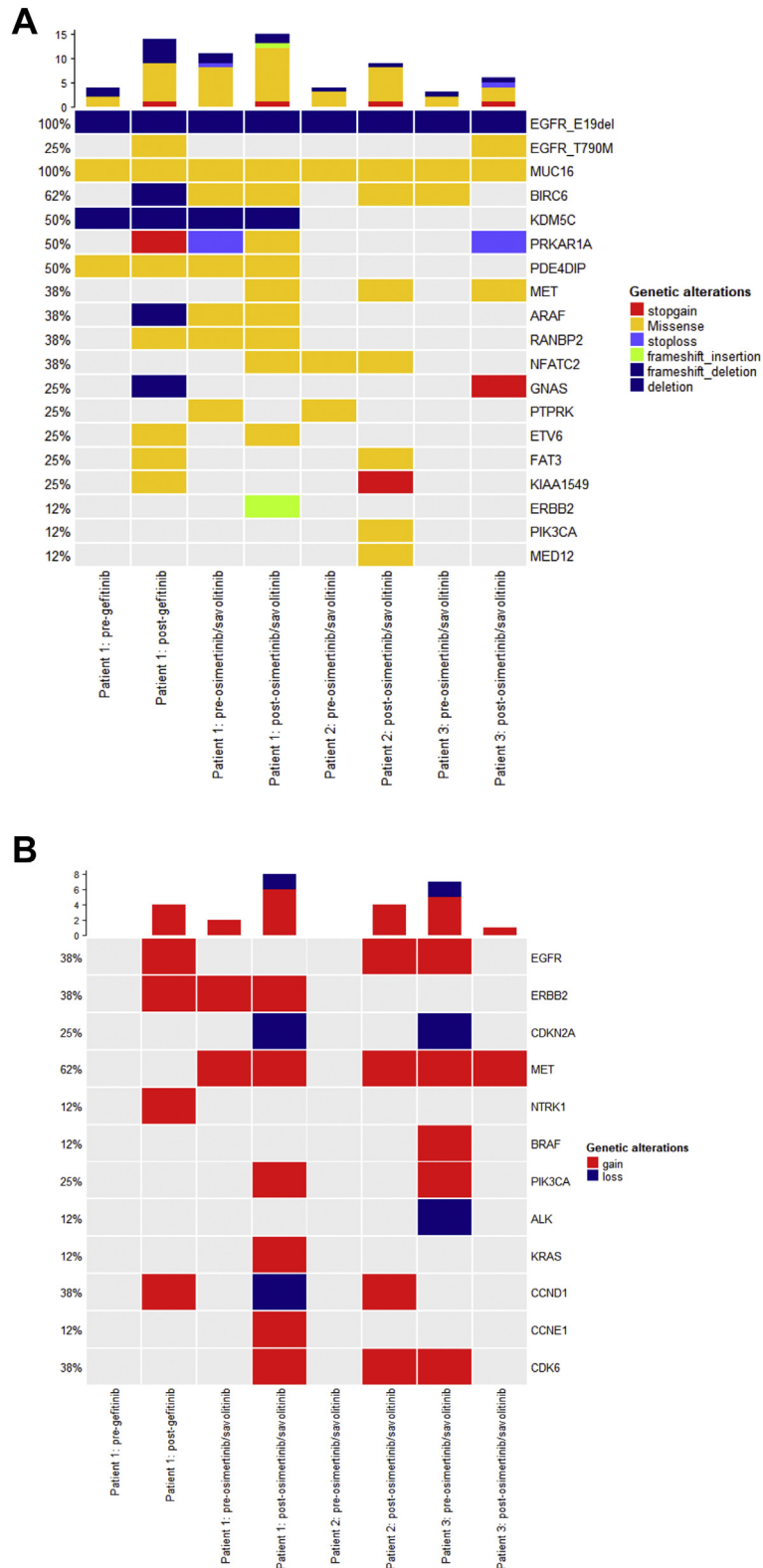
A 50-year-old woman was diagnosed with stage 4, *EGFR* exon 19 deletion mutation lung cancer in January 2015, and she received gefitinib as first-line therapy. Her disease progressed after 8 months, and she received pemetrexed and cisplatin as second-line therapy. Nevertheless, she experienced disease progression after 8 months, and the *EGFR* mutation test revealed acquired T790M mutation. This tumor also harbored acquired *GNAS* p.P553H mutation. Subsequently, she received osimertinib and was on osimertinib for 2 years until progression, and then she was enrolled in the TATTON trial ([Fig. 1A](#)). Her rebiopsied tumor sample at osimertinib progression was found to have squamous cell differentiation with average MET CN of 6.18 on SISH (CN = 3), with acquired *PRKAR1A* p.R352Q mutation. She achieved a partial response ( $-55\%$  tumor shrinkage) to osimertinib and savolitinib, before developing progressive disease in 6 months. A repeat biopsy at her chest wall revealed various alterations, including *ERBB2* p.L1152M, *MET* p.D1246N, *KDM5C* p.W622L, and *NFATC2* p.E465K mutation ([Fig. 2A](#)). *MET* CN even more amplified in the post-osimertinib/-savolitinib tissue (CN = 8). In addition, increased CN of *ERBB2* after resistance to osimertinib and savolitinib (CN = 2  $\rightarrow$  3) was observed ([Fig. 2B and C](#)). [Figure 2D](#) reveals a clonal evolution of reconstructed cell populations as a phylogenetic tree in this patient.

### Patient 2

A 61-year-old man who was diagnosed with stage IV NSCLC with *EGFR* exon 19 deletion mutation was treated with first-line gefitinib and then progressed to receive lazertinib, a third-generation EGFR TKI in phase 3 development. When he progressed to lazertinib, his tumor was found to have *MET* amplification, so he was started with osimertinib and savolitinib. His tumor had  $-23.9\%$  shrinkage in the right lung mass, and his disease remained stable for 6 months, but the primary lung lesion regrew. A repeat tumor biopsy was

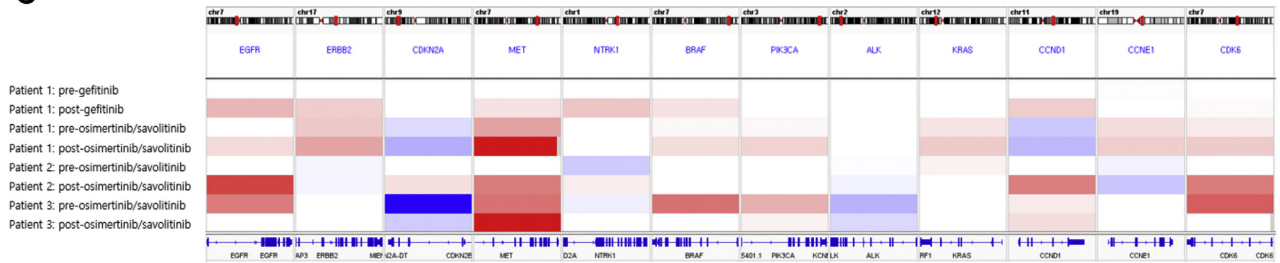


**Figure 1.** Treatment history and timing of tissue collection of the three patients. (A) Treatment timeline from diagnosis for patient 1. The patient had previously received gefitinib, pemetrexed/cisplatin, and osimertinib. After progression on osimertinib, her tumor had MET amplification, and imaging at first restaging revealed a treatment response in the right upper lung tumor (orange arrow). The subject subsequently progressed after 5 months, and rebiopsy was performed in the enlarging chest wall mass. (B) Treatment timeline from diagnosis for patient 2. The patient had previously received gefitinib and osimertinib before enrollment into the TATTON trial. He reported a partial response to osimertinib/savolitinib (orange arrow), and after progression, rebiopsy was performed on the right lung lesion. (C) Treatment timeline from diagnosis for patient 3. The patient had previously received gefitinib and osimertinib and was enrolled into the TATTON trial. She reported 100% shrinkage of the target lesion (left subphrenic nodule) while on treatment with osimertinib/savolitinib but progressed after 17 months. Repeat biopsy was performed on the left axillary lymph node. osimertinib before enrollment into the TATTON trial. He reported a partial response to osimertinib/savolitinib (orange arrow), and after progression, rebiopsy was performed on the right lung lesion. (C) Treatment timeline from diagnosis for patient 3. The patient had previously received gefitinib and osimertinib and was enrolled into the TATTON trial. She reported 100% shrinkage of the target lesion (left subphrenic nodule) while on treatment with osimertinib/savolitinib but progressed after 17 months. Repeat biopsy was performed on the left axillary lymph node. H&E, hematoxylin & eosin; LN, lymph node; RUL, right upper lung; SISH, silver in situ hybridization; WES, whole exome sequencing

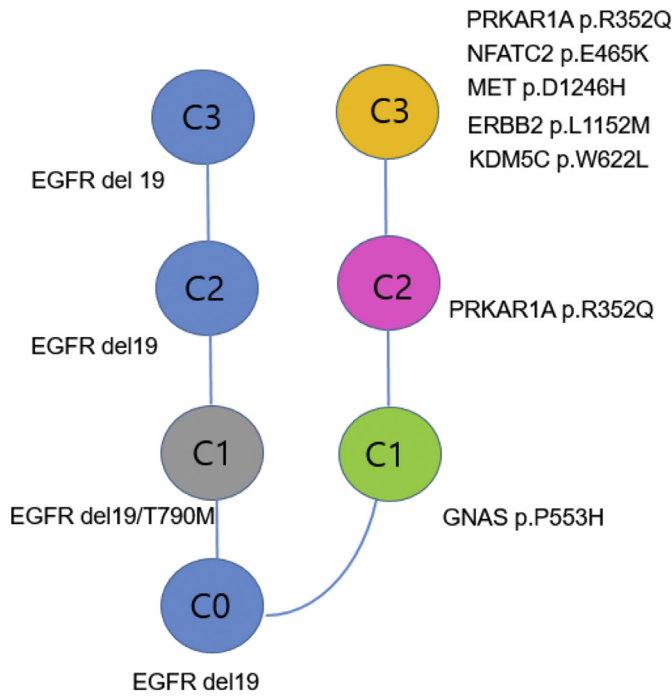


**Figure 2.** Landscape of acquired resistance to osimertinib and savolitinib and clonal evolution during targeted therapy. (A) A heatmap depicts the distribution of nonsilent somatic mutations among pre- and post-treatment tissues. Patient 1 had pre-gefitinib, post-gefitinib, pre-osimertinib/savolitinib, and post-osimertinib/savolitinib samples. Patients 2 and 3 had pre-osimertinib/savolitinib and post-osimertinib/savolitinib samples. (B) A heatmap depicts the CN gain or loss in known oncogenes. (C) Profiles of CN alterations (red = CN gain, blue = CN loss) for known oncogenes. (D-F) Clonal evolution of reconstructed cell populations is presented as a phylogenetic tree in patients 1 to 3, respectively. The computationally inferred most common ancestor C0 is typical to all subsequent clones, and newly acquired mutations are present in descendent clones. CN, copy number.

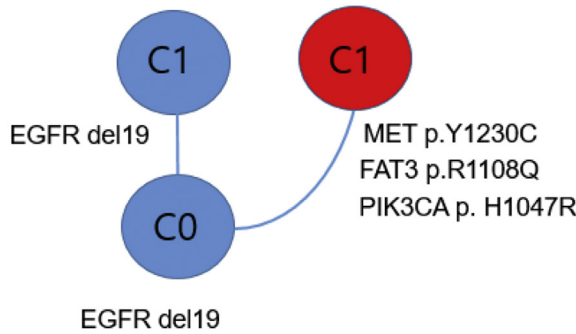
C



D



E



F

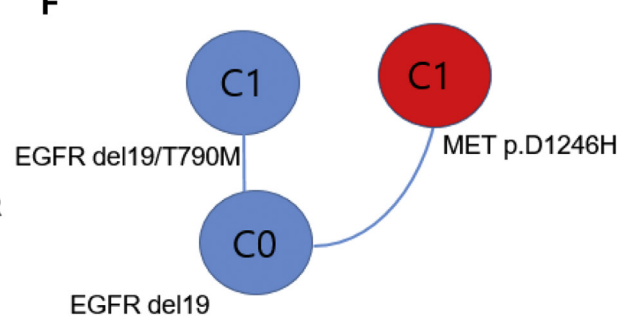
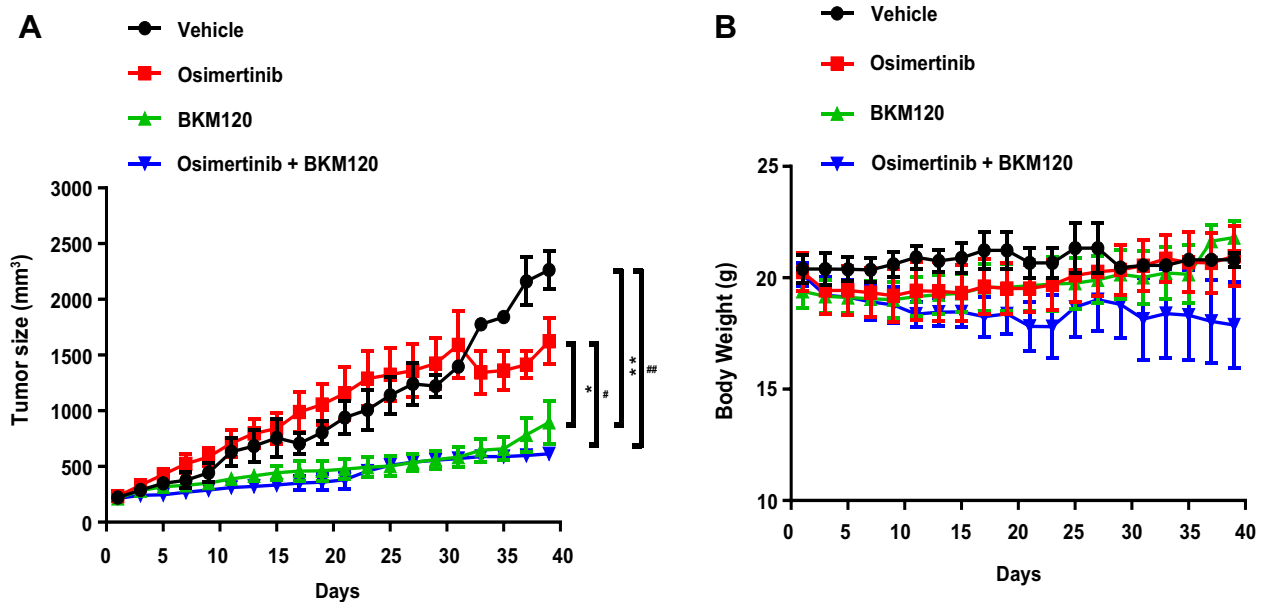


Figure 2. Continued

performed to characterize genomic landscape of resistance (Fig. 1B). The WES analysis revealed acquired *MET* p.Y1230C mutation (MAF = 0.165) and *PIK3CA* p.H1047R mutation (MAF = 0.3). In addition, CN gains in

*CCNE1* (CN = 4), *CCND1* (CN = 4), *CDK6* (CN = 3), and *EGFR* (CN = 5) were observed (Fig. 2B). Figure 2E reveals a clonal evolution of reconstructed cell populations as a phylogenetic tree in patient 2.



**Figure 3.** In vivo experiment using a patient-derived xenograft obtained from patient 2. (A) A patient-derived xenograft model (YH1061) was established from patient 2 and was treated with four groups (vehicle, osimertinib 25 mg/kg, BKM120 35 mg/kg, and osimertinib 25 mg/kg plus BKM120 35 mg/kg). A graph reveals the delayed tumor growth in the BKM120 and osimertinib plus BKM120 groups. (B) A graph revealing body weight changes according to treatment. The  $p$  values are depicted as  $*p < 0.05$ ,  $^{\#}p < 0.05$ ,  $^{**}p < 0.01$ , and  $^{###}p < 0.001$ .

We established a patient-derived xenograft model (YH1061) from this patient using a rebiopsied tumor after resistance, and combinations of osimertinib and BKM120 were treated to find whether addition of PI3K inhibitor could overcome resistance (Fig. 3A). Combination of osimertinib 25 mg/kg and BKM120 35 mg/kg revealed significant tumor growth delay compared with vehicle or osimertinib without significant toxicity ( $p < 0.001$  and  $p < 0.01$ , respectively; Fig. 3B).

### Patient 3

A 57-year-old woman was diagnosed with stage IV NSCLC with *EGFR* exon 19 deletion mutation. She started her first-line systemic treatment with gefitinib in January 2016 and was treated for 14 months until development of acquired resistance. She had developed T790M mutation and thus received osimertinib as second line for 11 months. After progression on osimertinib, her rebiopsied tumor sample was found to have *MET* amplification on MET SISH, and she was enrolled into the TATTON trial. She achieved a partial response with a 100% shrinkage of the target lesion. Her response maintained for 17 months, until she developed progression in bilateral axillary lymph nodes (Fig. 1C). Repeat biopsies were performed in both axillary lymph nodes for further mechanistic study. The WES analyses of the progressed lesions revealed acquired *MET* mutation p.D1246H (MAF = 0.238). On CNV analysis, *MET* CN was increased to 10

(Fig. 2A and C). Figure 2F reveals a clonal evolution of reconstructed cell populations as a phylogenetic tree in patient 3.

## Discussion

In this study, we identified putative on-target and off-target mechanisms of EGFR/*MET* blockade in patients with *EGFR*-mutant NSCLC treated with osimertinib and savolitinib. *MET* mutations may be acquired resistance mechanism after progression on EGFR/*MET* inhibitor in patients with NSCLC with primary *EGFR* mutation and secondary acquired *MET* amplification. *MET* Y1230C and D1246H mutations identified in three patients occur in the *MET* kinase domain, which limits the activity of savolitinib, a type 1b *MET* TKI. In one patient, multiple off-target resistance mechanisms were identified, including *ERBB2* mutation/amplification. Concurrent *MET* amplification was also found with CN gain in genes involved in cell cycle machinery (*CCNE1*, *CCND1*, *CDK6*).

The optimal treatment approach for patients on osimertinib remains heterogeneous, and the risk of acquiring *MET*-amplified subclones in such patients is high.<sup>7</sup> Although combined EGFR/*MET* blockade may provide encouraging antitumor activity in these patients, treatment options are limited for patients who progress on EGFR/*MET* blockade. Therefore, understanding the diversity of *MET* mutations as a mechanism of resistance to osimertinib plus savolitinib is helpful in defining the need to develop novel *MET* inhibitors with broader

activity against *MET* mutations. Our evolutionary analysis using temporal sequencing revealed that *MET*-driven resistance mechanisms on both single-nucleotide variants and CN variation level may dampen the response. We suggest that on progression on osimertinib and savolitinib, rebiopsy of tumor is essential to identify heterogeneous mechanisms of acquired resistance. We identified novel putative resistance mechanisms, such as mutations in *ERBB2*, *KDM5C*, *ARAF*, and *NFATC2*, which were all turned out to be damaging by in silico prediction. Nevertheless, the functions of these genes need to be further validated to prove their role in acquired resistance.

Many agents targeting *MET* are currently in development for *MET*-driven lung cancer. *MET* exon 14 skipping mutation is a different genotype that has recently gained attention owing to targeted agents, such as capmatinib<sup>8</sup> and tepotinib.<sup>9</sup> In addition to TKIs, several antibodies have been generated to effectively inhibit *MET*. For example, REGN5093, which targets two epitopes of *MET*, is actively investigated in a first-in-human trial of *MET*-altered advanced NSCLC (NCT04077099).<sup>10</sup> Acquired resistance mechanisms that have been reported with other *MET* inhibitors include amplification and mutations in *KRAS* and other RAS-MAPK pathway components.<sup>11–13</sup> Secondary *MET* mutations, such as Y1230X, as reported here in one patient, have also been identified as acquired resistance mechanisms in both in vitro<sup>14</sup> and clinical case reports.<sup>15</sup> Nevertheless, it is not clear whether resistance mechanisms are different between *MET*-amplified tumors and *MET* exon 14 skipping-mutant tumors.

Given the recent promising clinical data, *MET* is still an attractive target, and ultimately, a more complete understanding of the mechanisms by which tumor cells resist therapy will pave the way for novel approaches that will maximize the efficacy of *MET*-directed therapy.

## Supplementary Data

Note: To access the supplementary material accompanying this article, visit the online version of the *JTO Clinical and Research Reports* at [www.jtocrr.org](http://www.jtocrr.org) and at <https://doi.org/10.1016/j.jtocrr.2021.100180>

## References

- Hanna N, Johnson D, Temin S, et al. Systemic therapy for stage IV non-small-cell lung cancer: American Society of Clinical Oncology clinical practice guideline update. *J Clin Oncol*. 2017;35:3484-3515.
- Lim SM, Syn NL, Cho BC, Soo RA. Acquired resistance to EGFR targeted therapy in non-small cell lung cancer: mechanisms and therapeutic strategies. *Cancer Treat Rev*. 2018;65:1-10.
- Oxnard GR, Hu Y, Mileham KF, et al. Assessment of resistance mechanisms and clinical implications in patients with EGFR T790M-positive lung cancer and acquired resistance to osimertinib. *JAMA Oncol*. 2018;4:1527-1534.
- Papadimitrakopoulou VA, Wu YL, Han JY, et al. LBA51 analysis of resistance mechanisms to osimertinib in patients with EGFR T790M advanced NSCLC from the AURA3 study. *Ann Oncol*. 2018;29(suppl 8):viii741.
- Sequist LV, Han JY, Ahn MJ, et al. Osimertinib plus savolitinib in patients with EGFR mutation-positive, MET-amplified, non-small-cell lung cancer after progression on EGFR tyrosine kinase inhibitors: interim results from a multicentre, open-label, phase 1b study. *Lancet Oncol*. 2020;21:373-386.
- Piper-Vallillo AJ, Halbert BT, Rangachari D, Kobayashi SS, Costa DB. Acquired resistance to osimertinib plus savolitinib is mediated by MET-D1228 and MET-Y1230 mutations in EGFR-mutated MET-amplified lung cancer. *JTO Clin and Res Rep*. 2020;1:100071.
- Leonetti A, Sharma S, Minari R, Perego P, Giovannetti E, Tiseo M. Resistance mechanisms to osimertinib in EGFR-mutated non-small cell lung cancer. *Br J Cancer*. 2019;121:725-737.
- Wolf J, Seto T, Han JY, et al. Capmatinib in MET exon 14-mutated or MET-amplified non-small-cell lung cancer. *N Engl J Med*. 2020;383:944-957.
- Paik PK, Felip E, Veillon R, et al. Tepotinib in non-small-cell lung cancer with MET Exon 14 skipping mutations. *N Engl J Med*. 2020;383:931-943.
- DaSilva JO, Yang K, Perez Bay AE, et al. A biparatopic antibody that modulates MET trafficking exhibits enhanced efficacy compared with parental antibodies in MET-driven tumor models. *Clin Cancer Res*. 2020;26:1408-1419.
- Bahcall M, Awad MM, Sholl LM, et al. Amplification of wild-type *KRAS* imparts resistance to crizotinib in MET exon 14 mutant non-small cell lung cancer. *Clin Cancer Res*. 2018;24:5963-5976.
- Jamme P, Fernandes M, Copin MC, et al. Alterations in the PI3K pathway drive resistance to MET inhibitors in NSCLC harboring MET exon 14 skipping mutations. *J Thorac Oncol*. 2020;15:741-751.
- Rotow JK, Gui P, Wu W, et al. Co-occurring alterations in the RAS-MAPK pathway limit response to MET inhibitor treatment in MET exon 14 skipping mutation-positive lung cancer. *Clin Cancer Res*. 2020;26:439-449.
- Fujino T, Kobayashi Y, Suda K, et al. Sensitivity and resistance of MET exon 14 mutations in lung cancer to eight MET tyrosine kinase inhibitors in vitro. *J Thorac Oncol*. 2019;14:1753-1765.
- Ou SI, Young L, Schrock AB, et al. Emergence of preexisting MET Y1230C mutation as a resistance mechanism to crizotinib in NSCLC with MET exon 14 skipping. *J Thorac Oncol*. 2017;12:137-140.