

# Incessant ventricular tachycardia treated with cardiac radioablation in an 11-year-old boy with dilated cardiomyopathy



Youngchae Lee, MD,\* Hong In Yoon, MD, PhD,<sup>†</sup> Jin-Sung Kim, PhD,<sup>†</sup>  
Ah-Young Kim, MD, PhD,<sup>‡</sup> Saruul Tsevendee, MD, PhD,<sup>§</sup> Jae-Sun Uhm, MD, PhD\*

From the \*Division of Cardiology, Severance Cardiovascular Hospital, College of Medicine, Yonsei University, Seoul, Republic of Korea, <sup>†</sup>Department of Radiation Oncology, Yonsei Cancer Hospital, College of Medicine, Yonsei University, Seoul, Republic of Korea, <sup>‡</sup>Department of Pediatric Cardiology, Severance Cardiovascular Hospital, College of Medicine, Yonsei University, Seoul, Republic of Korea, and <sup>§</sup>Department of Cardiology, Third State Central Hospital, Ulaanbaatar, Mongolia.

## Introduction

Noninvasive cardiac radioablation for ventricular tachycardia (VT) is an emerging and promising treatment option for cases of VT that are refractory to conventional treatment modalities. However, the efficacy and safety of cardiac radioablation have not been investigated in pediatric patients with VT. Here, we report the case of an 11-year-old boy with dilated cardiomyopathy and incessant VT, who was treated with cardiac radioablation.

## Case report

An 11-year-old Mongolian boy visited a local hospital after complaining of dyspnea on exertion over a 3-year period. His condition was treated as a respiratory infection, but his symptoms did not improve, and he was subsequently transferred to a tertiary hospital 2 months after his treatment began. Echocardiography revealed findings consistent with dilated cardiomyopathy: severely decreased global left ventricular (LV) systolic function, LV ejection fraction (LVEF) reduced to 10%, and severely dilated left ventricle. Magnetic resonance imaging of the heart showed LVEF reduced to 3% and no delayed enhancement. He was diagnosed with heart failure (HF) with reduced EF. He was treated for HF with sacubitril/valsartan, carvedilol,

furosemide, and spironolactone, but 2 months after the onset of his treatment he complained of palpitations. An electrocardiogram (ECG) was performed, revealing an incessant monomorphic VT. A focal VT originating from the right ventricular (RV) free wall was found through electrophysiological study. However, despite several attempts with radiofrequency catheter ablation (RFCA), the VT was sustained. At this stage, the patient was transferred to our hospital.

At admission, the patient's vital signs were as follows: blood pressure, 84/39 mm Hg; heart rate, 114 beats/min; respiratory rate, 20 beats/min; and body temperature, 36.7°C. Auscultation revealed S3 gallop and normal lung sounds. The abdomen was soft and not distended. No peripheral edema was noted. The level of N-terminal pro-brain natriuretic peptide was 6195 pg/mL, while all other laboratory findings were within the normal limits. A chest radiograph revealed cardiomegaly and clear lung fields. ECG showed sustained monomorphic VT with a heart rate of 116 beats/min (Figure 1). ECG monitoring revealed the VT was incessant all day long. Echocardiography during VT revealed 10% of LVEF, global hypokinesia of both ventricles, dyssynchronous LV wall motion, dilated left ventricle (63/49 mm of LV end-diastolic dimension / end-systolic dimension, respectively), left atrial enlargement (57 mL/m<sup>2</sup> of left atrial volume index), and severe functional mitral regurgitation.

On the second day of hospitalization, elective electrical cardioversion was performed but failed to convert the VT to a sinus rhythm. Temporary atrial pacing at 120 beats/min (a faster rate than the VT) was attempted on the third day of hospitalization in order to suppress the VT. However, this resulted in a prolonged PR interval and simultaneous atrial and ventricular contraction. LV systolic function was not improved during atrial pacing.

On the eleventh day of hospitalization, an electrophysiological study was performed using CARTO (Johnson & Johnson, Diamond Bar, CA) 3-dimensional (3-D) mapping.

**KEYWORDS** Ablation; Child; Dilated cardiomyopathy; Pediatrics; Stereotactic radiotherapy; Ventricular tachycardia  
(Heart Rhythm Case Reports 2021;7:186–190)

Conflicts of Interest and Source of Funding: The authors have no conflicts to disclose. **Address reprint requests and correspondence:** Dr Jae-Sun Uhm, Division of Cardiology, Severance Cardiovascular Hospital, College of Medicine, Yonsei University, 50-1 Yonsei-ro, Seodaemun-gu, Seoul, 03722, Republic of Korea. E-mail address: [jason@yuhs.ac](mailto:jason@yuhs.ac); or **Address reprint requests and correspondence:** Dr Hong In Yoon, Division of Radiation Oncology, Yonsei Cancer Center, College of Medicine, Yonsei University, 50-1 Yonsei-ro, Seodaemun-gu, Seoul, 03722, Republic of Korea. E-mail address: [yhi0225@yuhs.ac](mailto:yhi0225@yuhs.ac).

**KEY TEACHING POINTS**

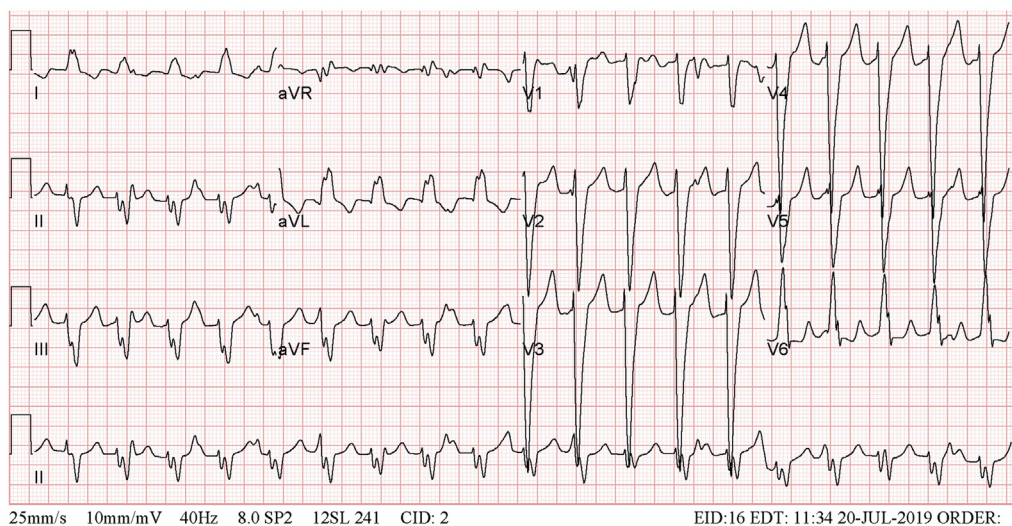
- Radiofrequency catheter ablation (RFCA) for ventricular tachycardia (VT) may be challenging.
- Cardiac radioablation can be considered in patients with refractory VT despite medical treatment and/or RFCA.
- Cardiac radioablation for VT is feasible in pediatric patients.

The 3-D electroanatomical map revealed a focal tachycardia originating from the RV free wall (Figure 2). The VT was terminated by RFCA performed at its origin, and it was not induced by programmed electrical stimulation. However, VT recurred 1 hour after the procedure and was accelerated (heart rate, 144 beats/min). Several antiarrhythmic drugs were administered but were ineffective owing to a variety of reasons. Carvedilol was not tolerated because of low blood pressure; intravenous amiodarone was neither effective nor tolerated because of nausea; lidocaine was effective only at the maximum dose, but was not tolerated because of nausea; and mexiletine was only minimally effective. Eventually, VT was partially managed through a combination of low-dose intravenous lidocaine and 100 mg of oral mexiletine 3 times a day. On the nineteenth day of hospitalization, a dual-chamber implantable cardioverter-defibrillator (ICD) was implanted to prevent sudden cardiac death.

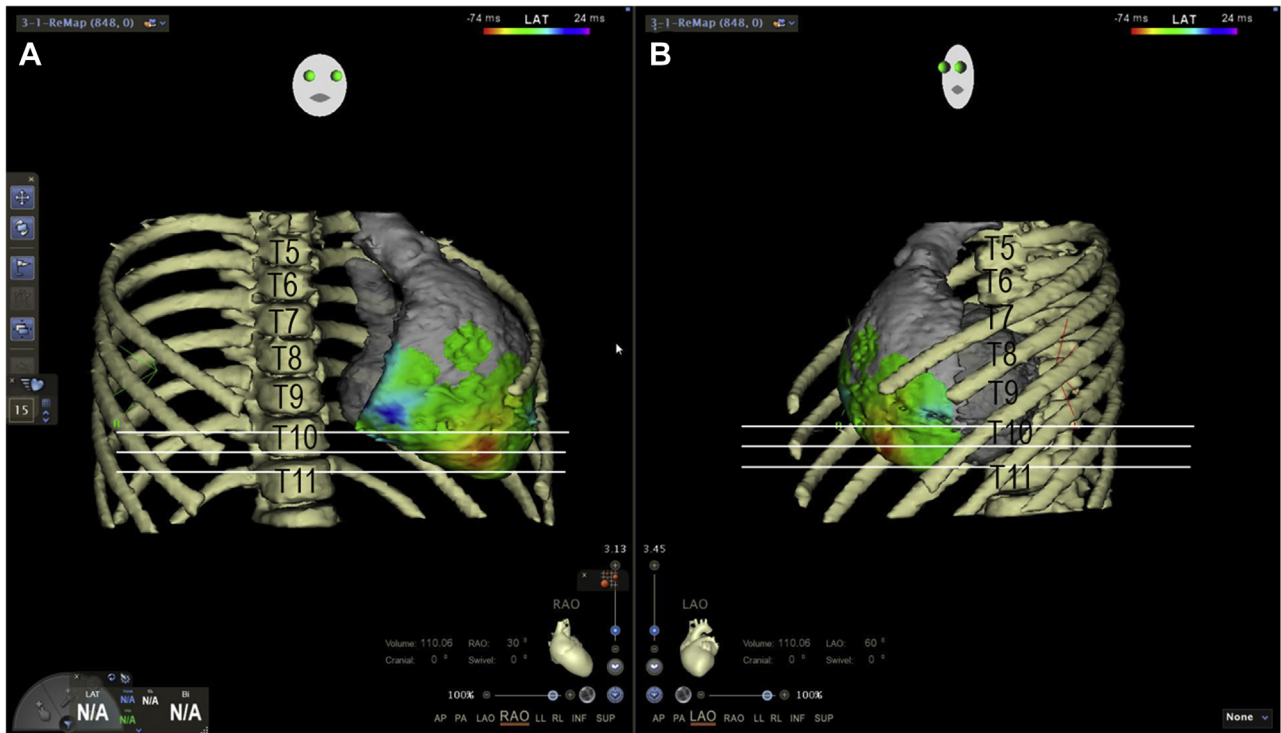
Given the ineffectiveness of the antiarrhythmic drugs, the 2 consecutive RFCA failures, and the very low LVEF, we decided to perform cardiac radioablation. Planning computed tomography (CT) of the chest was performed using an ECG-gating and metal artifact reduction technique. Through the coordinated efforts of cardiac electrophysiologists, radiation

oncologists, and medical physicists, the cardiac radioablation was planned by transferring the 3-D map of the VT to the planning CT using bone landmarks that included the ribs and vertebrae using CARTO and the CARTOMERGE module (Figure 3). We first delineated the gross target volume using previously generated 3-D mapping. The internal target volume was defined as the gross target volume plus a margin to account for the maximum range of respiratory and cardiac motion observed on 4-dimensional CT and phased-binned chest CT. The planning target volume was created as a 3- to 5-mm expansion of the internal target volume. The cardiac radioablation plan was carried out in the RayStation treatment planning system (v5.0.2.35; RaySearch Laboratories, Stockholm, Sweden). A volumetric modulated arc radiotherapy technique was used with a 6-MV flattening filter-free beam from an Elekta VersaHD (Elekta, Crawley, UK) linear accelerator. The dose was normalized to deliver 95% of the prescribed dose to 95% of the planning target volume. On the 38th day of hospitalization, noninvasive cardiac radioablation was performed on the VT origin, the RV mid free wall, with a single fraction of 25 Gy using a total of 5 arc beams including 4 non-coplanar beams.<sup>1,2</sup> After radioablation, carvedilol, mexiletine, lidocaine, sacubitril/valsartan, and diuretics were administered.

Holter monitoring was performed shortly before and weekly after radioablation to assess the burden of VT after antiarrhythmic drugs were ceased for 2 days, which is equivalent to 4 times their half-lives. VT burden was 98% 9 days after radioablation, 95% after 5 weeks, and 61% after 6 weeks. Six weeks after radioablation, VT burden was further reduced with percutaneous bilateral stellate ganglion blockade, and 7 weeks after radioablation the burden was reduced to 24% (Supplemental Figure 1). Chest CT performed 6 weeks after radioablation showed no adverse effects related to the procedure.



**Figure 1** Baseline electrocardiography at the time of admission.



**Figure 2** Three-dimensional electroanatomical mapping for ventricular tachycardia at (A) a right anterior oblique 30° view and (B) a left anterior oblique 60° view. T = thoracic vertebra.

The patient's blood pressure was increased during sinus rhythm compared with during VT. Medications for HF could therefore be increased owing to the increased blood pressure. N-terminal pro-brain natriuretic peptide was still 6537 pg/mL before discharge, a total of 46 days after radioablation. Echocardiography showed an LVEF of 12% and synchronous wall motion. The patient was discharged with oral medications consisting of 100 mg sacubitril/valsartan twice a day, 25 mg carvedilol twice a day, 12.5 mg spironolactone once a day, 100 mg amiodarone twice a week, and 100 mg mexiletine 3 times a day.

The 3-month follow-up visit to the hospital in Mongolia revealed the patient was in good condition. The patient's ECG and ICD interrogation showed normal sinus rhythm and no evidence of VT. Six months after radioablation, the patient was hospitalized for HF management for 2 weeks in Mongolia. During hospitalization, ECG monitoring showed normal sinus rhythm and no VT. LVEF still remained 15%.

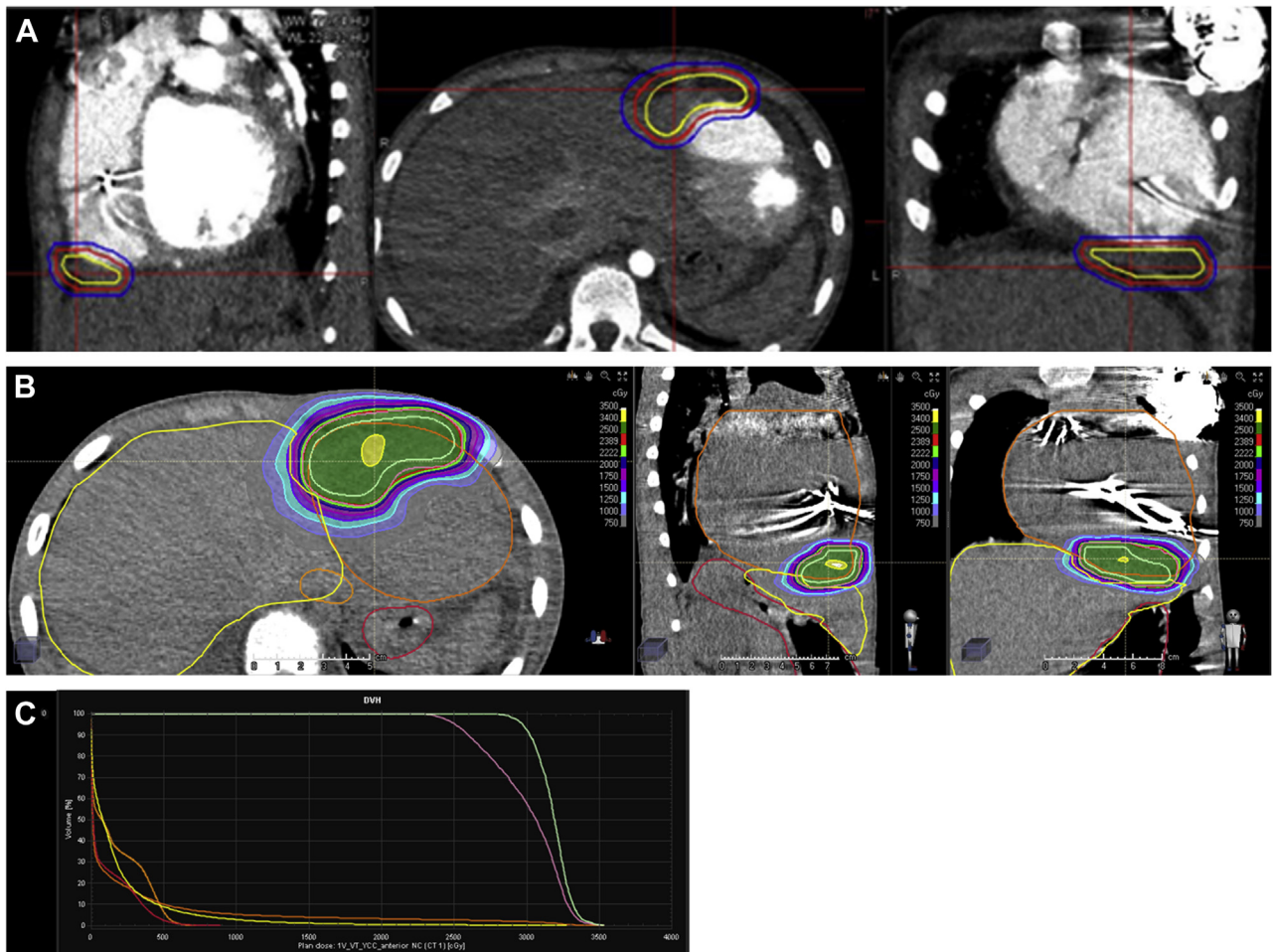
## Discussion

We have presented a case of incessant VT in an 11-year-old male patient with dilated cardiomyopathy that we treated with noninvasive cardiac radioablation. There have been several previous studies that have reported case reports or clinical trials involving a small number of patients with refractory VT that have been treated with noninvasive cardiac radioablation or stereotactic radiosurgery. One such report presented the case of a 71-year-old man with ischemic

cardiomyopathy (27% LVEF) and VT refractory to medical therapy who was treated with radioablation.<sup>3</sup> RFCA was not attempted in this case owing to the patient's comorbidities. Radioablation was successful for this patient, and he was free from VT at a 9-month follow-up. Similarly, Cvek and colleagues<sup>4</sup> reported the successful use of radioablation in a 72-year-old woman with dilated cardiomyopathy and 25% LVEF. This patient received radioablation after medical and RFCA therapies were unsuccessful, and remained free of malignant arrhythmia at a 120-day follow-up. A slightly larger study documenting the treatment of 5 patients also confirmed the effectiveness of radioablation in reducing ventricular arrhythmia burden for at least 6 months after treatment.<sup>1</sup> In this series, VT mapping was performed noninvasively using electrocardiographic imaging, which was obtained through programmed stimulation along the ICD leads.

A prospective, single-arm phase I/II trial involving 19 patients and performed in a single center found that radioablation was effective in reducing ventricular arrhythmia burden over a 6-month follow-up period.<sup>1</sup> The assessment of long-term radioablation efficacy and toxicity in 10 patients treated with radioablation delivered as a bailout therapy proved it to be successful in managing nausea as an acute toxicity in 4 patients.<sup>5</sup> One patient in this study displayed worsened mitral regurgitation, which was thought to be a possible grade 3 late toxicity.

RFCA for VT is challenging. The major reasons for RFCA failure in VT are as follows: (1) inaccurate VT



**Figure 3** A: Planning for cardiac radioablation. The area within the yellow lines indicates the gross target volume, the red lines indicate the internal target volume, and the blue lines highlight the planning target volume. B: The cardiac radioablation plan in axial, sagittal, and coronal view. C: Dose-volume histogram. Twenty-five Gy was prescribed on 95% isodose line.

mapping, (2) instability of the ablation catheter, (3) deep intramural origins, and (4) origins protected by the adjacent structure including the epicardial fat, coronary arteries, and hypertrabeculation. Cardiac radioablation can be used to overcome all but the first reason. As bailout therapy after RFCA failure, it is crucial to transfer the 3-D electroanatomical VT map to the radiotherapy planning CT image. In the present case, we used bone landmarks including the ribs and vertebrae for transferring the VT map to the planning CT. During 3-D mapping, the geometries of the other cardiac chambers and great vessels can be beneficial, as they can be used as landmarks for transferring the 3-D map to the planning CT.

In the present case, the VT might have been from either enhanced automaticity or triggered activity, which is thought so because continuous ECG monitoring showed that VT was competitive with sinus rhythm. The most likely reason for the RFCA failure is that the radiofrequency energy was not delivered to the focus of the VT because of hypertrabeculation of the RV free wall endocardium. Compared with the prior studies, the response to radiation was more delayed in our

case. The suppression of VT by vascular damage and ischemic cell death takes weeks to months. In terms of radioablation, the induction of vascular damage and ischemic cell death may be the more important rather than double-strand breaks in deoxyribonucleic acids in their mechanisms of action in the treatment of VT, because myocytes are quiescent in terms of cell proliferation.<sup>6</sup> The reason for this is unclear, but it may be owing to the mechanism and origin of tachycardia. In our case, the area of automaticity or triggered activity might have been larger and more refractory than that of the critical isthmus of the scar-related reentry.

The youngest patient having previously received radioablation reported in the literature was 49 years old.<sup>2</sup> Thus, this is the first report of noninvasive cardiac radioablation for VT in a pediatric patient. There are 2 essential points that need to be considered for radioablation in pediatric patients. First, the smaller physical constitution of pediatric patients means that the adjacent structures that need to be avoided can be closer, and therefore are more difficult to avoid. Second, pediatric patients are still growing. If the ribs and sternum are included in the target area, radiation

therapy may lead to long-term growth retardation or distortion of these structures. These factors should be considered before radioablation is performed in pediatric patients.<sup>7</sup>

## Conclusion

Cardiac radioablation for VT can be feasible and effective in pediatric patients, although careful planning is required. Further long-term effects of cardiac radioablation need to be studied in pediatric patients.

## Acknowledgments

The authors thank Hye-Jeong Lee, MD, PhD, from Department of Radiology, Severance Hospital, for her support with scanning and interpretation of CT and Hye Lin An from Biosense Webster, Johnson & Johnson Inc., for her support with 3-D electroanatomical mapping with the CARTO system.

We would like to thank Editage ([www.editage.co.kr](http://www.editage.co.kr)) for English-language editing.

## Appendix Supplementary data

Supplementary data associated with this article can be found in the online version at <https://doi.org/10.1016/j.hrcr.2020.12.009>.

## References

1. Cuculich PS, Schill MR, Kashani R, et al. Noninvasive cardiac radiation for ablation of ventricular tachycardia. *N Engl J Med* 2017;377:2325–2336.
2. Robinson CG, Samson PP, Moore KMS, et al. Phase I/II trial of electrophysiology-guided noninvasive cardiac radioablation for ventricular tachycardia. *Circulation* 2019;139:313–321.
3. Loo BW Jr, Soltys SG, Wang L, et al. Stereotactic ablative radiotherapy for the treatment of refractory cardiac ventricular arrhythmia. *Circ Arrhythm Electrophysiol* 2015;8:748–750.
4. Cvek J, Neuwirth R, Knybel L, et al. Cardiac radiosurgery for malignant ventricular tachycardia. *Cureus* 2014;6:e190.
5. Neuwirth R, Cvek J, Knybel L, et al. Stereotactic radiosurgery for ablation of ventricular tachycardia. *Europace* 2019;21:1088–1095.
6. Sharma A, Wong D, Weidlich G, et al. Noninvasive stereotactic radiosurgery (CyberHeart) for creation of ablation lesions in the atrium. *Heart Rhythm* 2010;7:802–810.
7. Kim EJ, Davogustto G, Stevenson WG, John RM. Non-invasive cardiac radiation for ablation of ventricular tachycardia: a new therapeutic paradigm in electrophysiology. *Arrhythm Electrophysiol Rev* 2018;7:8–10.