



## Changes in the Color and Sensitivity of the Tongue in Adult Women After COVID-19 Treatment

**Luciana de Barros Correia Fontes\***, **Maria da Conceição de Barros Correia**, **Kátia Maria Gonçalves Marques**, **Pedro Henrique Bezerra Fontes**, **Nayara Ferreira da Silva**, **Marília Cleide Tenório Gomes**, **Rita de Cássia Barreto Fernandes**, **Daniele Andrade da Cunha**, **Hilton Justino da Silva**, **Leonardo Bezerra Cavalcanti dos Santos** and **Niedje Siqueira de Lima**

*Federal University of Pernambuco, Brazil*

**\*Corresponding Author:** Luciana de Barros Correia Fontes, Federal University of Pernambuco, Brazil.

**Received:** November 16, 2020

**Published:** March 10, 2021

© All rights are reserved by **Luciana de Barros Correia Fontes., et al.**

### Abstract

**Objectives:** to describe the changes in color and sensitivity of the tongue in adult women, in the period after the treatment of COVID-19 and explain the dental conduct for treatment. **Case report:** there was a request for dental evaluation by a public and reference University Hospital in the city of Recife, northeast of Brazil. The patient in question was a 33 years-old white female. There was a history of diagnosis and treatment for COVID-19, with antibiotic, antipyretic and medication for worms, with the complaint of much sensitivity and change in language. The physical examination showed gingivitis in the lower sextant, with spontaneous gingival bleeding and dark spots on the dorsum of the tongue, associated with increased discomfort in the region. It was observed that the patient did not receive any orientation about oral hygiene, even with the report of pain in this region. It was opted for the orientation of the hygienization, with the reinforcement of the cleanness of the tongue, cheeks with hydrogen peroxide or oxygenated water to 10 volumes and the reinforcement for the ingestion of vitamin C, beyond the control of the biofilm, for the treatment of the gingivitis in the anterior and inferior sextant. **Conclusions:** this report covers the control made in seven days, being the images referring to the third day after the guidelines. There was a change in the color of the tongue and sensibility, with regular ingestion of food and liquids. There was also an improvement in gingivitis, but control is necessary.

**Keywords:** Oral Health; Tongue; Coronavirus Infection

### Introduction

Since the beginning of the COVID-19 pandemic, worldwide and up to the present day, there are still many doubts about this disease, its symptoms and treatments; as it manifests and advances in a complex and individual manner, with extensive particularities. In this context, and with regard to orofacial conditions, there is still no broader knowledge; probably due to the fact that professionals more directly related to this region have not been established as a “front line to confront”.

However, the oral cavity, in a more specific way, is a unique region in the issue of early diagnosis of many health problems. As

time goes by in this “COVID-19 coexistence”, some reports begin to describe possible alterations in the site [1-3]. Even if it cannot be clearly determined if they come directly from the SARS-Cov-2 infection or from the associated treatment, they need to be investigated in greater depth. The orofacial region has an impact on the nutrition and hydration of individuals (directly associated with their immunity), in addition to communication and emotional and social representations.

The present case report seeks to guide signs and symptoms related to adult women, in the period immediately after the COVID-19 treatment and that presented oral manifestations, related to pain

and difficulty in fluid intake, taste, food intake and oral hygiene, emphasizing the behaviors adopted and the results achieved, three days after the recommendations and during the first week of control.

### Case Report

There was the prior signature of a Free and Informed Consent Term by the patient in question for the description of this clinical case.

A 33 years-old white female, married and with children sought assistance at the Hospital Universitário de Referência, in the city of Recife, northeast of Brazil. She was diagnosed with COVID-19, but presented moderate symptoms, with fever of 39°C, respiratory difficulty (saturation in 94%), episodes of diarrhea and dry cough.

She did not presented comorbidities (besides chronic asthma) and having taken the flu vaccine, an antipyretic, antibiotic and drugs to fight infections by parasites were prescribed. The patient in question made regular use of spray for the regular control and prevention of bronchial spasm associated with the prevention of asthma crisis.

The above-mentioned approach occurred in Phase 1 and for a period of five days, and there was no evidence of a differentiated pulmonary aspect with opacities in frosted glass when the chest was examined [4].

Fifteen days after diagnostic confirmation for COVID-19 the patient began with episodes of spontaneous gingival bleeding in the anterior lower sextant, changes in the coloring of the dorsum of the tongue (with transient lingual papillitis and mouth burning), complaints about sensitivity and changes in taste, during the ingestion of liquid and food.

Findings from literature about oral signs and symptoms of COVID-19 include: alteration, oral blister and ulcers, and oral lesions associated with Kawasaki-like diseases (erythema, bleeding of lips, "strawberry tongue"). The higher expression of Angiotensin-converting enzyme 2 in the oral cavity and in endothelial cells might be responsible for oral manifestation and the major report of signs and symptoms in the occidental countries [5].

As the patient in question did not receive any orientation as to oral hygiene, this approach was proceeded, with the inclusion of tongue cleaner, cheeks with oxygen peroxide and the reinforce-

ment in the vitamin C ingestion. The patient was referred to the supragingival scraping procedures of the anterior lower sextante.

Figure A shows the initial appearance of the tongue. In figures B and C, the tongue and the region of the periodontium, three days after the orientations. The initial image of the spontaneous bleeding of the gums did not get a good resolution.

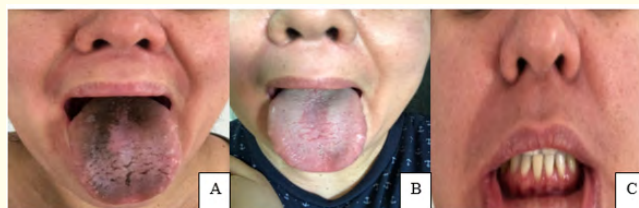


Figure 1

Despite the improvement in the complaints and oral conditions of the patient, after three days, there was a follow-up sequence in the first seven days, fifteen days, thirty days and, subsequently, in the subsequent three months. It should be noted that the option for oxygen peroxide, in addition to its properties, occurred due to complaints involving the taste and burning mouth. Tongue coloration may also be associated with the use of regular firecrackers in many asthmatic individuals. It should also be noted that all orientation occurred with the endorsement of the medical team. So far, no other changes have been observed related to the referral of this patient.

### Final Considerations

Complaints related to staining and tenderness on the tongue, as well as spontaneous gingival bleeding, were resolved over a three-day period, with simple guidelines and procedures. The participation of the oral health team, together with other health professionals, is reinforced in order to contribute with the integrality of the attention and quality of life of the population affected by COVID-19.

### Bibliography

1. Sinadinos A and Shewswell J. "Oral ulceration and blistering in patients with COVID-19". *Evidence-Based Dentistry* 21.2 (2020): 49.
2. Baghizadeh Fini M. "Oral saliva and COVID-19". *Oral Oncology* 108 (2020): 104821.

3. Dziedzic A and Wojtyczka R. "The impact of coronavirus infectious disease 19 (COVID-19) on oral health". *Oral Disease* (2020).
4. Tian S., et al. "Pulmonary Pathology of Early-Phase 2019 Novel Coronavirus (COVID-19) Pneumonia in Two Patients With Lung Cancer". *Journal of Thoracic Oncology* 15.5 (2020): 700-704.
5. Al-Khatib A. "Oral manifestations in COVID-19 patients". *Oral Disease* (2020).
6. Ansari R., et al. "Oral cavity lesions as a manifestation of the novel virus (COVID-19)". *Oral Disease* (2020).

#### Assets from publication with us

- Prompt Acknowledgement after receiving the article
- Thorough Double blinded peer review
- Rapid Publication
- Issue of Publication Certificate
- High visibility of your Published work

**Website:** [www.actascientific.com/](http://www.actascientific.com/)

**Submit Article:** [www.actascientific.com/submission.php](http://www.actascientific.com/submission.php)

**Email us:** [editor@actascientific.com](mailto:editor@actascientific.com)

**Contact us:** +91 9182824667