



**Karolinska  
Institutet**

Karolinska Institutet

<http://openarchive.ki.se>

---

This is a Peer Reviewed Accepted version of the following article, accepted for publication in *Pediatric transplantation*.

2022-03-28

# Contrast-Enhanced Ultrasound for identifying circulatory complications after liver transplants in children

Torres, Alvaro; Koskinen, Seppo K; Gjertsen, Henrik; Fischler, Björn

---

*Pediatr Transplant*. 2019 Feb;23(1):e13327.

Wiley

<http://doi.org/10.1111/petr.13327>

<http://hdl.handle.net/10616/47970>

*If not otherwise stated by the Publisher's Terms and conditions, the manuscript is deposited under the terms of the Creative Commons Attribution-NonCommercial-NoDerivatives License (<http://creativecommons.org/licenses/by-nc-nd/4.0/>), which permits non-commercial re-use, distribution, and reproduction in any medium, provided the original work is properly cited, and is not altered, transformed, or built upon in any way.*

# Contrast-Enhanced Ultrasound for identifying circulatory complications after liver transplants in children

Alvaro Torres<sup>1,2</sup>, Seppo K Koskinen<sup>1</sup>, Henrik Gjertsen<sup>1,3</sup> and Björn Fischler<sup>1,4</sup>

---

<sup>1</sup> Department of Clinical Science, Intervention and Technology (CLINTEC), Karolinska Institutet, Stockholm, Sweden

<sup>2</sup> Department of Radiology, Karolinska University Hospital, Huddinge Sweden

<sup>3</sup> Department of Transplantation Surgery, Karolinska University Hospital, Huddinge, Sweden

<sup>4</sup> Department of Pediatrics, Karolinska University Hospital, Huddinge, Sweden

Corresponding Author: Alvaro Torres

Karolinska University Hospital, Huddinge, Dept. of Radiology

Stockholm, Sweden

Phone: +46858580000 Email: [alvaro.torres.urzua@ki.se](mailto:alvaro.torres.urzua@ki.se)

Author contribution statement: Drs Torres, Koskinen, Gjertsen and Fischler designed and conducted the study, including data collection and analysis. Dr Torres prepared the manuscript draft with important intellectual input from Drs Koskinen, Gjertsen and Fischler. All authors approved the final manuscript.

List of abbreviations: OLT, Orthotopic liver transplantation; US, Ultrasound; CEUS, Contrast-Enhanced Ultrasound; PPV, Positive Predictive Value; NPV, Negative Predictive Value; ELTR, European Liver Transplant Registry; DD, Diseased Donor; HAT, Hepatic Artery Thrombosis; PVT, Portal Vein Thrombosis; EFSUMB, European Federation of Societies for Ultrasound in Medicine and Biology

## Abstract

Our main goal with this study was to share our off-label experience with CEUS for identifying circulatory complications after liver transplantation in children. 74 CEUS exams performed on 34 pediatric patients who underwent a liver transplant were retrospectively included. 53% of the exams were performed on children 2 yrs. old or younger. 82% of the exams were performed within 30 days from the transplant. 62% of patients were transplanted due to a cholestatic disease, 11% due to a metabolic disease, 8 % were re-transplanted due to graft failure and 19% was due to other conditions. BA was the most common reason for transplantation and represented 38% of patients. 38 % of the transplantations were performed with whole grafts from DD, 40% with split liver grafts, and 22% with left lateral segments from LD. For diagnosing arterial circulatory complications, the PPV was 80 %. For diagnosing portal vein circulatory complications, the PPV was 66.7%. NPV was 100%. In 28% of the exams the examiner could not visualize the normal arterial blood flow without CEUS. CEUS is a non-invasive and safe imaging technique that seems valuable in these patients and further efforts are needed to license its use in the post-transplant setting.<sup>†</sup>

## Keywords

contrast-enhanced ultrasound, paediatric, liver transplant, circulatory complications, off-label

---

<sup>†</sup> Abbreviations: CEUS, contrast-enhanced ultrasound; BA, biliary atresia, DD, deceased donor; LD, living donor; PPV, positive predictive value; NPV, negative predictive value.

## Introduction

Orthotopic liver transplantation (OLT) is life saving for patients with end stage liver disease. Complications can occur at any moment but are most common in the first postoperative weeks. Some of the most feared complication are the vascular complications, such as bleeding, stenosis and thrombosis. They can arise from any of the vascular anastomoses created during surgery and are especially feared in pediatric OLT's as they can have immediate and devastating effects on both patient- and graft survival (1–3)

Ultrasound (US) with Doppler capability is usually the primary imaging technique used by the radiologist for identification of vascular complications - particularly in the early postoperative period due to its portable, fast, non-radioactive and noninvasive nature. It can be used to reveal the parenchymal appearance of the liver graft, the structure of blood vessels and perihepatic conditions. Additionally, Doppler ultrasound can evaluate the hemodynamics including patency, direction, and velocity of the blood flow (4–6)

The diagnostic capabilities of US can be further expanded using an intravenously (i.v) administered microbubble contrast agent. In the post liver transplant setting, contrast-enhanced ultrasound (CEUS) can be used to assess microcirculation and perfusion of the liver graft and facilitates visualization of blood vessels, providing real-time angiographic-like images with high diagnostic accuracy. (4,7–10)

In the adult population, official guidelines and recommendations have been issued for the use of CEUS after transplantation (11). However, sulfur hexafluoride, is except for recently in the US (12), not licensed for use in children (13), and therefore it is used off-label. Nevertheless, as in the adult population, recommendations for the pediatric population are in fact in place (14). A recently published review concludes that CEUS can confidently detect important postoperative complications in the pediatric liver transplantation population (15).

In our institution, it is a standard protocol to have a radiologist perform a bedside Doppler ultrasound within the first 24 postoperative hours. Doppler ultrasound is also the modality of choice when it comes to the outpatient standard follow up exams. Sulfur hexafluoride microbubbles are administered and a CEUS is performed at the discretion of the radiologist.

This retrospective study was conducted to outline our experience regarding the circulatory evaluation of pediatric patients post liver transplantation using sulfur hexafluoride CEUS.

## Materials and Methods

Using the hospital's RIS, we retrieved all records of 10681 exams on patients aged less than 18 years who underwent any US investigation during 2004–2014, at the Department of Radiology, Karolinska University Hospital, Huddinge. We then identified those who underwent an abdominal CEUS using sulfur hexafluoride. Of these, all exams performed on a transplanted liver with “circulatory status” as its primary focus were selected. In addition to the contrast images, all exams included both greyscale imaging as well as color Doppler imaging of the region of interest.

Data regarding patient weight, height, and administered contrast dose were also collected. Sulfur hexafluoride is delivered in 5 mL vials and the recommended standard dose for adults is 2.4 mL. The standard dosage for pediatric patients in our institution is to administer 0.1 mL/kg body weight, up to 24 kg. Patients weighing 24 kg or more are given the full dose of 2.4 mL. When needed, repeated doses were given.

Electronic patient charts were used to verify the indication for the exam, the outcome of the exam and any action taken in response to that outcome.

For calculation of the positive predictive value (PPV) our reference was the transplant surgeon's diagnosis per-operatively since all clinically significant true positive findings result in emergency surgery after the exam. The patient not needing surgery for vascular complications within 30 days from the transplantation served as the reference for calculating the negative predictive value (NPV).

The institutional review board approved this study.

## Results

Between January 1, 2004 and December 31, 2014, 74 CEUS exams with “circulatory status” as its focus were performed on transplanted livers on 34 patients (Table 1). Three of these patients were re-transplanted due to serious complications. Hence, 37 pediatric liver transplantations were studied. The majority of the CEUS exams, 57 (57/74; 77%), were performed within the first 14 days post-transplant, 61 (61/74; 82%) were performed within the first 30 days post-transplant. The majority of the late follow up exams did not require CEUS, but some did, and these represent the remaining 13 (13/74; 18%).

The main indications for the postoperative exams were evaluation of vascular patency and complications, graft perfusion and identification of necrotic areas as well as the evaluation of post-operative complications such as fluid collections suggestive of biliary leak or hemorrhage. It should be noted that a large portion of the exams were performed on very young and small patients (Table 1).

(TABLE 1)

**(FIGURE 1)**

Biliary atresia was the most common cause for transplantation. The relative frequency of the different pre-transplant diagnoses (figure 1) was in proportion with current statistics from the European Liver Transplant Registry (ELTR) (16).

**(TABLE 2)**

As seen in table 2, three of 37 patients (8%) in the “cholestatic condition” group had either an arterial or a portal vein problem. The same was true for one patient (3%) in the “other” group.

The total arterial and portal venous complication rate was 11% (4/37) and 5% (2/37) respectively. Two of the arterial complications were attributed to HAT which represented 5% (2/37). One of the venous complications were due to PVT which represented 3% (1/37). Initially one additional case of arterial complication and one case of portal venous complication was reported on CEUS, but both were considered false positives (see cases 5 & 6 in “Case descriptions”)

## Case descriptions

Four patients had no hepatic arterial circulation. Of these, two also lacked portal vein circulation. Another patient was reported to have no arterial circulation on CEUS but turned out to be a false positive. Furthermore, 1 patient was reported to have reduced portal vein circulation. This case also turned out to be a false positive. Here we present a short description of the specific circumstances around each of these 6 patients.

Case 1: A 9-year-old girl with hepatopulmonary syndrome related to Adams-Oliver syndrome in stable condition preoperatively who received a whole liver from a deceased donor. During surgery the hepatic artery was spastic and arterial flow severely reduced. Portal flow was normal. On the 1<sup>st</sup> postoperative day the routinely performed CEUS reported absent arterial as well as portal vein circulation. The patient went to emergency surgery where the diagnosis of HAT and PVT was confirmed. However, the circulation could not be restored and a transplantectomy had to be performed. The patient was urgently relisted on the transplant list and after a few days was retransplanted.

Case 2: A 1-year old boy with Alagille's syndrome in stable condition preoperatively who received a left lateral segment from a split liver. During surgery both arterial and portal venous circulation was normal, however no bile production was seen during surgery which was a concern. The first postoperative period was relatively uncomplicated and routinely performed US exams including a CEUS on the third postoperative day where all normal. Clinically the patient deteriorated and a HAT was suspected. Therefore, an urgent CEUS exam was requested. On the 5<sup>th</sup> postoperative day the CEUS reported that there was no hepatic arterial circulation. The patient went to emergency surgery where the diagnosis of HAT was confirmed. The liver-graft recovered well after reperfusion preoperatively

Case 3: An 8-month-old girl with biliary atresia in stable condition preoperatively who received a left lateral segment from a living donor. Surgery was complicated by the fact that the portal vein kept becoming obstructed due to recipient portal malformation. Therefore, a venous jumpgraft was used to obtain adequate portal flow. A routine US exam was performed a few hours post-operatively which reported no circulatory abnormalities. Due to clinical deterioration of the patient an urgent CEUS was requested on the first post-operative day. The CEUS reported absent arterial as well as portal vein circulation as well as complete absence of liver perfusion. The patient went to emergency surgery and there the absence of arterial and portal vein flow was confirmed. However, no thrombosis was found. 6 hours later a hepatectomy had to be performed due to complete graft failure and the patient was listed for urgent re-transplantation.

Case 4: A 7-month-old girl with biliary atresia in stable condition preoperatively who received a left lateral segment from a living donor. During the surgery they did not manage to attain adequate arterial circulation but were obligated to accept the situation at the time. The immediate postoperative period was complicated with several medical issues. On the 2<sup>nd</sup> postoperative day the CEUS reported that there still was no hepatic artery circulation. Several US exams were performed before and after the CEUS exam and neither showed intrahepatic arterial circulation. Due to the good hepatic status of the patient, no immediate actions were taken. On the 6<sup>th</sup> postoperative day, due to clinical deterioration of the patient, an urgent US exam was performed where neither arterial, nor portal vein blood flow could be detected. The patient went to emergency surgery where neither

a HAT nor a PVT could be confirmed, nonetheless no circulation could be achieved and complete graft failure was apparent. Consequentially the liver had to be extracted. The patient was urgently re-listed on the transplant list.

Case 5: a 13-year-old boy with Progressive familial intrahepatic cholestasis type 1 in stable condition preoperatively who received a left segment from a living donor. The surgery was without complication. A CEUS on the 1<sup>st</sup> postoperative day showed no circulatory issue. Several routine US exams were performed during the first week post-surgery all of which showed normal circulatory status. On the 8<sup>th</sup> postoperative day a routine CEUS was performed which reported reduced intrahepatic portal blood flow. The same day the patient underwent a multiphase CT of the liver which showed normal portal circulation. The patient did not require surgery and was later discharged from the hospital in good health. This case is considered a false positive.

Case 6: An 8-month-old boy with Alfa-1-antitrypsin deficiency in stable condition preoperatively who received a left lateral segment from a split liver. During surgery, no biliary production was seen but no other complication occurred. The postoperative period was complicated. On the 9<sup>th</sup> postoperative day the patient underwent surgery due to a bile leak. On the 11<sup>th</sup> postoperative day a CEUS reported that there was no intrahepatic arterial circulation. Additionally, the report said that there was a large fluid accumulation adjacent to the liver. The patient went to surgery that same day to explore the reason for the fluid accumulation. No additional bile leak was found and serous fluid was removed. Oddly enough no mention of the circulatory status of the liver graft could be found in the hospital charts and no additional exams were performed to visualize the arterial circulation. Three days later a non-contrast US was performed and no circulatory issue could be found. The patient did not need any further surgery after this. The case was considered a false positive.

## **Positive and negative predictive values**

For diagnosing arterial circulatory complications, the PPV was 80 %, with one false positive result and four true positive results. For diagnosing portal vein circulatory complications, the PPV was 66.7% with one false positive and two true positives. For diagnosing any arterial or portal vein circulatory issue the PPV was 75%. CEUS exams that found perfusion issues only and no other circulatory pathology were not perceived as serious enough and no specific action to correct the finding was deemed necessary from the transplantation surgeons.

The NPV was 100% and no patients without arterial or portal vein circulatory issue on CEUS needed surgery within the first 30 days after transplantation.

### **(TABLE 3)**

As showed in table 3, in 28% of the exams the radiologist could not visualize the normal arterial blood flow without CEUS.



## Discussion

Clearly and accurately visualizing flow or absence thereof, in arteries as thin as 2mm in diameter can be very challenging. However, it is extremely important, especially in the immediate post-operative setting, and the physician in charge of the exam needs all the help she/he can get. If this help comes in a safe, reliable and fast package it is even better. In our experience CEUS fits this description perfectly.

Our study was done with the aim of adding to the growing knowledge regarding the relatively rare pediatric use of CEUS in liver transplantation.

The most common vascular complications after OLT's are hepatic artery thrombosis (HAT) and portal vein thrombosis (PVT). HAT is reported to complicate 0-19% of OLTs and is generally more frequent after pediatric liver transplantation than after adult transplantation (1,2,17–20) PVT complicates 2-17% of OLTs and this complication too is seen more frequently in the pediatric population (1,2,17,19).

Our results suggest a complication rate that is in accordance with these other studies. However, it must be noted that we only have data on patients who performed a CEUS post transplantation, meaning that a potentially significant portion of transplantations are not included in our numbers.

In general, the use of CEUS for post liver transplantation evaluation is documented in a number of original studies and reviews on adult patients. For instance, in one prospective study published in 2006 (4), sensitivity, specificity, and diagnostic accuracy for correctly identifying vascular complications following liver transplantation were 91.3%, 100%, and 91.5%, respectively for Doppler US alone. When performing a CEUS - sensitivity, specificity, and accuracy were all 100%.

Other studies showed that PPV and NPV ranged between 77-92.9% and 99-100 % respectively for hepatic artery complications (6,7). No studies presenting equivalent results for portal vein complications are available. The notion that CEUS is useful in diagnosing vascular complications following liver transplants is in concordance with several other studies where CEUS is shown to surpass conventional US in that regard (6,8,21–25).

As mentioned above, none of the aforementioned studies were performed specifically on pediatric patients. However, the European federation of societies for ultrasound in medicine and biology (EFSUMB) guidelines and recommendations document from 2016 (14) states - "The application of CEUS in the child following transplantation is likely to be similar to the adult, with vascular patency, areas of necrosis, assessment of new focal lesions and the assessment of postoperative complications (e.g. fluid collections) most likely the areas of use".

Our experience so far shows this statement to be valid and our results regarding PPV and NPV for hepatic artery complications using CEUS are in concordance with the adult literature.

Our choice of reference for the calculation of PPV and NPV was a pragmatic one. We defined a true positive as a patient needing surgery for the vascular complication confirmed by the CEUS. On the other hand, a patient not needing surgery within 30 days from the transplant was defined as a true negative. These definitions are in line with the clinical reality of post-transplant evaluation of patients, where relevant CEUS findings, with associated clinical correlation, are acted upon

operatively without any additional diagnostics such as catheter angiography or multiphase contrast CT. Additional diagnostics may be used when the CEUS finding is in discord with the patient's clinical status to confirm or disconfirm the finding.

Although the use of CEUS in children has its place in the post liver-transplantation setting, the off-label status associated with its use, interferes with its wider acceptance. In Sweden and in the rest of Europe none of the available US contrast agents have been licensed for intravenous (i.v) use in children under the age of 18 years. This can sometimes be problematic and cause some apprehension among health care personnel. Notwithstanding, the use of off-label drugs in pediatric practice is well known and widespread (26–28). A recent report from the department of health and food safety of the European Commission (29) provides a comprehensive analysis on the current status of off-label drugs in Europe. They report a prevalence of in-hospital use of off-label drugs in children ranging between 13-69%, depending on the definition of off-label, which specific drugs were studied and the age of the patients.

This report highlights the poor correlation between the actual use of a drug and its licensing status. Pediatricians order these drugs because they are important tools in diagnosing and treating many diseases and symptoms and have proven their place in the care of pediatric patients through gained experience and careful clinical evaluation. Support for the use of CEUS in both adults and in children, in a multitude of settings can also be found in various reports (14,30–35). When considering the alternative imaging options as CT or MRI, CEUS proves to be as safe or safer (36–39).

Diagnostic qualities and safety aside, CEUS exams have been shown to have much shorter exam times in comparison with conventional Doppler US (4,40). This is very important in pediatric radiology, where exam times and patient compliance are directly correlated. A single center study (40) suggested that, aside from being safe and accurate, CEUS avoided a great number of CT and/or MRI exams thus saving the institution money and resources, as well as avoiding the risks associated with above mentioned exams.

The strengths of our study are that we present a relatively large number of patients and that we have detailed information regarding the graft and the recipient through our electronic patient chart. All transplants and postoperative care, as well as follow up of these patients take place in our institution. The limitations of our study, on the other hand, are mainly concerned with the retrospective nature of our study. We have no control of the documentation and no possibility to standardize the examination and reporting.

Our data suggest CEUS to be an efficient, accurate and safe diagnostic method for detecting postoperative vascular complications after liver transplantation in the pediatric population. We especially see its potential use as a “problem solver”, and a viable alternative to other diagnostic methods in inconclusive or difficult cases.

In conclusion, concerted efforts are needed to achieve official licensing in order to facilitate the use of pediatric CEUS.

## REFERENCES

1. Duffy JP, Hong JC, Farmer DG, Ghobrial RM, Yersiz H, Hiatt JR, et al. Vascular Complications of

- Orthotopic Liver Transplantation: Experience in More than 4,200 Patients. *J Am Coll Surg*. 2009 May 1;208(5):896–903.
2. Rather SA, Nayeem MA, Agarwal S, Goyal N, Gupta S. Vascular complications in living donor liver transplantation at a high-volume center: Evolving protocols and trends observed over 10 years. *Liver Transpl*. 2017 Apr 1;23(4):457–64.
  3. Tiao GM, Alonso MH, Ryckman FC. Pediatric liver transplantation. *Semin Pediatr Surg*. 2006 Aug 1;15(3):218–27.
  4. Hom BK, Shrestha R, Palmer SL, Katz MD, Selby RR, Asatryan Z, et al. Prospective Evaluation of Vascular Complications after Liver Transplantation: Comparison of Conventional and Microbubble Contrast-enhanced US. *Radiology*. 2006 Oct 1;241(1):267–74.
  5. Ma L, Lu Q, Luo Y. Vascular complications after adult living donor liver transplantation: Evaluation with ultrasonography. *World J Gastroenterol*. 2016 Jan 28;22(4):1617–26.
  6. Tamsel S, Demirpolat G, Killi R, Aydın U, Kılıç M, Zeytinlu M, et al. Vascular complications after liver transplantation: evaluation with Doppler US. *Abdom Imaging*. 2007 Jun 1;32(3):339–47.
  7. Lu Q, Zhong XF, Huang ZX, Yu BY, Ma BY, Ling WW, et al. Role of contrast-enhanced ultrasound in decision support for diagnosis and treatment of hepatic artery thrombosis after liver transplantation. *Eur J Radiol*. 2012 Mar 1;81(3):338–43.
  8. Luo Y, Fan Y-T, Lu Q, Li B, Wen T-F, Zhang Z-W. CEUS: A new imaging approach for postoperative vascular complications after right-lobe LDLT. *World J Gastroenterol WJG*. 2009 Aug 7;15(29):3670–5.
  9. Ren J, Wu T, Zheng B-W, Tan Y-Y, Zheng R-Q, Chen G-H. Application of contrast-enhanced ultrasound after liver transplantation: Current status and perspectives. *World J Gastroenterol*. 2016 Jan 28;22(4):1607–16.
  10. Teegen, Eva Maria, Timm Denecke, Robert Eisele, Christian Lojewski, Peter Neuhaus, Sascha Santosh Chopra. Clinical application of modern ultrasound techniques after liver transplantation. *Acta Radiol*. 2016 Oct 1;57(10):1161–70.
  11. Claudon M, Dietrich CF, Choi BI, Cosgrove DO, Kudo M, Nolsøe CP, et al. Guidelines and Good Clinical Practice Recommendations for Contrast Enhanced Ultrasound (CEUS) in the Liver – Update 2012: A WFUMB-EFSUMB Initiative in Cooperation with Representatives of AFSUMB, AIUM, ASUM, FLAUS and ICUS. *Ultrasound Med Biol*. 2013 Feb 1;39(2):187–210.
  12. Clinical Pharmacology review for Lumason [Internet]. [cited 2018 Jan 26]. Available from: <http://www.fda.gov/downloads/drugs/developmentapprovalprocess/developmentresources/ucm502146.pdf>
  13. Scientific discussion for the approval of Sonovue [Internet]. [cited 2018 Jan 26]. Available from: [http://www.ema.europa.eu/docs/en\\_GB/document\\_library/EPAR\\_-\\_Scientific\\_Discussion/human/000303/WC500055376.pdf](http://www.ema.europa.eu/docs/en_GB/document_library/EPAR_-_Scientific_Discussion/human/000303/WC500055376.pdf)
  14. Sidhu PS, Cantisani V, Deganello A, Dietrich CF, Duran C, Franke D, et al. Role of Contrast-Enhanced Ultrasound (CEUS) in Paediatric Practice: An EFSUMB Position Statement. *Ultraschall Med - Eur J Ultrasound*. 2017 Jan;38(01):33–43.

15. Rafailidis V, Deganello A, Watson T, Sidhu PS, Sellars ME. Enhancing the role of paediatric ultrasound with microbubbles: a review of intravenous applications. *Br J Radiol.* 2016 Sep 26;90(1069):20160556.
16. Pediatric transplantation - European Liver Transplant Registry - ELTR [Internet]. [cited 2018 Jan 22]. Available from: <http://www.eltr.org/Pediatric-transplantation.html>
17. Alobaidi R, Anton N, Cave D, Moez EK, Joffe AR. Predicting early outcomes of liver transplantation in young children: The EARLY study. *World J Hepatol.* 2018 Jan 27;10(1):62–72.
18. Bekker J, Ploem S, De Jong KP. Early Hepatic Artery Thrombosis after Liver Transplantation: A Systematic Review of the Incidence, Outcome and Risk Factors. *Am J Transplant.* 2009 Apr 1;9(4):746–57.
19. Piardi T, Lhuire M, Bruno O, Memeo R, Pessaux P, Kianmanesh R, et al. Vascular complications following liver transplantation: A literature review of advances in 2015. *World J Hepatol.* 2016 Jan 8;8(1):36–57.
20. Seda-Neto J, Antunes da Fonseca E, Pugliese R, Candido HL, Benavides MR, Carballo Afonso R, et al. Twenty Years of Experience in Pediatric Living Donor Liver Transplantation: Focus on Hepatic Artery Reconstruction, Complications, and Outcomes. *Transplantation.* 2016 May;100(5):1066–72.
21. Clevert D-A, Stickel M, Minaifar N, Löhe F, Graeb C, Jauch KW, et al. Contrast-enhanced ultrasound in liver transplant: First results and potential for complications in the postoperative period. *Clin Hemorheol Microcirc.* 2009 Jan 1;43(1–2):83–94.
22. García-Criado Á, Gilabert R, Bianchi L, Vilana R, Burrel M, Barrufet M, et al. Impact of contrast-enhanced ultrasound in the study of hepatic artery hypoperfusion shortly after liver transplantation: contribution to the diagnosis of artery steal syndrome. *Eur Radiol.* 2015 Jan 1;25(1):196–202.
23. Rennert J, Dornia C, Georgieva M, Roehrl S, Fellner C, Schleder S, et al. Identification of early complications following liver transplantation using contrast enhanced ultrasound (CEUS). First results. *J Gastrointest Liver Dis JGLD.* 2012 Dec;21(4):407–12.
24. Rossi S, Rosa L, Ravetta V, Cascina A, Quaretti P, Azzaretti A, et al. Contrast-Enhanced Versus Conventional and Color Doppler Sonography for the Detection of Thrombosis of the Portal and Hepatic Venous Systems. *Am J Roentgenol.* 2006 Mar 1;186(3):763–73.
25. Sidhu PS, Shaw AS, Ellis SM, Karani JB, Ryan SM. Microbubble ultrasound contrast in the assessment of hepatic artery patency following liver transplantation: role in reducing frequency of hepatic artery arteriography. *Eur Radiol.* 2004 Jan 1;14(1):21–30.
26. Conroy S, Choonara I, Impicciatore P, Mohn A, Arnell H, Rane A, et al. Survey of unlicensed and off label drug use in paediatric wards in European countries. *BMJ.* 2000 Jan 8;320(7227):79–82.
27. Pandolfini C, Bonati M. A literature review on off-label drug use in children. *Eur J Pediatr.* 2005 Sep 1;164(9):552–8.
28. Sachs AN, Avant D, Lee CS, Rodriguez W, Murphy MD. Pediatric Information in Drug Product Labeling. *JAMA.* 2012 May 9;307(18):1914–5.

29. Weda M, Hoebert J, Vervloet M, Moltó Puigmarti C. Study on off-label use of medicinal products in the European Union [Internet]. European Commission Department of Health and Food Safety; 2017 [cited 2018 Jan 25]. Available from: [https://ec.europa.eu/health/sites/health/files/files/documents/2017\\_02\\_28\\_final\\_study\\_report\\_on\\_off-label\\_use\\_.pdf](https://ec.europa.eu/health/sites/health/files/files/documents/2017_02_28_final_study_report_on_off-label_use_.pdf)
30. Darge K, Papadopoulou F, Ntoulia A, Bulas DI, Coley BD, Fordham LA, et al. Safety of contrast-enhanced ultrasound in children for non-cardiac applications: a review by the Society for Pediatric Radiology (SPR) and the International Contrast Ultrasound Society (ICUS). *Pediatr Radiol*. 2013 Sep 1;43(9):1063–73.
31. Ntoulia A, Anupindi SA, Darge K, Back SJ. Applications of contrast-enhanced ultrasound in the pediatric abdomen. *Abdom Radiol*. 2017 Oct 4;1–12.
32. Piscaglia F, Nolsøe C, Dietrich CF, Cosgrove DO, Gilja OH, Nielsen MB, et al. The EFSUMB Guidelines and Recommendations on the Clinical Practice of Contrast Enhanced Ultrasound (CEUS): Update 2011 on non-hepatic applications. *Ultraschall Med - Eur J Ultrasound*. 2012 Feb;33(01):33–59.
33. Piscaglia F, Bolondi L. The safety of Sonovue® in abdominal applications: Retrospective analysis of 23188 investigations. *Ultrasound Med Biol*. 2006 Sep 1;32(9):1369–75.
34. Rosado E, Riccabona M. Off-Label Use of Ultrasound Contrast Agents for Intravenous Applications in Children. *J Ultrasound Med*. 2016 Mar 1;35(3):487–96.
35. Torres A, Koskinen SK, Gjertsen H, Fischler B. Contrast-enhanced ultrasound using sulfur hexafluoride is safe in the pediatric setting. *Acta Radiol*. 2017 Nov 1;58(11):1395–9.
36. Brenner DJ, Elliston CD, Hall EJ, Berdon WE. Estimated Risks of Radiation-Induced Fatal Cancer from Pediatric CT. *Am J Roentgenol*. 2001 Feb 1;176(2):289–96.
37. Dillman JR, Strouse PJ, Ellis JH, Cohan RH, Jan SC. Incidence and Severity of Acute Allergic-Like Reactions to IV Nonionic Iodinated Contrast Material in Children. *Am J Roentgenol*. 2007 Jun 1;188(6):1643–7.
38. Karcaaltincaba M, Oguz B, Haliloglu M. Current status of contrast-induced nephropathy and nephrogenic systemic fibrosis in children. *Pediatr Radiol*. 2009 Jun 1;39(3):382–4.
39. Pearce MS, Salotti JA, Little MP, McHugh K, Lee C, Kim KP, et al. Radiation exposure from CT scans in childhood and subsequent risk of leukaemia and brain tumours: a retrospective cohort study. *The Lancet*. 2012 Aug 4;380(9840):499–505.
40. Yusuf GT, Sellars ME, Deganello A, Cosgrove DO, Sidhu PS. Retrospective Analysis of the Safety and Cost Implications of Pediatric Contrast-Enhanced Ultrasound at a Single Center. *Am J Roentgenol*. 2016 Dec 13;208(2):446–52.

## Figure Legends

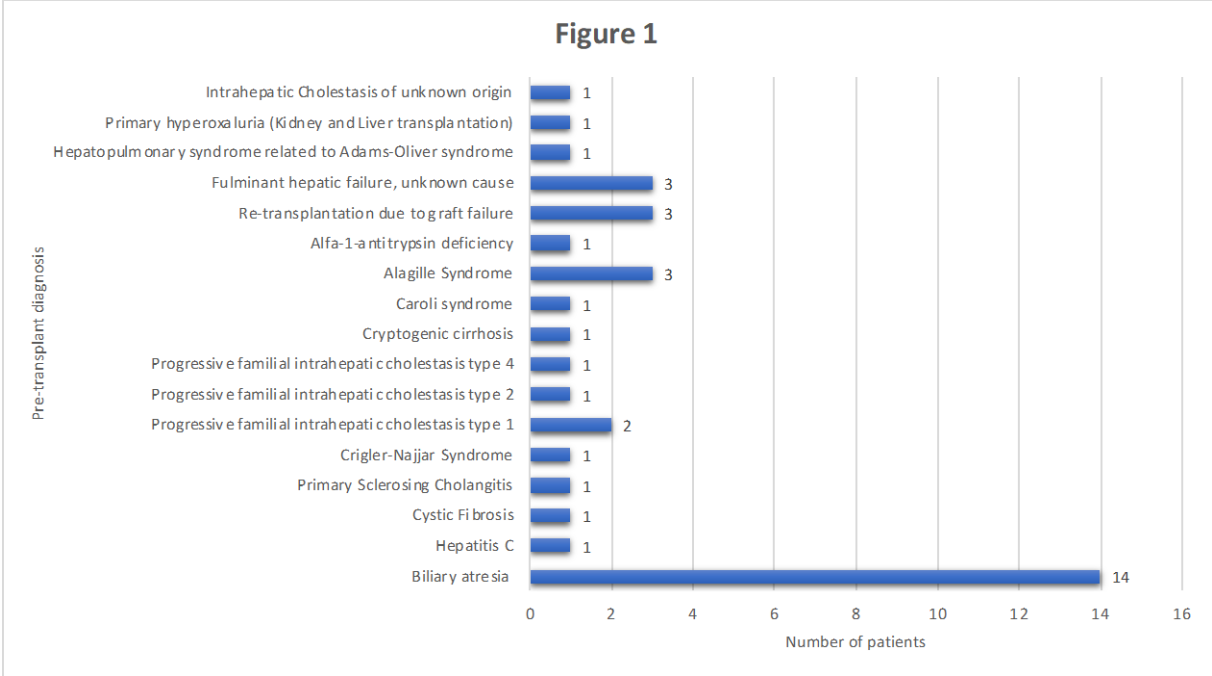
Figure 1. † Cause for liver disease leading to transplantation presented by frequency.

Table 1. Anthropometric data for performed exams, sorted and grouped by patients age. †

Age (Years)	0.0-1.0	1.1-2.0	2.1-7.0	7.1-12.0	12.1-17.9
Number of exams	28 (38%)	11 (15%)	10 (13%)	6 (8%)	19 (26%)
Age Average (Yrs)	0.8	1.5	4.4	9.3	14.4
Age Median (Yrs)	0.8	1.3	4.1	9.1	13.8
Age Range (yrs)	0.6 - 1.0	1.2-1.9	2.8-6.8	8.8-10.0	12.6-17.1
Female	17 (61%)	6 (55%)	3 (30%)	3 (50%)	7 (37%)
Male	11 (39%)	5 (45%)	7 (70%)	3 (50%)	12 (63%)
Height Average (cm)	66.3 (n=25)	78.3 (n=11)	95.1 (n=10)	137.5 (n=6)	156.8 (n=19)
Height Median (cm)	66 (n=25)	78 (n=11)	90 (n=10)	138 (n=6)	155 (n=19)
Height Range (cm)	63-73 (n=25)	76-83 (n=11)	83-124 (n=10)	114-150 (n=6)	124-175 (n=19)
Weight Average (Kg)	7.8 (n=25)	10.5 (n=11)	14.7 (n=10)	34.0 (n=6)	47.4 (n=19)
Weight Median (Kg)	8 (n=25)	11 (n=11)	13 (n=10)	38 (n=6)	45 (n=19)
Weight Range(Kg)	6-10 (n=25)	9-13 (n=11)	11-23 (n=10)	22-41 (n=6)	27-72 (n=19)
Dose Average (ml)	0.5 (n=18)	0.81 (n=9)	0.84 (n=7)	2 (n=3)	56.8 (n=17)
Dose Median (ml)	0.35 (n=18)	1 (n=9)	1 (n=7)	2.4 (n=3)	2.4 (n=17)
Dose Range (ml)	0.2 -2.0 (n=18)	0.4-1.1 (n=9)	0.3-1.3 (n=7)	1.2-2.4 (n=3)	1.2-5 (n=17)

† Number of data points available for calculation are presented as (n=x). Variations in these numbers are due to missing data.

Figure 1 – Pre-transplant diagnosis per patient<sup>†</sup>.



<sup>†</sup> Cause for liver disease leading to transplantation presented by frequency.



Table 2- Cause for transplantation in relation to transplantation technique and in relation to confirmed vascular complications within 30 days from surgery.

Cause for transplantation		Cholestatic condition †	Metabolic Disease ‡	Re-transplantation due to graft failure	Other §
<b>No. of patients</b>	37 total	23 (62%)	4 (11%)	3 (8%)	7 (19%)
<b>Transplantation technique</b>	Diseased Donor (DD), split liver	10 (44%)	2 (50%)	0	3 (43%)
	DD, whole liver	7 (30%)	2 (50%)	1 (33%)	4 (57%)
	Living Donor (left lateral segment)	6 (26%)	0	2 (67%)	0
<b>Circulatory status</b>	No circulatory problem	17 (74%)	4 (100%)	2 (67%)	6 (86%)
	Arterial problem	2 <sup>1</sup> (9%)	0	0	0
	Arterial and portal vein problem	1 (4%)	0	0	1 (14%)
	Portal vein problem	0	0	0	0
	Perfusion problem	4 <sup>1</sup> (17%)	0	1 (33%)	0

<sup>1</sup> One patient had both an arterial and perfusion problem.

†Biliary Atresia, Alagille syndrome, Primary sclerosing cholangitis, Progressive Familial Intrahepatic Cholestasis, Intrahepatic cholestasis of unknown origin, ‡Alfa-1- antitrypsin deficiency, Cystic Fibrosis, Primary hyperoxaluria, Crigler-Najjar syndrome, §Caroli syndrome, Cryptogenic cirrhosis, Fulminant hepatic failure, Hepatitis C, Hepatopulmonary syndrome related to Adams-Oliver syndrome

Table 3- Added diagnostic value of CEUS (per exam)

Diagnostic value of CEUS	N - number of exams
No added value other than visualization of perfusion	46 (62%)
CEUS required for visualization of normal hepatic artery blood flow	21 (28%)
CEUS required for visualization of normal portal vein blood flow.	3 (4%)
CEUS used for verification of absent arterial and/or portal blood flow	4 (5%)