

2-2-2022

Novel Approaches to Coronary Perforations: Everything But the Kitchen Sink.

Dany Jacob

Michael P Savage

David L Fischman

Follow this and additional works at: <https://jdc.jefferson.edu/cardiologyp>



Part of the [Cardiology Commons](#)

[Let us know how access to this document benefits you](#)

This Article is brought to you for free and open access by the Jefferson Digital Commons. The Jefferson Digital Commons is a service of Thomas Jefferson University's [Center for Teaching and Learning \(CTL\)](#). The Commons is a showcase for Jefferson books and journals, peer-reviewed scholarly publications, unique historical collections from the University archives, and teaching tools. The Jefferson Digital Commons allows researchers and interested readers anywhere in the world to learn about and keep up to date with Jefferson scholarship. This article has been accepted for inclusion in Division of Cardiology Faculty Papers by an authorized administrator of the Jefferson Digital Commons. For more information, please contact: JeffersonDigitalCommons@jefferson.edu.

EDITORIAL COMMENT

Novel Approaches to Coronary Perforations



Everything But the Kitchen Sink

Dany Jacob, MD,^a Michael P. Savage, MD,^b David L. Fischman, MD^b

Although major complications rarely occur during percutaneous coronary interventions (PCI), they can be associated with increased in-hospital mortality and major adverse cardiac events.^{1,2} Coronary artery perforation is one of the major complications that can occur in 0.29%-0.71% of cases.³ The incidence increases to 8.9% with complex PCI, particularly chronic total occlusion (CTO) PCI, despite contemporary strategies.⁴ Coronary artery perforation is associated with a 5-fold increase in in-hospital mortality (10% to 15%) because it can lead to cardiac tamponade and hemodynamic compromise.^{3,5,6}

Coronary artery perforation can be classified by anatomy and severity. Anatomically, it is divided into 3 distinct categories: large vessel, distal vessel/branch vessel, and collaterals.⁷ Common causes of large-vessel perforation include the following: the use of atherectomy devices, particularly in an angled segment; oversized balloon or stent; high inflation pressures in calcified lesion; and balloon rupture.⁷ Distal vessel perforation is often the result of distal wire migration, particularly when a polymer-jacketed guidewire is used; this has been associated with 90% of distal coronary perforations.^{8,9} Collateral perforation can occur during retrograde CTO PCI.

The severity of coronary artery perforation is graded with the Ellis classification.¹⁰ The classification ranges gradually from type 1 (minor) to type III (frank perforation), which is more often associated with cardiac tamponade, hemodynamic compromise, and death. A contemporary analysis revealed that in addition to proximal vessel perforation, “cloud-like” and “floating” patterns of perforations are associated with poor clinical outcomes for perforations occurring during CTO PCI.⁴

In the event of a type III coronary artery perforation, the interventional cardiologist should use a systematic algorithmic approach (**Figure 1**). The first step involves inflating a balloon proximal to the vessel perforation to reduce extravasation of blood in the pericardium and to reduce the risk of cardiac tamponade. If hemodynamic compromise occurs, it is recommended that the patient's condition be stabilized with intravenous fluids, vasopressors, mechanical circulatory support, and the support from other PCI operators.¹¹

Main vessel perforation is usually treated with a covered stent if prolonged balloon tamponade fails. This can be accomplished with 1 large guiding catheter while a blocking balloon is in place, or through a “ping-pong” technique with 2 catheters if a single guiding catheter is insufficient to accommodate a covered stent with a balloon.¹¹

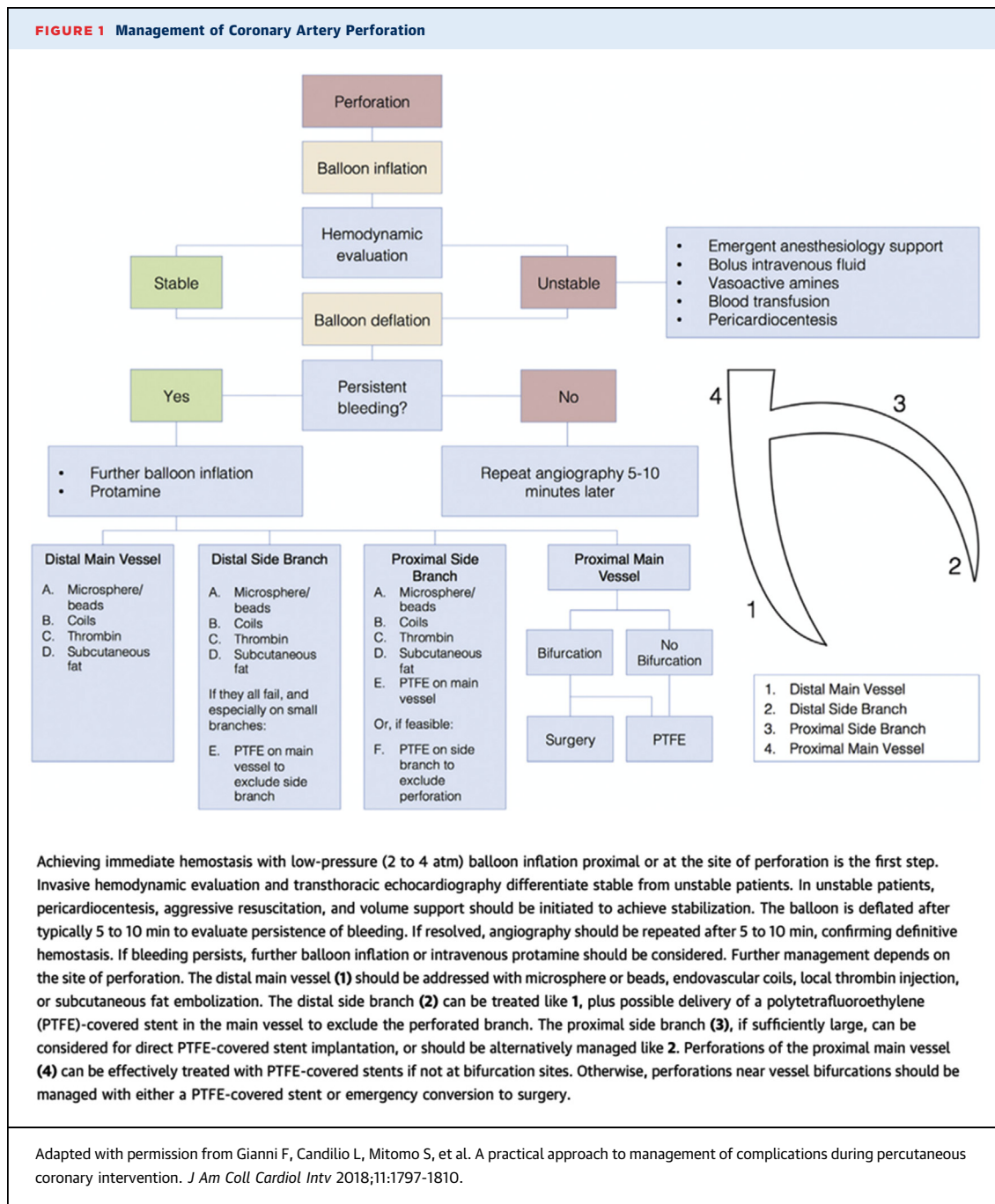
Distal vessel perforation can also be treated with prolonged balloon inflation. However, in cases where prolonged balloon inflation fails, embolization with various materials, such as coils, subcutaneous fat, thrombin, autologous blood clots, gelatin sponge, polyvinyl alcohol particles, and microspheres, can be performed.⁷ Embolization of these materials creates a blood clot that seals the perforation and stops the bleeding.

From the ^aDivision of Cardiology, Saint Luke's Mid America Heart Institute, Kansas City, Missouri, USA; and the ^bDivision of Cardiology, Department of Medicine, Thomas Jefferson University Hospital, Philadelphia, Pennsylvania, USA.

The authors attest they are in compliance with human studies committees and animal welfare regulations of the authors' institutions and Food and Drug Administration guidelines, including patient consent where appropriate. For more information, visit the [Author Center](#).

In this issue of *JACC: Case Reports*, Al-Omary et al¹² and Alavi et al¹³ report a less familiar technique to treat distal coronary perforation, contributing to the “everything but the kitchen sink” approach to address this complication. In 1 case, a distal posterior descending artery perforation was successfully sealed with 2 distal balloon fragments. Owing to the lack of availability of more common materials, the authors innovatively snipped the distal end of a used balloon

and loaded it on the guidewire. The balloon fragment was then advanced with another balloon loaded on the wire, proximal to the balloon fragment. Once the fragment reached the distal portion of the vessel, the guidewire was withdrawn, leaving the balloon fragment in place and successfully sealing the perforation. Al-Omary et al¹² report a case series of distal vessel perforations that were successfully treated with embolized absorbable suture. An absorbable



Vicryl suture was cut into small fragments 5-6 mm long, followed by insertion of these fragments into a microcatheter. The suture fragments were then advanced by inserting a workhorse wire into a microcatheter and pushing the fragments out to the desired location to successfully seal the perforation. Both techniques were effective in treating the distal vessel perforation, can be cheaper alternatives to other well-known strategies, and are available to operators when more expensive materials are not available.

Snipping the distal end of the balloon and using it to seal distal vessel perforation has been previously described in the literature.^{14,15} Among the few reported cases, no adverse events were observed. However, caution must be exercised when using this method. If the vessel being treated is tortuous or when severe proximal atherosclerosis is present, the operator may be unable to advance the balloon fragment resulting in proximal vessel occlusion. The embolization of suture material has also been reported in previous publications.¹⁶ In the few cases that have been reported, there have been no issues with advancing the snipped suture. Although the authors did report that they had difficulty advancing the suture in the microcatheter in 1 case, it was circumvented with guidewire torque. The potential for coronary recanalization with absorbable sutures is an

interesting phenomenon of unknown clinical significance. Importantly, the natural biologic inflammatory stimulus of the embolized balloon fragment or absorbable sutures is unknown. Whether recanalization can occur and its longer-term clinical significance are yet to be determined.¹⁷

Treatment of distal coronary artery perforation should be performed in an algorithmic fashion. As demonstrated, embolization of the distal balloon fragment and absorbable sutures seem to be reasonable alternative strategies in the appropriate anatomy. Given that the most common cause of distal vessel perforation is guidewire migration in a distal small caliber branch, meticulous constant attention to the guidewire is of paramount importance. As the old adage goes, “an ounce of prevention is worth a pound of cure.”

FUNDING SUPPORT AND AUTHOR DISCLOSURES

The authors have reported that they have no relationships relevant to the contents of this paper to disclose.

ADDRESS FOR CORRESPONDENCE: Dr David L. Fischman, Jefferson Angioplasty Center, 111 South 11th Street, Suite 6210, Philadelphia, Pennsylvania, 19107, USA. E-mail: david.fischman@jefferson.edu. Twitter: [@fischman_david](https://twitter.com/fischman_david).

REFERENCES

- Bauer T, Boeder N, Nef HM, et al. Fate of patients with coronary perforation complicating percutaneous coronary intervention (from the Euro Heart Survey Percutaneous Coronary Intervention Registry). *Am J Cardiol*. 2015;116:1363-1367.
- Riley RF, Sapontis J, Kirtane AJ, et al. Prevalence, predictors, and health status implications of periprocedural complications during coronary chronic total occlusion angioplasty. *Euro-Intervention*. 2018;14:e1199-e1206.
- Shaukat A, Tajti P, Sandoval Y, et al. Incidence, predictors, management and outcomes of coronary perforations. *Cath Cardiovasc Interv*. 2019;93:48-56.
- Hirai T, Nicholson WJ, Sapontis J, et al. A detailed analysis of perforations during chronic total occlusion angioplasty. *J Am Coll Cardiol Interv*. 2019;12:1902-1912.
- Parsh J, Seth M, Green J, et al. Coronary artery perforations after contemporary percutaneous coronary interventions: Evaluation of incidence, risk factors, outcomes, and predictors of mortality. *Cath Cardiovasc Interv*. 2017;89:966-973.
- Sapontis J, Salisbury AC, Yeh RW, et al. Early procedural and health status outcomes after chronic total occlusion angioplasty: a report from the OPEN-CTO Registry (Outcomes, Patient Health Status, and Efficiency in Chronic Total Occlusion Hybrid Procedures). *J Am Coll Cardiol Interv*. 2017;10:1523-1534.
- Abdulwahab A, Farag M, Brilakis ES, Galassi AR, Egred M. Management of coronary artery perforation. *Cardiovasc Revasc Med*. 2021;26:55-60.
- Kiernan TJ, Yan BP, Ruggiero N, et al. Coronary artery perforations in the contemporary interventional era. *J Interv Cardiol*. 2009;22:350-353.
- Teis A, Fernandez-Nofrerias E, Rodriguez-Leor O, et al. Coronary artery perforation by intracoronary guide wires: risk factors and clinical outcomes. *Rev Esp Cardiol*. 2010;63:730-734.
- Ellis SG, Ajluni S, Arnold AZ, et al. Increased coronary perforation in the new device era. Incidence, classification, management, and outcome. *Circulation*. 1994;90:2725-2730.
- Doll JA, Hira RS, Kearney KE, et al. Management of percutaneous coronary intervention complications: algorithms from the 2018 and 2019 Seattle Percutaneous Coronary Intervention Complications Conference. *Circ Cardiovasc Interv*. 2020;13:e008962.
- Al-Omary MS, Collins NJ, Sung JG, et al. Absorbable suture embolization in distal coronary perforation. *J Am Coll Cardiol Case Rep*. 2022;4:133-136.
- Alavi SH, Hassanzadeh M, Dehghani P, Namdar ZM, Aslani A. A novel technique for managing guidewire-induced distal coronary perforation using coronary balloon pieces. *J Am Coll Cardiol Case Rep*. 2022;4:137-141.
- Egred AACMMFM. Novel economic treatment for coronary wire perforation: a case report. *World J Cardiol*. 2021;13:177-182.
- Zieba GSB. Balloon fragment technique used to close distal coronary vessel perforation. *J Invasive Cardiol*. 2020;32:E370-E372.
- Li Y, Wang G, Sheng L, et al. Silk suture embolization for sealing distal coronary artery perforation: report of two cases. *Rev Cardiovasc Med*. 2015;16:165-169.
- Kawano H, Arakawa S, Satoh O, Matsumoto Y, Hayano M, Miyabara S. Foreign body granulomatous change from absorbable gelatin sponge and microcoil embolization after a guidewire-induced perforation in the distal coronary artery. *Intern Med*. 2010;49:1871-1874.

KEY WORDS complication, coronary angiography, percutaneous coronary intervention, treatment