

3-4-2022

Association of chronic central serous chorioretinopathy with subclinical Cushing's syndrome.

Rebecca Russ Soares

Annika Samuelson

Allen Chiang


Follow this and additional works at: <https://jdc.jefferson.edu/willsfp>



Part of the [Ophthalmology Commons](#), and the [Surgery Commons](#)

[Let us know how access to this document benefits you](#)

This Article is brought to you for free and open access by the Jefferson Digital Commons. The Jefferson Digital Commons is a service of Thomas Jefferson University's [Center for Teaching and Learning \(CTL\)](#). The Commons is a showcase for Jefferson books and journals, peer-reviewed scholarly publications, unique historical collections from the University archives, and teaching tools. The Jefferson Digital Commons allows researchers and interested readers anywhere in the world to learn about and keep up to date with Jefferson scholarship. This article has been accepted for inclusion in Wills Eye Hospital Papers by an authorized administrator of the Jefferson Digital Commons. For more information, please contact: JeffersonDigitalCommons@jefferson.edu.



Association of chronic central serous chorioretinopathy with subclinical Cushing's syndrome

Rebecca Russ Soares^a, Annika Samuelson^b, Allen Chiang^{a,*}

^a Retina Service, Wills Eye Hospital, Philadelphia, PA, USA

^b Sidney Kimmel Medical College, Thomas Jefferson University, Philadelphia, PA, USA

ARTICLE INFO

Keywords:

Central serous chorioretinopathy
Subclinical Cushing's syndrome
Hypercortisolism
Adrenalectomy
Retina
Surgical intervention

ABSTRACT

Purpose: To report the clinical course of a patient with central serous chorioretinopathy (CSCR) secondary to subclinical hypercortisolism before and after adrenalectomy.

Observations: A 50-year-old female patient with multifocal, chronic CSCR was found to have an adrenal incidentaloma and was diagnosed with subclinical hypercortisolism. Patient elected to undergo minimally-invasive adrenalectomy and presented at 3 months after surgery without subretinal fluid.

Conclusions and Importance: Subclinical Cushing's Syndrome (SCS) may present an underrecognized risk factor for developing chronic CSCR. Further investigation is needed to determine the threshold of visual comorbidity that may influence surgical management.

1. Introduction

Central serous chorioretinopathy (CSCR) is characterized by accumulation of fluid in the subretinal or sub-RPE space, often with consequential visual impairment. Chronic CSCR has been reported as a manifestation of hypercortisolism due to Cushing's syndrome and subclinical hypercortisolism.^{1,2} However, the latter is often underrecognized owing to its inherently subtle nature and the optimal threshold for intervention based on associated comorbidities remains unclear. Herein we report the clinical course of a patient with CSCR secondary to subclinical hypercortisolism before and after adrenalectomy.

2. Case report

A 50-year-old female presented with blurred, discolored spots in the right eye for several months. Her past medical history included mild hypertension treated with amlodipine. Past ocular and family history were noncontributory.

On exam, Snellen visual acuity was 20/50 OD, 20/25 OS. Her pupils, intraocular pressure, and anterior segment exam were within normal limits. Dilated fundus exam revealed bilateral, multifocal areas of subretinal fluid and mottled pigmentary changes (Fig. 1A). Optical coherence tomography confirmed areas of subretinal fluid and other areas of outer retinal atrophy (Fig. 1B). Fundus autofluorescence revealed areas

of hyperautofluorescence that highlighted the fundoscopic findings (Fig. 1C). Fluorescein angiography showed multifocal areas of expansile dot leakage (Fig. 1D). Altogether these findings were consistent with multifocal, chronic CSCR.

On further clinical follow-up, an adrenal incidentaloma (AI) was detected when the patient underwent imaging for back pain. Subsequently she saw an endocrinologist; she had a normal serum cortisol, but low ACTH and an abnormal dexamethasone suppression test. This led to a diagnosis of subclinical hypercortisolism and provided a reason for her hypertension and chronic CSCR.

Since the blur and relative scotomata interfered with her daily activities, she elected to try eplerenone, which yielded a moderate but suboptimal therapeutic response at 50 mg daily. While contemplating photodynamic therapy, in discussion with her endocrinologist, the patient opted to undergo minimally-invasive adrenalectomy. At last follow-up 3 months after surgery and 6 years after her initial presentation, she has been off eplerenone and without subretinal fluid (Fig. 2).

3. Discussion

CSCR has previously been associated with many risk factors including exposure to excess steroid. A recent study analyzing a nationally representative dataset of 35,000 patients found that patients with CSCR had a higher odds of Cushing's syndrome (OR 2.19, 95% CI

* Corresponding author. Wills Eye Hospital, Mid Atlantic Retina, Thomas Jefferson University, 840 Walnut Street, Suite 1020, Philadelphia, PA, 19107, USA.

E-mail address: achiang@midatlanticretina.com (A. Chiang).

<https://doi.org/10.1016/j.ajoc.2022.101455>

Received 6 June 2021; Received in revised form 14 February 2022; Accepted 22 February 2022

Available online 4 March 2022

2451-9936/© 2022 Published by Elsevier Inc. This is an open access article under the CC BY-NC-ND license (<http://creativecommons.org/licenses/by-nc-nd/4.0/>).

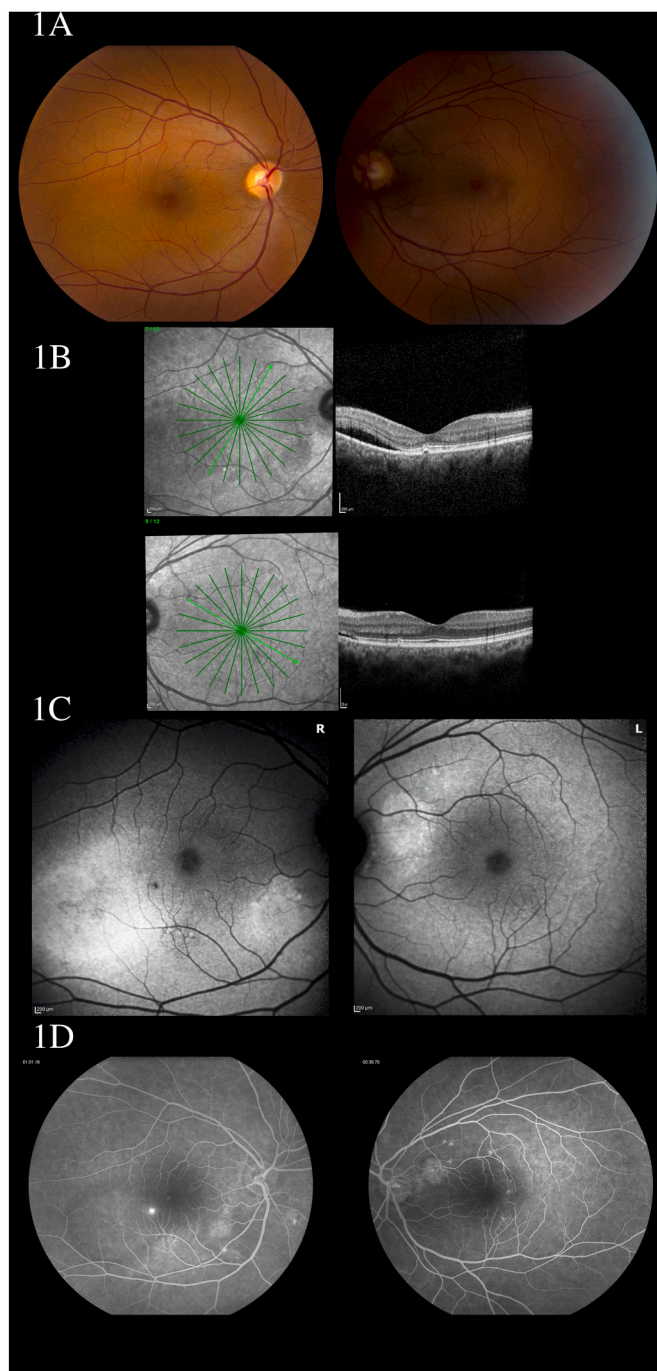


Fig. 1. Multimodal imaging of bilateral multifocal central serous chorioretinopathy. Fundus photographs reveal multifocal subretinal fluid and pigmentary changes (Fig. 1A). Optical coherence tomography demonstrates subretinal fluid and outer retinal atrophy (Fig. 1B). Areas of hyperautofluorescence highlight the fundoscopic findings of subretinal fluid (Fig. 1C). Fluorescein angiography showing multiple areas of expansile dot leakage (Fig. 1D).

1.33 to 3.59, $p = 0.002$) than exposure to exogenous steroids (OR 1.14, 95% CI 1.09 to 1.19, $p < 0.001$).¹ Our case highlights the importance of thorough medication reconciliation and careful consideration of comorbid conditions in patients with chronic CSCR.

In recent years, subtle endogenous hypercortisolism, termed subclinical Cushing's syndrome (SCS), has been of particular interest in the endocrinology literature because it can be a challenging diagnosis and the most appropriate management remains controversial.³ In general, SCS is comprised of: 1) the presence of an adrenal incidentaloma or mass, 2) biochemical confirmation of cortisol excess, and 3) no classic

phenotypic manifestations of Cushing's syndrome.⁴ Since adrenal incidentaloma has an estimated prevalence of 1–8% of the population,⁵ it is quite possible that SCS is an underrecognized risk factor for CSCR.

SCS may potentiate metabolic syndrome and osteoporosis; studies have found that surgical resection of adrenal incidentalomas improve weight, blood pressure, and glucose control. Consequently, some authors recommend those with SCS-associated comorbidities be considered for resection.⁶ An important consideration in these patients is how visual comorbidity factors into intervention. In our patient's case, the recurrent CSCR, hypertension, and increased risk of metabolic syndrome

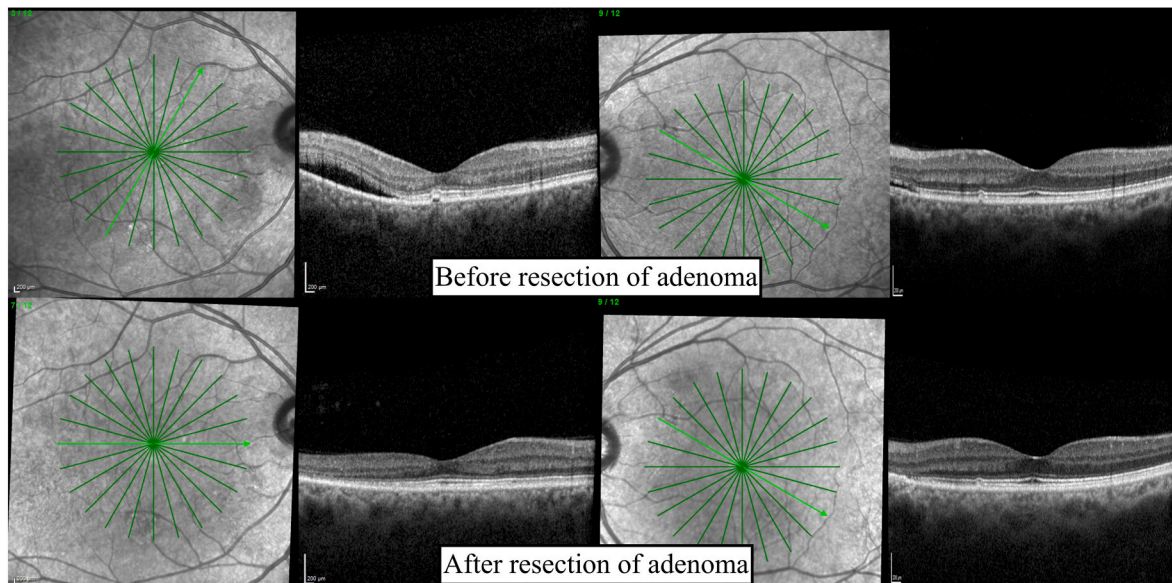


Fig. 2. Optical coherence tomography imaging at presentation and at last follow-up 3 months after adrenalectomy. There is a significant improvement in subretinal fluid in both eyes, though outer retinal irregularity remains.

were sufficient reasons to elect to have surgery.

4. Conclusion

In summary, SCS is a condition of subtle cortisol dysregulation that may represent an underrecognized risk factor for chronic CSCR. Further investigation is needed to determine the threshold of visual comorbidity that may influence surgical management.

Patient consent

Consent to publish the case report was not obtained. This report does not contain any personal information that could lead to the identification of the patient.

Acknowledgments and Disclosures

No funding or grant support. The following authors have no financial disclosures: RRS, AS, AC All authors attest that they meet the current ICMJE criteria for Authorship. No other contributions to acknowledge.

References

1. Zhou M, Bakri SJ, Pershing S. Risk factors for incident central serous retinopathy: case-control analysis of a US national managed care population. *Br J Ophthalmol.* 2019;103(12):1784–1788. <https://doi.org/10.1136/bjophthalmol-2018-313050>.
2. Appa SN. Subclinical hypercortisolism in central serous chorioretinopathy. *Retin Cases Brief Rep.* 2014;8(4):310–313. <https://doi.org/10.1097/ICB.0000000000000036>.
3. Chiodini I, Albani A, Ambrogio AG, et al. Six controversial issues on subclinical Cushing's syndrome. *Endocrine.* 2017;56(2):262–266. <https://doi.org/10.1007/s12020-016-1017-3>.
4. Zeiger MA, Thompson GB, Duh Q-Y, et al. American association of clinical endocrinologists and American association of endocrine surgeons medical guidelines for the management of adrenal incidentalomas: executive summary of recommendations. *Endocr Pract Off J Am Coll Endocrinol Am Assoc Clin Endocrinol.* 2009;15(5):450–453. <https://doi.org/10.4158/EP.15.5.450>.
5. Terzolo M, Stigliano A, Chiodini I, et al. AME position statement on adrenal incidentaloma. *Eur J Endocrinol.* 2011;164(6):851–870. <https://doi.org/10.1530/EJE-10-1147>.
6. Hsieh LB, Mackinney E, Wang TS. When to intervene for subclinical cushing's syndrome. *Surg Clin North Am.* 2019;99(4):747–758. <https://doi.org/10.1016/j.suc.2019.04.011>.