

2-9-2022

## Differences in Clinical and Functional Outcomes Between Osteochondral Allograft Transplantation and Autologous Chondrocyte Implantation for the Treatment of Focal Articular Cartilage Defects

John R Matthews

Joseph Brutico

Daniel Abraham

Jeremy Heard

Bradford Tucker

*See next page for additional authors*

Follow this and additional works at: [https://jdc.jefferson.edu/rothman\\_institute](https://jdc.jefferson.edu/rothman_institute)



Part of the [Orthopedics Commons](#)

**[Let us know how access to this document benefits you](#)**

---

This Article is brought to you for free and open access by the Jefferson Digital Commons. The Jefferson Digital Commons is a service of Thomas Jefferson University's [Center for Teaching and Learning \(CTL\)](#). The Commons is a showcase for Jefferson books and journals, peer-reviewed scholarly publications, unique historical collections from the University archives, and teaching tools. The Jefferson Digital Commons allows researchers and interested readers anywhere in the world to learn about and keep up to date with Jefferson scholarship. This article has been accepted for inclusion in Rothman Institute Faculty Papers by an authorized administrator of the Jefferson Digital Commons. For more information, please contact: [JeffersonDigitalCommons@jefferson.edu](mailto:JeffersonDigitalCommons@jefferson.edu).

---

**Authors**

John R Matthews, Joseph Brutico, Daniel Abraham, Jeremy Heard, Bradford Tucker, Fotios Tjoumakaris,  
and Kevin Freedman

---

# Differences in Clinical and Functional Outcomes Between Osteochondral Allograft Transplantation and Autologous Chondrocyte Implantation for the Treatment of Focal Articular Cartilage Defects

John R. Matthews,\* MD, Joseph M. Brutico,\* BS, Daniel T. Abraham,<sup>†</sup> BS, Jeremy C. Heard,<sup>†</sup> BS, Bradford S. Tucker,\* MD, Fotios P. Tjoumakaris,\* MD, and Kevin B. Freedman,\*<sup>‡</sup> MD

*Investigation performed at Thomas Jefferson Rothman Orthopedic Institute, Philadelphia, Pennsylvania, USA*

**Background:** Articular cartilage pathology can result from a spectrum of origins, including trauma, osteochondritis dissecans, avascular necrosis, or degenerative joint disease.

**Purpose:** To compare the differences in clinical and patient-reported outcomes after autologous chondrocyte implantation (ACI) versus osteochondral allograft transplantation (OCA) in patients with focal articular cartilage defects without underlying bone loss.

**Study Design:** Cohort study; Level of evidence, 3.

**Methods:** A retrospective review identified patients who underwent ACI or OCA between 2008 and 2016 for isolated grades 3 and 4 articular cartilage defects without underlying bone loss. Outcome measures included the Knee injury and Osteoarthritis Outcome Score for Joint Replacement (KOOS JR), International Knee Documentation Committee (IKDC) evaluation, and 12-Item Short Form Health Survey–Physical Component (SF-12-P) scores. Defect location, size, complications, and rate of subsequent surgery were determined.

**Results:** Overall, 148 patients were included: 82 (55%) underwent ACI and 66 (45%) underwent OCA. The mean age at the time of surgery was 31.2 years within the ACI cohort and 37.7 years within the OCA cohort ( $P < .001$ ); the mean follow-up for both cohorts was 6.7 years ( $P = .902$ ). Within the ACI group, 28 (34%) patients had multifocal defects, 21 (26%) had defects confined to the femoral condyles, and 33 (40%) had defects in the patellofemoral region. Within the OCA group, 23 (35%) patients had multifocal defects, 30 (46%) had confined femoral condyle lesions, and 13 (20%) had patellofemoral defects. When comparing by lesion location, there were no significant differences in KOOS JR, and IKDC scores between the ACI and OCA cohorts ( $P < .05$ ). There was, however, a significant difference for SF-12-P scores for FDD trochlear lesions. In both cohorts, traumatic patellofemoral pathology demonstrated lower patient-reported outcomes and higher failure rates than degenerative lesions. The overall rate of failure, defined as graft failure with revision surgery and/or conversion to arthroplasty, was significantly greater in the OCA group (21% vs 4%;  $P = .002$ ).

**Conclusion:** Study results indicated that ACI provides similar outcomes to OCA with or without concomitant procedures for the treatment of symptomatic articular cartilage defects in all lesion locations and may have a lower revision rate for multifocal and condylar lesions.

**Keywords:** osteochondral allograft transplantation; articular cartilage defect; autologous chondrocyte implantation

In the United States, approximately 200,000 to 300,000 chondral-related surgeries are performed annually.<sup>44</sup> Chondral lesions are commonly encountered during knee

arthroscopic surgery, with a reported prevalence of 63% to 66%.<sup>2,12</sup> Patients with symptomatic lesions may experience pain, locking, catching, recurrent effusions, and functional impairment.<sup>13,51</sup> When damaged, articular cartilage has limited capacity to regenerate because of poor vascularity and limited chondrocytes.<sup>1</sup> Prior studies<sup>1,2,14,35,41,57</sup> have demonstrated that unaddressed lesions and excised

The Orthopaedic Journal of Sports Medicine, 10(2), 23259671211058425  
DOI: 10.1177/23259671211058425  
© The Author(s) 2022

This open-access article is published and distributed under the Creative Commons Attribution - NonCommercial - No Derivatives License (<https://creativecommons.org/licenses/by-nc-nd/4.0/>), which permits the noncommercial use, distribution, and reproduction of the article in any medium, provided the original author and source are credited. You may not alter, transform, or build upon this article without the permission of the Author(s). For article reuse guidelines, please visit SAGE's website at <http://www.sagepub.com/journals-permissions>.

fragments result in poor knee function and progression to diffuse osteoarthritis.

There are several options available to address focal chondral defects, including palliative, reparative, and restorative treatments. Palliative measures such as chondroplasty and debridement can help reduce irritation and inflammation.<sup>24</sup> Reparative techniques involve fixation of the loose fragment or microfracture.<sup>11,18,50</sup> Restorative techniques attempt to recreate the type 2 hyaline cartilage via autologous chondrocyte implantation (ACI), osteochondral autograft transfer (OAT), or osteochondral allograft transplantation (OCA).<sup>5,23,40</sup> Ultimately, treatment selection depends on a variety of factors including lesion size, location, extension to the underlying subchondral bone, patient age, function, and concomitant pathology.<sup>11</sup> Prior studies<sup>3,6,28,51</sup> have demonstrated that microfracture has the best results in lesions <2 cm<sup>2</sup>; lesions between 2 and 4 cm<sup>2</sup> can be addressed using ACI, OAT, or OCA; and lesions >4 cm<sup>2</sup> can be addressed using ACI or OCA. Although unicompartmental and total knee arthroplasty are alternative options, they are generally cost-inefficient because of concerns regarding implant survivorship in younger patients and limitations in activity level.<sup>20</sup>

OCA transfers mature viable chondrocytes with subchondral bone into size-matched chondral defects while avoiding donor site morbidity seen with OATs.<sup>32,48,60</sup> The use of OCA has increased in recent years as new studies have demonstrated satisfactory long-term outcomes, with 5- and 10-year survival rates of 95% and 85%, respectively.<sup>§</sup> There are several limitations to the use of OCA, including the availability of donor tissue, contour matching, limited time from graft harvest to implantation, high cost, and potential for disease transmission.<sup>27,53,54</sup>

With ACI, autologous chondrocytes are harvested from a donor site and cultured *in vitro*. These chondrocytes are then reimplanted into the chondral defect in a second operation. There are various methods of applying the chondrocytes to the cartilage defect, including applying them under a periosteal cover (ACI-P), applying them under a porcine-derived type 1/type 3 collagen cover (ACI-C), or implanting the cells into a membrane using a matrix-induced ACI (MACI) technique. The former 2 methods involve implantation of chondrocytes in suspension leading to concerns with uneven distribution of cells as well as leakage. The MACI technique alleviates these concerns.<sup>4,49</sup> The results of several randomized controlled trials have indicated

favorable short-term results for MACI when used to treat focal articular cartilage defects.<sup>31,37</sup>

When there is significant subchondral bone damage or loss, OCA may be superior to ACI since it has the advantage of restoring the subchondral bone. In the setting of articular cartilage damage without subchondral bone loss, both OCA and ACI are viable options. Because of the increased popularity of cartilage restoration techniques for treatment of focal cartilage defects, the purpose of this study was to compare differences in clinical and patient-reported outcomes in patients treated with OCA or ACI for grades 3 and 4 chondral defects without underlying bone loss or defects.

## METHODS

After receiving institutional review board approval, we conducted a database query to identify patients at a single institution who had undergone ACI or OCA between 2008 and 2016. Patients in whom articular cartilage disease occurred in the setting of concomitant bone loss and/or unaddressed malalignment were excluded from the study. In addition, patients with <2 years of postoperative follow-up were excluded.

Eligible patients completed functional outcome surveys including the Knee injury and Osteoarthritis Outcome Score for Joint Replacement (KOOS JR), International Knee Documentation Committee (IKDC), and 12-Item Short Form Health Survey–Physical Component (SF-12-P) scores. A retrospective chart review was performed to obtain patient information, including age at time of surgery, sex, and body mass index (BMI). We also collected information related to ACI and OCA, including technique, laterality, injury origin, chondral lesion grade, defect size, defect location, number of defects, concomitant procedures, previous and subsequent procedures on the ipsilateral knee, and complications. Failure after ACI and OCA was defined as graft failure with revision surgery and/or conversion to arthroplasty.

The decision for ACI or OCA was previously determined based on surgeon experience, preference, patient age, and incorporated lesion characteristics (location, size, containment, and presence of subchondral cysts/sclerosis). ACI was performed using a porcine collagen patch with no subchondral bone grafting. Postoperative rehabilitation included nonweightbearing for 6 weeks with continuous passive motion use. There were slight variabilities with regard to range of motion restrictions initially based on lesion location, size, and concomitant procedures. Within

§References 7, 9, 15, 19, 26, 27, 33, 62, 63.

†Address correspondence to Kevin B. Freedman, MD, Sidney Kimmel Medical College - Thomas Jefferson University, Rothman Institute, Sports Medicine, Medical Arts Pavilion Suite 200, 825 Old Lancaster Road, Bryn Mawr, PA 19010, USA (email: kevin.freedman@rothmanortho.com).

\*Thomas Jefferson Rothman Orthopedic Institute, Philadelphia, Pennsylvania, USA.

†Thomas Jefferson University, Philadelphia, Pennsylvania, USA.

Final revision submitted July 20, 2021; accepted August 24, 2021.

One or more of the authors has declared the following potential conflict of interest or source of funding: B.S.T. has received education payments from Liberty Surgical and consulting fees from Medical Device Business Services. F.P.T. has received consulting fees from Medical Device Business Services and nonconsulting fees from Medtronic and Smith & Nephew. K.B.F. has received education payments from Liberty Surgical, consulting fees from Medical Device Business Services, and nonconsulting fees and honoraria from Vericel. AOSSM checks author disclosures against the Open Payments Database (OPD). AOSSM has not conducted an independent investigation on the OPD and disclaims any liability or responsibility relating thereto.

Ethical approval for this study was obtained from Thomas Jefferson University.

TABLE 1  
Comparison of Characteristics Between  
the ACI and OCA Groups<sup>a</sup>

	ACI (n = 82)	OCA (n = 66)	P Value
Age at surgery, y	31.2 ± 9.5	37.7 ± 10.7	<b>&lt;.001</b>
Follow-up, y	6.7 ± 1.7	6.7 ± 1.6	.902
Sex			.284
Male	35 (42.7)	34 (51.5)	
Female	47 (57.3)	32 (48.5)	
BMI	27.4 ± 5.2	29.1 ± 5.3	.056
Laterality			.123
Right	44 (53.7)	27 (40.9)	
Left	38 (46.3)	39 (59.1)	
Origin			<b>.040</b>
Acute trauma	32 (39.0)	34 (51.5)	
FDD	50 (61.0)	32 (48.5)	
Lesion grade			<b>.001</b>
Grade 3	1 (1.2)	12 (18.2)	
Grade 4	81 (98.8)	54 (81.8)	

<sup>a</sup>Data are presented as mean ± SD or n (%). Bolded *P* values indicate a statistically significant difference between groups ( $P < .05$ ). ACI, autologous chondrocyte implantation; BMI, body mass index; FDD, focal degenerative defect; OCA, osteochondral allograft transplantation.

each group, patients with lesions in both the femoral condyle and patellofemoral (patella, trochlea) regions were categorized as multifocal, while those with isolated lesions were grouped as femoral condyle (medial or lateral), patellar, or trochlear.

Descriptive statistics including the mean, standard deviation, and range were calculated. The Fisher exact test or chi-square test was used to compare categorical data. The Student *t* test was used to compare means of parametric data between 2 groups, while analysis of variance was used to compare means of parametric data among 3 groups. Linear regression was used to determine the association between age at surgery and patient-reported outcome scores. Statistical significance was set at  $P < .05$ . All statistical analyses were performed with Statistical Package for the Social Sciences (SPSS) Statistics software 26 (IBM Corp., Armonk, NY, USA).

## RESULTS

A total of 202 patients were identified as being eligible to participate in the study. Of these, 54 (27%) patients were lost to follow-up. The remaining 148 (73%) patients were included in the final analysis. The patient cohort comprised 82 (55%) patients who had undergone ACI and 66 (45%) patients who underwent OCA (Table 1). In both cohorts, cartilage injuries were a result of acute trauma, or they were atraumatic and characterized as focal degenerative defect (FDD). Within the ACI group, acute trauma was further categorized as athletic (11 patients, 34%), fall (5 patients, 16%), work-related (5 patients, 16%), motor vehicle accident (2 patients, 6%), acute patellar dislocation (2 patients, 6%), and unspecified (7 patients, 22%). Within

TABLE 2  
Comparison of Lesion Location Between the ACI and OCA  
Groups Based on Origin<sup>a</sup>

Lesion Location	ACI (n = 82)	OCA (n = 66)	P Value
Multifocal			
FDD	19 (23)	11 (17)	.328
Trauma	9 (11)	12 (18)	.212
<i>P</i> value	.358	.938	
Combined	28 (34)	23 (35)	.928
Condylar			
FDD	10 (12)	15 (23)	.089
Trauma	11 (13)	15 (23)	.139
<i>P</i> value	.146	.822	
Combined	21 (26)	30 (45)	<b>.011</b>
Patellar			
FDD	18 (22)	5 (8)	<b>.016</b>
Trauma	12 (15)	5 (8)	.181
<i>P</i> value	.891	.917	
Combined	30 (37)	10 (16)	<b>.004</b>
Trochlear			
FDD	3 (4)	1 (2)	.424
Trauma	0 (0)	2 (3)	.437
<i>P</i> value	.555	.591	
Combined	3 (4)	3 (5)	.786

<sup>a</sup>Data are presented as n (%). Bolded *P* values indicate a statistically significant difference between groups ( $P < .05$ ). ACI, autologous chondrocyte implantation; FDD, focal degenerative defect; OCA, osteochondral allograft transplantation.

the OCA group, acute trauma was further categorized as athletic (11 patients, 32%), fall (12 patients, 35%), work-related (4 patients, 12%), motor vehicle accident (2 patients, 6%), gunshot (1 patient, 3%), and unspecified (4 patients, 12%).

Articular cartilage defects were grouped into the following locations: multifocal (lesions involving >1 area), condylar (isolated medial or lateral femoral condyle), patellar, and trochlear regions. The only statistically significant difference was seen in degenerative patellar lesions, with 18 in the ACI cohort and 5 in the OCA cohort, as demonstrated in Table 2 ( $P = .016$ ).

Within the ACI group, the defect locations from most to least frequent were the patella (46%), followed by the lateral femoral condyle (19%), medial femoral condyle (18%), medial trochlea (14%), and lateral trochlea (3%). Within the OCA group, the defect locations from most to least frequent were the medial femoral condyle (44%), patella (17%), lateral femoral condyle (17%), medial trochlea (13%), and lateral trochlea (8%). When comparing the mean defect area per patient, the OCA group was found to have a significantly greater mean area at the medial femoral condyle ( $486 \pm 264$  vs  $326 \pm 137$  mm<sup>2</sup>;  $P = .003$ ) and lateral femoral condyle ( $458 \pm 250$  vs  $284 \pm 130$  mm<sup>2</sup>;  $P = .019$ ). The mean area of the patellofemoral region was not statistically different between the 2 groups (OCA,  $453 \pm 296$  vs ACI,  $509 \pm 320$  mm<sup>2</sup>;  $P = .409$ ).

Surgical history was also collected and compared. A significantly greater proportion of patients within the OCA group had a previous procedure on their affected knee

compared with the ACI group (76% vs 18%;  $P < .001$ ). In contrast, patients were significantly more likely to have undergone a concomitant procedure at the time of ACI compared with OCA (93% vs 53%;  $P < .001$ ). Detailed surgical history is shown in Table 3. Although the rate of subsequent surgery was greater in the OCA group, the difference was not significant (46% vs 31%;  $P = .061$ ).

When comparing the ACI and OCA groups, patient-reported outcomes including KOOS JR ( $72.4 \pm 16.6$  vs

$69.7 \pm 20.3$ ,  $P = .385$ ), IKDC ( $61.6 \pm 20.8$  vs  $59.1 \pm 23.1$ ,  $P = .491$ ), and SF-12 ( $48.9 \pm 7.6$  vs  $45.9 \pm 10.4$ ,  $P = .060$ ) did not significantly differ. The patient-reported outcome scores were also compared based on lesion location and between FDD versus traumatic lesions (Table 4). When comparing KOOS JR, IKDC, and SF-12-P scores in FDD lesions between ACI and OCA, the only statistically significant difference was seen in trochlear lesions, where ACI demonstrated higher SF-12-P scores compared with OCA. There were no differences between groups in the scores for traumatic lesions.

Within the ACI group, we noted only 1 statistically significant difference with degenerative patellar lesions ( $n=18$ ) having superior KOOS Jr scores compared with traumatic patellar lesions ( $n=12$ ). Comparing degenerative lesions to traumatic lesions in the OCA cohort, we also found 1 statistically significant difference, with degenerative trochlear lesions ( $n = 1$ ) having superior IKDC scores to those of traumatic injuries ( $n = 2$ ). Patient-reported outcome scores were also compared within and between the ACI and OCA groups based on the presence or absence of concomitant procedures at the time of surgery (Figure 1). No significant differences were found in any of the 3 patient-reported outcome scores among the 4 subgroups ( $P > .05$ ). Within the ACI group, age was associated with significantly worse KOOS JR ( $P = .003$ ), IKDC ( $P < .001$ ), and SF-12-P ( $P = .007$ ) scores. However, age was not significantly associated with KOOS JR ( $P = .281$ ), IKDC ( $P = .110$ ), or SF-12-P ( $P = .196$ ) scores after OCA.

The rate of failure based on lesion location and origin is depicted in Table 5. Multifocal degenerative lesions within the OCA cohort demonstrated statistically significantly higher failure rates ( $n = 3$ ) compared with the ACI group ( $n = 0$ ) ( $P = .041$ ). Furthermore, the overall condylar lesions (degenerative plus traumatic) in the OCA group demonstrated statistically significantly higher failure rates than did the ACI group, with 7 total compared with 0, respectively ( $P = .017$ ). There were no statistically significant differences comparing the rate of failure between degenerative and traumatic lesions within the patella; however, there was a trend toward greater failure rates in traumatic lesions in both groups than in degenerative lesions. Within the ACI group, 3 patients with isolated patellar lesions required an additional surgery because of failure. Two of these patients underwent revision using OCA, and 1

TABLE 3

Comparison of Concomitant and Subsequent Procedures of Patients Who Underwent ACI or OCA<sup>a</sup>

Additional Treatment	Concomitant Surgeries		Subsequent Surgeries	
	ACI (n = 76; 92.7%)	OCA (n = 35; 53.0%)	ACI (n = 25; 30.5%)	OCA (n = 30; 45.5%)
ACI	0	0	0	1
ACLR	2	3	0	3
ACLR + meniscal repair	1	1	0	0
ACLR + meniscectomy	2	0	0	1
ACLR + meniscal transplant	0	1	0	0
Partial knee arthroplasty	0	0	1	8
Curettage and bone grafting	0	0	0	0
Debridement	44	8	23	15
Fulkerson TTO	26	6	1	0
Fulkerson TTO + MPFLR	10	3	0	0
Lateral retinacular lengthening	22	7	3	0
Meniscal repair	1	0	0	0
Meniscectomy	8	6	7	8
Meniscal transplant	4	1	0	2
Microfracture	0	1	1	3
MPFLR	1	5	0	0
OCA	0	0	2	0
Synovectomy	8	1	4	2

<sup>a</sup>Data are presented as n. Debridement includes lysis of adhesions, chondroplasty, removal of hard, and excision of loose bodies. Arthroplasty includes total and unicompartmental. ACI, autologous chondrocyte implantation; ACLR, anterior cruciate ligament reconstruction; MPFLR, medial patellofemoral ligament reconstruction; OCA, osteochondral allograft transplantation; TTO, tibial tubercle osteotomy.

TABLE 4A

Comparison of Patient-Reported Outcomes in Focal Degenerative Defects for ACI and OCA Based on Location<sup>a</sup>

Lesion Location	KOOS JR			IKDC			SF-12-P		
	ACI	OCA	<i>P</i>	ACI	OCA	<i>P</i>	ACI	OCA	<i>P</i>
Multifocal	75.3 ± 20.2	67.2 ± 14.0	.245	65.2 ± 23.4	63.7 ± 15.6	.854	48.3 ± 8.9	46.6 ± 10.0	.628
Femoral Condyle	68.0 ± 16.2	71.7 ± 17.8	.602	52.4 ± 20.0	57.5 ± 22.3	.569	46.7 ± 9.4	46.9 ± 10.8	.955
Patellar	78.8 ± 15.8	70.4 ± 11.0	.282	68.2 ± 21.1	63.0 ± 15.1	.614	50.6 ± 6.3	47.9 ± 5.5	.400
Trochlear	66.5 ± 9.6	100.0 ± 0.0	.094	54.6 ± 2.4	73.6 ± 0.0	.099	50.9 ± 0.8	36.0 ± 0.0	<b>.042</b>

<sup>a</sup>Values presented as mean ± SD. Bolded *P* value indicates a statistically significant difference between groups ( $P < 0.05$ ). ACI, autologous chondrocyte implantation; IKDC, International Knee Documentation Committee; KOOS JR, Knee injury and Osteoarthritis Outcome Score for Joint Replacement; OCA, osteochondral allograft transplantation; SF-12-P, Short Form Health Survey Physical Component.

TABLE 4B  
Comparison of Patient-Reported Outcomes in Traumatic lesions for ACI and OCA Based on Location<sup>a</sup>

Lesion Location	KOOS JR			IKDC			SF-12-P		
	ACI	OCA	P	ACI	OCA	P	ACI	OCA	P
Multifocal	68.3 ± 19.8	62.9 ± 29.7	.644	57.2 ± 26.0	51.0 ± 33.8	.650	51.5 ± 7.2	43.5 ± 13.7	.179
Femoral Condyle	72.1 ± 12.4	61.8 ± 12.9	.588	61.8 ± 12.9	65.8 ± 20.0	.534	48.6 ± 6.6	48.2 ± 9.4	.890
Patellar	66.6 ± 12.9	65.5 ± 20.0	.900	58.2 ± 19.7	52.0 ± 30.3	.615	47.4 ± 8.2	41.9 ± 12.0	.294
Trochlear	-	57.1 ± 0.0	-	-	45.4 ± 0.8	-	-	42.8 ± 3.5	-

<sup>a</sup>Values presented as mean ± SD. Dashes indicate no patients were in the category or comparison could not be made. ACI, autologous chondrocyte implantation; IKDC, International Knee Documentation Committee; KOOS JR, Knee injury and Osteoarthritis Outcome Score for Joint Replacement; OCA, osteochondral allograft transplantation; SF-12-P, Short Form Health Survey Physical Component.

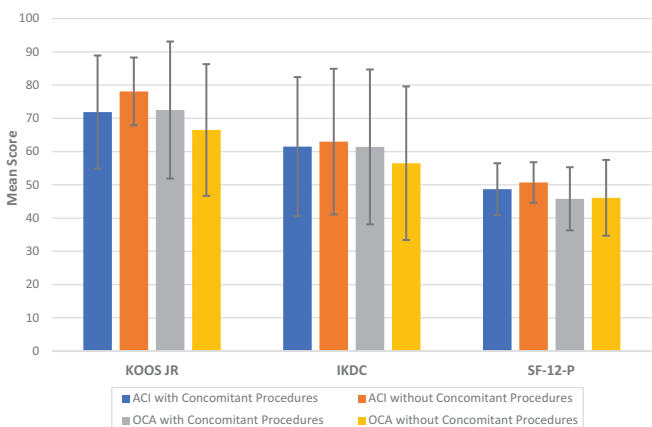


Figure 1. Comparison of mean patient-reported outcome scores by surgical procedure with and without concomitant procedures. Error bars indicate SDs. No outcome scores were significantly different among the 4 groups. ACI, autologous chondrocyte implantation; IKDC, International Knee Documentation Committee; KOOS JR, Knee injury and Osteoarthritis Outcome Score for Joint Replacement; OCA, osteochondral allograft transplantation; SF-12-P, 12-Item Short Form Health Survey-Physical Component.

patient underwent conversion to patellofemoral arthroplasty. Within the OCA group, 14 patients required an additional surgery because of OCA failure. Three patients underwent OCA revision because of implant failure, 1 underwent microfracture for a delaminated plug, 2 required removal of a loose plug, and 8 patients required conversion to total or unicompartmental knee arthroplasty. The overall rate of failure was significantly greater in the OCA group (21% vs 4%;  $P = .002$ ). Complications after ACI included complex regional pain syndrome in 1 (1.2%) patient and an incisional stitch abscess that was successfully managed nonoperatively in 1 (1.2%) patient. No other complications were reported in the OCA group.

DISCUSSION

Prior studies have evaluated long-term outcomes after ACI and OCA, but direct comparisons between these two

TABLE 5  
Comparison of Treatment Failure Based on Lesion Location Between Patients Who Underwent ACI or OCA<sup>a</sup>

Lesion Location	ACI	OCA	P value
Multifocal			
FDD	0 (0.0)	3 (27.3)	<b>.041</b>
Trauma	0 (0.0)	0 (0.0)	.999
P value	.999	.093	
Condylar			
FDD	0 (0.0)	3 (20.0)	.250
Trauma	0 (0.0)	4 (26.7)	.113
P value	.999	.999	
Patellar			
FDD	0 (0.0)	0 (0.0)	.999
Trauma	3 (25.0)	3 (60.0)	.280
P value	.054	.167	
Trochlear			
FDD	0 (0.0)	0 (0.0)	.999
Trauma	-	1 (50.0)	-
P value	-	.999	

<sup>a</sup>Data are presented as n (%). Bolded P value indicates a statistically significant difference between groups ( $P < .05$ ). Dashes indicate no patients matched the criteria. ACI, autologous chondrocyte implantation; FDD, focal degenerative defect; OCA, osteochondral allograft transplantation.

techniques for isolated chondral defects have not been reviewed. The present study evaluated clinical and patient-reported outcomes of patients who underwent either ACI or OCA for focal grades 3 and 4 articular cartilage defects. Both patient cohorts were found to have similar patient-reported outcome scores at a mean follow-up of 6.7 years. The OCA group had a significantly higher rate of failure compared with the ACI group (21% vs 4%;  $P = .002$ ). Traumatic patellofemoral pathology in both cohorts demonstrated lower patient-reported outcomes and higher failure rates than degenerative lesions. Although both interventions produced similar patient-reported outcomes, the findings of this study suggest that ACI may have a lower failure rate than OCA in select patients and lesion locations.

Patient data between the ACI and OCA cohorts were similar with respect to sex, BMI, and laterality. However, the OCA group was significantly older than the ACI group

at the time of surgery. While Frank et al<sup>17</sup> reported that age was not predictive of functional outcomes after OCA, previous studies<sup>43,64</sup> have found age to be associated with worse outcomes after ACI. Similar findings were seen in the present study, with advanced age demonstrating a significant association with worse functional outcome scores after ACI but not OCA. This may be because of the inherent quality of the chondrocytes harvested in the ACI group, with older patients having less viable and active cells, while OCA directly replaces the lost chondrocytes with donor tissue. The younger population within the ACI group may have contributed to the similar patient-reported outcome scores seen at final follow-up. In addition to being an older cohort, patients within the OCA group were more likely to have undergone a previous procedure compared with patients in the ACI group. With no baseline subjective data because of the retrospective design, it is not possible to determine the degree of symptoms at the time of surgery. Frank et al<sup>19</sup> found that past surgical history was associated with worse functional outcomes after OCA. The higher rate of prior operations may have resulted in lower-than-expected patient-reported outcomes within the OCA group in comparison with published literature. In contrast, patients within the ACI group were more likely to have undergone a concomitant procedure at the time of surgery. Harris et al<sup>29</sup> examined patient-reported outcomes after cartilage repair (ACI, OCA, microfracture) with or without meniscal transplantation and osteotomy. Aside from the KOOS quality of life subscale, the authors found no significant differences in IKDC, KOOS subscale (pain, symptoms, activities of daily living, sport), Lysholm, and SF-12 scores between the groups after a minimum follow-up of 2 years.<sup>29</sup> In the present study, no significant difference was found in regard to patient-reported outcome scores between the ACI and OCA groups when comparing patients based on the presence or absence of concomitant surgery (Figure 1).

Previous literature has provided mixed conclusions regarding the effect of defect size on long-term outcomes after ACI and OCA. Some studies<sup>38,41,42,47</sup> have found correlations between larger lesions with worse outcomes at long-term follow-up, while others<sup>56,59</sup> have not found an association between these 2 variables. The results of the present study indicate that lesion size was not associated with patient-reported outcome scores at the final follow-up, as the OCA group was found to have a significantly greater mean defect area at the medial and lateral femoral condyle but similar patient-reported outcome scores in comparison with the ACI group. Although the OCA group had a significantly greater proportion of patients with grade 3 injuries, previous literature<sup>56</sup> has found lesion grade to be a poor predictor of functional outcomes. In contrast, lesion location, specifically the patellofemoral joint, has been established as a risk factor for worse outcomes after both ACI and OCA.<sup>8,21,25,43</sup> In our study, when comparing isolated patellofemoral lesions in the OCA and ACI cohorts, patient-reported outcomes in both cohorts were similar to those of patients with multifocal or confined condylar lesions.

The patient-reported outcomes of the present study aligned with those of previous literature. With regard to the ACI group, the mean KOOS JR score (72.4) was slightly lower than the range of 74.7 to 84.6 as reported by Saris et al<sup>52</sup> and Hoburg et al.<sup>30</sup> In addition, the mean IKDC score (61.6) aligned with the scores of Viste et al,<sup>58</sup> who reported a mean score of 60.2 at an average follow-up of 6 years, and Martincic et al,<sup>36</sup> who reported a mean score of 67 at an average follow-up of 5 years. The mean SF-12-P score (48.9) aligned with those of Gillogly and Arnold,<sup>22</sup> who reported a mean score of 47.6 at an average follow-up of 7.6 years, and Ogura et al,<sup>45</sup> who reported a mean score of 49.2 at a mean follow-up of 2 years.

Within the OCA group, the mean KOOS JR score (69.7) was slightly less than the mean scores found in previous literature, including the studies by Mirzayan et al,<sup>39</sup> who reported a mean score of 83.1, and Tírico et al,<sup>55</sup> who reported a mean score of 85.2. The superior outcomes reported by Mirzayan et al<sup>39</sup> and Tírico et al<sup>55</sup> are not surprising, as the studies had an average follow-up of 2 years compared with 6 years in the present study. The mean IKDC score (59.1) was within the range of 54.8 to 81.2 established by a number of previous studies.<sup>10,17,19,34,55,59,61</sup> The mean SF-12-P score (45.9) also aligned with the reported range of 43.4 to 48.7.<sup>17,34,46</sup>

Comparison of traumatic to degenerative lesions between OCA and ACI also did not demonstrate any major differences in patient-reported outcomes. The only statistically significant difference was noted in trochlear lesions, in which degenerative lesions treated with ACI demonstrated superior SF-12-P compared with those treated with OCA; however, the patient sample was small, with only 3 patients with ACI and 1 with OCA. Subgroup analysis of each cohort demonstrated that degenerative lesions within the patellofemoral joint fared superior to traumatic lesions. Degenerative patellar lesions treated with ACI not only demonstrated superior KOOS JR scores compared with traumatic lesions addressed with ACI but also had zero failures as opposed to the 25% (n = 3) failure rate seen in traumatic lesions (Table 5). A similar trend was seen in the OCA cohort, with degenerative trochlear pathology treated with OCA having better IKDC scores and no failures as opposed to traumatic trochlear lesions. With higher failure rates in traumatic patellofemoral lesions, it was not surprising to see lower patient-reported outcomes. The higher failure rates in traumatic lesions could be a result of underlying subchondral bone damage that may occur at the time of injury, which could affect the integration of both ACI and OCA grafts. Further research exploring traumatic lesions is needed.

Overall, the failure rate of 3.7% within the ACI group was slightly lower than the rates reported in the literature (5%-7%).<sup>31,36,58</sup> While some of these studies focused solely on lesions in the femoral condyle, current literature suggests that lesion location is not associated with rate of failure after ACI.<sup>59</sup> However, our study results suggest the cause of the lesion may affect graft survivorship, with traumatic patellofemoral pathology having inferior outcomes and higher failure rates compared with degenerative lesions. With regard to OCA, the failure rate of 21% was



slightly higher than the range of 13% to 18%<sup>16,19,61</sup> reported in the literature. The OCA group had a higher failure rate compared with the ACI cohort in terms of multifocal degenerative lesions and isolated condylar lesions. This finding is likely multifactorial and attributable to the older patient population in the OCA group, larger defect size in the femoral condyles, greater prevalence of prior operations, and differences in etiopathogenesis.

The findings of the present study suggest that both ACI and OCA are effective techniques for the management of grades 3 and 4 articular cartilage defects, as evidenced by the similarity in outcome scores at final follow-up. Furthermore, concomitant procedures during both ACI and OCA can be performed with similar patient-reported outcomes for either procedure in isolation. Advanced age was an independent risk factor for worst outcomes after ACI but not OCA. Overall, ACI had a lower failure rate in regard to degenerative multifocal and isolated condylar lesions compared with OCA; however, the age at the time of surgery, lesion size, and incidence of previous operations were greater in the latter group, which may have contributed to a higher rate of failure. Further research on the efficacy of ACI and OCA for the treatment of articular cartilage defects and on the implications of third-generation ACI techniques (MACI) is required.

The present study had several limitations. The retrospective study design did not allow for the formation of groups with identical patient and lesion characteristics, including defect size. Although similar, the OCA group had a significantly higher average age at the time of surgery, larger condylar lesions, and higher prevalence of previous operations when compared with the ACI group. Because of the retrospective study design, there were no baseline subjective data, and therefore it was not possible to determine the degree of symptomology at the time of surgery within each cohort. Despite collecting data on >70% of patients who underwent ACI or OCA between 2008 and 2016, a power analysis demonstrated that the results were underpowered and at risk of a type 2 error. The mean follow-up of 6.7 years for both patient groups underscored the effectiveness of these surgical techniques in the short and intermediate periods. Extended follow-up would provide more definitive conclusions on the longevity and long-term outcomes after ACI and OCA. The extent of improved patient-reported outcomes purely due to cartilage restoration procedures is also difficult to determine, as concomitant procedures were also performed. There were also slight variations with postoperative protocols among surgeons, which may have contributed to functional recovery. Although clinical outcomes were tracked, long-term postoperative radiographs were not routinely obtained, limiting the ability to grade the progression of osteoarthritis. Furthermore, there was potential for selection bias among surgeons, with preference toward 1 technique to address subchondral cysts or sclerosis. Lastly, this study only included patients treated by several surgeons at 1 institution who perform a high volume of OCAs and ACIs, which may have potentially introduced performance bias.

## CONCLUSION

The results of the current study indicated that ACI provides similar patient-reported outcomes to OCA with or without concomitant procedures for the treatment of symptomatic articular cartilage defects in all lesion locations and may have a lower revision rate for multifocal and condylar lesions.

## ACKNOWLEDGMENT

The authors would like to acknowledge Emma E. Johnson for her contribution to revision of the manuscript.

## REFERENCES

- Alford JW, Cole BJ. Cartilage restoration, part 1: basic science, historical perspective, patient evaluation, and treatment options. *Am J Sports Med.* 2005;33(2):295-306. doi:10.1177/0363546504273510
- Årøen A, Løken S, Heir S, et al. Articular cartilage lesions in 993 consecutive knee arthroscopies. *Am J Sports Med.* 2004;32(1):211-215. doi:10.1177/0363546503259345
- Asik M, Ciftci F, Sen C, Erdil M, Atalar A. The microfracture technique for the treatment of full-thickness articular cartilage lesions of the knee: midterm results. *Arthroscopy.* 2008;24(11):1214-1220. doi:10.1016/j.arthro.2008.06.015
- Bartlett W, Skinner JA, Gooding CR, et al. Autologous chondrocyte implantation versus matrix-induced autologous chondrocyte implantation for osteochondral defects of the knee: a prospective, randomized study. *J Bone Joint Surg Br.* 2005;87(5):640-645. doi:10.1302/0301-620X.87B5.15905
- Bedi A, Feeley BT, Williams RJ. Management of articular cartilage defects of the knee. *J Bone Joint Surg Am.* 2010;92(4):994-1009. doi:10.2106/JBJS.I.00895
- Bekkers JEJ, Inklaar M, Saris DBF. Treatment selection in articular cartilage lesions of the knee: a systematic review. *Am J Sports Med.* 2009;37(1 suppl):148-155. doi:10.1177/0363546509351143
- Briggs DT, Sadr KN, Pulido PA, Bugbee WD. The use of osteochondral allograft transplantation for primary treatment of cartilage lesions in the knee. *Cartilage.* 2015;6(4):203-207. doi:10.1177/1947603515595072
- Brittberg M, Lindahl A, Nilsson A, Ohlsson C, Isaksson O, Peterson L. Treatment of deep cartilage defects in the knee with autologous chondrocyte transplantation. *N Engl J Med.* 1994;331(14):889-895. doi:10.1056/NEJM199410063311401
- Bugbee W, Cavallo M, Giannini S. Osteochondral allograft transplantation in the knee. *J Knee Surg.* 2012;25(2):109-116. doi:10.1055/s-0032-1313743
- Cameron JI, Pulido PA, McCauley JC, Bugbee WD. Osteochondral allograft transplantation of the femoral trochlea. *Am J Sports Med.* 2016;44(3):633-638. doi:10.1177/0363546515620193
- Cole BJ, Pascual-Garrido C, Grumet RC. Surgical management of articular cartilage defects in the knee. *Instr Course Lect.* 2010;59:181-204.
- Curl WW, Krome J, Gordon ES, Rushing J, Smith BP, Poehling GG. Cartilage injuries: a review of 31,516 knee arthroscopies. *Arthroscopy.* 1997;13(4):456-460. doi:10.1016/s0749-8063(97)90124-9
- Davey A, Frank RM, Wang KC, Southworth TM, Cole BJ. Clinical outcomes of revision osteochondral allograft transplantation. *Arthroscopy.* 2019;35(9):2636-2645. doi:10.1016/j.arthro.2019.03.055
- Davies-Tuck ML, Wluka AE, Wang Y, et al. The natural history of cartilage defects in people with knee osteoarthritis. *Osteoarthritis Cartilage.* 2008;16(3):337-342. doi:10.1016/j.joca.2007.07.005
- Devitt BM, Bell SW, Webster KE, Feller JA, Whitehead TS. Surgical treatments of cartilage defects of the knee: systematic review of

- randomised controlled trials. *Knee*. 2017;24(3):508-517. doi:10.1016/j.knee.2016.12.002
16. Familiari F, Cinque ME, Chahla J, et al. Clinical outcomes and failure rates of osteochondral allograft transplantation in the knee: a systematic review. *Am J Sports Med*. 2018;46(14):3541-3549. doi:10.1177/0363546517732531
  17. Frank RM, Cotter EJ, Lee S, Poland S, Cole BJ. Do outcomes of osteochondral allograft transplantation differ based on age and sex? A comparative matched group analysis. *Am J Sports Med*. 2018;46(1):181-191. doi:10.1177/0363546517739625
  18. Frank RM, Cotter EJ, Strauss EJ, Gomoll AH, Cole BJ. The utility of biologics, osteotomy, and cartilage restoration in the knee. *J Am Acad Orthop Surg*. 2018;26(1):e11-e25. doi:10.5435/JAAOS-D-17-00087
  19. Frank RM, Lee S, Levy D, et al. Osteochondral allograft transplantation of the knee: analysis of failures at 5 years. *Am J Sports Med*. 2017;45(4):864-874. doi:10.1177/0363546516676072
  20. Ghomrawi HM, Eggman AA, Pearle AD. Effect of age on cost-effectiveness of unicompartmental knee arthroplasty compared with total knee arthroplasty in the U.S. *J Bone Joint Surg Am*. 2015;97(5):396-402. doi:10.2106/JBJS.N.00169
  21. Gigante A, Enea D, Greco F, et al. Distal realignment and patellar autologous chondrocyte implantation: mid-term results in a selected population. *Knee Surg Sports Traumatol Arthrosc*. 2009;17(1):2-10. doi:10.1007/s00167-008-0635-6
  22. Gillogly SD, Arnold RM. Autologous chondrocyte implantation and anteromedialization for isolated patellar articular cartilage lesions: 5- to 11-year follow-up. *Am J Sports Med*. 2014;42(4):912-920. doi:10.1177/0363546513519077
  23. Gomoll AH, Farr J, Gillogly SD, Kercher JS, Minas T. Surgical management of articular cartilage defects of the knee. *Instr Course Lect*. 2011;60:461-483.
  24. Gowd AK, Cvetanovich GL, Liu JN, et al. Management of chondral lesions of the knee: analysis of trends and short-term complications using the National Surgical Quality Improvement Program database. *Arthroscopy*. 2019;35(1):138-146. doi:10.1016/j.arthro.2018.07.049
  25. Gracitelli GC, Meric G, Pulido PA, Görtz S, De Young AJ, Bugbee WD. Fresh osteochondral allograft transplantation for isolated patellar cartilage injury. *Am J Sports Med*. 2015;43(4):879-884. doi:10.1177/0363546514564144
  26. Gracitelli GC, Meric G, Pulido PA, McCauley JC, Bugbee WD. Osteochondral allograft transplantation for knee lesions after failure of cartilage repair surgery. *Cartilage*. 2015;6(2):98-105. doi:10.1177/1947603514566298
  27. Gross AE, Aubin P, Cheah HK, Davis AM, Ghazavi MT. A fresh osteochondral allograft alternative. *J Arthroplasty*. 2002;17(4)(suppl 1):50-53. doi:10.1054/arth.2002.32447
  28. Hangody L, Füles P. Autologous osteochondral mosaicplasty for the treatment of full-thickness defects of weight-bearing joints: ten years of experimental and clinical experience. *J Bone Joint Surg Am*. 2003;85-A(suppl 2):25-32. doi:10.2106/00004623-200300002-00004
  29. Harris JD, Hussey K, Saltzman BM, et al. Cartilage repair with or without meniscal transplantation and osteotomy for lateral compartment chondral defects of the knee: case series with minimum 2-year follow-up. *Orthop J Sports Med*. 2014;2(10):2325967114551528. doi:10.1177/2325967114551528
  30. Hoburg A, Lörer I, Körsmeier K, et al. Matrix-associated autologous chondrocyte implantation is an effective treatment at midterm follow-up in adolescents and young adults. *Orthop J Sports Med*. 2019;7(4):2325967119841077. doi:10.1177/2325967119841077
  31. Knutsen G, Engebretsen L, Ludvigsen TC, et al. Autologous chondrocyte implantation compared with microfracture in the knee: a randomized trial. *J Bone Joint Surg Am*. 2004;86(3):455-464. doi:10.2106/00004623-200403000-00001
  32. Krych AJ, Robertson CM, Williams RJ III, Cartilage Study Group. Return to athletic activity after osteochondral allograft transplantation in the knee. *Am J Sports Med*. 2012;40(5):1053-1059. doi:10.1177/0363546511435780
  33. Lamplot JD, Schafer KA, Matava MJ. Treatment of failed articular cartilage reconstructive procedures of the knee: a systematic review. *Orthop J Sports Med*. 2018;6(3):2325967118761871. doi:10.1177/2325967118761871
  34. Lee S, Frank RM, Christian DR, Cole BJ. Analysis of defect size and ratio to condylar size with respect to outcomes after isolated osteochondral allograft transplantation. *Am J Sports Med*. 2019;47(7):1601-1612. doi:10.1177/0363546519841378
  35. Linden B. Osteochondritis dissecans of the femoral condyles: a long-term follow-up study. *J Bone Joint Surg Am*. 1977;59(6):769-776.
  36. Martincic D, Radosavljevic D, Drobnic M. Ten-year clinical and radiographic outcomes after autologous chondrocyte implantation of femoral condyles. *Knee Surg Sports Traumatol Arthrosc*. 2014;22(6):1277-1283. doi:10.1007/s00167-013-2778-3
  37. Micheli LJ, Browne JE, Ergelet C, et al. Autologous chondrocyte implantation of the knee: multicenter experience and minimum 3-year follow-up. *Clin J Sport Med*. 2001;11(4):223-228. doi:10.1097/00042752-200110000-00003
  38. Minas T, Von Keudell A, Bryant T, Gomoll AH. The John Insall Award: a minimum 10-year outcome study of autologous chondrocyte implantation. *Clin Orthop Relat Res*. 2014;472(1):41-51. doi:10.1007/s11999-013-3146-9
  39. Mirzayan R, Charles MD, Batech M, Suh BD, DeWitt D. Bipolar osteochondral allograft transplantation of the patella and trochlea. *Cartilage*. 2020;11(4):431-440. doi:10.1177/1947603518796124
  40. Mistry H, Metcalfe A, Smith N, et al. The cost-effectiveness of osteochondral allograft transplantation in the knee. *Knee Surg Sports Traumatol Arthrosc*. 2019;27(6):1739-1753. doi:10.1007/s00167-019-05392-8
  41. Mithoefer K, Hambly K, Della Villa S, Silvers H, Mandelbaum BR. Return to sports participation after articular cartilage repair in the knee: scientific evidence. *Am J Sports Med*. 2009;37(suppl 1):167S-176S. doi:10.1177/0363546509351650
  42. Mithoefer K, Williams RJ, Warren RF, Wickiewicz TL, Marx RG. High-impact athletics after knee articular cartilage repair: a prospective evaluation of the microfracture technique. *Am J Sports Med*. 2006;34(9):1413-1418. doi:10.1177/0363546506288240
  43. Nawaz SZ, Bentley G, Briggs TWR, et al. Autologous chondrocyte implantation in the knee: mid-term to long-term results. *J Bone Joint Surg Am*. 2014;96(10):824-830. doi:10.2106/JBJS.L.01695
  44. Niethammer TR, Holzgruber M, Gülecüyü MF, Weber P, Pietschmann MF, Müller PE. Matrix based autologous chondrocyte implantation in children and adolescents: a match paired analysis in a follow-up over three years post-operation. *Int Orthop*. 2017;41(2):343-350. doi:10.1007/s00264-016-3321-1
  45. Ogura T, Ackermann J, Barbieri Mestriner A, Merkely G, Gomoll AH. Minimal clinically important differences and substantial clinical benefit in patient-reported outcome measures after autologous chondrocyte implantation. *Cartilage*. 2020;11(4):412-422. doi:10.1177/1947603518799839
  46. Ogura T, Ackermann J, Mestriner AB, Merkely G, Gomoll AH. The minimal clinically important difference and substantial clinical benefit in the patient-reported outcome measures of patients undergoing osteochondral allograft transplantation in the knee. *Cartilage*. 2021;12(1):42-50. doi:10.1177/1947603518812552
  47. Pareek A, Carey JL, Reardon PJ, Peterson L, Stuart MJ, Krych AJ. Long-term outcomes after autologous chondrocyte implantation: a systematic review at mean follow-up of 11.4 years. *Cartilage*. 2016;7(4):298-308. doi:10.1177/1947603516630786
  48. Pearsall AW, Tucker JA, Hester RB, Heitman RJ. Chondrocyte viability in refrigerated osteochondral allografts used for transplantation within the knee. *Am J Sports Med*. 2004;32(1):125-131. doi:10.1177/0095399703258614
  49. Peterson L, Minas T, Brittberg M, Nilsson A, Sjögren-Jansson E, Lindahl A. Two- to 9-year outcome after autologous chondrocyte transplantation of the knee. *Clin Orthop Relat Res*. 2000;374:212-234. doi:10.1097/00003086-200005000-00020
  50. Redondo ML, Beer AJ, Yanke AB. Cartilage restoration: microfracture and osteochondral autograft transplantation. *J Knee Surg*. 2018;31(3):231-238. doi:10.1055/s-0037-1618592

51. Richter DL, Schenck RC, Wascher DC, Treme G. Knee articular cartilage repair and restoration techniques: a review of the literature. *Sports Health*. 2016;8(2):153-160. doi:10.1177/1941738115611350
52. Saris DBF, Vanlauwe J, Victor J, et al. Characterized chondrocyte implantation results in better structural repair when treating symptomatic cartilage defects of the knee in a randomized controlled trial versus microfracture. *Am J Sports Med*. 2008;36(2):235-246. doi:10.1177/0363546507311095
53. Sherman SL, Garrity J, Bauer K, Cook J, Stannard J, Bugbee W. Fresh osteochondral allograft transplantation for the knee: current concepts. *J Am Acad Orthop Surg*. 2014;22(2):121-133. doi:10.5435/JAOS-22-02-121
54. Stoker AM, Stannard JP, Cook JL. Chondrocyte viability at time of transplantation for osteochondral allografts preserved by the Missouri Osteochondral Preservation System versus standard tissue bank protocol. *J Knee Surg*. 2018;31(8):772-780. doi:10.1055/s-0037-1608947
55. Tirico LEP, Demange MK, Santos LAU, et al. Development of a fresh osteochondral allograft program outside North America. *Cartilage*. 2016;7(3):222-228. doi:10.1177/1947603515618484
56. Tírigo LEP, McCauley JC, Pulido PA, Bugbee WD. Lesion size does not predict outcomes in fresh osteochondral allograft transplantation. *Am J Sports Med*. 2018;46(4):900-907. doi:10.1177/0363546517746106
57. Twyman RS, Desai K, Aichroth PM. Osteochondritis dissecans of the knee: a long-term study. *J Bone Joint Surg Br*. 1991;73(3):461-464. doi:10.1302/0301-620X.73B3.1670450
58. Viste A, Piperno M, Desmarchelier R, Grosclaude S, Moyen B, Fessy MH. Autologous chondrocyte implantation for traumatic full-thickness cartilage defects of the knee in 14 patients: 6-year functional outcomes. *Orthop Traumatol Surg Res*. 2012;98(7):737-743. doi:10.1016/j.otsr.2012.04.019
59. Wang D, Chang B, Coxe FR, et al. Clinically meaningful improvement after treatment of cartilage defects of the knee with osteochondral grafts. *Am J Sports Med*. 2019;47(1):71-81. doi:10.1177/0363546518808030
60. Wang D, Eliasberg CD, Wang T, et al. Similar outcomes after osteochondral allograft transplantation in anterior cruciate ligament-intact and -reconstructed knees: a comparative matched-group analysis with minimum 2-year follow-up. *Arthroscopy*. 2017;33(12):2198-2207. doi:10.1016/j.arthro.2017.06.034
61. Wang D, Rebolledo BJ, Dare DM, et al. Osteochondral allograft transplantation of the knee in patients with an elevated body mass index. *Cartilage*. 2019;10(2):214-221. doi:10.1177/1947603518754630
62. Wang T, Wang DX, Burge AJ, et al. Clinical and MRI outcomes of fresh osteochondral allograft transplantation after failed cartilage repair surgery in the knee. *J Bone Joint Surg Am*. 2018;100(22):1949-1959. doi:10.2106/JBJS.17.01418
63. Williams RJ, Ranawat AS, Potter HG, Carter T, Warren RF. Fresh stored allografts for the treatment of osteochondral defects of the knee. *J Bone Joint Surg Am*. 2007;89(4):718-726. doi:10.2106/JBJS.F.00625
64. Windt TS, Bekkers JEJ, Creemers LB, Dhert WJA, Saris DBF. Patient profiling in cartilage regeneration: prognostic factors determining success of treatment for cartilage defects. *Am J Sports Med*. 2009;37(suppl 1):58S-62S. doi:10.1177/0363546509349765