


## ORIGINAL RESEARCH

# Hürthle cell neoplasms of the thyroid: Pathologic outcomes and ultrasonographic analysis

Timothy J. Shin MD<sup>1,2</sup>  | Cyrus C. Rabbani MD<sup>1,2</sup> | Henna D. Murthy MD<sup>2</sup> | Katie Traylor MD<sup>2,3</sup> | Michael W. Sim MD<sup>1,2</sup>

<sup>1</sup>Department of Otolaryngology—Head and Neck Surgery, Indiana University, Indianapolis, Indiana

<sup>2</sup>Indiana University School of Medicine, Indianapolis, Indiana

<sup>3</sup>The Department of Radiology and Imaging Sciences, Indiana University, Indianapolis, Indiana

## Correspondence

Michael W. Sim, MD, Department of Otolaryngology—Head and Neck Surgery, Indiana University, Fesler Hall Ste #400 | 1130 W. Michigan Street | Indianapolis, IN 46202  
Email: mwsim@iu.edu

## Abstract

**Background:** Fine-needle aspiration (FNA) of thyroid nodules suspicious for Hürthle cell neoplasms (HCN) have uncertain rate of malignancy. We aim to characterize rate and predictors of malignancy at our institution and compare these findings with established literature to help guide management.

**Methods:** Single tertiary-referral center, retrospective study of 166 adults who underwent hemithyroidectomy or total thyroidectomy following FNA suspicious for HCN from 1998-2018. Demographic information and surgical histopathologic results were collected. Preoperative ultrasonography was independently scored on the American College of Radiology Thyroid Imaging Reporting and Data System (TI-RADS) by a board-certified head and neck radiologist.

**Results:** There were 39 males and 127 females. Overall, 25 (15.1%) patients had carcinoma, with 15 (9%) being Hürthle cell carcinoma (HCC). Men had higher incidence of carcinoma (25.6% v. 11.8%,  $P = .035$ ), and especially older males. Contralateral carcinoma was seen in 3 of 13 (23.1%) patients that underwent completion thyroidectomy. Patients with carcinoma had larger nodules (average diameter 3.3 cm versus 2.5 cm, respectively,  $P = .01$ ), but no association with TI-RADS.

**Conclusion:** Adults with nodules suspicious for HCN have significant risk of malignancy consistent with prior studies. Older males and larger nodule diameter are associated with malignancy in this cohort, but TI-RADS grade is not. These findings provide a framework for management and counseling for lesions suspicious for HCN.

## KEYWORDS

Hürthle cell neoplasm, thyroid cancer, thyroid cytology/FNA, thyroid nodule evaluation, thyroidectomy

## 1 | INTRODUCTION

Fine-needle aspiration (FNA) of the thyroid gland is a safe and effective diagnostic tool in the evaluation of thyroid nodules.<sup>1-4</sup> Diagnostic

terminology and morphologic criteria for cytologic analysis are established,<sup>5</sup> but there is diagnostic and prognostic uncertainty with specimens suspicious for Hürthle cell neoplasms (HCN) due to overlapping features in benign and malignant follicular thyroid lesions.<sup>6</sup>

This is an open access article under the terms of the Creative Commons Attribution-NonCommercial-NoDerivs License, which permits use and distribution in any medium, provided the original work is properly cited, the use is non-commercial and no modifications or adaptations are made.

© 2020 The Authors. *Laryngoscope Investigative Otolaryngology* published by Wiley Periodicals LLC. on behalf of The Triological Society.

This finding occurs in approximately 1% of ultrasound-guided FNA of thyroid incidentalomas.<sup>7</sup> Patients are typically offered hemithyroidectomy,<sup>8</sup> although not all patients opt to proceed with surgery.<sup>6</sup> Hemithyroidectomy patients found to have malignancy on surgical pathology are typically offered completion thyroidectomy.<sup>9</sup> Rates of thyroid malignancy found in patients who undergo surgery range from 14% to 46%.<sup>10-14</sup>

The wide range in rate of malignancy raises questions for prognosis, optimal management, and patient counseling. Prior research has identified male sex and older age as predictors of malignancy in HCN.<sup>8,10,12,15,16</sup> Sonographic features such as larger tumor size and hypochoic appearance have been shown in some studies to be significant.<sup>8,12,13,15,17,18</sup> TI-RADS has emerged as a radiographic scoring system developed by the American College of Radiology<sup>19</sup> that is valuable in evaluating thyroid nodules<sup>20</sup>; however, it has poor performance in differentiating Hürthle cell carcinoma (HCC) from adenoma.<sup>21</sup> Genomic studies have suggested HCC is genetically unique,<sup>22,23</sup> and sequencing has been used with some success to improve the specificity of FNA.<sup>24</sup>

We sought to perform a retrospective analysis of patients seen at our institution to determine if final pathologic diagnosis was consistent with published rates. Furthermore, we sought to elucidate predictors for malignancy that can be identified preoperatively to stratify patients, including demographic characteristics, ultrasonographic imaging, and the TI-RADS classification. These findings can be used in further meta-analyses to help determine optimal management of Hürthle cell neoplasms, as well as incorporated into patient evaluation, management, and counseling.

## 2 | MATERIALS AND METHODS

### 2.1 | Patient selection

Institutional Review Board approval was obtained. A retrospective chart review was performed of adult patients seen at a single academic US cancer center in a mid-size metropolitan city from 1998 to 2018. Patients were included if they had at least one thyroid nodule which underwent fine needle aspiration found to be suspicious for HCN on the cytology report, and subsequently underwent hemithyroidectomy or complete thyroidectomy. Cytologic analysis was routinely performed by board-certified cytopathologists and adhered to the diagnostic criteria established by the National Cancer Institute thyroid FNA guidelines following 2008.<sup>5</sup>

### 2.2 | Data collection

Demographic information was collected including age, gender, and race. Operative records, tissue pathology, and ultrasonographic imaging were collected. Preoperative ultrasound images were systematically and independently reviewed through computer-based radiographic image viewing software and scored by a fellowship-trained head and neck radiologist according to the American College

of Radiology Thyroid Imaging Reporting and Data System (TI-RADS).<sup>19</sup> The radiologist was blinded to the official radiology reports, cytology, and surgical pathology, and only had preoperative information available at the time of reading. The radiologist also measured thyroid nodule diameter and size.

### 2.3 | Statistical analysis

Statistical analysis was carried out between groups using two-sample *t*-tests, Chi Square, and Binary Logistic Regression statistical analysis using Microsoft Excel 2016 and STATA. *P*-values less than .05 were determined to be statistically significant.

## 3 | RESULTS

Initial data gathering included 583 patients, of which 328 did not undergo surgery and were excluded. Of the 255 remaining, 69 were excluded due to cytology not suspicious for HCN. Of the 186 remaining patients, 20 were excluded for incomplete records or duplicates. 166 total patients were included in the final analysis. There were 39 males and 127 females with an average age (SD) of 52.8 (13.1) years (Table 1). Preoperative ultrasonographic imaging was available for 98 patients.

### 3.1 | Surgical pathology

Overall, 25 patients (15.1%) were found to have thyroid malignancy (15 HCC, 4 follicular carcinoma, 4 follicular or oncocyctic variant papillary carcinoma, 1 medullary carcinoma, 1 well-differentiated carcinoma—summarized in Figure 1). Thirty-seven patients (22.3%) had occult micronodules with papillary carcinoma, but these were not counted as thyroid malignancy for the purposes of this study. Carcinoma was found in 13 of the 81 patients that underwent a hemithyroidectomy and 12 of the 85 patients that underwent a total thyroidectomy. Three of the 13 (23.1%) patients that underwent completion thyroidectomy following hemithyroidectomy were found to have contralateral malignancy. Two of these patients had papillary thyroid carcinoma in their primary specimen and were found to have contralateral papillary thyroid carcinoma. The third patient had HCC in the primary specimen, and was found to have contralateral HCC. Of the 141 patients who did not have malignancy, 91 (64.5%) had Hürthle cell adenoma, 16 (11.3%) had lymphocytic thyroiditis, 15 (10.6%) had nodular hyperplasia, 14 (9.9%) had diffuse goiter, and 5 (3.5%) had other benign findings or fibrosis.

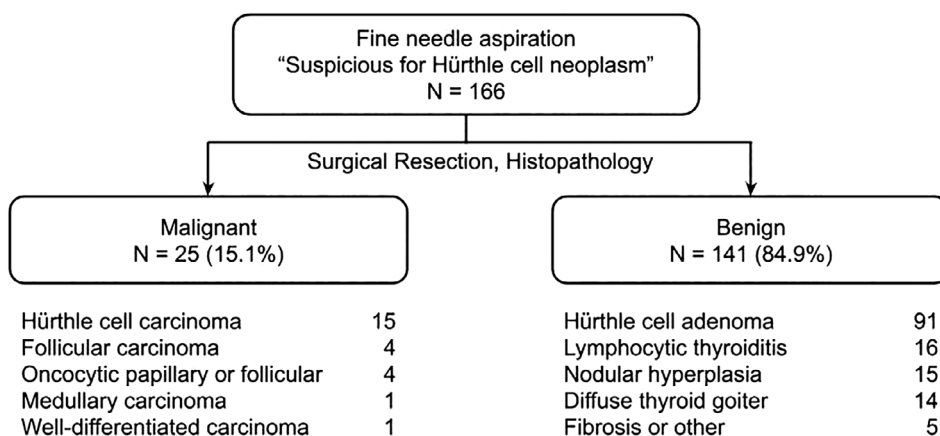
### 3.2 | Demographic associations

Men had a higher incidence of carcinoma (25.6% vs 11.8%,  $\chi^2 = 4.46$ ,  $P = .034$ ). The average age (SD) of men with malignancy was higher than women (59.4 [11.8] vs 47.4 [12.0] years,  $t = 2.46$ ,  $P = .02$ ,

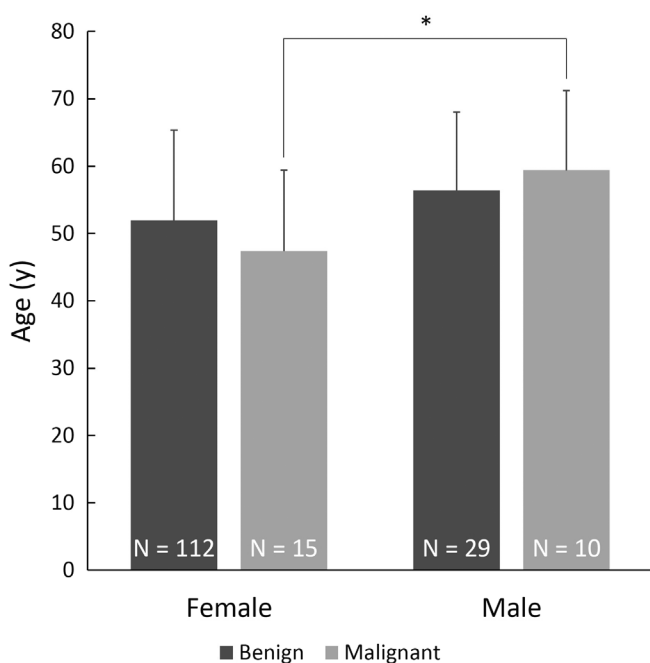
**TABLE 1** Age, gender, and race distribution

	Total n = 166	Benign n = 141	Malignant n = 25	P-value
Age, y (SD)	52.8 (13.1)	52.9 (13.2)	52.2 (13.2)	.81
Gender, n				.03
Male	39	29	10	
Female	127	112	15	
Race, n				.50
Black	20	18	2	
White	139	118	21	
Unknown/Other	7	5	2	

Abbreviation: n, number of patients.



**FIGURE 1** Surgical pathology results of 166 patients following hemithyroidectomy or thyroidectomy for patients with thyroid nodules which underwent fine-needle aspiration and were found to be suspicious for Hürthle cell neoplasm. N, number of patients



**FIGURE 2** Age and gender distribution. Older male patients with suspicion for Hürthle cell neoplasm (HCN) by fine-needle aspiration had significantly higher rate of malignancy. N, number of patients

**TABLE 2** Stratification of age; distribution of malignancy

Age (y)	Pathology	Frequency (n, %)		P-value
		Male	Female	
<40	Benign	2 (67%)	22 (84.6%)	.44
	Malignant	1 (33%)	4 (15.4%)	
≥40 & <60	Benign	16 (84.2%)	55 (87.3%)	.73
	Malignant	3 (15.8%)	8 (12.7%)	
≥60	Benign	11 (64.7%)	35 (92.1%)	.01
	Malignant	6 (35.3%)	3 (7.9%)	

Abbreviation: n, number of patients.

Figure 2). Age alone was not found to be a predictor of malignancy. With subgroup analysis, there was a significantly higher rate of carcinoma in men versus women in ages 60 years and greater (35.3% vs 7.9%,  $\chi^2 = 6.44$ ,  $p = .02$ , Table 2).

### 3.3 | Preoperative ultrasonography

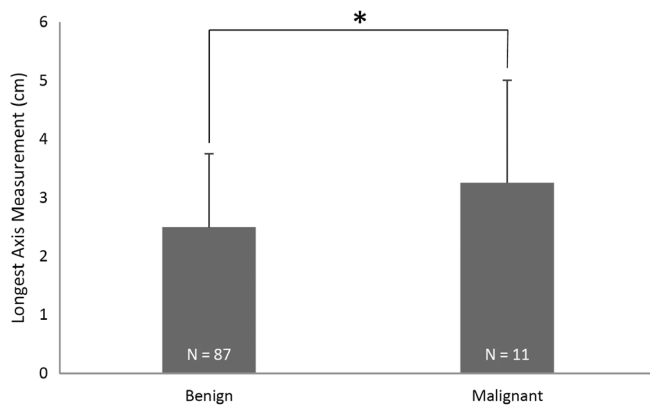
Preoperative ultrasonographic imaging was available in 98 patients (Table 3). 11 of the 98 patients were found to have carcinoma upon

thyroidectomy. Patients with carcinoma had significantly larger diameter nodules (3.26 vs 2.50 cm,  $P = .01$ , Figure 3). TI-RADS scoring did not significantly predict malignancy ( $\chi^2 = 0.669$ ,  $P = .88$ ). Binary logistic regression did not reveal significant independent predictive factors for the diagnosis of carcinoma on final surgical pathology (Table 4).

**TABLE 3** TI-RADS score distribution

		Malignancy		Total
		No	Yes	
TI-RADS score	1	0	0	0 (0%)
	2	4	0	4 (0%)
	3	33	5	38 (13.2%)
	4	41	5	46 (10.9%)
	5	9	1	10 (10%)
Total		87	11	98 (11.2%)

Abbreviation: TI-RADS, Thyroid Imaging Reporting and Data System.



**FIGURE 3** Longest axis measurement. Thyroid nodules suspicious for Hürthle cell neoplasm (HCN) by fine-needle aspiration that were ultimately found to be malignant lesions were significantly larger than nodules suspicious for HCN that were found to be benign. N, number of patients

**TABLE 4** Binary logistic regression model; predictors of malignancy

	$\beta$	SE	Wald	P-value	Exp ( $\beta$ )	95% CI for Exp ( $\beta$ )	
						Lower	Upper
Age (y)	-0.022	0.025	0.786	.375	0.978	0.930	1.028
Gender	-0.647	0.742	0.760	.383	0.524	0.122	2.242
Race	-19.177	10571.1	0.000	.999	0.000	0.000	
Longest axis measurement (cm)	0.353	0.220	2.571	.109	1.423	0.925	2.192
TI-RADS score	-0.003	0.479	0.000	.995	0.997	0.390	2.550
Constant	-1.237	2.361	0.275	.600	0.290		

Abbreviations:  $\beta$ , intercept; CI, confidence interval; Exp( $\beta$ ), Exponentiation of the  $\beta$  Coefficient; TI-RADS, Thyroid Imaging Reporting and Data System; Wald, Wald  $\chi^2$ .

## 4 | DISCUSSION

The overall rate of thyroid malignancy was 15.1%; this included oncocytic variants of other types of thyroid malignancy. This is consistent with rates previously described.<sup>10-14</sup> Of the patients who underwent an initial hemithyroidectomy and were found to have malignancy, 23.1% were found to have a contralateral malignancy after completion thyroidectomy. These findings can be incorporated into patient counseling and management.

Male sex was significantly associated with thyroid malignancy in patients with HCN. Prior studies have in some cases found sex to be an independent predictor for thyroid cancer<sup>6,16</sup>; others have not found it to be significant,<sup>10,12,13</sup> although in some cases it approaches significance.<sup>7</sup> This may also be related to higher prevalence of autoimmune conditions among females. While age has been found to be a significant predictor of malignancy in some studies,<sup>6,10,12</sup> age alone was not a predictor of malignancy in our series. However, with subgroup analysis, older aged males ( $\geq 60$  years) were found to have significantly higher incidence of thyroid malignancy. Cut-off values of 40 years, 45 years, and 65 years have previously been used to stratify patients.<sup>6,10,12</sup> Females predominate in all histologic types of thyroid cancer and this is also reflected in the female to male ratio in our series,<sup>25</sup> but older males with thyroid cancer may represent a high risk group. Meta-analysis or larger studies would be helpful in determining if this is truly a risk factor.

Average nodule size was found to be significantly larger in malignancies compared to benign nodules. Prior studies have sought to establish threshold values to stratify patients; for instance, diameters of 1.5 cm (odds ratio 8.00, 95% CI 1.92-33.37),<sup>12</sup> 2.5 cm (odds ratio 2.087, 95% CI 1.046-4.161),<sup>13</sup> 3 cm,<sup>6</sup> and 4 cm<sup>10</sup> have been used. For nodules without cytology, cut-off values of 3 cm or 4 cm are commonly used, and larger nodules are associated with greater risk of malignancy.<sup>18</sup> The use of cut-off values may provide convenient clinical application, but unfortunately contribute to a higher chance of type I error when applied to continuous variables and this may in part account for the variety of proposed cut-off values for age and nodule size described in the literature.<sup>26</sup>

TI-RADS scoring was not found to be significantly predictive of malignancy in our study. This agrees with a prior study by Santana

et al. who found that TI-RADS 4 or 5 had a specificity of only 51.8% and a likelihood ratio of 1.21 for HCC in 101 patients with HCN.<sup>21</sup> While TI-RADS may have limited utility in predicting malignancy of HCN lesions, other sonographic features such as solid (rather than cystic) appearance, hypoechoic echogenicity, absence of calcifications, and ill-defined margins have been shown in some studies to be helpful in predicting malignancy.<sup>7,8,12,13,15,17,18</sup> Our findings suggest TI-RADS is not reliable in the evaluation of HCN lesions, but review of preoperative ultrasonography may be clinically useful.

Binary logistic regression modeling did not identify any significant independent predictors of malignancy in this series. This study is limited in that it is a retrospective single-institution experience in a mid-size US metropolitan city. Patients that did not undergo thyroidectomy did not have pathologic follow-up and were unable to be included in the analysis; therefore, the true incidence of carcinoma in patients with HCN may be overestimated. Ultrasound images were not available for the entire cohort of patients, but they were available for the majority of patients. Due to the limited number of patients with disease when stratified by type of thyroid malignancy, analyses specific to type of thyroid malignancy were not useful. Further investigations and meta-analysis would be useful in increasing study power. While outside the scope of the present study, molecular testing has increasingly been used to guide treatment decisions, and should be considered if available.<sup>24</sup>

In conclusion, adults with lesions suspicious for HCN on thyroid fine needle aspiration have a significant risk of thyroid malignancy. Completion thyroidectomy should be considered in patients who are found to have malignancy after hemithyroidectomy, although this must be weighed with the clinical significance of contralateral malignancy, as not all micropapillary carcinomas are treated surgically. Patients who are older males or have larger nodules are associated with greater risk of malignancy. TI-RADS grading was not useful for determining risk of malignancy for HCN. We suggest that age, sex, and nodule size should be carefully incorporated into surgical decision-making and discussion with patients and their families.

## CONFLICT OF INTEREST

The authors declare no potential conflict of interest.

## ORCID

Timothy J. Shin  <https://orcid.org/0000-0001-7460-9458>

## REFERENCES

1. Polyzos Stergios A., Anastasilakis Athanasios D.. Clinical complications following thyroid fine-needle biopsy: a systematic review. *Clinical Endocrinology*. 2009;71(2):157-165. <http://dx.doi.org/10.1111/j.1365-2265.2009.03522.x>.
2. Cooper David S., Doherty Gerard M., Haugen Bryan R., Kloos Richard T., Lee Stephanie L., Mandel Susan J., Mazzaferri Ernest L., McIver Bryan, Pacini Furio, Schlumberger Martin, Sherman Steven I., Steward David L., Tuttle R. Michael. Revised American Thyroid Association Management Guidelines for Patients with Thyroid Nodules and Differentiated Thyroid Cancer. *Thyroid*. 2009;19(11):1167-1214. <http://dx.doi.org/10.1089/thy.2009.0110>.
3. Frates Mary C., Benson Carol B., Charboneau J. William, Cibas Edmund S., Clark Orlo H., Coleman Beverly G., Cronan John J., Doubilet Peter M., Evans Douglas B., Goellner John R., Hay Ian D., Hertzberg Barbara S., Intenzo Charles M., Jeffrey R. Brooke, Langer Jill E., Larsen P. Reed, Mandel Susan J., Middleton William D., Reading Carl C., Sherman Steven I., Tessler Franklin N.. Management of Thyroid Nodules Detected at US. *Ultrasound Quarterly*. 2006;22(4):231-238. <http://dx.doi.org/10.1097/O1.ruq.0000226877.19937.a1>.
4. Suen KC. Fine-needle aspiration biopsy of the thyroid. *CMAJ*. 2002;167(5):491-495.
5. Baloch ZW, LiVolsi VA, Asa SL, et al. Diagnostic terminology and morphologic criteria for cytologic diagnosis of thyroid lesions: a synopsis of the national cancer institute thyroid fine-needle aspiration state of the science conference. *Diagn Cytopathol*. 2008;36:425-437. <https://doi.org/10.1002/dc.20830>
6. Baloch ZW, Fleisher S, LiVolsi VA, Gupta PK. Diagnosis of "follicular neoplasm": a gray zone in thyroid fine-needle aspiration cytology. *Diagn Cytopathol*. 2002;26(1):41-44. <https://doi.org/10.1002/dc.10043>
7. Nam-Goong IS, Kim HY, Gong G, et al. Ultrasonography-guided fine-needle aspiration of thyroid incidentaloma: Correlation with pathological findings. *Clin Endocrinol*. 2004;60(1):21-28. <https://doi.org/10.1046/j.1365-2265.2003.01912.x>
8. Goffredo P, Roman SA, Sosa JA. Hurthle cell carcinoma: a population-level analysis of 3311 patients. *Cancer*. 2013;119(3):504-511. <https://doi.org/10.1002/cncr.27770>
9. Kupferman Michael E., Mandel Susan J., DiDonato Liesje, Wolf Pat, Weber Randal S.. Safety of Completion Thyroidectomy Following Unilateral Lobectomy for Well-Differentiated Thyroid Cancer. *The Laryngoscope*. 2002;112(7):1209-1212. <http://dx.doi.org/10.1097/00005537-200207000-00013>.
10. Strazisar B, Petric R, Seseck M, Zgajnar J, Hocevar M, Besic N. Predictive factors of carcinoma in 279 patients with hurthle cell neoplasm of the thyroid gland. *J Surg Oncol*. 2010;101(7):582-586. <https://doi.org/10.1002/jso.21526>
11. Roh MH, Jo VY, Stelow EB, et al. The predictive value of the fine-needle aspiration diagnosis "Suspicious for a follicular neoplasm, Hurthle cell type" in patients with Hashimoto thyroiditis. *Am J Clin Pathol*. 2011;135(1):139-145. <https://doi.org/10.1309/AJCP0RW2WMDUAKGK>
12. Kim TH, Lim JA, Ahn HY, et al. Tumor size and age predict the risk of malignancy in Hurthle cell neoplasm of the thyroid and can therefore guide the extent of initial thyroid surgery. *Thyroid*. 2010;20(11):1229-1234. <https://doi.org/10.1089/thy.2009.0443>
13. Lee KH, Shin JH, Ko ES, et al. Predictive factors of malignancy in patients with cytologically suspicious for Hurthle cell neoplasm of thyroid nodules. *Int J Surg*. 2013;11(9):898-902. <https://doi.org/10.1016/j.ijsu.2013.07.010>
14. Agarwal S, Bychkov A, Jung CK, et al. The prevalence and surgical outcomes of Hurthle cell lesions in FNAs of the thyroid: a multi-institutional study in 6 Asian countries. *Cancer Cytopathol*. 2019;127(3):181-191. <https://doi.org/10.1002/cncy.22101>
15. Lopez-Penabad Luis, Chiu Alice C., Hoff Ana O., Schultz Pamela, Gaztambide Sonia, Ordoñez Nelson G., Sherman Steven I.. Prognostic factors in patients with Hurthle cell neoplasms of the thyroid. *Cancer*. 2003;97(5):1186-1194. <http://dx.doi.org/10.1002/cncr.11176>.
16. Dahl Linda D., Myssiorek David, Heller Keith S.. Hurthle Cell Neoplasms of the Thyroid. *The Laryngoscope*. 2002;112(12):2178-2180. <http://dx.doi.org/10.1097/00005537-200212000-00009>.
17. Sillery John C., Reading Carl C., Charboneau J. William, Henrichsen Tara L., Hay Ian D., Mandrekar Jayawant N.. Thyroid Follicular Carcinoma: Sonographic Features of 50 Cases. *American Journal of Roentgenology*. 2010;194(1):44-54. <http://dx.doi.org/10.2214/ajr.09.3195>.

18. Shin JJ, Caragacianu D, Randolph GW. Impact of thyroid nodule size on prevalence and post-test probability of malignancy: a systematic review. *Laryngoscope*. 2015;125(1):263-272. <https://doi.org/10.1002/lary.24784>
19. Tessler Franklin N., Middleton William D., Grant Edward G., Hoang Jenny K., Berland Lincoln L., Teefey Sharlene A., Cronan John J., Beland Michael D., Desser Terry S., Frates Mary C., Hammers Lynwood W., Hamper Ulrike M., Langer Jill E., Reading Carl C., Scoutt Leslie M., Stavros A. Thomas. ACR Thyroid Imaging, Reporting and Data System (TI-RADS): White Paper of the ACR TI-RADS Committee. *Journal of the American College of Radiology*. 2017; 14(5):587-595. <http://dx.doi.org/10.1016/j.jacr.2017.01.046>.
20. Wei X, Li Y, Zhang S, Gao M. Thyroid imaging reporting and data system (TI-RADS) in the diagnostic value of thyroid nodules: a systematic review. *Tumor Biol*. 2014;35(7):6769-6776. <https://doi.org/10.1007/s13277-014-1837-9>
21. Santana Nathalie Oliveira, Freitas Ricardo Miguel Costa, Marcos Vinicius Neves, Chammas Maria Cristina, Camargo Rosalinda Yossie Asato, Schmerling Cláudia Kliemann, Vanderlei Felipe Augusto Brasileiro, Hoff Ana Oliveira, Marui Suemi, Danilovic Debora Lucia Seguro. Diagnostic performance of thyroid ultrasound in Hürthle cell carcinomas. *Archives of Endocrinology and Metabolism*. 2019;<http://dx.doi.org/10.20945/2359-3997000000131>.
22. Ganly Ian, Ricarte Filho Julio, Eng Stephanie, Ghossein Ronald, Morris Luc G. T., Liang Yupu, Socci Nicholas, Kannan Kasthuri, Mo Qianxing, Fagin James A., Chan Timothy A.. Genomic Dissection of Hurthle Cell Carcinoma Reveals a Unique Class of Thyroid Malignancy. *The Journal of Clinical Endocrinology & Metabolism*. 2013; 98(5):E962-E972. <http://dx.doi.org/10.1210/jc.2012-3539>.
23. Li W, Xia S, Aronova A, et al. CHL1 expression differentiates Hürthle cell carcinoma from benign Hürthle cell nodules. *J Surg Oncol*. 2018;118(6):1042-1049. <https://doi.org/10.1002/jso.25214>
24. Hao Y, Duh QY, Kloos RT, et al. Identification of Hürthle cell cancers: solving a clinical challenge with genomic sequencing and a trio of machine learning algorithms. *BMC Syst Biol*. 2019;13(Suppl 2):1-14. <https://doi.org/10.1186/s12918-019-0693-z>
25. Hundahl Scott A., Fleming Irvin D., Fremgen Amy M., Menck Herman R. A National Cancer Data Base report on 53,856 cases of thyroid carcinoma treated in the U.S., 1985-1995. *Cancer*. 1998;83(12): 2638-2648. [http://dx.doi.org/10.1002/\(sici\)1097-0142\(19981215\)83:12<2638::aid-cncr31>3.0.co;2-1](http://dx.doi.org/10.1002/(sici)1097-0142(19981215)83:12<2638::aid-cncr31>3.0.co;2-1).
26. Royston P, Altman DG, Sauerbrei W. Dichotomizing continuous predictors in multiple regression: a bad idea. *Stat Med*. 2006;25(1):127-141. <https://doi.org/10.1002/sim.2331>

**How to cite this article:** Shin TJ, Rabbani CC, Murthy HD, Traylor K, Sim MW. Hürthle cell neoplasms of the thyroid: Pathologic outcomes and ultrasonographic analysis. *Laryngoscope Investigative Otolaryngology*. 2020;5:1254-1259. <https://doi.org/10.1002/lio2.465>