



Contents lists available at ScienceDirect

## International Journal of Surgery Case Reports

journal homepage: [www.casereports.com](http://www.casereports.com)

# Appendectomy or not in middle-aged male with non-inflamed appendix in Amyand's hernia? Case report and literature review<sup>☆</sup>

David S. Millay<sup>a</sup>, Chiedozie Max Ofoma<sup>a</sup>, Lionel R. Brounts<sup>a,b,\*</sup><sup>a</sup> Indiana University School of Medicine, 2101 E Coliseum Blvd E, Fort Wayne, IN, 46805, USA<sup>b</sup> VA Northern Indiana Health Care System, Department of General Surgery, 2121 Lake Avenue, Fort Wayne, IN, 46805, USA

## ARTICLE INFO

## Article history:

Received 27 October 2020

Received in revised form 2 November 2020

Accepted 3 November 2020

Available online 7 November 2020

## Keywords:

Amyand's hernia

Inguinal hernia

Case report

Classification

Literature review

Appendectomy

## ABSTRACT

**INTRODUCTION:** An Amyand's hernia is a rare disease where a vermiform appendix is found within an inguinal hernia sac. It is reported in the literature as having an incidence between 0.4%–1.0% of reported hernia cases. Typically, an incidental finding, Amyand's hernia is consequently found more frequently intra-operatively rather than preoperatively.

**PRESENTATION OF CASE:** This case is a recount of a 56-year-old male, who presented in an outpatient setting for the evaluation of right inguinal pain and bulge. The patient was diagnosed with a vermiform appendix within the indirect hernia. The patient underwent elective repair of his inguinal hernia via Transabdominal Preperitoneal (TAPP) approach of the hernia with avoidance of appendectomy.

**DISCUSSION:** An Amyand's hernia presents a challenging diagnosis and the treatment algorithm is contingent on the condition of the appendix in individual cases. This case presents a Type 1 Amyand's hernia that was repaired through laparoscopic approach using prosthetic mesh. The aim of this case study highlights the approach to surgical decision making in the diagnosis and treatment of Amyand's hernia proposed in the current literature.

**CONCLUSION:** This case presents a rare condition known as Amyand's hernia followed by a discussion on the epidemiology, diagnostic workup, and treatment options. Treatment is dependent on the state of the appendix found in the hernia sac and the clinical scenario. Comprehensive literature review shows that the true prevalence of this disease is lower than classically described and still has no clear standardized approaches.

Published by Elsevier Ltd on behalf of IJS Publishing Group Ltd. This is an open access article under the CC BY-NC-ND license (<http://creativecommons.org/licenses/by-nc-nd/4.0/>).

## 1. Introduction

An Amyand's hernia is a rare disease where a vermiform appendix is found within an inguinal hernia sac. This rare pathology, which is named after the French-born, English Surgeon Claudius Amyand, can occur either with or without appendiceal inflammation. It is reported in the literature as having an incidence between 0.4%–1.0% of reported hernia cases [1–3]. Typically an incidental finding, Amyand's hernia is consequently found more frequently intra-operatively rather than preoperatively [1,2,4–6]. There are no evidence-based approaches for dealing with this disease and many controversies exist due the fact that there are no randomized-controlled studies. There have been some proposed treatment algorithms, but without more research, no clear guidelines for surgeons are available [1,7]. Overall the treatment

algorithm is contingent on the condition of the appendix in individual cases. We present a case of a Type 1 Amyand's hernia which was reduced intra-operatively without an appendectomy and repaired through a laparoscopic approach using a prosthetic mesh. The aim of this case study highlights the approach to surgical decision making in the diagnosis and treatment of Amyand's hernia proposed in the current literature. In addition, we review the current literature regarding its management. This case has been reported in accordance with the SCARE criteria [8].

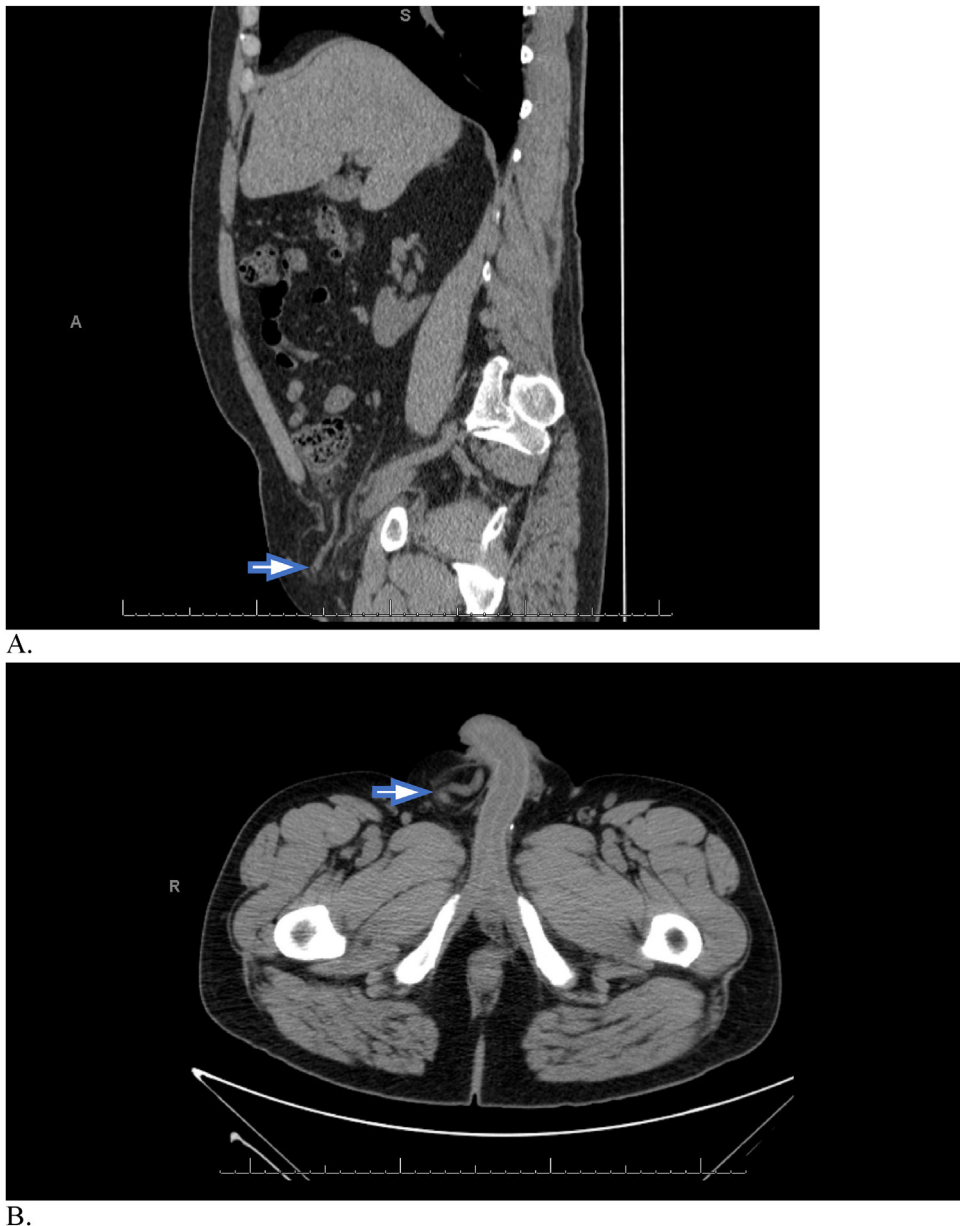## 2. Presentation of case

A 56-year-old male with a history of medication-controlled hypertension and hyperlipidemia was referred by his primary care provider for a right-sided inguinal mass which had progressively enlarged in the past year. The patient reported pain exacerbated by bowel movements, voiding, and lifting. Pertinent surgical history included an open left inguinal hernia repair 30–40 years ago. He denied any history of constipation, history of smoking or alcohol abuse, or pertinent family history. On physical exam the patient was afebrile, non-tachycardic and normotensive. Groin examination revealed a palpable large, inguinal mass with minimal tenderness to palpation and no overlying skin changes. The hernia was only

<sup>☆</sup> This material is the result of work supported with resources and the use of facilities at the Northern Indiana Health Care System. The contents do not represent the views of the U.S. Department of Veterans Affairs or the United States Government.

\* Corresponding author at: Indiana University School of Medicine, 2101 E Coliseum Blvd E, Fort Wayne, IN, 46805, USA.

E-mail address: [lrbrounts@gmail.com](mailto:lrbrounts@gmail.com) (L.R. Brounts).



**Fig. 1.** Non-contrast-enhanced CT image (sagittal view (A) and axial view (B)). A blind-ending tubular structure in the right inguinal canal with no signs of inflammation (Arrow).

partially reducible on physical exam. A pre-consult non-contrast-enhanced Computed Tomography (CT) abdomen/pelvis ordered by the Primary Care Physician revealed a right-sided hernia with a non-dilated appendix (Fig. 1). Pre-operative workup, including laboratory and electrocardiogram was unremarkable.

The patient was consented for a diagnostic laparoscopy and hernia repair through a trans-abdominal pre-peritoneal (TAPP) approach with possible appendectomy. Intra-operatively, the patient had some adhesions in the right lower quadrant which were taken down by the staff surgeon and allowed full mobilization of the cecum. The appendix was easily reduced and appeared without inflammation or other abnormality (Fig. 2). Inspection showed an indirect hernia (Fig. 3). The peritoneum was taken down and the indirect hernia sac was reduced. The hernia defect was repaired using a large 3D Bard prosthetic mesh without appendectomy. The patient was sent home the same day and was seen three weeks post-operatively in clinic at which time he was doing well and pleased with the results.

### 3. Discussion

Due to the rarity of Amyand's hernia and recent increased literature interest, it would be worthwhile to review the current literature for surgical recommendations [7]. In a Scopus search for the last 5 years from January 2015 to June 2020 there were 86 articles related to appendiceal hernias. Cases other than inguinal hernias were excluded. The articles were sorted for larger studies, meta analyses, and literature reviews to garner the current opinions on surgical approach. There were 14 articles that fit the review criteria, and these were used for our discussion of the surgical approach opinions.

Amyand's hernia is the presentation of a vermiform appendix within an inguinal hernia. Typically it presents in an indirect rather than direct hernia [9]. It is interestingly a combination of the two most common pediatric surgeries, while being a rare surgical finding [1,10]. It is classically reported in the literature as having an incidence of 1.0% in inguinal hernias, though some reviews indicate that among adults a more accurate estimate would be between

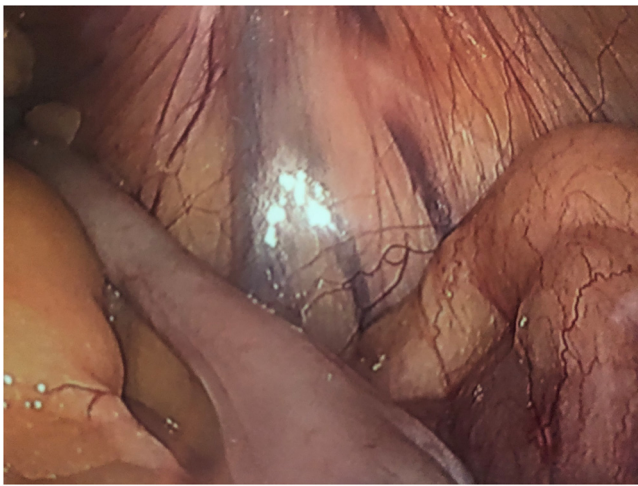


Fig. 2. Laparoscopic findings of reduced appendix with no signs of inflammation.

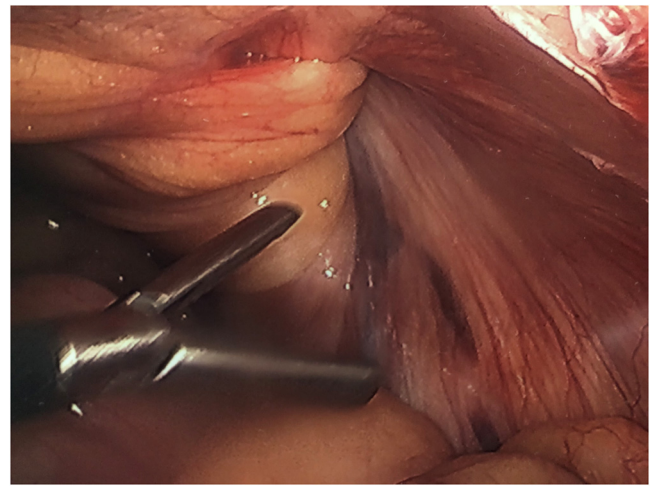


Fig. 3. Laparoscopic findings of indirect hernia.

0.4–0.6% [1,3,11]. It carries a bimodal distribution being found predominantly in the elderly and the young with a much heavier incidence in males and a predilection to incarceration [1,9]. It occurs more commonly in the pediatric population, being heavily associated with appendicitis in neonates, which is thought to be related to a patent process vaginalis [12,13].

Amyand's is typically found intra-operatively instead of pre-operatively. Many times, this is because patients present with incarcerated bowel, requiring emergency surgery and foregoing imaging [1,9]. In the case of our patient, the presence of the appendix within the inguinal hernia was diagnosed preoperatively by CT which happens in under 25% of the cases in the literature [7]. CT is highly sensitive and specific in diagnosing acute appendicitis, but the use of both CT and US for the diagnosis of Amyand's hernia is an area of debate [1,3,6]. Vermillion et al. reported the first laparoscopic Amyand's hernia reduction in 1999 and others have reported this approach [14,15]. In our case the pre-operative CT

scan ordered by the Primary Care Physician allowed us to determine a likely Amyand's type 1 hernia and to plan a laparoscopic approach with a trans-abdominal pre-peritoneal hernia repair with prosthetic mesh.

The two main controversies in the treatment of this type of hernia are when to perform an appendectomy and when to use mesh [2]. Regarding the former, the first two classes in the Losanoff and Basson classification seem to be the areas of debate on this topic with category 2 being the most controversial [4]. In our patient we did not perform an appendectomy as the appendix did not show signs of inflammation, either pre-operatively or intra-operatively, and no great manipulation had to be done to reduce it from the hernia sac. Both the Losanoff and Basson classification—the most followed algorithm—and the Rikki modification recommend hernia reduction and mesh repair without appendectomy, but there are authors who have recommended appendectomy for all cases of Amyand's hernia due to the possibility of repeat herniation, chance

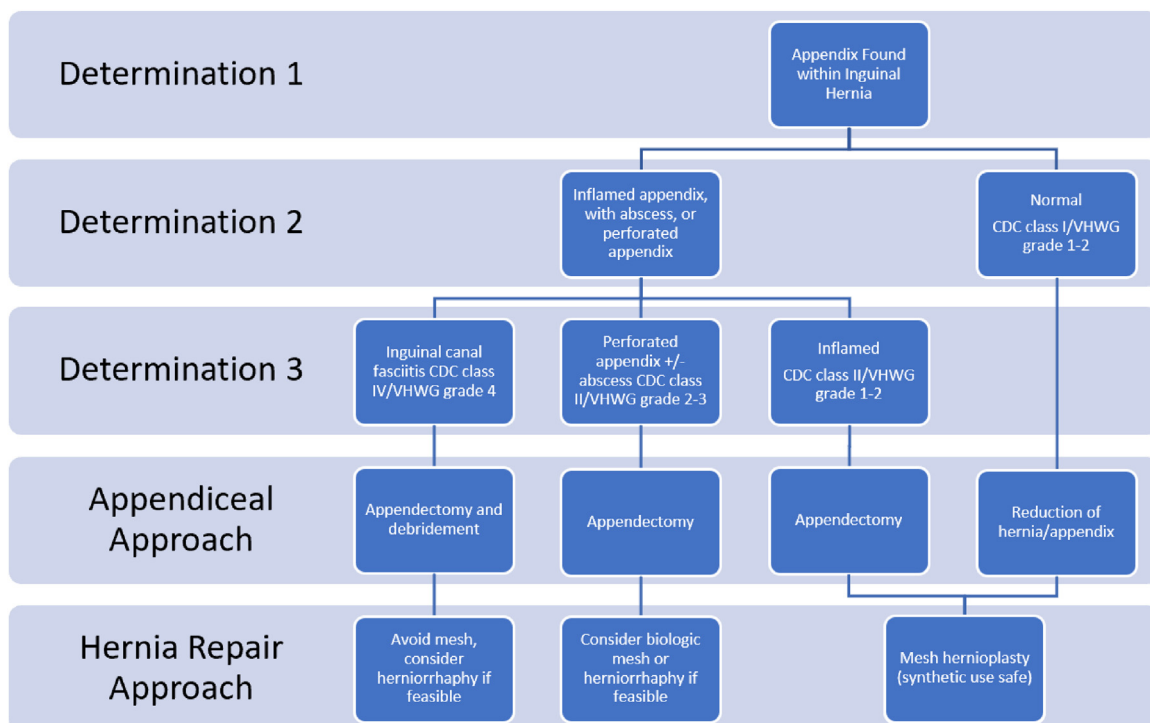


Fig. 4. Graphic adapted from surgical algorithm proposed by Papaconstantinou et al. [7].

of future appendicitis and need for future surgery [3,9]. The consensus of the articles cited seems to indicate that appendectomy without regard to the status of the appendix has declined over the last several years; however, this may simply be an opinion consensus by the authors and not actually backed up by the data as Papaconstantinou et al., showed a significantly high rate of appendectomy even without appendiceal inflammation [7].

With regards to mesh repair, the traditional approach has been to avoid it whenever signs of inflammation are present. Some, however, argue that even with mild signs of inflammation, the benefit of the mesh repair and the low likelihood of progression once the appendix is outside of the hernia sac, outweighs the concern for progression of inflammation [14,16]. Others have recommended a laparoscopic approach for the appendectomy immediately followed by an open approach for the hernia defect or a two-staged approach with a future surgical date for the hernia repair [7,14]. The opinion in favor of more substantial use of mesh seems to fall in line with 2020 WSES guidelines for complicated abdominal hernias [7]. Papaconstantinou et al., proposed a new surgical approach algorithm with increased use of mesh based on the recommendations from these guidelines and recommend utilizing the CDC surgical wound classification and the Ventral Hernia Working Group Grading platform (Fig. 4) [7].

#### 4. Conclusion

Amyand's hernia is a rare surgical entity that still lacks a standard surgical approach. This lack of consensus seems to arise from a lack of research, especially regarding newer surgical repair options like biosynthetic mesh or benefits of laparoscopic approach, leading to lack of a universally accepted algorithmic surgical approach. The presence of only one recent meta-analysis article found in the literature underlines the importance of further investigation into this topic. While an attempt at surgical approach partly addressed, by Papaconstantinou, Rikki, Losanoff and Basson, there is a lack of breakdown with regards to the hernia appearance, mesh type, and surgical method, though Papaconstantinou et al. made a significant headway in their more advanced surgical algorithm. The use of CT scan can assist in pre-operative planning, but in most cases is not indicated. Although many algorithms indicate no need for appendectomy if the appendix is not inflamed, there still seems to be a significant rate of appendectomy in Amyand's hernias without appendiceal inflammation. More research could change this lack of consensus. Lastly, regarding the use of mesh, although the status of the appendix needs to be taken into consideration, there seems to be an increased favor of more substantial use of mesh. In conclusion each case should be given special consideration for multiple factors. In our case we performed a reduction of a normal appendix and repaired the hernia defect with a prosthetic mesh using a TAPP approach without appendectomy. Overall surgical treatment depends on surgeon's experience and on the clinical situation, but further research is needed into this rare surgical disease.

#### Declaration of Competing Interest

The authors report no declarations of interest.

#### Funding

No sources of Funding.

#### Open Access

This article is published Open Access at [sciencedirect.com](https://www.sciencedirect.com). It is distributed under the [IJSCR Supplemental terms and conditions](#), which permits unrestricted non commercial use, distribution, and reproduction in any medium, provided the original authors and source are credited.

#### Ethical approval

No need for Ethical Approval.

#### Consent

Written Informed Consent was obtained from the patient for publication of this case report and accompanying images. A copy of the written consent is available for review by the Editor-in-Chief of this journal on request.

#### Author contribution

All authors contributed equally to the paper including writing and editing the paper.

#### Registration of research studies

N/A.

#### Guarantor

Lionel R Brounts, MD, FACS.

#### Provenance and peer review

Not commissioned, externally peer-reviewed.

#### References

- [1] D. Patoulias, M. Kalogirou, I. Patoulias, Amyand's hernia: an up-to-date review of the literature, *Acta Med. (Hradec Kralove)* 60 (3) (2017) 131–134.
- [2] T. Kalayci, ÜH. İLİKlerden, Management of incidental Amyand hernia with a case report, *East. J. Med.* 24 (4) (2019) 551–553.
- [3] A. Michalinos, D. Moris, S. Vernadakis, Amyand's hernia: a review, *Am. J. Surg.* 207 (6) (2014) 989–995.
- [4] Y. Shaban, A. Elkbuli, M. McKenney, D. Boneva, Amyand's hernia: a case report and review of the literature, *Int. J. Surg. Case Rep.* 47 (2018) 92–96.
- [5] W. Kromka, A.S. Rau, C.J. Fox, Amyand's hernia with acute gangrenous appendicitis and cecal perforation: a case report and review of the literature, *Int. J. Surg. Case Rep.* 44 (2018) 8–10.
- [6] A. Drago, M. Carbone, V. Lorusso, et al., Amyand's hernia: role of CT for a correct diagnosis, *G. Chir.* 40 (1) (2019) 44–48.
- [7] D. Papaconstantinou, Z. Garoufalia, S. Kykalos, et al., Implications of the presence of the vermiform appendix inside an inguinal hernia (Amyand's hernia): a systematic review of the literature, *Hernia* 24 (2020) 951–959.
- [8] R.A. Agha, M.R. Borrelli, R. Farwana, K. Koshy, A.J. Fowler, D.P. Orgill, The SCARE 2018 statement: updating consensus Surgical CAse REport (SCARE) guidelines, *Int. J. Surg.* (60) (2018) 132–136.
- [9] B. Sarici, S. Akbulut, T. Piskin, Appendiceal carcinoid tumor within Amyand's hernia: a case report and review of the literature, *Turk. J. Emerg. Med.* 19 (2) (2019) 73–75.
- [10] E.B. Cigsar, C.A. Karadag, A.I. Dokucu, Amyand's hernia: 11 years of experience, *J. Pediatr. Surg.* 51 (8) (2016) 1327–1329.
- [11] K. Rajaguru, D. Tan Ee Lee, Amyand's hernia with appendicitis masquerading as Fournier's gangrene: a case report and review of the literature, *J. Med. Case Rep.* 10 (1) (2016) 263.
- [12] H.A. Almetaher, M.A. Mansour, M.A. Arafa, Management of Amyand's hernia in children: should appendectomy be mandatory or not? *Ann. Pediatr. Surg.* 16 (1) (2020).
- [13] F. Fascetti-Leon, W. Sherwood, Neonatal appendicitis and incarcerated inguinal hernia: case report and review of the literature, *J. Indian Assoc. Pediatr. Surg.* 22 (4) (2017) 248–250.
- [14] D. Sahu, S. Swain, M. Wani, P.K. Reddy, Amyand's hernia: our experience in the laparoscopic era, *J. Minim. Access Surg.* 11 (2) (2015) 151–153.
- [15] J.M. Vermillion, S.W. Abernathy, S.K. Snyder, Laparoscopic reduction of Amyand's hernia, *Hernia* 3 (3) (1999) 159–160.
- [16] G. Desai, Pande P. Suhani, S. Thomas, Amyand's hernia: our experience and review of literature, *Arq. Bras. Cir. Dig.* 30 (4) (2017) 287–288.