

# Primary cutaneous peripheral T-cell lymphoma, not otherwise specified with mammalian target of rapamycin mutation: A novel finding for targeted treatment



Carlo De la Sancha, MD,<sup>a</sup> Callie Burgin, MD,<sup>b</sup> Simon Warren, MBBS,<sup>a</sup> Kristin Hoffmann, MD,<sup>b</sup> Utpal Davé, MD,<sup>b</sup> and Mehdi Nassiri, MD<sup>a</sup>  
Indianapolis, Indiana

**Key words:** BCL6 corepressor; BCL6 corepressor loss; CD30<sup>-</sup> lymphoma; CD30<sup>-</sup> T-cell lymphoma; CD30<sup>-</sup> cutaneous T-cell lymphoma; CD20; cutaneous T-cell lymphoma, cutaneous T-cell lymphoma, not otherwise specified; mammalian target of rapamycin; mammalian target of rapamycin mutation; mammalian target of rapamycin inhibitor; peripheral T-cell lymphoma; peripheral T-cell lymphoma, unspecified; peripheral T-cell lymphoma, not otherwise specified; primary cutaneous lymphoma; primary cutaneous peripheral T-cell lymphoma; primary cutaneous peripheral T cell lymphoma, not otherwise specified; rituximab; T-cell lymphoma; TAK-228.

## INTRODUCTION

Primary cutaneous peripheral T-cell lymphoma, not otherwise specified (pcPTCL-NOS) is a rare, progressive, and often fatal disease with no specific treatment regimen that presents as rapidly enlarging plaques or nodules. Here, we present a case of progressive pcPTCL-NOS with mammalian target of rapamycin (mTOR) mutation and variable T-cell antigen expression. mTOR mutation in pcPTCL-NOS may represent a new therapeutic target.

## CASE REPORT

A 70-year old white man with a history of T-cell prolymphocytic leukemia (2001), post-allogenic bone marrow transplant (2004), and donor-derived natural killer lymphoproliferative disorder (2017) had 2 adjacent asymptomatic 4-cm indurated pink nonscaly plaques on the lower abdomen. Biopsy found a diffuse dermal infiltrate of medium-sized atypical lymphocytes positive for CD2, CD3, CD5, CD7, CD8, CD20, weak CD4, and TCL1 and negative for CD30 (Fig 1, A and B). Short tandem repeat analysis found that this neoplasm was of host origin. T-cell receptor analysis (T-cell receptor  $\beta$  and T-cell receptor  $\gamma$  by polymerase chain reaction and

### Abbreviations used:

mTOR:	mammalian target of rapamycin
pcPTCL-NOS:	primary cutaneous peripheral T-cell lymphoma, not otherwise specified

Adaptive Biotechnologies clonoSEQ next-generation sequencing) showed clonality (75 bp and 255 bp), which was different from his original T-cell prolymphocytic leukemia (63 bp). Next-generation sequencing (FoundationOne Heme) found mTOR mutations (E1799K, S2215F at VAF of 1.6% and 44.4%, respectively) and BCL6 corepressor loss. The patient was treated with topical clobetasol 0.05% for 1 month. At follow-up, the plaques had coalesced, thickened, and developed overlying peau d'orange appearance. Repeat biopsy found loss of CD4. He also had axillary lymphadenopathy, breast mass, and new cutaneous plaques and nodules with similar clone and immunophenotype. All were treated successfully with local radiotherapy over the next 10 months. He then experienced rapid disease progression with numerous thick indurated and variably ulcerated plaques and nodules on the

From the Departments of Pathology and Laboratory Medicine<sup>a</sup> and Dermatology,<sup>b</sup> Indiana University School of Medicine.

Funding sources: None.

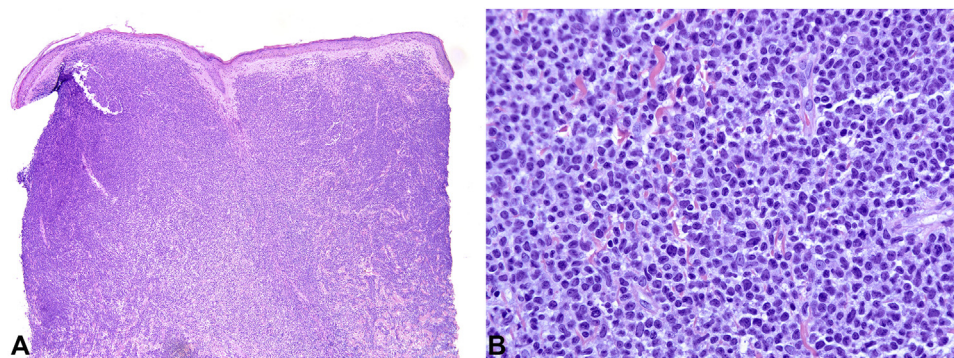
Conflicts of interest: None disclosed.

Correspondence to: Mehdi Nassiri, MD, Department of Pathology and Laboratory Medicine, Indiana University School of Medicine, 350 W 11th St, Indianapolis, IN 46202. E-mail: mnassiri@iupui.edu.

JAAD Case Reports 2020;6:1342-4.  
2352-5126

© 2020 by the American Academy of Dermatology, Inc. Published by Elsevier, Inc. This is an open access article under the CC BY-NC-ND license (<http://creativecommons.org/licenses/by-nc-nd/4.0/>).

<https://doi.org/10.1016/j.jidcr.2020.08.041>



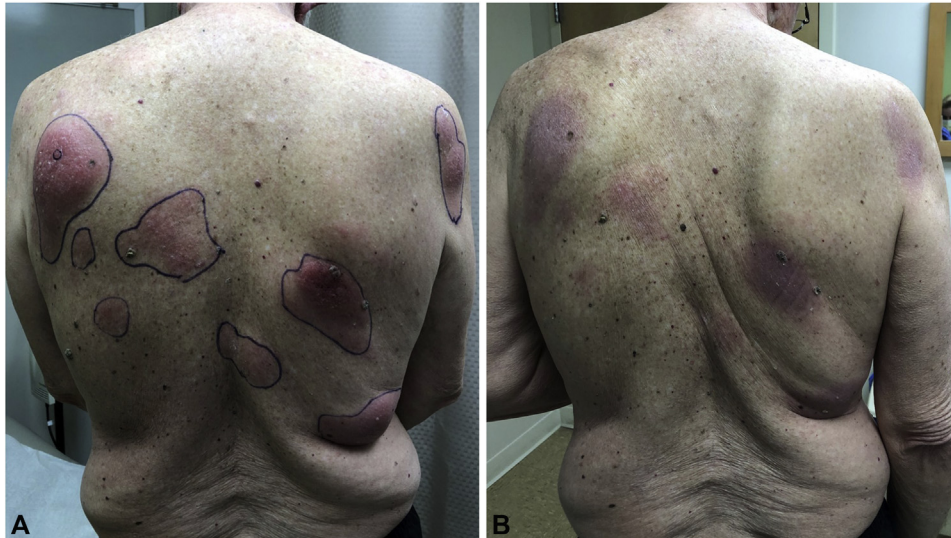**Fig 1.** Microscopic examination shows a diffuse, dense, atypical lymphocytic proliferation effacing the papillary and reticular dermis. (A and B, Hematoxylin-eosin stain; original magnifications: A,  $\times 20$ ; B,  $\times 400$ .)

neck, chest, abdomen, back, and right upper extremity. Repeat biopsy found strong CD4 and weak CD8 expression. Because of known CD20 expression, he completed 4 weekly cycles of rituximab without side effects but had continued growth of plaques. Because of clonal mTOR mutation, he was eligible for treatment with the mTOR inhibitor TAK-228 under the NCI MATCH clinical trial (Fig 2, A). The drug had a dramatic effect for almost 6 months (Fig 2, B). Treatment was temporarily interrupted for 15 days because of neutropenia and decreased in the fourth month because of various complications, such as severe fatigue, nausea, loss of appetite, dry mouth, sore throat, and hyperglycemia. Two months after dose reduction, positron emission tomography/computed tomography scan showed marked progression of disease. The patient was started on romidepsin, but his lesions continued to enlarge. He became progressively debilitated, had multiorgan failure, and passed away soon after.

## DISCUSSION

In the hematolymphoid system, BCL6 corepressor alterations have been associated with T-cell prolymphocytic leukemia and extranodal natural killer/T-cell lymphoma, nasal-type.<sup>1</sup> On the other hand, constitutive activation of mTOR has been observed in T-cell acute lymphoblastic leukemia.<sup>2,3</sup> The mTOR pathway operates in 2 distinct multiprotein complexes, mTORC1 and mTORC2. The pathway acts as a key regulator of many cellular processes such as growth, protein synthesis, and cell-cycle progression.<sup>2</sup> The mTORC1 inhibitor everolimus has demonstrated antitumor activity in a phase 2 trial involving 16 patients with relapsed/refractory T-cell lymphoma, from which, 7 (44%) were cutaneous (mycosis fungoides). The overall response rate in all 16 patients was 44% with 1 patient achieving a complete response and 6 patients a partial

remission.<sup>4</sup> TAK-228 is an investigational, oral, and selective ATP-site kinase inhibitor of both mTORC1 and mTORC2 previously studied in patients with relapsed/refractory multiple myeloma, non-Hodgkin lymphoma and Waldenstrom macroglobulinemia. Of the 33 response-evaluable patients, 3 achieved an objective response, 4 achieved stable disease lasting 6 months or longer, 14 achieved stable disease lasting less than 6 months, and 12 had progressive disease.<sup>5</sup> To our knowledge, TAK-228 has not been reported in the treatment of pcPTCL-NOS. The initial response in our case was dramatic; however, the brief drug interruption secondary to neutropenia led to a return of several tumors. Only 2 days after its reintroduction, the skin lesions had a remarkable response. Unfortunately, the dose had to be reduced from 3 mg to 2 mg daily because of marked asthenia and a decrease in the patient's performance status, and 2 months later, he had rapidly progressive disease. Most cases of pcPTCL-NOS present with a T-helper immunophenotype (CD4<sup>+</sup>, CD8<sup>-</sup>), but rare tumors may be CD8<sup>+</sup>, CD4<sup>+</sup>/CD8<sup>+</sup>, or negative for both CD4 and CD8.<sup>6</sup> In our case, the progressive development of new lesions occurred concomitantly with a change in immunophenotype. Despite the variable expression of CD4 and CD8, tumors showed the same clones (NGS) of the T-cell receptor  $\gamma$  gene, suggesting tumor immunohistochemical heterogeneity. According to a large study that involved 82 patients, pcPTCL-NOS demonstrated an unfavorable prognosis irrespective of the presence or absence of extracutaneous disease at the time of diagnosis, cell size, and expression of CD4<sup>+</sup> or CD8<sup>+</sup> phenotype. Complete remission was achieved in 71% of patients treated with radiotherapy and in 28% of patients treated with chemotherapy; however, remission was short lived, with the median disease-free survival for complete responders of only 8 months and overall 5-year



**Fig 2.** Multiple pink, indurated plaques and nodules before (A) and after (B) treatment with the mTOR inhibitor TAK-228.

survival rate of 20%.<sup>7</sup> Aberrant CD20 expression in cutaneous T-cell lymphomas is uncommon.<sup>8</sup> In our case, the anti-CD20 monoclonal antibody rituximab was attempted for 2 months; however, there was no significant response.

### CONCLUSION

pcPTCL-NOS is an aggressive, cutaneous T-cell lymphoma that can develop immunohistochemical heterogeneity and needs to be distinguished from other cutaneous T-cell lymphomas because of its prognostic and therapeutic implications. In addition, NGS can identify cases with mTOR mutation, which may benefit from targeted therapy.

### REFERENCES

1. Astolfi A, Michele F, Fraia M, et al. BCOR involvement in cancer. *Epigenomics*. 2019;11(7):835-855.
2. Calimeri T, Ferreri AJM. m-TOR inhibitors and their potential role in haematological malignancies. *Br J Haematol*. 2017; 177(5):684-702.
3. Gao Y, Yuan CY, Yuan W. Will targeting PI3K/Akt/mTOR signaling work in hematopoietic malignancies? *Stem Cell Investigation*. 2016;3:31.
4. Witzing TE, Reeder C, Han JJ, et al. The mTORC1 inhibitor everolimus has antitumor activity in vitro and produces tumor responses in patients with relapsed T-cell lymphoma. *Blood*. 2015;126(3):328-335.
5. Ghobrial IM, Siegel DS, Vij R, et al. TAK-228 (formerly MLN0128), an investigational oral dual TORC1/2 inhibitor: a phase I dose escalation study in patients with relapsed or refractory multiple myeloma, non-Hodgkin lymphoma, or Waldenström's macroglobulinemia. *Am J Hematol*. 2016; 91(4):400-405.
6. Philip EL, Gunter B, David W, Alain S. *World Health Organization Classification of Tumours: Pathology and Genetics of Skin Tumours*. Lyon, France: IARC Press; 2006.
7. Bekkenk MW, Wermeer MH, Jansen PM, et al. Peripheral T-cell lymphomas unspecified presenting in the skin: analysis of prognostic factors in a group of 82 patients. *Blood*. 2003;102: 2213-2219.
8. Amaia S, Ricardo M, Daniel M, et al. CD8-positive peripheral T-cell lymphoma with aberrant expression of CD20 and concurrent *in situ* follicular lymphoma. *J Cutan Pathol*. 2015;42: 66-72.