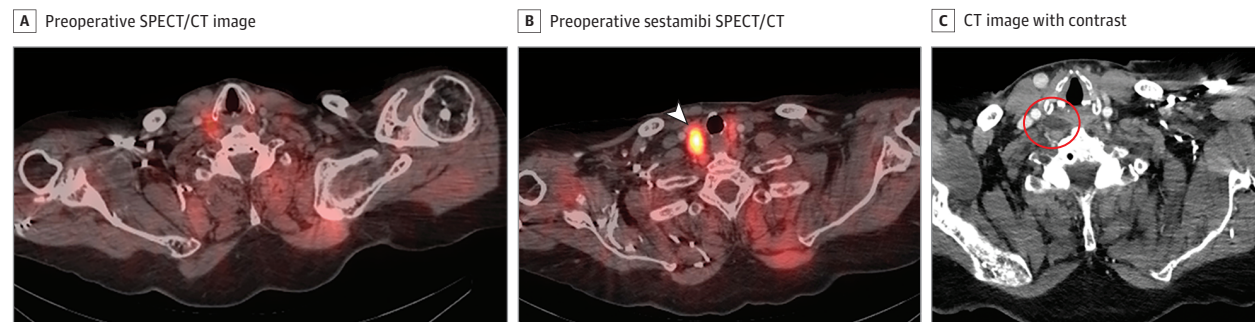


## Clinical Challenge | RADIOLOGY

## An Unusual Retropharyngeal Lesion

Christine J. Yang; Leah J. Novinger, MD, PhD; Michael W. Sim, MD



**Figure.** A, Results of single-photon emission computed tomography/computed tomography (SPECT/CT) demonstrated relatively low radiopharmaceutical uptake superior to the expected area of the parathyroid glands. B, Findings of technetium-99m sestamibi SPECT/CT demonstrated increased radiopharmaceutical uptake in the previously identified dominant right inferior thyroid nodule (white arrowhead). C, A CT neck scan with contrast showing a mass in the right retropharyngeal space with complex internal areas of increased attenuation (red circle).

**A female smoker** in her 50s was referred for hyperparathyroidism and a multinodular goiter. The patient reported symptoms of joint and musculoskeletal pain and fatigue but denied fever, sore throat, abdominal pain, and kidney stones. Her medical history was remarkable for congestive heart failure and schizophrenia. Neck examination revealed no meaningful findings except right thyroid enlargement. Results of laboratory evaluation demonstrated normal white blood cell count, borderline hypercalcemia (10.6 mg/dL), and elevated parathyroid hormone level (208 pg/mL). She underwent ultrasonography at an outside facility, and results demonstrated a 2.2-cm dominant right thyroid nodule with additional smaller thyroid nodules. Findings of preoperative technetium-99m (Tc-99m) sestamibi planar and single-photon emission computed tomographic/computed tomographic (SPECT/CT) imaging (Figure, A) were nonlocalizing for a parathyroid adenoma and showed increased uptake in the dominant right thyroid nodule (Figure, B). Results of an ultrasound-guided biopsy of the thyroid nodule demonstrated a benign colloid nodule with cystic changes. Computed tomography with intravenous contrast was obtained, and findings were initially reported as negative except for right multinodular goiter. However, on additional review, a well-circumscribed fat density mass measuring 3.0 × 2.3 × 1.1-cm was identified in the right retropharyngeal space posterior to the hypopharynx (Figure, C).

## WHAT IS YOUR DIAGNOSIS?

- A. Ectopic parathyroid lipoadenoma
- B. Liposarcoma
- C. Ectopic thyroid
- D. Retropharyngeal abscess

## Diagnosis

**A. Ectopic parathyroid lipoadenoma**

## Discussion

The patient underwent transcervical excision of the mass, located in the retropharyngeal space posterolateral to the right inferior constrictor muscle at the level of the hypopharynx. There was intraoperative normalization of parathyroid hormone levels, and final pathological results confirmed parathyroid lipoadenoma. Thus, to our knowledge, the present case is the first reported ectopic parathyroid lipoadenoma within the retropharyngeal space. In addition, this case demonstrates how parathyroid lipoadenomas are less reliably detected by Tc-99m SPECT/CT than their typical parathyroid adenoma counterparts, which highlights the value of contrasted CT.

Parathyroid lipoadenoma is a rare variant of parathyroid adenoma with a similar presentation owing to hyperfunctioning parathyroid tissue. The presence of increased fatty stroma differenti-

ates parathyroid lipoadenoma from parathyroid adenoma and also renders it more difficult to identify on preoperative imaging. Although it is uncertain where the fatty stroma originates from, it has been postulated that the same factors that drive growth of parathyroid chief cells are also responsible for fatty growth. Obesity and advanced age may increase this percentage of fatty tissue. Only 70 cases of parathyroid lipoadenoma have been described to date,<sup>1-5</sup> accounting for less than 1% of all cases of hyperparathyroidism, and most ectopic locations have been in the mediastinum.<sup>6</sup> Of note, although a liposarcoma may have similar imaging findings to a lipoadenoma, corresponding primary hyperparathyroidism would be unlikely. The imaging characteristics are clearly not consistent with thyroid tissue. An isolated retropharyngeal abscess would be less likely without infectious symptoms as well.

Additionally, SPECT, and more recently SPECT/CT, have helped localize parathyroid lesions and differentiate between thyroid and parathyroid tissue.<sup>7</sup> Technetium-99m sestamibi SPECT has a re-

ported sensitivity of 89% to 95% in detecting typical parathyroid lesions.<sup>1</sup> As a result, Tc-99m sestamibi has become the preferred method of preoperative parathyroid imaging because of its high sensitivity and cost-effectiveness.

In the present patient, however, the parathyroid lipoadenoma was nonlocalizing on SPECT/CT. Parathyroid lipoadenomas are characterized by decreased ratio of oxyphil cells to chief cells and fatty stroma, which leads to a low target-to-background signal ratio. Small lesions with high fatty content (>50%) have a higher likelihood of false-negative results. Other common reasons for nonlocalization include small size, parathyroid hyperplasia, multigland disease, and ectopic location.<sup>8</sup> In a case series of 21 patients, only 12 (57%) parathyroid lipoadenomas could be identified with Tc-99m sestamibi.<sup>1</sup> Other case reports support the inability to identify parathyroid lipoadenomas using this modality.<sup>2-5</sup> Therefore, these results show the necessity of using other imaging modalities to locate this less common variant.

If localization does not occur on SPECT, CT with contrast is a useful alternative despite its reported sensitivity of 45% to 55% in detecting parathyroid lesions.<sup>7</sup> In addition to detecting parathyroid

lipoadenomas, this method has slightly higher sensitivity in detecting mediastinal parathyroid tumors. Of note, although predominantly having fat density, the lesion in the current patient had complex internal density that was more than expected for a typical lipoma.

It is also important to mention that ultrasonography (US) has a sensitivity of 36% to 76% for detecting parathyroid lesions. In experienced hands, US is an excellent tool for detecting parathyroid lesions in the upper cervical area, though the difference in echogenicity of a parathyroid adenoma vs a higher fat density parathyroid lipoadenoma should be recognized. In the present case, US was not useful in localization owing to operator dependence. The present patient went on to have the lesion excised with no further sequelae. Postoperative parathyroid hormone levels were normal.

In summary, this case demonstrates that in patients with primary hyperparathyroidism without localization on Tc-99m sestamibi scintigraphy or SPECT, contrasted CT can be a critical tool for localization. Moreover, it is important to recognize that a fatty density in the retropharyngeal space as well as in the expected areas of parathyroid glands could represent a parathyroid lipoadenoma that is responsible for primary hyperparathyroidism.

#### ARTICLE INFORMATION

**Author Affiliations:** Indiana University School of Medicine, Indianapolis (Yang); Department of Otolaryngology–Head and Neck Surgery, Indiana University School of Medicine, Indianapolis (Novinger, Sim).

**Corresponding Author:** Michael W. Sim, MD, Department of Otolaryngology–Head and Neck Surgery, Indiana University School of Medicine, 1130 W Michigan St, Ste 400, Indianapolis, IN 46202 (mwsim@iu.edu).

**Published Online:** September 17, 2020.  
doi:10.1001/jamaoto.2020.2703

**Conflict of Interest Disclosures:** None reported.

**Additional Contributions:** We thank the patient's mother for granting permission to publish this information.

#### REFERENCES

1. Hycza MD, Sargin P, Mete O. Parathyroid lipoadenoma: a clinicopathological diagnosis and possible trap for the unaware pathologist. *Endocr Pathol.* 2016;27(1):34-41. doi:10.1007/s12022-015-9404-5
2. Triviño A, Varela J, Ayllón S. Mediastinal parathyroid lipoadenoma. *Arch Bronconeumol.* 2020;56(5):323. doi:10.1016/j.arbres.2019.04.016
3. Fujisawa S, Inagaki K, Wada J. Parathyroid lipoadenoma: a pitfall in preoperative localization. *Intern Med.* 2019;58(8):1183-1184. doi:10.2169/internalmedicine.1249-18
4. Özden S, Güreşçi S, Saylam B, Dağlar G. A rare cause of primary hyperparathyroidism: parathyroid lipoadenoma. *Auris Nasus Larynx.* 2018;45(6):1245-1248. doi:10.1016/j.anl.2018.05.001
5. Aggarwal A, Wadhwa R, Aggarwal V. Parathyroid lipoadenoma: a rare entity. *Indian J Endocrinol Metab.* 2018;22(1):174-176. doi:10.4103/ijem.IJEM\_273\_17
6. Gowda K, Matippa P. Parathyroid lipoadenoma: a diagnostic pitfall during frozen section evaluation of parathyroid lesions. *Int Clin Pathol J.* 2016; 3(2): 193-194. doi:10.15406/icpjl.2016.03.00070
7. Nguyen BD. Parathyroid imaging with Tc-99m sestamibi planar and SPECT scintigraphy. *Radiographics.* 1999;19(3):601-614. doi:10.1148/radiographics.19.3.g99ma10601
8. Alenezi S, Asa'ad S, Elgazzar A. Scintigraphic parathyroid imaging: concepts and new developments. *Res Rep Nucl Med.* 2015;2015(5): 9-18.