

CLINICAL NOTES

LPAC syndrome associated with deletion of the full exon 4 in a ABCB4 genetic mutation in a patient with hepatitis C

Blanca Fombuena¹, Javier Ampuero¹, Luis Álvarez², Reyes Aparcero¹, Rocío Llorca¹, Raquel Millán¹, Helena Pastor-Ramírez¹, Sara Andueza², Veronique Barbu³ and Manuel Romero-Gómez¹

¹UGMQ Digestive Diseases and CIBERehd. Universidad de Sevilla. Hospital Universitario de Valme. Sevilla, Spain. ²Research Unit. Hospital Universitario La Paz-IdiPAZ. Madrid, Spain. ³Service de Biochimie, Biologie Cellulaire et Moléculaire. Hôpital Universitaire Saint-Antoine. Paris, France

ABSTRACT

Low-phospholipid-associated cholelithiasis syndrome (LPAC) is associated with ABCB4 *genetic mutation*. ABCB4 encodes MDR3 protein, involved in biliary phosphatidylcholine excretion. Higher prevalence in women, biliary symptoms in young adults and ursodesoxycholic acid (UDCA) response are the main features. We report the case of a 48-year-old man with hepatitis C, genotype 1b, fibrosis F3, null responder to Peg-IFN α 2b/ribavirin and nephritic colic. In 2011 he developed jaundice, pruritus and epigastric pain. He showed increased serum levels of AST, ALT, GGT, bilirubin and alpha-fetoprotein, and viral load (14,600,000IU/mL). Pancreatic-CT, endoscopic ultrasonography and echo-Doppler showed non-cirrhotic chronic liver disease. The episode resolved spontaneously and one year later he suffered a similar episode. UDCA was started with excellent response. An immunohistochemistry study and sequencing of ABCB4 did not find alteration. MLPA[®] technique detected heterozygous deletion of the full exon 4 confirming LPAC syndrome diagnosis.

Key words: LPAC. ABCB4. MDR3. Exon 4.

Fombuena B, Ampuero J, Álvarez L, Aparcero R, Llorca R, Millán R, Pastor-Ramírez H, Andueza S, Barbu V, Romero-Gómez M. LPAC syndrome associated with deletion of the full exon 4 in a ABCB4 genetic mutation in a patient with hepatitis C. *Rev Esp Enferm Dig* 2014;106:544-547.

Received: 12-03-2014
Accepted: 31-03-2014

Correspondence: Manuel Romero Gómez. Unit for the Clinical Management of Digestive Diseases and CIBERehd. Hospital Universitario de Valme. Avda. de Bellavista, s/n. 41014 Sevilla, Spain
e-mail: mromerogomez@us.es

INTRODUCTION

Low-phospholipid-associated cholelithiasis syndrome (LPAC) was first described in 2001 as a specific form of cholelithiasis, characterized by intrahepatic sludge and/or symptomatic cholesterol cholelithiasis, usually before the age of 40, and by the association of ABCB4 mutations –located on chromosome 7q-21 (1)–, responsible for encoding MDR3 (2), a member of MDR (multidrug resistance protein). ABCB4 is an ATP-binding cassette membrane transporter that translocates phosphatidylcholine from the inner to the outer leaflet of the canalicular membrane of the hepatocyte by bile salts (3). The phosphatidylcholine, along with cholesterol and bile acids, makes bile micelles that inactivate the detergent action of bile salts and prevents damage to the epithelial cells lining the bile duct, as well as inhibiting cholesterol gallstone formation (4). ABCB4 mutations can produce low phospholipid content in bile, an increase in gallstones and an elevated detergent effect, resulting in damage to the biliary epithelium (5). Gene alterations causing defective ABCB4 protein are associated with progressive familial intrahepatic cholestasis type 3 (PFIC3), low-phospholipid-associated cholelithiasis syndrome (LPAC) (6) and intrahepatic cholestasis of pregnancy (ICP). The variety of phenotypes, which is due to mutations in the ABCB4 gene, may reduce but not eliminate the protein, leaving residual activity of the transporter. Cholelithiasis is more frequent in Asia than in Europe (7). Gallstones are present in more than 10 % of the European and American population, with 25 % displaying symptoms and less than 2 % suffering severe complications (acute cholangitis or acute pancreatitis). Since the first description of MDR3 mutations, the number of patients diagnosed with LPAC (8) has increased.

CASE REPORT

We report the case of a 48-year-old man, with a family history of a mother who died from chronic liver disease

that evolved towards cirrhosis and a sister with liver disease of unknown origin. In his personal history he suffers from the hepatitis C virus (HCV) infection, with genotype 1b and a null response to peginterferon α -2a and ribavirin therapy. Furthermore, he has been suffering from recurrent renal colic.

In February 2011, he developed jaundice, pruritus and epigastric pain. He showed increased serum levels: AST 145 U/L (0-37 U/L), ALT 121 U/L (0-37 U/L), alkaline phosphatase 116 U/L (50-190 U/L), GGT 167 U/L (6-50 U/L), bilirubin 14.6 mg/dl (0-1.8 mg/dl), alpha-fetoprotein 19.14 ng/ml (0-5 ng/ml) and viral load 14,600,000 UI/ml. The following tests were performed: a digestive ultrasonography with no masses lesions, nor visible dilatation of the bile ducts, showing a dense bile without conclusive evidence of cholelithiasis; an MR cholangiopancreatography, where choledocholithiasis and intrahepatic stones were discarded; a normal oral endoscopy; a computed tomographic angiography, which showed homogeneous hepatomegaly; and an endoscopic ultrasonography, which ruled out lesions of the pancreas or bile duct. The liver biopsy revealed a stage 3 fibrosis, according to METAVIR, compatible with hepatitis C without other altered values.

A year later (February 2012), the patient came back to the hospital and exhibited similar symptoms (jaundice, pruritus and epigastric pain), and due to the recurrence of the episode UDCA was prescribed with rapid improvement (Fig. 1).

Given the recurrent clinical episode and the absence of etiology, LPAC syndrome was suspected. A sample from the liver biopsy was sent to University Hospital La Paz (Madrid, Spain) for immunohistochemical analysis, where a normal canalicular MDR3 expression (Fig. 2) was appreciated. Subsequently, the coding sequence of the ABCB4 gene of the DNA sample from peripheral blood lymphocytes was studied in Saint-Antoine University Hospital (Paris) using Roche GS 454 Junior sequencing technology, this being a new generation of DNA sequencing through the ultra-deep sequencing of PCR products, with no muta-

tions being found. Given the persistence of clinical suspicion in La Paz University Hospital, the ABCB4 gene was analyzed again, this time with MLPA[®] (Multiplex Ligation-dependent Probe Amplification technique) (9), this being a complementary technique that detects changes in the number of genomic copies, insertions or deletions not detected by conventional sequencing methods. A patient's sample was compared to a sample from his sister (control 1) and another from a healthy individual (control 2). A mutation in heterozygosis was identified as being because of the deletion of a gene fragment containing the complete exon 4 (Fig. 3) and is compatible with a partial deficiency of MDR3 (10), confirming the diagnosis of LPAC.

DISCUSSION

The LPAC syndrome is a condition marked by intrahepatic cholesterol stones and cholelithiasis with biliary symptoms, even after cholecystectomy. LPAC has been associated with mutations in the ABCB4 gene that encodes the MDR3 protein. However, these mutations are observed in only approximately 60 % of cases (in a subset of patients) (11), so the diagnosis is mainly based on clinical criteria and ultrasound, although it should be noted that the percentage of patients with mutations in ABCB4 only relates to alterations in sequencing and not to deletions, so the percentage could be higher. The diagnosis can be suspected when at least two of the following criteria are present: a) Age under 40 years old; b) recurrence of biliary symptoms after cholecystectomy; and c) intrahepatic hyperechoic foci or sludge or microlithiasis along the biliary tree (12). The other clinical characteristics of LPAC are: a) A history of intrahepatic cholestasis in pregnancy; b) a history of cholelithiasis among first-degree relatives; c) a predominance in women; and d) a remarkable efficacy

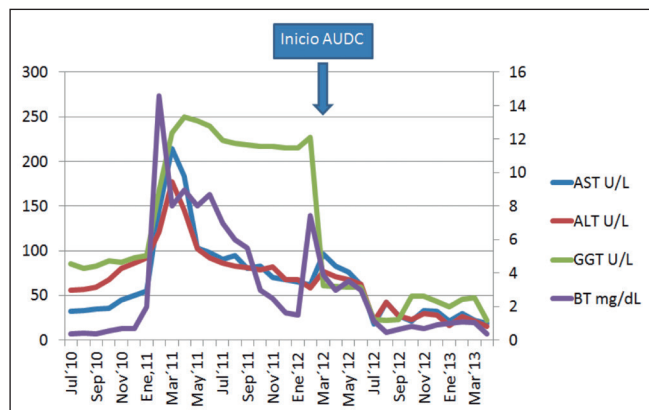


Fig. 1. Biochemical evolution of two episodes of jaundice with increased transaminases in January 2011 and February 2012, showing the excellent response to treatment with ursodeoxycholic acid.

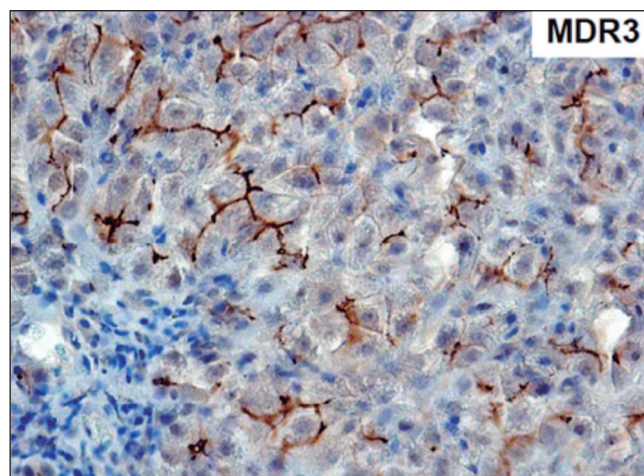


Fig. 2. Immunohistochemistry liver biopsy with the anti-MDR3 antibody using the method of antigen unmasking through heat, where a normal canalicular expression of MDR3 was observed.

of UDCA therapy on symptoms, usually within six months. This suggests that the symptoms are not always directly related to lithiasis but to an underlying inflammation of the intrahepatic bile ducts. Our patient was the first case reported in Spain and also had some singular characteristics. First, the observed mutation (deletion of exon 4) had not been previously reported (13). Second, it was a male over 40 years old, which represented an atypical case in terms of gender and age. Third, as this was a patient with hepatitis C and a non-responder to previous treatment with a high viral load, the final diagnosis was delayed because of suspicion directly related to infectious disease. However, the response to UDCA was favorable, as the literature says it usually is. In clinical practice, the diagnosis of LPAC should be suspected in young patient with biliary symptoms (cholangitis, cholestatic jaundice, biliary colic), and

an ABCB4 genetic analysis must be carried out to confirm the diagnosis. Considering that sometimes patients do not have gene mutations, this case represents an example of the application of molecular biology in clinical medicine.

REFERENCES

1. Jacquemin E, De Vree JM, Cresteil D, Sokal EM, Sturm E, Dumont M, et al. The wide spectrum of multidrug resistance 3 deficiency: From neonatal cholestasis to cirrhosis of adulthood. *Gastroenterology* 2001;120:1448-58.
2. Rosmorduc O, Hermelin B, Poupon R. MDR3 gene defect in adults with symptomatic intrahepatic and gallbladder cholesterol cholelithiasis. *Gastroenterology* 2001;120:1459-67.
3. De Vree JM, Jacquemin E, Sturm E, Cresteil D, Bosma PJ, Aten J, et al. Mutations in the MDR3 gene cause progressive familial intrahepatic cholestasis. *Proc Natl Acad Sci U S A* 1998;95:282-7.

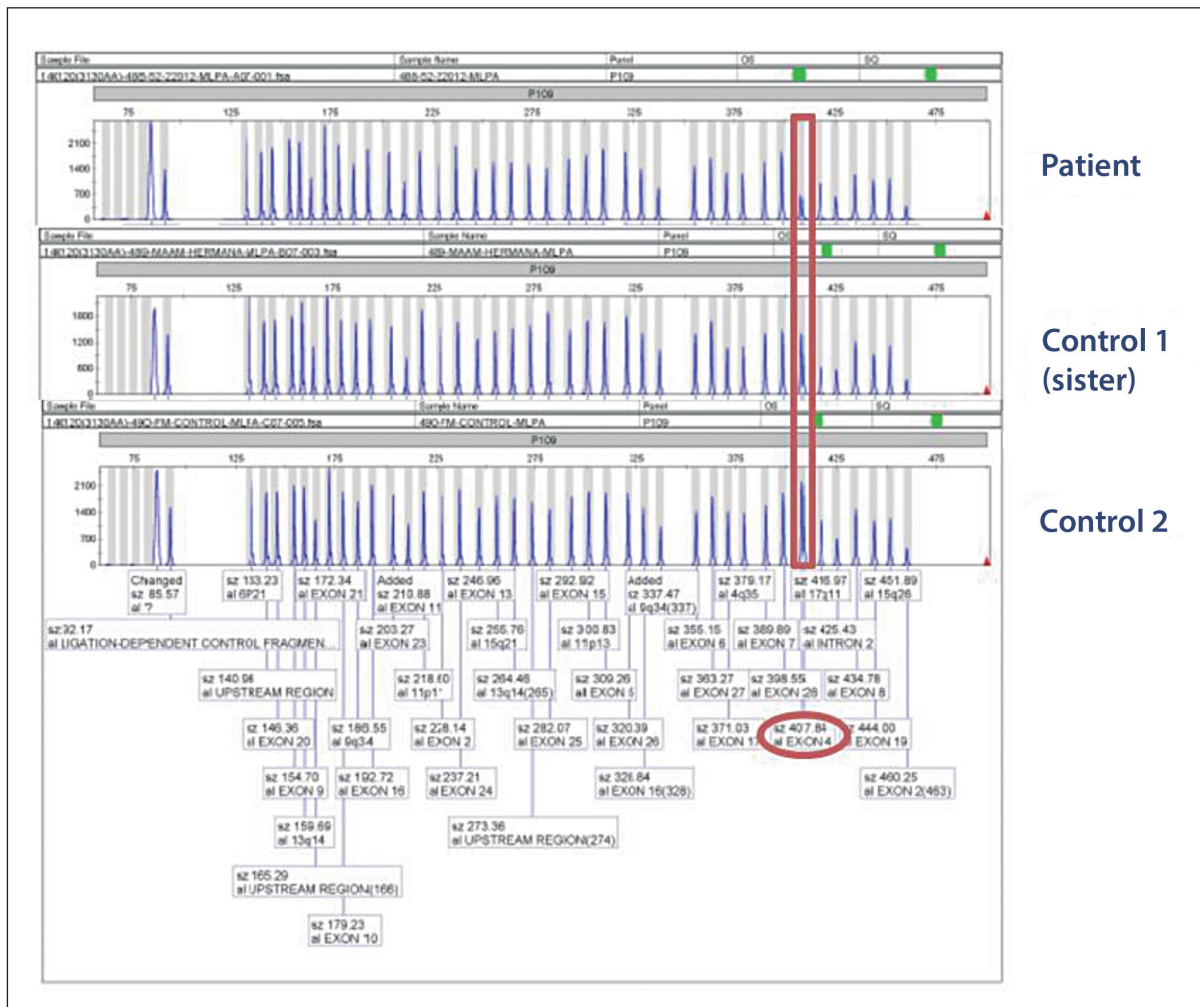


Fig. 3. Genetic mapping using the MPLA technique of the ABCB4 gene, where it is detected that the peak of exon 4, framed in red, is inferior in the patient sample relative to the other two samples, corresponding to the patient's sister (control 1) and the healthy patient control (control 2). Figures showing the peak values of exon 4 in the patient, which have a height and an area of 677 and 6,105 respectively, these being about half those for control 1 (1,398 and 12,686) and control 2 (1,487 and 13,346), thus indicating a heterozygous deletion of exon 4.

4. Erlinger S. From MDR3 to LPAC: Cross talk between molecular biology and clinical medicine. *Gastroenterol Clin Biol* 2010;34:345-6.
5. Fracchia M, Pellegrino S, Secreto P, Gallo L, Masoero G, Pera A, et al. Biliary lipid composition in cholesterol microlithiasis. *Gut* 2001;48:702-6.
6. Poupon R, Rosmorduc O, Boëlle PY, Chrétien Y, Corpechot C, Chazouillères O, et al. Genotype-phenotype relationships in the low-phospholipid-associated cholelithiasis syndrome: A study of 156 consecutive patients. *Hepatology* 2013;58:1105-10.
7. Shoda J, Oda K, Suzuki H, Sugiyama Y, Ito K, Cohen DE, et al. Etiologic significance of defects in cholesterol, phospholipid, and bile acid metabolism in the liver of patients with intrahepatic calculi. *Hepatology* 2001;33:1194-205.
8. Rosmorduc O, Poupon R. Low phospholipid associated cholelithiasis: Association with mutation in the MDR3/ABCB4 gene. *Orphanet J Rare Dis* 2007;2:29.
9. Schouten JP, McElgunn CJ, Waaijer R, Zwijnenburg D, Diepvens F, Pals G. Relative quantification of 40 nucleic acid sequences by multiplex ligation-dependent probe amplification. *Nucleic Acids Res* 2002;30:e57.
10. Pasmant E, Goussard P, Baranes L, Laurendeau I, Quentin S, Ponsot P, et al. First description of ABCB4 gene deletions in familial low phospholipid-associated cholelithiasis and oral contraceptives-induced cholestasis. *Eur J Hum Genet* 2012;20:277-82.
11. Rosmorduc O, Hermelin B, Boelle PY, Parc R, Taboury J, Poupon R. ABCB4 gene mutation-associated cholelithiasis in adults. *Gastroenterology* 2003;125:452-9.
12. Benzimra J, Derhy S, Rosmorduc O, Menu Y, Poupon R, Arrivé L. Hepatobiliary anomalies associated with ABCB4/MDR3 deficiency in adults: A pictorial essay. *Insights Imaging* 2013;4:331-8.
13. Condat B, Zanditenas D, Barbu V, Hauuy MP, Parfait B, El Naggar A, et al. Prevalence of low phospholipid-associated cholelithiasis in young female patients. *Dig Liver Dis* 2013;45:915-9.