

UMass Chan Medical School

eScholarship@UMassChan

Radiology Publications

Radiology

2022-03-15

Prospective study on embolization of intracranial aneurysms with the pipeline device (PREMIER study): 3-year results with the application of a flow diverter specific occlusion classification

Ricardo A. Hanel
Baptist Neurological Institute

Et al.

Let us know how access to this document benefits you.

Follow this and additional works at: https://escholarship.umassmed.edu/radiology_pubs



Part of the [Cardiovascular Diseases Commons](#), [Neurology Commons](#), [Neurosurgery Commons](#), and the [Radiology Commons](#)

Repository Citation

Hanel RA, Puri AS. (2022). Prospective study on embolization of intracranial aneurysms with the pipeline device (PREMIER study): 3-year results with the application of a flow diverter specific occlusion classification. Radiology Publications. <https://doi.org/10.1136/neurintsurg-2021-018501>. Retrieved from https://escholarship.umassmed.edu/radiology_pubs/687

Creative Commons License



This work is licensed under a [Creative Commons Attribution-NonCommercial 4.0 License](#)














This material is brought to you by eScholarship@UMassChan. It has been accepted for inclusion in Radiology Publications by an authorized administrator of eScholarship@UMassChan. For more information, please contact Lisa.Palmer@umassmed.edu.



OPEN ACCESS

Original research

Prospective study on embolization of intracranial aneurysms with the pipeline device (PREMIER study): 3-year results with the application of a flow diverter specific occlusion classification

Ricardo A Hanel ¹, Gustavo M Cortez,¹ Demetrius Klee Lopes ², Peter Kim Nelson,³ Adnan H Siddiqui,⁴ Pascal Jabbour ⁵, Vitor Mendes Pereira ⁶, Istvan Szikora István,⁷ Osama O Zaidat,⁸ Chetan Bettegowda,⁹ Geoffrey P Colby,¹⁰ Maxim Mokin ¹¹, Clemens M Schirmer,¹² Frank R Hellinger,¹³ Curtis Given,¹⁴ Timo Krings,¹⁵ Philipp Tausky ¹⁶, Gabor Toth ¹⁷, Justin F Fraser ¹⁸, Michael Chen ¹⁹, Ryan Priest,²⁰ Peter Kan ²¹, David Fiorella ²², Donald Frei ²³, Beverly Aagaard-Kienitz,²⁴ Orlando Diaz,²⁵ Adel M Malek ²⁶, C Michael Cawley,²⁷ Ajit S Puri,²⁸ David F Kallmes²⁹

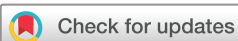For numbered affiliations see end of article.

Correspondence to

Dr Ricardo A Hanel, Baptist Neurological Institute, Lyerly Neurosurgery 800 Prudential Drive, Weaver Tower B, 11th Floor, Jacksonville, Florida 32207, USA; rhanel@lyerlyneuro.com

RAH and GMC are joint first authors.

Received 30 November 2021
Accepted 6 February 2022



© Author(s) (or their employer(s)) 2022. Re-use permitted under CC BY-NC. No commercial re-use. See rights and permissions. Published by BMJ.

To cite: Hanel RA, Cortez GM, Lopes DK, et al. *J NeuroIntervent Surg* Epub ahead of print: [please include Day Month Year]. doi:10.1136/neurintsurg-2021-018501

ABSTRACT

Background The pipeline embolization device (PED; Medtronic) has presented as a safe and efficacious treatment for small- and medium-sized intracranial aneurysms. Independently adjudicated long-term results of the device in treating these lesions are still indeterminate. We present 3-year results, with additional application of a flow diverter specific occlusion scale.

Methods PREMIER (prospective study on embolization of intracranial aneurysms with pipeline embolization device) is a prospective, single-arm trial. Inclusion criteria were patients with unruptured wide-necked intracranial aneurysms ≤ 12 mm. Primary effectiveness (complete aneurysm occlusion) and safety (major neurologic event) endpoints were independently monitored and adjudicated.

Results As per the protocol, of 141 patients treated with a PED, 25 (17.7%) required angiographic follow-up after the first year due to incomplete aneurysm occlusion. According to the Core Radiology Laboratory review, three (12%) of these patients progressed to complete occlusion, with an overall rate of complete aneurysm occlusion at 3 years of 83.3% (115/138). Further angiographic evaluation using the modified Cekirge–Saatci classification demonstrated that complete occlusion, neck residual, or aneurysm size reduction occurred in 97.1%. The overall combined safety endpoint at 3 years was 2.8% (4/141), with only one non-debilitating major event occurring after the first year. There was one case of aneurysm recurrence but no cases of delayed rupture in this series.

Conclusions The PED device presents as a safe and effective modality in treating small- and medium-sized intracranial aneurysms. The application of a flow diverter specific occlusion classification attested the long-term durability with higher rate of successful aneurysm occlusion and no documented aneurysm rupture.

Trial registration NCT02186561.

INTRODUCTION

The pipeline embolization device (PED; Medtronic, Irvine, California, USA) was approved by the Food and Drug Administration in 2011. It was initially reserved for managing large and giant wide-necked intracranial aneurysms, from petrous to superior hypophyseal internal carotid artery (ICA) segments. The device presented as a safe and efficacious breakthrough therapy for treating complex aneurysms, commonly not amenable to conventional endovascular techniques.^{1–3}

Subsequent studies unveiled the potentialities and viability of the use of flow diverters (FDs) to treat small aneurysms.^{4–6} The PREMIER (prospective study on embolization of intracranial aneurysms with pipeline embolization device) trial was the first prospective study to examine the efficacy of PEDs for the management of small- and medium-sized wide-necked aneurysms. The 1-year follow-up results supported a low device-related and procedure-related morbidity and mortality, with a primary safety endpoint rate of 2.2%. Additionally, the primary effectiveness endpoint was achieved in 76.7% of patients (defined by complete aneurysm occlusion, with no significant vessel stenosis [$>50\%$] and/or retreatment), and final complete occlusion rate of 81.9%.⁷ Subsequent to the study, the indication of the use of the device expanded to small- and medium-sized aneurysms extending from the petrous to the terminus segment of the ICA.

Currently, there is a paucity of independently adjudicated data supporting the long-term efficacy of flow diversion in the setting of small- and medium-sized unruptured aneurysms.⁸ This manuscript aims to present the 3-year follow-up results from the PREMIER cohort. Additionally, a specific FD occlusion classification was applied to better address the device efficacy and stability for aneurysm treatment.

METHODS

Study design, enrollment, and patient selection

PREMIER was a prospective, single-arm, multicenter interventional study to evaluate the PED device in the management of unruptured intracranial aneurysms. The original subject treatment target was 141 with a planned 3-year follow-up. Patient enrollment occurred between July 2014 and November 2015 in 23 participant sites. Patients were included if they had a target wide-necked aneurysm of ≤ 12 mm, located in the ICA (up to the carotid terminus) or vertebral artery (up to and including the posterior inferior cerebellar artery). Detailed inclusion and exclusion criteria, aneurysm features, and baseline characteristics have been previously described.⁷

Study device and procedure detail

The PED Classic and PED Flex are braided wire mesh, cylindrical, implanted devices intended to treat intracranial aneurysms, with detailed device features previously reported. The intervention was performed by experienced operators under general or local anesthesia with sedation through femoral or radial approaches. The trial protocol allowed the placement of additional PED devices if needed and coil use at the operator’s discretion. PREMIER’s dual antiplatelet therapy protocol required drug dosage optimization guided by the antiplatelet response (VerifyNow, Accumetrics). Loading dose was not permitted, and patients were excluded if clopidogrel resistance was demonstrated. Post-treatment, dual antiplatelet therapy was maintained for at least 3 months.

Study endpoints

The primary effectiveness endpoint was complete occlusion (Raymond–Roy classification 1) of the target aneurysm without significant parent artery stenosis ($\leq 50\%$) or retreatment of the target aneurysm. Additionally, effectiveness was evaluated by the modified Cekirge–Saatci classification (mCSC) to account

for dynamic aneurysm healing over time. The primary safety endpoint was the incidence of major stroke (ischemic or hemorrhagic) in the territory supplied by the treated artery, defined as an increased National Institutes of Health Stroke Scale score of ≥ 4 points or neurologic death. A Clinical Events Committee, comprised of clinical experts, independently reviewed and adjudicated the safety data.

Additional outcomes included aneurysm retreatment, recurrence, the incidence of delayed device-related adverse events (defined by a strong temporal relationship with the deployed device and a less likely alternative etiology), and long-term functional outcome (modified Rankin Scale).

Follow-up assessments

Radiological follow-up was mandatory at 1 year, and further imaging follow-up at 2 and 3 years was only required if complete occlusion had not been achieved. Additionally, radiological evaluation in cases of complete occlusion could be performed per standard of care. The primary effectiveness endpoint was evaluated using imputation by the last observation carried forward method. All images were evaluated by an independent Core Radiology Laboratory (CRL), in which the Raymond–Roy classification was used to define the degree of aneurysm occlusion (complete occlusion, residual neck, or residual aneurysm).

A supplementary long-term follow-up review of the cases using the mCSC was used to classify cases initially adjudicated by the CRL as incomplete occlusion. The classification elaborates on the remodeling concept by addressing the hemodynamic and healing processes of the aneurysm sac after FD treatment (unpublished data; under review). The concept portrays a shift in the natural history of intracranial aneurysms following FD usage. [Table 1](#) summarizes the classification.

Table 1 Modified Cekirge–Saatci classification

| Class | Description | Commentaries |
|---------|---|--|
| Class 1 | Complete aneurysm occlusion | In aneurysms with no incorporated branches |
| 1A | With full patency of the integrated branch | Subclassification 1A–C is reserved for aneurysms cases with an incorporated branch |
| 1B | With the branch reduced in caliber | |
| 1C | With no anterograde filling of the branch | |
| Class 2 | Residual neck filling | |
| Class 3 | Residual aneurysm filling | Residual aneurysms with unaltered dimensions, regardless of the presence of a side branch |
| 3A | With stable residuum in a sidewall aneurysm (with no incorporated branch) | Residual aneurysm with no incorporated branch showing stable or progressive reduced size on subsequent follow-up(s) |
| 3C | With documented growth | |
| Class 4 | Aneurysm filling (immediate results) | Class 4 is reserved for immediate postoperative results |
| 4A | With contrast stagnation within the aneurysm sac | |
| 4B | Without contrast stagnation | |
| Class 5 | Residual aneurysm filling with remodeling | Aneurysms with an incorporated vessel branch demonstrating stable reduced size on subsequent follow-up(s)* |
| 5A | Progressive remodeling | Aneurysm with an incorporated vessel branch demonstrating a progressive decrease in dimensions on subsequent follow-up(s)* |

For satisfactory radiological classification of aneurysm remodeling, two imaging controls are required (at least 6 months apart) and extending beyond 1 year of the index procedure.

*According to the original definition, there is an exceptional situation in which class 5 can be adjudicated at the first imaging control. It pertains to cases in which the branch is seen patent but with a different contrast course than originally expected within the aneurysm sac, in the absence of apparent aneurysm filling.

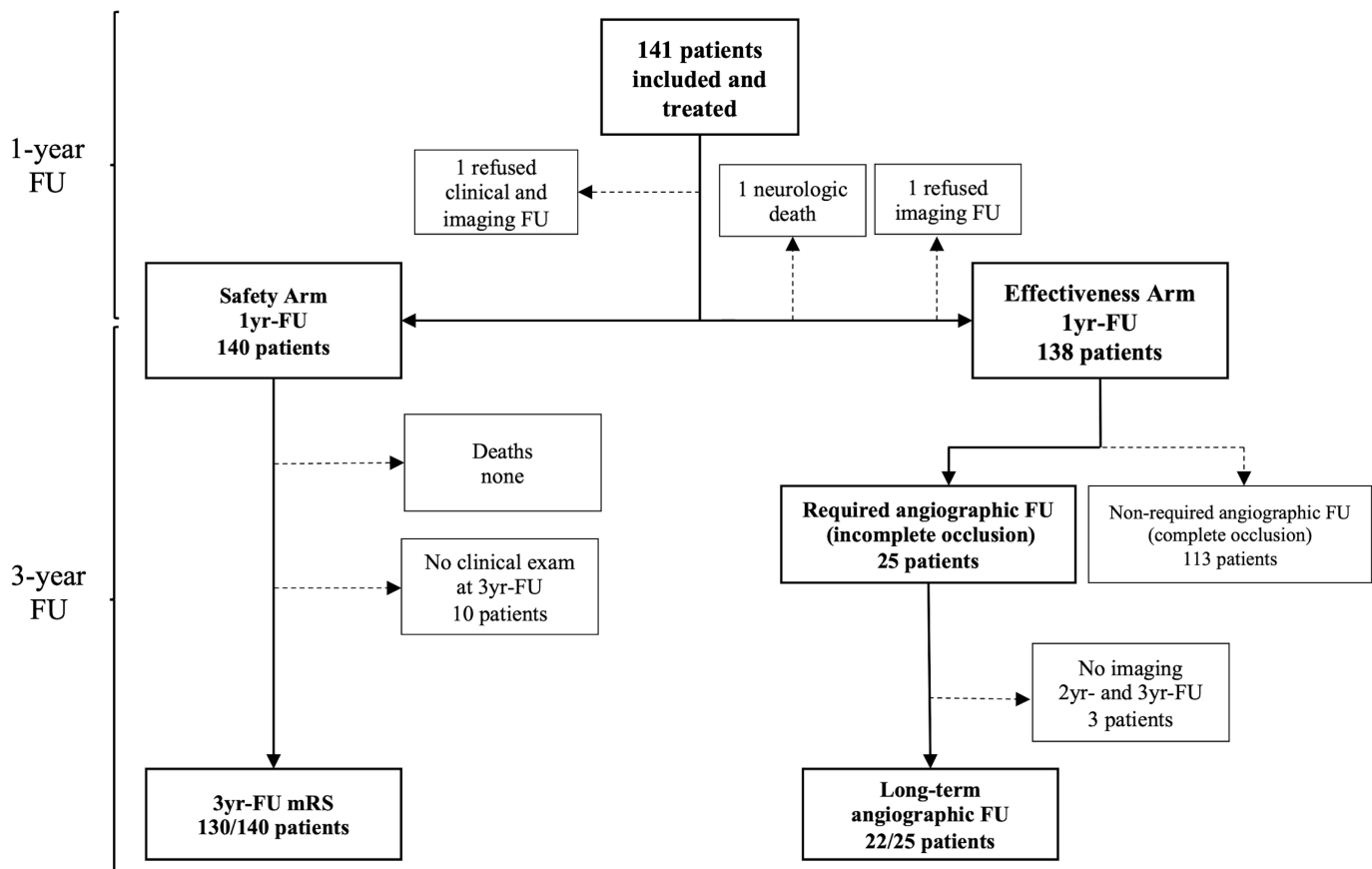


Figure 1 PREMIER (prospective study on embolization of intracranial aneurysms with pipeline embolization device) patient disposition at the 3-year time point. FU, follow-up; mRS, modified Rankin Scale; yr, year. Primary effectiveness endpoint was evaluated using imputation by the last observation carried forward method. Angiographic follow-up was only required per protocol if complete aneurysm occlusion had not been achieved.

Statistical analysis

Categorical and binary data were summarized using rates and percentages. A two-sided 95% exact binomial test was used to evaluate the primary endpoints with a significance level of $\alpha=0.025$. Multiple imputation method had previously been performed to fill missing data. In addition, a logistic regression model was performed, with the probability of success as the dependent variable and age, gender, maximal aneurysm diameter, and parent artery location as independent variables. Statistical analysis was performed using R (V.3.0 and above, R Foundation for Statistical Computing, Vienna, Austria) and SAS (V.9.0 and above, SAS Institute, Cary, North Carolina, USA).

RESULTS

Baseline characteristics, aneurysm feature, and procedure details were described in the initial PREMIER report. One hundred and forty-one patients were initially included in the study and 138 patients composed the intention-to-treat population. In the effectiveness endpoint arm, of the 25 patients requiring follow-up angiograms (due to incomplete aneurysm occlusion at 1 year), all but three patients had imaging control in at least one of the subsequent years (22/25, 88%). Additionally, of the 113 cases in which radiological follow-up was not mandatory (due to complete aneurysm occlusion at 1 year), imaging control was available in 34 and 37 cases during the second and third year follow-up, respectively. For the remaining cases, the last observation carried forward imputation method of the last CRL consensus reading was used. In the safety arm, functional

outcomes were available for 130 patients. The patient flowchart at the 3 year time point is shown in [figure 1](#).

Long-term effectiveness

Of the 25 patients requiring continued imaging follow-up due to incomplete occlusion at 1 year, 12% (3/25) progressed to occlusion without retreatment according to CRL. There was one case of recurrence, resulting in a complete occlusion rate (Raymond–Roy 1) at 3 years of 83.3% (115/138). Of the aneurysms that progressed to complete occlusion after the first year, two were located at the ophthalmic segment of the ICA and one at the communicating segment (C7), with two of these aneurysms characterized by an incorporated vessel branch arising from the aneurysm neck. Including those aneurysms achieving near complete treatment outcomes, adequate aneurysm occlusion (neck remnant or complete occlusion) progressed from 84.1% (116/138) at 1 year to 88.4% (122/138) at 3 years. The ultimate effectiveness endpoint (complete aneurysm occlusion without significant parent vessel stenosis or target aneurysm retreatment) according to the intention-to-treat principle was achieved in 78.3% (108/138, 95% confidence interval [CI] 70.4% to 84.8%) of cases.

Modified occlusion classification

Of the 25 patients with adjudicated incomplete occlusion by the Raymond–Roy classification scale at 1 year, 22 had at least one additional radiological follow-up, for which the mCSC was applied for radiological analysis. Complete occlusion after

Table 2 Effectiveness, safety, and functional long-term outcomes (n=138)

| | 1-year follow-up | 3-year follow-up† |
|---|------------------|-------------------|
| Primary effectiveness outcome | 106 (76.8) | 108 (78.3) |
| Occlusion status: Raymond–Roy | | |
| Complete occlusion (1) | 113 (81.9) | 115 (83.3) |
| Residual neck (2) | 3 (2.2) | 7 (5.1) |
| Residual aneurysm (3) | 22 (15.9) | 16 (11.6) |
| Occlusion status: mCSC | | |
| Complete occlusion (1/1A/1B) | 113 (81.9) | 118 (85.5) |
| Residual neck (2) | 3 (2.2) | 1 (0.7) |
| Aneurysm size reduction (3A/5/5A) | – | 15 (10.8) |
| Residual aneurysm (3/3C) | 22 (15.9) | 1 (0.7) |
| No consecutive follow-up for classification | – | 3 (0.9) |
| Target aneurysm retreatment | 4 (2.9) | 7 (5.0) |
| Target aneurysm recurrence | 0 | 1 (0.7) |
| Stenosis >50% | 4 (2.9) | 5 (3.6) |
| Primary safety outcome* | 3 (2.2) | 4 (2.9) |
| Functional independence (mRS ≤2) | 137/139 (98.6) | 127/130 (97.7) |

Data are n (%) or n/N (%).

*Defined as major stroke in the supplied territory or neurologic death; three events occurred within the first year, and one within the second year.

†In cases where 3-year digital subtraction angiography (DSA) control was not available, last observation carried forward of 2-year DSA was used. The latest follow-up is used for the mCSC.

mCSC, modified Cekirge–Saatci classification; mRS, modified Rankin Scale.

review of radiological imaging using the mCSC criteria was found in 27.3% (6/22), three more cases than the initial CRL adjudication using the Raymond–Roy scale. One additional patient (4.5%; 1/22) progressed to an aneurysm neck (class 2), and aneurysm size reduction was noted in 68.2% (15/22) of the remaining cases, three of which were sidewall aneurysms with no incorporated branches (class 3A). The additional 12 cases of size reduction were aneurysms with a side branch, which demonstrated either stable (class 5, eight cases) or progressive (class 5A, four cases) remodeling. When applying the mCSC, the combination of 118 (85.5%) completely occluded aneurysms, 1 (0.7%) residual neck aneurysm, and 15 (10.8%) aneurysms with either stable or progressive aneurysm size reduction resulted in a 97.1% successful treatment rate. Central study endpoints and angiographic outcomes are depicted in [tables 2 and 3](#), respectively.

Long-term safety and functional outcomes

Safety endpoint occurred in 2.8% (4/140) of the patients over the 3 year follow-up; three cases within the first year of device implantation have been previously described. Briefly, there was one case of intraparenchymal hemorrhage unrelated to aneurysm rupture, one right middle cerebral artery infarct after dual antiplatelet therapy discontinuation, and one sizable intraparenchymal hemorrhage that occurred a few hours after the procedure and resulted in neurological death. Only one (1/140, 0.7%) major safety event occurred after the first year, 498 days after the procedure. The patient had a major stroke with concomitant intraparenchymal hemorrhage, which was non-disabling at a 2-year follow-up.

Additional outcomes

There were no cases of aneurysm rupture in the series. Retreatment rate since initial device implantation was 5.0% (7/138): four within the first year and three within the second year. All retreatments were carried on with PED in planned (elective)

surgical procedures. None of the patients retreated after the first year progressed to complete occlusion according to CRL adjudication. There was one case of aneurysm recurrence (0.7%) in a patient with an initially occluded aneurysm who afterward demonstrated residual neck at a 3-year follow-up. Functional independence at 3 years was observed in 97.7% (127/130) of patients. The overall device-related adverse event rate was 10.6% (15/141): 11 occurred within the first year, four within the second year, and none in the third year. Notably, most device-related injuries were minor events (11/15, 73.3%). The final rate of significant in-stent stenosis (>50%) across the 36 months was 3.6% (5/138). There was only one case of delayed stenosis (after 12 months of the procedure) in a patient with incomplete aneurysm occlusion.

DISCUSSION

PREMIER is the largest prospective trial evaluating PED for the treatment of small- and medium-sized unruptured intracranial aneurysms located at the ICA and vertebral artery. According to the absence of retreatment and significant parent vessel stenosis, a final effectiveness endpoint at the 3-year follow-up was achieved in 78.3% (108/138), with complete aneurysm occlusion depicted in 83.3% (115/138) of patients. Cumulative safety events occurred in 2.8% (4/140) over the same period, with only one case occurring after the first year, though it was unrelated to the device. There was no case of aneurysm rupture in the series. Radiological evaluation demonstrated that all aneurysms with residual filling in the first year progressed to complete occlusion or showed reduced dimensions on the latest available follow-up. These findings emphasize the PED safety profile when considering the long-term follow-up of these aneurysms.

Table 3 Long-term angiographic outcomes: aneurysms with incomplete occlusion

| Patient No | Location | Incorporated branch | 1-year follow-up CRL RR | 2-year follow-up CRL RR | 3-year follow-up CRL RR | Latest follow-up mCSC | Retreatment |
|------------|----------|---------------------|-------------------------|-------------------------|-------------------------|-----------------------|-------------|
| 1 | ICA-C6 | No | 3 | 2 | 1 | 1 | No |
| 2 | ICA-C7 | Yes | 3 | 3 | 1 | 1A | No |
| 3 | ICA-C6 | Yes | 3 | 3 | 1 | 1A | No |
| 4 | V4 | Yes | 3 | 3 | 3* | 1A | PED |
| 5 | ICA-C7 | Yes | 2 | 2 | 2 | 1B | No |
| 6 | V4 | Yes | 2 | 2* | 2 | 1B | No |
| 7 | ICA-C6 | No | 3 | 2 | 2* | 2 | No |
| 8 | ICA-C5 | No | 3 | 3 | 3 | 3A | No |
| 9 | ICA-C6 | No | 3 | 3 | 3 | 3A | No |
| 10 | ICA-C7 | No | 3 | 3 | 3 | 3A | No |
| 11 | ICA-C6 | Yes | 3 | 3 | 3* | 5 | No |
| 12 | ICA-C6 | Yes | 2 | 2 | 3 | 5 | No |
| 13 | ICA-C6 | Yes | 3 | 3 | 3* | 5 | PED |
| 14 | ICA-C6 | Yes | 3 | 3 | 3 | 5 | PED |
| 15 | ICA-C7 | Yes | 3 | 3 | 3 | 5 | No |
| 16 | ICA-C7 | Yes | 3 | 3 | 3* | 5 | No |
| 17 | ICA-C7 | Yes | 3 | 3* | 2 | 5 | No |
| 18 | ICA-C7 | Yes | 3 | 3 | 3* | 5 | No |
| 19 | ICA-C6 | Yes | 3 | 3 | 2 | 5A | No |
| 20 | ICA-C6 | Yes | 3 | 3 | 3 | 5A | No |
| 21 | V4 | Yes | 3 | 3 | 3* | 5A | No |
| 22 | V4 | Yes | 3 | 3 | 3* | 5A | PED |
| 23 | ICA-C6 | No | 3 | 3* | 3* | NP | No |
| 24 | ICA-C6 | Yes | 3 | 3* | 3* | NP | No |
| 25 | ICA-C7 | Yes | 3 | 3* | 3* | NP | No |

*No radiological follow-up available (last observation carried forward method). CRL, Core Radiology Laboratory; ICA, internal carotid artery; mCSC, modified Cekirge-Saatci classification; NP, not possible (inability to classify due to the absence of at least two consecutive angiographic controls); PED, pipeline embolization device; RR, Raymond-Roy classification; V4, vertebral artery fourth portion.

Efficacy of FDs for small- and medium-sized aneurysms

Overall, flow diversion therapy proved to be an efficacious and safe strategy for managing intracranial aneurysms.⁸ Animal and in vitro models have assisted in outlining the mechanisms associated with structural and dynamical changes, ensuring optimization and refinement of the technology over the years.^{9,10} Although small aneurysms carry a lower risk of rupture when compared with their larger counterparts, they still represent the source of bleeding in a significant percentage of patients presenting with subarachnoid hemorrhage, given that lesions ≤ 12 mm account for approximately four in every five intracranial aneurysms.^{11,12} Hence, early stage treatment provides the promise of preventing lesion enlargement and mitigating rupture risk. A central question that remains elusive is establishing tangible efficacy and safety in the long term, an essential component while evaluating the tools designed for small intracranial aneurysms. Factors such as hypertension, posterior circulation location, and younger age have been suggested as predictors for small aneurysm rupture, potentially supporting treatment decision and patient counseling.^{13,14}

An extensive experience, including 445 cases of implanted PED by Bender *et al*, reported a rate of complete aneurysm occlusion progressing from 78% to 87% between the first and second year of follow-up. Most of the treated aneurysms were small (80%; mean size 6.6 mm) and located at

the ICA (82%).¹⁵ Similarly, in a follow-up series of >2 years, complete occlusion in aneurysms <10 mm progressed from 87.3% at 1 year to 93.2% at last follow-up.¹⁶ The PEDESTRIAN study encompassed 1000 aneurysms treated with the PED over 13 years, with the majority of treated aneurysms being small (64.6%; ≤ 10 mm) and located along the ICA (86.7%).¹⁷ The rate of complete occlusion progressed from 75.8% at the 1 year follow-up to 92.9% and 96.4% at the intermediate (2–4 years) and long-term (>5 years) follow-up, respectively.¹⁷ Likewise, the 3-year PREMIER results emphasize that, although 1-year follow-up is a determining time point for overall therapy success, aneurysm size reduction and progression to complete occlusion can be expected in the long term. According to the CRL adjudication, two ICA ophthalmic segment aneurysms and one ICA communicating segment aneurysm progressed to complete occlusion more than 1 year after the index procedure, resulting in high complete occlusion rates at 36 months (83.3%). Notably, none of these three cases had been retreated.

Aneurysm occlusion classification in the presence of a side branch

Adjacent analysis of the 1-year results of the PREMIER cohort identified that patients who were non-smokers (adjusted odds ratio [OR] 4.5; 95% CI 1.1 to 18.1) and the presence of a side branch involvement (adjusted OR 11.7; 95% CI 3.8 to 35.5) were independent predictors of incomplete occlusion at 1 year.¹⁸ Thus, in the occurrence of an end vessel side branch, continued aneurysm filling and patency across the ostium after PED deployment is more likely to be maintained due to a persistent pressure gradient.^{19,20} The concept of aneurysm remodeling has been commonly regarded when patency is maintained due to a side branch but aneurysm shrinking is noticed over time, commonly resulting in an 'infundibula-like' appearance at its origin or a tortuous takeoff from the parent artery.²¹ For adequate confirmation of aneurysm stability and remodeling, a radiological follow-up of least two angiographic controls expanding for a period greater than 1 year, at least 6 months apart, is recommended.^{20,22} Three additional patients were considered to have complete aneurysm occlusion, aside from the initial three cases adjudicated as complete occlusion by the CRL, when the mCSC was applied; this leveraged the rate of complete occlusion from 83.3% to 85.5%. This difference is explained by the latter classification considering incorporated vessel branches when adjudicating aneurysm occlusion. Additionally, all cases with initial incomplete occlusion and available long-term imaging control demonstrated at least some degree of size reduction, regardless of the presence of an end vessel branch. This finding portrays the dynamic natural history of aneurysms treated with FDs and reinforces the device's safety profile.

Safety of FDs for small- and medium-sized aneurysms

After the first year of follow-up, there was one (0.7%) major safety event in a patient who had a major ischemic stroke with associated intraparenchymal hemorrhage, but with a non-disabling outcome at a 2-year time point. The cumulative safety endpoint at the 3-year follow-up using the PED for small and medium aneurysms was 2.8%, posing the device as a safe strategy for managing aneurysms along the ICA. Additionally, there was no aneurysm rupture following initial intervention in the present cohort. Although the PUFs trial³ did not observe any

instances of aneurysm recanalization or delayed target aneurysm rupture, previous reports described cases of delayed rupture following PED deployment for the management of large and giant aneurysms.^{6,23} This risk, however, appears to be minimal in small lesions.^{4,6,16,24,25} The International Retrospectives Study of the PED (IntrePED) included 793 patients harboring 906 aneurysms, 349 of which were located at the ICA and were <10 mm. Patients who presented for treatment with unruptured aneurysms and pertained to the small aneurysm group had a lower rate of neurologic morbidity and mortality (4.1%) compared with larger ICA aneurysms (9.2%), posterior circulation aneurysms (13.7%), and other anterior circulation aneurysms (8.4%, $p=0.03$).⁶ Moreover, the risk of spontaneous rupture was higher in giant aneurysms (4.5%) compared with large (0.6%) and small aneurysms (0%, $p<0.001$).⁶ Compared with coiling, PEDs demonstrated a favorable efficacy profile and similar safety profile in managing non-complex unruptured small aneurysms in a similar population.²⁶ This favorable profile makes the PED a cost-effective tool, or at least comparable,²⁷ relative to stent-assisted coiling for treatment of small unruptured intracranial aneurysms.²⁸

The PREMIER trial represents the first prospective, independently adjudicated, multicenter study to report 3-year follow-up use of FDs to treat small and medium unruptured intracranial aneurysms. The results document the safety and efficacy of the device in the long term, with progressive rates of complete occlusion and no cases of aneurysm rupture. Although 1-year angiographic results remain central to defining the overall success of the therapy, delayed progression to complete occlusion and aneurysm remodeling can be expected in the long term.

Limitations

A significant limitation of this study included the absence of a concurrent control group, making it unfeasible to compare with other aneurysm therapies directly. This is a known limitation of FD studies due to an impracticable aspect of achieving clinical equipoise with the currently available treatment strategies. In addition, long-term angiographic follow-up was not mandatory in cases of complete occlusion, limiting the analysis of aneurysm recurrence and parent vessel stenosis. The study only included unruptured, wide-necked, small- and medium-sized intracranial aneurysms, therefore limiting the generalizability to other aneurysm types, sizes, and locations.

CONCLUSIONS

PREMIER is the first prospective, independently adjudicated trial to assess the long-term safety and efficacy of the PED for the treatment of unruptured, small and medium intracranial aneurysms. A sustained high rate of aneurysm occlusion, low procedure morbidity, and absence of aneurysm rupture reinforce the device as a safe treatment strategy for aneurysms located along the ICA and vertebral artery in the long term. In addition, FD specific aneurysm occlusion classification applied to this data set demonstrated an even higher rate of successful aneurysm occlusion with no documented aneurysm rupture and a low rate of delayed ischemic complications.

Author affiliations

- ¹Lyerly Neurosurgery, Baptist Neurological Institute, Jacksonville, Florida, USA
- ²Brain and Spine Institute, Advocate Aurora Health, Park Ridge, Illinois, USA
- ³Interventional Radiology, NYU Langone Medical Center, New York, New York, USA
- ⁴Department of Neurosurgery, University at Buffalo Jacobs School of Medicine and Biomedical Sciences, Buffalo, New York, USA
- ⁵Department of Neurosurgery, Thomas Jefferson University Hospital, Philadelphia, Pennsylvania, USA

- ⁶Division of Neuroradiology, Department of Medical Imaging and Division of Neurosurgery, Department of Surgery, Toronto Western Hospital, Toronto, Ontario, Canada
- ⁷Department of Neuroradiology, National Institute of Neurosciences, Budapest, Hungary
- ⁸Neuroscience Institute, Mercy Health Saint Vincent Medical Center, Toledo, Ohio, USA
- ⁹Department of Neurosurgery, Johns Hopkins University School of Medicine, Baltimore, Maryland, USA
- ¹⁰Department Neurosurgery, University of California Los Angeles, Los Angeles, California, USA
- ¹¹Department of Neurosurgery, University of South Florida College of Medicine, Tampa, Florida, USA
- ¹²Department of Neurosurgery, Geisinger Health System, Danville, Pennsylvania, USA
- ¹³Department of Radiology, Florida Hospital Neuroscience Institute, Winter Park, Florida, USA
- ¹⁴Department of Radiology, Baptist Health Lexington, Lexington, Kentucky, USA
- ¹⁵Department of Medical Imaging, Toronto Western Hospital, Toronto, Ontario, Canada
- ¹⁶Department of Neurosurgery, University of Utah Health, Salt Lake City, Utah, USA
- ¹⁷Cerebrovascular Center, Cleveland Clinic, Cleveland, Ohio, USA
- ¹⁸Department of Neurological Surgery, University of Kentucky, Lexington, Kentucky, USA
- ¹⁹Department of Neurological Surgery, Rush University Medical Center, Chicago, Illinois, USA
- ²⁰Charles T Dotter Department of Interventional Radiology, Dotter Interventional Institute, Oregon Health and Science University, Portland, Oregon, USA
- ²¹Department of Neurosurgery, Baylor College of Medicine, Houston, Texas, USA
- ²²Department of Neurosurgery, Cerebrovascular Center, Stony Brook University, Stony Brook, New York, USA
- ²³Department of Neuroradiology, Swedish Medical Center, Englewood, Colorado, USA
- ²⁴Department of Neurological Surgery, University of Wisconsin-Madison School of Medicine and Public Health, Madison, Wisconsin, USA
- ²⁵Cerebrovascular Center, Houston Methodist Research Institute, Houston, Texas, USA
- ²⁶Department of Neurosurgery, Tufts Medical Center, Boston, Massachusetts, USA
- ²⁷Department of Neurointerventional Radiology and Neurosurgery, Emory University School of Medicine, Atlanta, Georgia, USA
- ²⁸Department of Radiology, University of Massachusetts Medical School, Worcester, Massachusetts, USA
- ²⁹Department of Radiology, Mayo Clinic, Rochester, Minnesota, USA

Twitter Demetrius Klee Lopes @cure4stroke, Pascal Jabbour @PascalJabbourMD, Vitor Mendes Pereira @VitorMendesPer1, Gabor Toth @GaborTothMD, Michael Chen @dr_mchen, Peter Kan @PeterKa80460001, Donald Frei @donfreimd and Ajit S Puri @AjitSPuri1

Acknowledgements The authors acknowledge Oscar Bolanos and Medtronic for providing editing support for this manuscript.

Contributors RAH and GMC were responsible for the initial draft of the manuscript. All authors were involved and made substantial contributions to the conception or design of the work, or the acquisition, analysis, or interpretation of the data; drafting the work or revising it critically for important intellectual content; final approval of the version published; and agreement to be accountable for all aspects of the work in ensuring that questions related to the accuracy or integrity of any part of the work are appropriately investigated and resolved. RAH is responsible for the overall content as the guarantor.

Funding The PREMIER study was supported by by Medtronic, Inc.

Competing interests RAH is a consultant for Medtronic, Stryker, Cerenovus, Microvention, Balt, Phenox, Rapid Medical, and Q'Apel; he is on advisory board for MiVi, eLum, Three Rivers, Shape Medical and Corindus; he has received unrestricted research grants from NIH, Interline Endowment, Microvention, Stryker, CNX; he is an investor/stockholder for InNeuroCo, Cerebrotech, eLum, Endostream, Three Rivers Medical Inc, Scientia, RiSt, BlinkTBI, and Corindus. DKL is a consultant for Asahi, Medtronic, and Stryker; has received honoraria from Siemens, Medtronic, Stryker, and Phenox. PKN is a consultant for Medtronic, Phenox, and GmbH. AHS is a modest consultant for Amnis Therapeutics, Boston Scientific, Canon Medical Systems USA, Cerebrotech Medical Systems, Claret Medical, Corindus, Endostream Medical, Guidepoint Global Consulting, Imperative Care, Integra, Rapid Medical, Rebound Therapeutics Corp, Silk Road Medical, StimMed, Stryker, Three Rivers Medical, VasSol, and WL Gore and Associates; he is a consultant and serves on the national PI/steering committee for Cerenovus, Medtronic, Microvention, and Penumbra; he serves on the National PI/steering committee for the POSITIVE Trial for the Medical University of South Carolina and as DSMB Chair for the HEAT Trial for Northwest University and has ownership interest in Amnis Therapeutics, Apama

Medical, BlinkTBI, Buffalo Technology Partners, Cardinal Health, Cerebrotech Medical Systems, Claret Medical, Cognition Medical, Endostream Medical Ltd, Imperative Care, International Medical Distribution Partners, Rebound Therapeutics Corp, Silk Road Medical, StimMed, Synchron, Three Rivers Medical, and Viseon. PJ serves as a consultant for Medtronic, Cerenovus, and Microvention. VMP serves as a consultant/steering committee member for Stryker, Penumbra, and Balt, and as a consultant for Medtronic and Neurovasc, and receives a research grant from Philips. ISI serves as a scientific consultant regarding trial design and conduct to Medtronic. OOOZ is a consultant for Medtronic, Stryker, Penumbra, and Cerenovus. CB is a consultant for Depuy-Synthes, Bionaut labs, and Galectin Therapeutics. GPC serves as a consultant for Medtronic, Microvention-Terumo, and Stryker. MM serves as a consultant for Cerebrotech, Imperative Care, and Penumbra; receives consulting fees from Medtronic, Cerenovus, and Canon Medical; and is a member of the Journal of NeuroInterventional Surgery editorial board. CMS has received honoraria from the American Association of Neurological Surgeons and Toshiba, and has ownership interest in NTI. CG serves as a consultant, proctor, and on the Speakers' Bureau for Medtronic and Stryker. TK is a consultant for Stryker, Cerenovus, Penumbra, and Medtronic. PT serves as a consultant for Stryker Neurovascular, Cerenovus, and Medtronic. GT serves as a consultant for Dynamed EBSCO and Microvention; and is a member of the Journal of NeuroInterventional Surgery editorial board. JFF is an equity interest holder for Fawkes Biotechnology, LLC, and Cerelux; is a consultant for Stream Biomedical, Penumbra, and Medtronic; and is a member of the Journal of NeuroInterventional Surgery editorial board. MC is a consultant for Medtronic, Stryker, Penumbra, Genentech, and GE; and a member of the Journal of NeuroInterventional Surgery editorial board. RP is a consultant for Medtronic, Stryker, and Cerenovus. PK is a consultant for Stryker Neurovascular, Medtronic, and Cerenovus; and a member of the Journal of NeuroInterventional Surgery editorial board. DFI is a consultant for Arsenal Medical, Balt USA, Cerenovus, Marblehead, Medtronic, MENTICE-Vascular Simulations, Microvention, Neurogami, Qapel Medical, RAPID Medical, RAPID.AI, Stryker, and Siemens; received research support from Balt USA, Microvention, Penumbra, Siemens, and Stryker; has received honorarium from Qapel Medicine; is a stockholder in Marblehead, MENTICE-Vascular Simulations, and Neurogami; and a member of the Journal of NeuroInterventional Surgery editorial board. DFR is a consultant and on the Speakers' Bureau for Penumbra, Stryker Neurovascular, Genentech, Microvention, and Codman. OD serves as a proctor for Microvention/Terumo. AMM is a cofounder, investor, and shareholder of CereVasc. ASP consults for and has received research grants from Medtronic Neurovascular, Stryker Neurovascular, and Cerenovus; serves as a consultant for Microvention, Agile, Merit, Corindus, QApel, Arsenal, and Imperative Care. DFK is president of Marblehead Medical and has patent pending in balloon catheter technologies; he has received research support from Medtronic, Microvention, NeuroSave, Neurogami, Sequent Medical, NeuroSigma, and Insera; and serves on the Scientific Advisory Board for Triticum and Boston Scientific.

Patient consent for publication Not applicable.

Ethics approval This study involves human participants and was approved by institutional review board (IRB) of each participating institution approved the study: Baptist Health (main institution) internal IRB approval No IRB 14-57; Mayo Clinic IRB (IRB ID: IORG0000016); Emory University IRB (IRB ID: IORG0000267); Office of Human Research IRB (IRB ID: IORG0000095); University at Buffalo IRB (IRB ID: IORG0000206); Rush University Office of Research Affairs (IRB ID: IORG0000298); Johns Hopkins IRB (IRB ID: IORG0000019); Stony Brook University IRB (IRB ID: IORG0000037); Western IRB (IRB ID: IORG0009839); Baptist Health IRB (IRB ID: IORG0007951); UMass Medical School Human Subjects IRB (IRB ID: IORG0000160); Baptist Health Lexington IRB (IRB ID: IORG0002402); The Cleveland Clinic Foundation Office of the IRB (IRB ID: IORG0000301); Houston Methodist Research Institute IRB (IRB ID: IORG0004219); Oregon Health and Sciences University Research Integrity Office (IRB ID: IORG0000278); Florida Hospital IRB (IRB ID: IORG0000516); HCA-HealthONE IRB (IRB ID: IORG0004558); IRB for Baylor College of Medicine and Affiliated Hospitals (IRB ID: IORG0000055); Health Sciences Campus IRB (IRB ID: IORG0000435); Partners Human Research Committee (IRB ID: IORG0009015); Geisinger IRB (IRB ID: IORG0000125); University of Kentucky IRB (IRB ID: IORG0000250); University of Utah IRB (IRB ID: IORG0000072); Western IRB (IRB ID: IORG0009839); University Health Network Research Ethics Board (IRB ID: IORG0000891). Participants gave informed consent to participate in the study before taking part.

Provenance and peer review Not commissioned; externally peer reviewed.

Data availability statement Data are available upon reasonable request.

Open access This is an open access article distributed in accordance with the Creative Commons Attribution Non Commercial (CC BY-NC 4.0) license, which permits others to distribute, remix, adapt, build upon this work non-commercially, and license their derivative works on different terms, provided the original work is properly cited, appropriate credit is given, any changes made indicated, and the use is non-commercial. See: <http://creativecommons.org/licenses/by-nc/4.0/>.

ORCID iDs

Ricardo A Hanel <http://orcid.org/0000-0001-7195-5806>

Demetrius Klee Lopes <http://orcid.org/0000-0002-6280-0113>
 Pascal Jabbour <http://orcid.org/0000-0002-1544-4910>
 Vitor Mendes Pereira <http://orcid.org/0000-0002-6804-3985>
 Maxim Mokin <http://orcid.org/0000-0003-4270-8667>
 Philipp Taussky <http://orcid.org/0000-0001-9247-0146>
 Gabor Toth <http://orcid.org/0000-0002-3646-3635>
 Justin F Fraser <http://orcid.org/0000-0002-5980-3989>
 Michael Chen <http://orcid.org/0000-0003-2412-8167>
 Peter Kan <http://orcid.org/0000-0001-6649-4128>
 David Fiorella <http://orcid.org/0000-0002-2677-8780>
 Donald Frei <http://orcid.org/0000-0002-7811-5030>
 Adel M Malek <http://orcid.org/0000-0002-0642-7609>

REFERENCES

- Nelson PK, Lylyk P, Szikora I, *et al*. The pipeline embolization device for the intracranial treatment of aneurysms trial. *AJNR Am J Neuroradiol* 2011;32:34–40.
- Becske T, Kallmes DF, Saatci I, *et al*. Pipeline for uncoilable or failed aneurysms: results from a multicenter clinical trial. *Radiology* 2013;267:858–68.
- Becske T, Brinjikji W, Potts MB, *et al*. Long-term clinical and angiographic outcomes following pipeline embolization device treatment of complex internal carotid artery aneurysms: five-year results of the pipeline for uncoilable or failed aneurysms trial. *Neurosurgery* 2017;80:40–8.
- Chalouhi N, Zanaty M, Whiting A, *et al*. Safety and efficacy of the pipeline embolization device in 100 small intracranial aneurysms. *J Neurosurg* 2015;122:1498–502.
- Griessenauer CJ, Ogilvy CS, Foreman PM, *et al*. Pipeline embolization device for small intracranial aneurysms: evaluation of safety and efficacy in a multicenter cohort. *Neurosurgery* 2017;80:579–87.
- Kallmes DF, Hanel R, Lopes D, *et al*. International retrospective study of the pipeline embolization device: a multicenter aneurysm treatment study. *AJNR Am J Neuroradiol* 2015;36:108–15.
- Hanel RA, Kallmes DF, Lopes DK, *et al*. Prospective study on embolization of intracranial aneurysms with the pipeline device: the premier study 1 year results. *J Neurointerv Surg* 2020;12:62–6.
- Chancellor B, Raz E, Shapiro M, *et al*. Flow diversion for intracranial aneurysm treatment: trials involving flow diverters and long-term outcomes. *Neurosurgery* 2020;86:S36–45.
- Ravindran K, Casabella AM, Czebra J, *et al*. Mechanism of action and biology of flow diverters in the treatment of intracranial aneurysms. *Neurosurgery* 2020;86:S13–19.
- Kühn AL, Gounis MJ, Puri AS. Introduction: history and development of flow diverter technology and evolution. *Neurosurgery* 2020;86:S3–10.
- Rinkel GJ, Djibuti M, Algra A, *et al*. Prevalence and risk of rupture of intracranial aneurysms: a systematic review. *Stroke* 1998;29:251–6.
- Wiebers DO, Whisnant JP, Huston J, *et al*. Unruptured intracranial aneurysms: natural history, clinical outcome, and risks of surgical and endovascular treatment. *Lancet* 2003;362:103–10.
- Güresir E, Vatter H, Schuss P, *et al*. Natural history of small unruptured anterior circulation aneurysms: a prospective cohort study. *Stroke* 2013;44:3027–31.
- Nahed BV, DiLuna ML, Morgan T, *et al*. Hypertension, age, and location predict rupture of small intracranial aneurysms. *Neurosurgery* 2005;57:676–83.
- Bender MT, Colby GP, Lin L-M, *et al*. Predictors of cerebral aneurysm persistence and occlusion after flow diversion: a single-institution series of 445 cases with angiographic follow-up. *J Neurosurg* 2018;130:259–67.
- Chiu AHY, Cheung AK, Wenderoth JD, *et al*. Long-term follow-up results following elective treatment of unruptured intracranial aneurysms with the pipeline embolization device. *AJNR Am J Neuroradiol* 2015;36:1728–34.
- Lylyk I, Scrivero E, Lundquist J, *et al*. Pipeline embolization devices for the treatment of intracranial aneurysms, single-center registry: long-term angiographic and clinical outcomes from 1000 aneurysms. *Neurosurgery* 2021;89:443–9.
- Hanel RA, Monteiro A, Nelson PK, *et al*. Predictors of incomplete aneurysm occlusion after treatment with the pipeline embolization device: premier trial 1 year analysis. *J Neurointerv Surg* 2021;neurintsurg-2021-018054.
- Kan P, Srinivasan VM, Mbabuie N, *et al*. Aneurysms with persistent patency after treatment with the pipeline embolization device. *J Neurosurg* 2017;126:1894–8.
- Cekirge HS, Saatci I. A new aneurysm occlusion classification after the impact of flow modification. *AJNR Am J Neuroradiol* 2016;37:19–24.
- Saatci I, Yavuz K, Ozer C, *et al*. Treatment of intracranial aneurysms using the pipeline flow-diverter embolization device: a single-center experience with long-term follow-up results. *AJNR Am J Neuroradiol* 2012;33:1436–46.
- Yavuz K, Geyik S, Saatci I, *et al*. Endovascular treatment of middle cerebral artery aneurysms with flow modification with the use of the pipeline embolization device. *AJNR Am J Neuroradiol* 2014;35:529–35.
- Brinjikji W, Murad MH, Lanzino G, *et al*. Endovascular treatment of intracranial aneurysms with flow diverters: a meta-analysis. *Stroke* 2013;44:442–7.
- Chalouhi N, Starke RM, Yang S, *et al*. Extending the indications of flow diversion to small, unruptured, saccular aneurysms of the anterior circulation. *Stroke* 2014;45:54–8.

- 25 Lin L-M, Colby GP, Kim JE, *et al*. Immediate and follow-up results for 44 consecutive cases of small (<10 mm) internal carotid artery aneurysms treated with the pipeline embolization device. *Surg Neurol Int* 2013;4:114.
- 26 Chalouhi N, Daou B, Barros G, *et al*. Matched comparison of flow diversion and coiling in small, noncomplex intracranial aneurysms. *Neurosurgery* 2017;81:92–7.
- 27 Salem MM, Ravindran K, Enriquez-Marulanda A, *et al*. Pipeline embolization device versus stent-assisted coiling for intracranial aneurysm treatment: a retrospective propensity score-matched study. *Neurosurgery* 2020;87:516–22.
- 28 Malhotra A, Wu X, Brinjikji W, *et al*. Pipeline endovascular device vs stent-assisted coiling in small unruptured aneurysms: a cost-effectiveness analysis. *Neurosurgery* 2019;85:E1010–9.