

Marquette University

e-Publications@Marquette

School of Dentistry Faculty Research and
Publications

Dentistry, School of

3-2019

Primary Molar Pulpotomies with Different Hemorrhage Control Agents and Base Materials: A Randomized Clinical Trial

G. Atasever
Hacettepe University

T. I. Keceli
Hacettepe University

Serdar Uysal
Hacettepe University

H. Cem Güngör
Marquette University, hcem.gungor@marquette.edu

S. Olmez
Hacettepe University

Follow this and additional works at: https://epublications.marquette.edu/dentistry_fac



Part of the [Dentistry Commons](#)

Recommended Citation

Atasever, G.; Keceli, T. I.; Uysal, Serdar; Güngör, H. Cem; and Olmez, S., "Primary Molar Pulpotomies with Different Hemorrhage Control Agents and Base Materials: A Randomized Clinical Trial" (2019). *School of Dentistry Faculty Research and Publications*. 484.

https://epublications.marquette.edu/dentistry_fac/484

Primary Molar Pulpotomies with Different Hemorrhage Control Agents and Base Materials: A Randomized Clinical Trial

G Atasever, T İleri Keçeli¹, S Uysal², HC Güngör¹, S Ölmez¹

Private Practice,
Specialist in Pediatric
Dentistry, Departments
of ¹Pediatric Dentistry
and ²Dentomaxillofacial
Radiology, Faculty of
Dentistry, Hacettepe
University, Ankara, Turkey

ABSTRACT

Objective: To evaluate the clinical and radiographical success of primary molar pulpotomies which used 15.5% ferric sulfate (FS) or 1.25% sodium hypochlorite (NaOCl) for hemostasis and zinc oxide–eugenol (ZOE) and calcium hydroxide (CH) pastes as base materials. **Methods:** In 29 healthy children, 80 primary molars were randomly allocated to one of the study groups: Group 1: FS-ZOE, Group 2: FS-CH, Group 3: NaOCl-ZOE, and Group 4: NaOCl-CH. After hemostasis with the respective solutions, pulp stumps and floor of the pulp chambers were covered with either ZOE or CH pastes. All teeth were restored with stainless steel crowns. Follow-up examinations were carried out at 1, 3, 6, and 12 months. **Results:** One tooth in Group 1 and two teeth in Group 4 were extracted because of pain and periapical pathosis at sixth month. After 12 months, clinical success rates of pulpotomies in Groups 1–4 were 95%, 100%, 100%, and 89.5%, respectively. The differences were not significant ($P = 0.548$). Radiographic success rates for Groups 1–4 were 80%, 88.9%, 78.9%, and 84.2%, respectively. No statistically significant difference was found ($P = 0.968$). Pain on percussion was the most observed clinical finding. However, internal root resorption was the most common radiological finding and it was observed significantly more in mandibular primary molars ($P < 0.05$). **Conclusion:** Both ZOE and CH can be preferred as base materials after hemostasis achieved by the use of 15.5% FS or 1.25% NaOCl in primary tooth pulpotomy.

KEYWORDS: Calcium hydroxide, ferric sulfate, primary teeth, pulpotomy, sodium hypochlorite, zinc oxide–eugenol

Date of Acceptance:
31-Oct-2018

INTRODUCTION

The philosophy of primary tooth pulpotomy is to remove the inflamed or infected coronal pulp tissue and cover the pulp stumps with a therapeutic agent. The success mostly depends on correct diagnosis of pulp status. However, other factors such as control of pulpal bleeding after coronal pulp amputation, the choice of base material used, restoration, and microleakage also contribute to the outcome.^[1]

Pulpal hemorrhage control is an indispensable step in pulpotomy procedures. Some studies have indicated that if the hemorrhage is not controlled, the blood clot forming on the pulp surface could prevent intimate contact between the pulp tissue and the capping material, which may result in a chronic inflammatory response.^[1,2]

The most widely used method to control bleeding during pulp therapy is to apply slight mechanical pressure with a cotton pellet wetted with saline over the pulp exposure. Hydrogen peroxide and anesthetic solutions containing epinephrine have also been used to this end.^[3–5] Ferric sulfate (FeSO₄) (FS) is a widely known hemostatic agent which has gained considerable popularity in primary tooth pulpotomy. In contrast to other traditional agents, FS provides hemostasis by some chemical reactions in blood.^[6]

Address for correspondence: Asst Prof. T İleri Keçeli,
Department of Pediatric Dentistry, Faculty of Dentistry,
Hacettepe University, 06100 Ankara, Turkey.
E-mail: tulinileri@yahoo.com

This is an open access journal, and articles are distributed under the terms of the Creative Commons Attribution-NonCommercial-ShareAlike 4.0 License, which allows others to remix, tweak, and build upon the work non-commercially, as long as appropriate credit is given and the new creations are licensed under the identical terms.

For reprints contact: reprints@medknow.com

How to cite this article: Atasever G, Keçeli Tİ, Uysal S, Güngör HC, Ölmez S. Primary molar pulpotomies with different hemorrhage control agents and base materials: A randomized clinical trial. Niger J Clin Pract 2019;22:305-12.

Access this article online

Quick Response Code:



Website: www.njcponline.com

DOI: 10.4103/njcp.njcp_369_18

Another promising alternative to hemostatic agents is sodium hypochlorite (NaOCl). It is not only an effective hemostatic agent but also considered an invaluable antibacterial agent without adverse effects on pulp repair, healing, and tertiary dentinogenesis.^[7] Its duration of use and different concentrations have been evaluated for pulpal hemorrhage control in a number of pulpotomy studies with primary teeth.^[7,8] The current literature supports the use of NaOCl at various concentrations ranging from 0.12% to 5.25% as a safe and appropriate hemostatic agent in vital pulp therapy procedures.^[8,9]

Once hemostasis is obtained, the remaining pulp tissue should be covered with a biocompatible material. Zinc oxide–eugenol (ZOE) paste is a common medicament placed over the treated pulp. However, because of its irritating effect, the eugenol component of the paste has been associated with claims of failure in primary molar pulpotomy.^[10,11]

Calcium hydroxide (CH) is another preferred pulpotomy dressing material with a clinical success rate ranging from 31% to 100%.^[12] The alkaline pH induced by CH both neutralizes lactic acid formation from osteoclasts and activates alkaline phosphatases which play an important role in the formation of hard tissue. However, based on the possibility of internal resorption caused by pulpal inflammation or bleeding, there is no consensus on the use of CH in primary tooth pulpotomy.^[12-14]

This study aimed to evaluate the effects of ZOE and CH as base materials on the clinical and radiographic success of primary tooth pulpotomies where FS and NaOCl are used as hemorrhage control agents.

METHODS

Participants

The study was carried out in the pediatric dentistry clinics in the Faculty of Dentistry, Hacettepe University, Ankara, Turkey. Institutional Human Subject Review Committee of Hacettepe University approved the study protocol and the consent form (2013/14-01; KA-130074).

Patients with at least one primary molar with extensive caries that required pulpotomy treatment were invited to participate in the study if,

1. The tooth has no clinical symptoms or signs of pulp degeneration, such as a history of spontaneous pain or swelling, tenderness to percussion, sinus tract, pathological mobility
2. The tooth is without radiographical signs of pathological (internal or external) resorption, widened periodontal ligament space not exceeding one-third physiological root resorption

3. Hemorrhage control was obtained following access to the pulp chamber
4. The tooth is restorable with a stainless steel crown (SSC).

Patients with a history of systemic disease or known to have allergic reaction to local anesthetics used were excluded from the study. The parents were informed and written consents were obtained.

Interventions

In all the groups, the procedures started with the application of a 20% benzocaine gel (Topex, Sultan Dental, Hackensack, NJ, USA) for 5 min. An anesthetic solution containing 2% articaine with 1:100,000 epinephrine (Maxicain D-S; Aventis Pharma San ve Tic, İstanbul, Turkey) was administered. After isolation with rubber dam, caries was removed with high-speed diamond fissure burs under copious irrigation. Upon pulp exposure, the roof of the pulp chamber was removed with a sterile high-speed diamond round bur (ISO size 014-016, DIATECH-Coltène/Whaledent AG, Altstätten, Switzerland). The coronal pulp tissue was amputated at the pulp stumps with slow-speed steel round burs (ISO size 023-025), and the pulp chamber was thoroughly irrigated with sterile physiologic saline. Sterile cotton pellets were slightly compressed against the radicular pulp stumps for 5 min. If the bleeding did not stop after 5 min, the tooth was excluded from the study.

The teeth were then randomly allocated to one of the four study groups with respect to the hemorrhage control agent and the base material used: Group 1: FS-ZOE, Group 2: FS-CH, Group 3: NaOCl-ZOE, and Group 4: NaOCl-CH. Block randomization of allocation was done using sequentially numbered opaque-sealed envelopes.^[15]

In Groups 1 and 2, 15.5% FS (Astringent™; Ultradent Products Inc., Salt Lake City, UT, USA) was applied on the pulp stumps with the dental infuser for 15 s in accordance with the manufacturer's recommendation. The pulp chamber was then flushed with saline and dabbed with cotton pellets which was then filled with ZOE paste (Kalzinol; DENTSPLY DeTrey, Konstanz, Germany) in Group 1 or CH paste (Merck, Darmstadt, Germany) (powder mixed with sterile saline at 1:1 ratio) in Group 2. In Groups 3 and 4, a cotton pellet soaked in 1.25% NAOCL was placed in the chamber for 30 s. Following hemostasis, the pulp chamber was flushed with saline, dabbed with cotton pellets, and filled by either ZOE (in Group 3) or CH (in Group 4) pastes as described above.

In all the cavities, the base materials were then covered with glass ionomer cement (Kavitan Pro; SpofaDenta Inc., Markova, Czech Republic). SSCs were placed at

the same appointment and an immediate postoperative radiograph was taken from each tooth. All procedures were performed by the same investigator (GA).

Follow-up

The evaluations comprised clinical and radiographic examinations. Each examination (clinical or radiographic) was performed independently by two investigators who were blinded to the hemorrhage control agent or the dressing material used. A forced consensus was sought in any case of disagreement. The inter- and intraexaminer reproducibility was calculated by Cohen's unweighted kappa statistic.

The teeth were examined clinically at 1, 3, 6, and 12 months ($k = 0.87$ and 0.90 for inter- and intraexaminer reproducibility, respectively). Standardized forms were used to record the following signs and symptoms, any of which were regarded as failure: (1) history of spontaneous pain, (2) a reliable reporting of tenderness to percussion/palpation, (3) mobility, (4) swelling, and (5) fistula. Treatment was recorded as a clinical success if any of these failure parameters were not met.

The evaluation of the radiographs, taken at 6 and 12 months, was made using a standard viewing box. Radiographic success was considered as absence of (1) periapical/interradicular radiolucency, (2) widened periodontal ligament, (3) loss of lamina dura, and (4) internal/external root resorption. Any disagreement was resolved by having both examiners view the radiograph again and come to an agreement ($k = 0.85$ and 0.87 for inter- and intraexaminer reproducibility, respectively).

Statistical analysis

All data were tabulated and analyzed using the Statistical Package for Social Science (SPSS for

Windows version 11.5; SPSS Inc, Chicago, IL, USA). The differences were statistically analyzed using Fisher's exact and Chi-square tests. The level of significance was set at $P < 0.05$.

RESULTS

In all, 29 children, age 6–9 years (16 males and 13 females; mean age 7.39 ± 1.05 years) participated in the study. Eighty primary teeth were treated with pulpotomy. Four teeth, two from Group 2 (FS-CH), one from Group 3 (NaOCl-ZOE), and one from Group 4 (NaOCl-CH), were not available for evaluation at 12 months because of exfoliation. The remaining 76 teeth, with their SSCs on, were available for analysis. They were 13 maxillary first molars, 17 maxillary second molars, 27 mandibular first molars, and 19 mandibular second molars. At the sixth month control visits, one tooth in Group 1 and two teeth in Group 4 were extracted because of pain and periapical pathosis. Space maintainers were fabricated for those extracted teeth. The flow of participants and pulpotomies that were followed from allocation to final data analysis after 12 months are shown in Figure 1.

Clinical success rates for Groups 1–4 after 12 months were 95%, 94.4%, 100%, and 89.5%, respectively. The differences between the study groups were not statistically significant ($P > 0.05$) [Table 1]. With respect to the hemorrhage control agents, FS and NaOCl (i.e., Groups 1 and 2 vs. Groups 3 and 4) have the same success rates of 94.7%. Clinical success rates in ZOE and CH groups (i.e., Groups 1 and 3 vs. Groups 2 and 4) were 97.4% and 91.9%, respectively. There was no statistical significance ($P > 0.05$). The differences for tooth location (mandibular or maxillary

Table 1: Clinical and radiographical success rates with respect to groups, hemorrhage control agents, and base materials after 12 months

	<i>n</i>	Clinical evaluation		<i>P</i>	Radiographical evaluation		<i>P</i>
		Success (<i>n</i> =72) <i>n</i> (%)	Failure (<i>n</i> =4) <i>n</i> (%)		Success (<i>n</i> =59) <i>n</i> (%)	Failure (<i>n</i> =17) <i>n</i> (%)	
Group**							
1. FS-ZOE	20	19 (95%)	1 (5%) [†]	0.548	16 (80%)	4 (20%)	0.968
2. FS-CH	18 ^a	18 (100%)	0 (0%)		16 (88.9%)	2 (11.1%)	
3. NaOCl-ZOE	19 ^b	19 (100%)	0 (0%)		15 (78.9%)	4 (21.1%)	
4. NaOCl-CH	19 ^c	17 (89.5%)	2 (10.5%) ^Δ		16 (84.2%)	3 (15.8%)	
Hemorrhage control agent*							
FS	38	37 (97.3%)	1 (2.7%)	1.000	32 (84.2%)	6 (15.8%)	1.000
NaOCl	38	36 (94.7%)	2 (5.3%)		31 (81.6%)	7 (18.4%)	
Base material*							
ZOE	39	38 (97.4%)	1 (2.6%)	0.352	31 (79.5%)	8 (20.5%)	1.000
CH	37	35 (94.6%)	2 (5.4%)		32 (86.5%)	5 (13.5%)	

FS=Ferric sulfate; ZOE=Zinc oxide–eugenol; CH=Calcium hydroxide; NaOCl=Sodium hypochlorite. *Fisher's exact test, **Chi-square test. ^{a-c}Number of evaluated teeth available because of exfoliation. ^{†,Δ}Number of teeth extracted (at sixth month)

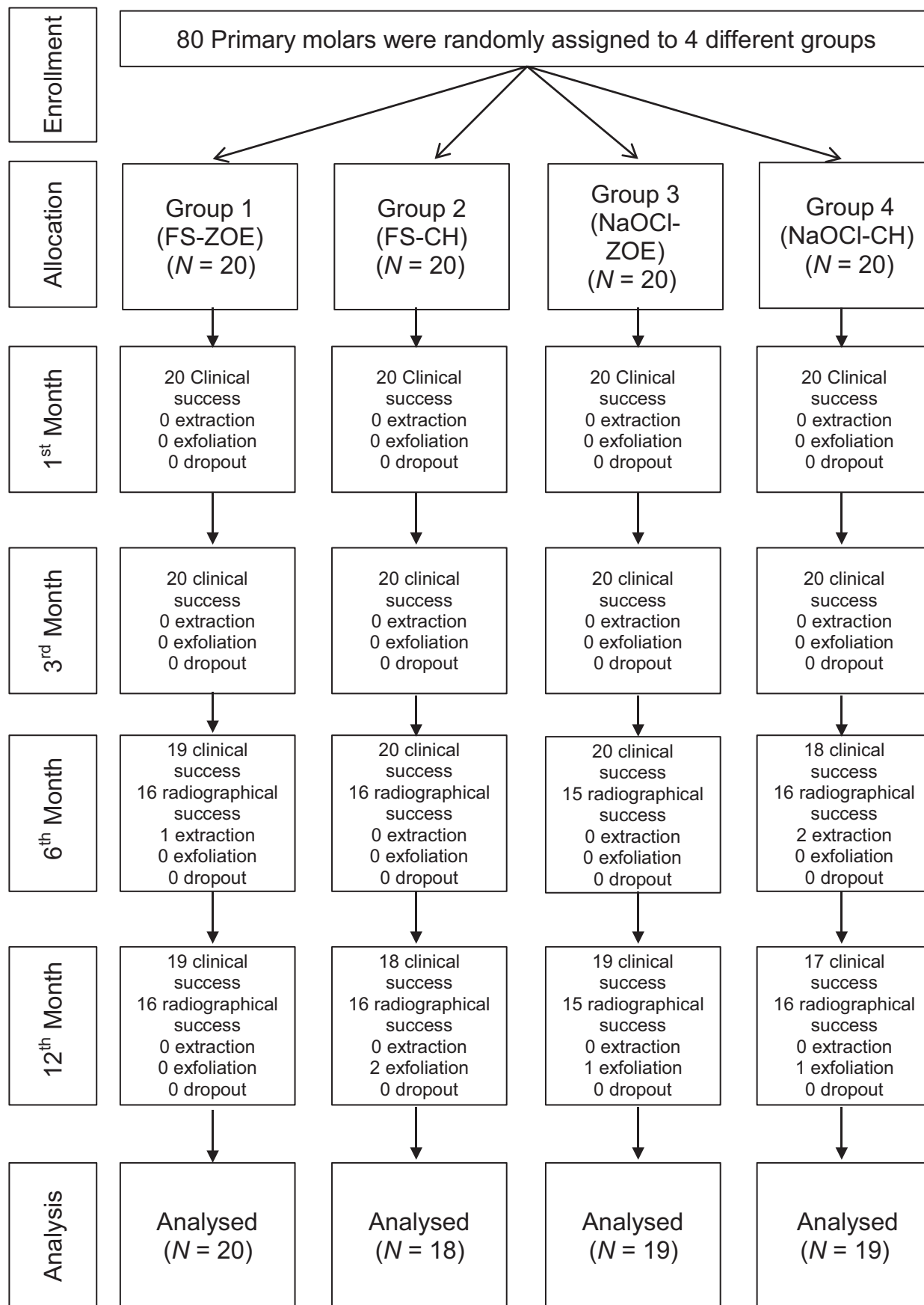


Figure 1: The flow of participants in the study

Table 2: Clinical and radiographical success rates in the study groups with respect to evaluation periods

	Study groups				P
	1. FS-ZOE (n=20)	2. FS-CH (n=20)	3. NaOCl-ZOE (n=20)	4. NaOCl-CH (n=20)	
Clinical success					
Baseline	20/20 (100%)	20/20 (100%)	20/20 (100%)	20/20 (100%)	-
1 st month	20/20 (100%)	20/20 (100%)	20/20 (100%)	20/20 (100%)	-
3 rd month	20/20 (100%)	20/20 (100%)	20/20 (100%)	20/20 (100%)	-
6 th month	19/20 (95%) [†]	20/20 (100%)	20/20 (100%)	18/20 (90%) ^Δ	0.584
12 th month	19/20 (95%)	18/18 ^a (100%)	19/19 ^b (100%)	17/19 ^c (89.5%)	0.585
Radiographical success					
Baseline	20/20 (100%)	20/20 (100%)	20/20 (100%)	20/20 (100%)	-
6 th month	16/20 (80%) [†]	16/20 (80%)	15/20 (75%)	16/20 (80%) ^Δ	0.605
12 th month	16/20 (80%)	16/18 ^a (88.9%)	15/19 ^b (78.9%)	16/19 ^c (84.2%)	0.261

FS=Ferric sulfate; ZOE=Zinc oxide-eugenol; CH=Calcium hydroxide; NaOCl=Sodium hypochlorite. ^{a-c}Number of evaluated teeth changed because of exfoliation. [†]One of the teeth was extracted because of pain and periapical pathosis. ^ΔTwo of the teeth were extracted because of pain and periapical pathosis

Table 3: Clinical and radiographical success rates with respect to hemorrhage control agents, base materials, and evaluation periods

	Hemorrhage control agents			Base materials		
	FS (n=40)	NaOCl (n=40)	P	ZOE (n=40)	CH (n=40)	P
Clinical success						
Baseline	40/40 (100%)	40/40 (100%)	-	40/40 (100%)	40/40 (100%)	-
1 st month	40/40 (100%)	40/40 (100%)	-	40/40 (100%)	40/40 (100%)	-
3 rd month	40/40 (100%)	40/40 (100%)	-	40/40 (100%)	40/40 (100%)	-
6 th month	39/40 (97.5%) [†]	38/40 (95%) ^Δ	0.754	39/40 (97.5%) [†]	38/40 (95%) ^Δ	1.000
12 th month	37/38* (97.3%)	36/38* (94.7%)	0.738	38/39* (97.4%)	35/37* (94.6%)	0.492
Radiographical success						
Baseline	40/40 (100%)	40/40 (100%)	-	40/40 (100%)	40/40 (100%)	-
6 th month	32/40 (80%) [†]	31/40 (77.5%) ^Δ	1.000	31/40 (77.5%) [†]	32/40 (80%) ^Δ	0.428
12 th month	32/38* (84.2%)	31/38* (81.6%)	1.000	31/39* (79.5%)	32/37* (86.5%)	0.114

FS=Ferric sulfate; NaOCl=Sodium hypochlorite; ZOE=Zinc oxide-eugenol; CH=Calcium hydroxide. *Number of evaluated teeth changed because of exfoliation. [†]One of the teeth was extracted because of pain and periapical pathosis. ^ΔTwo of the teeth were extracted because of pain and periapical pathosis

primary molar) and tooth types (first or second primary molar) were also insignificant for clinical success ($P > 0.05$, respectively).

Radiographical success rates were lower than those of clinical success in all study groups [Table 1]. The rates were 80%, 88.9%, 78.9%, and 84.2% for Groups 1–4, respectively. No statistically significant difference was found ($P > 0.05$). Radiographical success did not differ significantly with respect to hemorrhage control agents (i.e., Groups 1 and 2 vs. Groups 3 and 4) as these numbers were 84.2% for FS and 81.6% for NaOCl ($P > 0.05$). When the groups were compared according to base materials, radiographical success rates were 79.5% and 86.5% for ZOE and CH, respectively. The difference was not significant ($P > 0.05$).

Clinical and radiographical success rates with respect to evaluation periods are presented in Table 2. Similarly, in Table 3, those success rates were shown

for hemorrhage control agents and base materials. Tenderness to percussion was the most recorded clinical symptom. Internal root resorption was the most observed radiographic failure in all groups. Internal resorption was recorded for four teeth of Group 1 (FS-ZOE), two teeth of Group 2 (FS-CH), four teeth of Group 3 (NaOCl-ZOE), and three teeth of Group 4 (NaOCl-CH). Internal root resorption was observed significantly more in mandibular primary molars ($P < 0.05$).

DISCUSSION

Hemorrhage control following coronal pulp amputation is significant for the success of pulpotomy treatment. Prolonged bleeding may be a sign of pulpal inflammation which may diminish the healing capacity of the pulp. It has been suggested that pulp capping materials should not be placed over a bleeding pulp or a clinically observable blood clot, as it can be a

medium for bacterial growth.^[16] Moreover, during pulpal hemorrhage, erythrocytes within the pulp tissue would be hemolyzed to hemosiderin by macrophages. Hemosiderin, in excessive amounts, is detrimental to pulp vitality.^[3]

FS is commonly used as a hemostatic agent in dentistry, yet its exact mechanism is not fully understood. The metal–protein clot that forms at the surface upon contact with the solution has been suggested to control the hemorrhage. In pulpal procedures, this clot may also act as a barrier for irritative substances that cause inflammation and internal resorption.^[17] FS pulpotomies in primary molars using ZOE as base material have yielded clinical and radiographical success rates ranging from 85% to 100% and from 62% to 100% for the first year, respectively.^[3,6,18-21] All the teeth in these studies were restored with SSCs, as in this study. The clinical and radiographical success rates in FS-ZOE group were found to be comparable with the results of those studies cited above.

In Group 2, FS application was followed by placement of CH paste as a base material. The clinical and radiographic success rates at 12th month in this were 94.4% and 88.9%, respectively. Slightly different results were obtained in a study by Markovic *et al.*^[22] Their corresponding rates were 89% and 81% after 18-month evaluation period. In this study, the authors have chosen amalgam for restoration following pulpotomy, while this study used SSCs for final restoration of the teeth.

Previous studies revealed some negative aspects of ZOE as a base material in FS pulpotomies.^[18,23] Given the existing paucity of information, one of the aims of this study was to compare the effects of ZOE and CH as base materials on the success of FS pulpotomy. Although statistically not significant, when compared with ZOE, the application of CH as a base material after hemorrhage control with FS led to slightly better clinical (100% vs. 95%) and radiographical (88.9% vs. 80%) success.

Unlike FS, NaOCl selectively dissolves the superficial necrotic pulp tissue and establishes a dentin–pulp interface free of biofilm before placement of a base material.^[7,24-26] Its application at various concentrations and durations as a pulpal hemorrhage control agent in both vital noncarious and carious pulps has led to favorable results.^[27-29] Primary molar pulpotomy studies done with NaOCl and ZOE have reported clinical and radiographical success rates ranging from 95% to 100% and from 80% to 96% for the first year, respectively.^[6,21,30-34] In these studies, NaOCl was used at concentrations of 3%,^[31,32] 5%,^[6,30,33,34] and 5.25%.^[21] Durations of use varied among studies: while

30-s application was mostly preferred,^[6,30,33,34] 15-s^[21,32] and 5-min^[31] applications have also been reported. This study used 1.25% NaOCl with 30-s application time. The application was followed by saline flush similar to those studies above. The clinical and radiographical success rates in the NaOCl-ZOE group are 100% and 78.9%, respectively. These results are comparable to those stated above, given the significantly lower concentration of NaOCl used.

As an agent for hemorrhagic control, NaOCl has been used in CH pulpotomies of primary molars. Akcay and Sari^[35] applied 5% NaOCl after controlling pulpal hemorrhage with dry sterile cotton pellets. The pulp chambers were filled with reinforced ZOE after placement of CH base to the canal orifices. The teeth were restored with SSCs. They have reported 100% clinical and 84% radiographical success after 1 year. Tunc *et al.*^[12] compared the effect of 3% NaOCl with saline used as hemostatic agent on the outcome of CH pulpotomies of primary teeth. In the histologic evaluation carried out after extraction of the teeth, they found that none of the specimens in the saline group showed necrosis and one specimen in NaOCl group showed partial necrosis. The authors concluded that the use of 3% NaOCl as a hemorrhage control agent had no additive effect on the success of CH pulpotomies in primary teeth. They related their findings to the concentration and application time of NaOCl used. Akcay *et al.*,^[36] in another study, reported that the use of 5% NaOCl, compared with saline, did not contribute to the success of CH pulpotomies in primary molars after 12 months of observation. The authors reported 100% and 84% for clinical and radiographical success, respectively. Interestingly, the teeth which were “clinically and radiographically successful” after 1 year were subjected to histopathological evaluation, and significantly higher pulpal inflammation was observed in CH-treated teeth. In a recent systematic review and meta-analysis by Coll *et al.*,^[37] one of the conclusions was that CH was not recommended as a pulpotomy agent for primary teeth. Throughout this study, two of the three teeth that were extracted because of pain and periapical pathosis were in NaOCl-CH group. Clinical and radiographical success rates of this group were 89.5% and 84.2%, respectively.

In this study, the most recorded clinical symptom was “tenderness to percussion/palpation,” while internal resorption took the lead for radiographical failure. “Tenderness to percussion/palpation” is a subjective sign, especially in children. Moreover, pain history and pulp vitality tests have been regarded as unreliable in children, leading to inaccurate diagnosis of pulpal status.^[38] It

has also been stated that the reliability of the child's response to the percussion test is complicated depending on the psychological status involved.^[38] Therefore, this symptom alone was not regarded as clinical failure in this study and the teeth were included in the statistical analyses if other clinical and/or radiographical signs of failure were absent during follow-up visits.

Internal resorption is a frequently reported radiologic finding for pulpotomized primary teeth.^[6,39] There is a controversy in the literature whether internal root resorption is a failure. This pathology is generally considered to be the sign of a chronic inflammation.^[39] It has been suggested that after placement of ZOE paste, ongoing hydrolysis of zinc eugenolate may result in free eugenol to come in direct contact with the pulp tissue.^[11] This could cause moderate to severe inflammatory changes in the pulp leading to chronic inflammation and necrosis.^[10] Internal resorption is known to be one of the common responses of the pulp to chronic inflammation.^[39]

In this study, internal resorption was regarded as failure and recorded in a total of 16 teeth at the sixth month evaluation. Of those teeth, three (one in Group 1 and two in Group 4) were extracted because of other accompanying clinical and radiographical signs of pulpal infection. However, it was decided to follow the remaining 13 teeth to the 12th month visit as the resorption images were not involving osseous changes in the surrounding tissues.^[23,39] None of those 13 teeth showed clinical and radiographical changes necessitating extraction at the 12th month.

Internal resorption was observed significantly more in mandibular molars than in maxillary primary molars. This may be explained by the relatively less radiographic superpositioning of anatomical landmarks and primary molar teeth in mandibular radiographs compared with maxillary radiographs.^[40] For this reason, it has been assumed that it may be easier to identify and evaluate pathological conditions on mandibular radiographs.

This study is the first clinical trial to compare ZOE and CH as base materials where FS and NaOCl were used as hemorrhage control agents in primary tooth pulpotomy. It is also the first clinical trial where 1.25% NaOCl was used for hemorrhage control in primary tooth pulpotomy. Hence, no one-to-one comparisons could be made. The results of this study suggest that there are no significant differences between the base materials and hemorrhage control agents with respect to clinical and radiographic success of pulpotomies. However, there is no doubt that an increase in sample size and follow-up period would lead to more precise results. Second, the follow-up

radiographs were not obtained by paralleling technique. The use of a specific film holder is not routine in the institution where the study was carried out. Hence, the radiographs were obtained by the bisecting angle technique, making the standardization of the radiographs impossible. These should be stated as limitations of the study.

CONCLUSION

Within the limitations of this study, it can be concluded that both ZOE or CH may be preferred as suitable base materials in primary tooth pulpotomies either with 15.5% FS or 1.25% NaOCl as hemorrhage control agents.

Financial support and sponsorship

Nil.

Conflicts of interest

There are no conflicts of interest.

REFERENCES

1. Stanley HR. Conserving the dental pulp—Can it be done? Is it worth it? *Oral Surg Oral Med Oral Pathol* 1989;68:628-39.
2. Waterhouse PJ. Formocresol and alternative primary molar pulpotomy medicaments: A review. *Endod Dent Traumatol* 1995;11:157-62.
3. Fei AL, Udin RD, Johnson R. A clinical study of ferric sulfate as a pulpotomy agent in primary teeth. *Pediatr Dent* 1991;13:327-32.
4. Kitasako Y, Inokoshi S, Fujitani M, Otsuki M, Tagami J. Short-term reaction of exposed monkey pulp beneath adhesive resins. *Oper Dent* 1998;23:308-17.
5. Hebling J, Giro EMA, Costa CAD. Biocompatibility of an adhesive system applied to exposed human dental pulp. *J Endod* 1999;25:676-82.
6. Vargas KG, Packham B, Lowman D. Preliminary evaluation of sodium hypochlorite for pulpotomies in primary molars. *Pediatr Dent* 2006;28:511-7.
7. Hafez AA, Cox CF, Tarim B, Otsuki M, Akimoto N. An *in vivo* evaluation of hemorrhage control using sodium hypochlorite and direct capping with a one-or two-component adhesive system in exposed nonhuman primate pulps. *Quintessence Int* 2002;33:261-72.
8. Demir T, Cehreli ZC. Clinical and radiographic evaluation of adhesive pulp capping in primary molars following hemostasis with 1.25% sodium hypochlorite: 2-year results. *Am J Dent* 2007;20:182-8.
9. Hilton TJ. Keys to clinical success with pulp capping: A review of the literature. *Oper Dent* 2009;34:615-25.
10. Watts A, Paterson RC. Pulpal response to a zinc-oxide eugenol cement. *Int Endod J* 1987;20:82-6.
11. Hume WR. The pharmacologic and toxicologic properties of zinc oxide-eugenol. *J Am Dent Assoc* 1986;113:789-1.
12. Tunc ES, Saroglu I, Sari S, Gunhan O. The effect of sodium hypochlorite application on the success of calcium hydroxide pulpotomy in primary teeth. *Oral Surg Oral Med Oral Pathol Oral Radiol Endod* 2006;102:e22-6.
13. Percinoto C, de Castro AM, Pinto LM. Clinical and radiographic evaluation of pulpotomies employing calcium hydroxide and trioxide mineral aggregate. *Gen Dent* 2006;54:258-61.

14. Sonmez D, Duruturk L. Ca(OH)₂ pulpotomy in primary teeth. Part I: Internal resorption as a complication following pulpotomy. *Oral Surg Oral Med Oral Pathol Oral Radiol Endod* 2008;106:E94-8.
15. Doig GS, Simpson F. Randomization and allocation concealment: A practical guide for researchers. *J Crit Care* 2005;20:187-91; discussion 191-83.
16. Kopel HM. The pulp capping procedure in primary teeth "revisited." *ASDC J Dent Child* 1997;64:327-33.
17. Sonmez D, Sari S, Cetinbas T. A Comparison of four pulpotomy techniques in primary molars: A long-term follow-up. *J Endod* 2008;34:950-5.
18. Odabas ME, Alacam A, Sillelioglu H, Deveci C. Clinical and radiographic success rates of mineral trioxide aggregate and ferric sulphate pulpotomies performed by dental students. *Eur J Paediatr Dent* 2012;13:118-22.
19. Havale R, Anegundi RT, Indushekar K, Sudha P. Clinical and radiographic evaluation of pulpotomies in primary molars with formocresol, glutaraldehyde and ferric sulphate. *Oral Health Dent Manag* 2013;12:24-31.
20. Durmus B, Tanboga I. *In vivo* evaluation of the treatment outcome of pulpotomy in primary molars using diode laser, formocresol, and ferric sulphate. *Photomed Laser Surg* 2014;32:289-95.
21. Farsi DJ, El-Khodary HM, Farsi NM, El Ashiry EA, Yagmoor MA, Alzain SM. Sodium hypochlorite versus formocresol and ferric sulfate pulpotomies in primary molars: 18-month follow-up. *Pediatr Dent* 2015;37:535-40.
22. Markovic D, Zivojinovic V, Vucetic M. Evaluation of three pulpotomy medicaments in primary teeth. *Eur J Paediatr Dent* 2005;6:133-8.
23. Fuks AB, Holan G, Davis JM, Eidelman E. Ferric sulfate versus dilute formocresol in pulpotomized primary molars: long-term follow up. *Pediatr Dent* 1997;19:327-30.
24. Rosenfeld EF, James GA, Burch BS. Vital pulp tissue response to sodium hypochlorite. *J Endod* 1978;5:140-6.
25. Tang HM, Nordbo H, Bakland LK. Pulpal response to prolonged dentinal exposure to sodium hypochlorite. *Int Endod J* 2000;33:505-8.
26. Ibricevic H, al-Jame Q. Ferric sulfate as pulpotomy agent in primary teeth: Twenty-month clinical follow-up. *J Clin Paediatr Dent* 2000;24:269-72.
27. Cox CF, Hafez AA, Akimoto N, Otsuki M, Suzuki S, Tarim B. Biocompatibility of primer, adhesive, and resin composite systems on nonexposed and exposed pulps of nonhuman primate teeth. *Am J Dent* 1998;10:S55-63.
28. Clarkson RM, Moule AJ. Sodium hypochlorite and its use as an endodontic irrigant. *Aust Dent J* 1998;43:250-6.
29. Akimoto N, Momoi Y, Kohno A, Suzuki S, Otsuki M, Suzuki S, *et al.* Biocompatibility of Clearfil Liner Bond 2 and Clearfil AP-X system on nonexposed and exposed primate teeth. *Quintessence Int* 1998;29:177-88.
30. Vostatek SF, Kanellis MJ, Weber-Gasparoni K, Gregorsok RL. Sodium hypochlorite pulpotomies in primary teeth: A retrospective assessment. *Pediatr Dent* 2011;33:327-32.
31. Ruby JD, Cox CF, Mitchell SC, Makhija S, Chompu-Inwai P, Jackson J. A randomized study of sodium hypochlorite versus formocresol pulpotomy in primary molar teeth. *Int J Paediatr Dent* 2013;23:145-52.
32. Shabzendedar M, Mazhari F, Alami M, Talebi M. Sodium hypochlorite vs formocresol as pulpotomy medicaments in primary molars: 1-year follow-up. *Pediatr Dent* 2013;35:329-32.
33. Al-Mutairi MA, Bawazir OA. Sodium hypochlorite versus Formocresol in primary molars pulpotomies: A randomized clinical trial. *Eur J Paediatr Dent* 2013;14:33-6.
34. Fernández CC, Martínez SS, Jimeno FG, Lorente Rodríguez A, Mercadé M. Clinical and radiographic outcomes of the use of four dressing materials in pulpotomized primary molars: A randomized clinical trial with 2-year follow-up. *Int J Paediatr Dent* 2013;23:400-7.
35. Akcay M, Sari S. The effect of sodium hypochlorite application on the success of calcium hydroxide and mineral trioxide aggregate pulpotomies in primary teeth. *Pediatr Dent* 2014;36:316-21.
36. Akcay M, Sari S, Duruturk L, Gunhan O. Effects of sodium hypochlorite as disinfectant material previous to pulpotomies in primary teeth. *Clin Oral Investig* 2015;19:803-11.
37. Coll JA, Seale NS, Vargas K, Marghalani AA, Al Shamali S, Graham L. Primary tooth vital pulp therapy: A systematic review and meta-analysis. *Pediatr Dent* 2017;39:16-123.
38. Camp JH. Diagnosis dilemmas in vital pulp therapy: Treatment for the toothache is changing, especially in young, immature teeth. *J Endod* 2008;34:S6-12.
39. Smith NL, Seale NS, Nunn ME. Ferric sulfate pulpotomy in primary molars: A retrospective study. *Pediatr Dent* 2000;22:192-9.
40. Trairatvorakul C, Sastararuj T. Indirect pulp treatment vs antibiotic sterilization of deep caries in mandibular primary molars. *Int J Paediatr Dent* 2014;24:23-31.