

Marquette University

e-Publications@Marquette

School of Dentistry Faculty Research and
Publications

Dentistry, School of

9-2018

Management of Cervical Root Fracture Injury in a Patient with Epilepsy: Case Report with 5-year Follow-up

Elif Ataol

Ankara, Turkey

Gizem Erbaş Ünverdi

Hacettepe University Faculty of Dentistry

H. Cem Güngör

Marquette University, hcem.gungor@marquette.edu

Follow this and additional works at: https://epublications.marquette.edu/dentistry_fac



Part of the [Dentistry Commons](#)

Recommended Citation

Ataol, Elif; Ünverdi, Gizem Erbaş; and Güngör, H. Cem, "Management of Cervical Root Fracture Injury in a Patient with Epilepsy: Case Report with 5-year Follow-up" (2018). *School of Dentistry Faculty Research and Publications*. 473.

https://epublications.marquette.edu/dentistry_fac/473

Marquette University

e-Publications@Marquette

Dentistry Faculty Research and Publications/School of Dentistry

This paper is NOT THE PUBLISHED VERSION.

Access the published version via the link in the citation below.

Special Care in Dentistry, Vol. 38, No. 5 (September/October 2018): 319-323. [DOI](#). This article is © Wiley and permission has been granted for this version to appear in [e-Publications@Marquette](#). Wiley does not grant permission for this article to be further copied/distributed or hosted elsewhere without express permission from Wiley.

Management of Cervical Root Fracture Injury in a Patient with Epilepsy: Case Report with 5-Year Follow-up

Elif Ataol

Private Practice, Ankara, Turkey

Gizem Erbaş Ünverdi

Faculty of Dentistry, Department of Pediatric Dentistry, Hacettepe University, Ankara, Turkey

Hamdi Cem Güngör

Faculty of Dentistry, Department of Pediatric Dentistry, Hacettepe University, Ankara, Turkey

Abstract

The difficulty in providing stability to the coronal segment makes cervical root fracture one of the most challenging dental traumatic injury. This type of injury is less frequent in children. However, due to their serious consequences and poor prognosis, tooth loss may occur. This report presents the management of a case of cervical root fracture in an 11-year-old patient with epilepsy. The stabilization of the root-fractured tooth with a splint failed due to the recurrent seizures the patient had. Coronal fragment was removed and vital root submergence was performed in order to support the alveolar growth. The natural tooth crown was incorporated into a modified Nance appliance to meet the esthetic and functional requirements of the patient. After 5-year follow-up, this treatment

approach has seemed to offer a long-term provisional and satisfactory solution to the consequences of a cervical root fracture injury.

1 INTRODUCTION

Epilepsy is one of the most frequent diseases in children and adolescents. It is a brain disorder characterized by an excessive neuronal discharge that can produce seizures, unusual body movements, and loss or change in consciousness.¹ Its prevalence ranges between 4 and 6 cases per 1000 children.² The cause of epilepsy may be of genetic (single gene) origin, or related to acquired insults such as cerebrovascular, trauma, infection, neoplasms (acquired or as metastases to brain) or autoimmune/inflammatory.³ The 2010 report of the International League against Epilepsy recommends that seizures be clearly described according to their motor, cognitive, autonomic, and sensory-experiential manifestations.³ In addition to the seizures, patients medicated with antiepileptic drugs may also experience side effects such as drowsiness, ataxia, blurred vision, and diplopia.⁴ These conditions put these patients at specific risk of injury during daily activities.

Traumatic dental injuries are commonly observed among patients with epileptic seizures.^{4,5} When compared to healthy controls, the relative risk for having injury was found to be 3.42 in patients with epilepsy.⁴ Lagunju et al.⁶ have reported a significantly higher frequency of injuries in children with epilepsy compared with their age- and sex-matched counterparts. They have also found a statistically significant association between seizure frequency and seizure-related injuries.⁶ Available data indicate that the risk for dentoalveolar injuries further increases in patients with poorly controlled epileptic seizures.⁷ The loss of consciousness during seizure events and falls, which are often sudden and unexpected, increases the risk of injury in individuals with epilepsy.⁸ In addition, lack of awareness on how to approach an individual having a seizure and insufficient protection measures may contribute to the injury and its severity.

Root fracture is a rare traumatic dental injury. It affects 0.5 to 7% of permanent teeth.⁹ The injury damages periodontal ligament, cementum, dentin, and the pulp. Horizontal root fractures, which comprise less than 3% of all dental injuries, frequently occur in the middle third of the root, followed by apical, cervical-mid-root and cervical regions.¹⁰ Tooth survival is significantly affected by the location of the root fracture. Fractures that are located closer to the cervical area have lesser survival potential.¹¹ However, in addition to psychosocial problems, tooth loss in a growing child has unfavorable developmental and esthetic outcomes resulting from compromised buccopalatal width of the alveolus following tooth extraction or loss.¹²

This case report aims to present the treatment approach followed in an epileptic patient with cervical-mid-root fracture.

2 CASE REPORT

A 7-year-old girl was brought to the pediatric dentistry department clinics by her mother. The patient's complaint was related to her maxillary permanent right central incisor. As reported by her mother, the patient began to feel that "her tooth was slightly moving" 1 day after an epileptic seizure occurring 2 days earlier. During that seizure, the patient has fallen down and hit her mouth by the corner of the table. As for her medical history; she has had a surgery for the repair of ventricular-septal defect. She

was also an epilepsy patient with generalized tonic-clonic convulsive seizures, which were happening 1 to 2 times daily. Her prescribed medications included levetiracetam and sodium valproate.

On clinical examination, slight mobility of tooth #11 and tenderness to percussion and palpation were noted. She had a delayed response to cold and electrical vitality tests. Radiographic examination revealed a horizontal root fracture of #11 with incomplete maturogenesis (Figure 1). It was also observed that the diastasis between fragments were minimum and the coronal fragment was not excessively dislocated. A diagnosis of cervical-mid-root fracture was made.

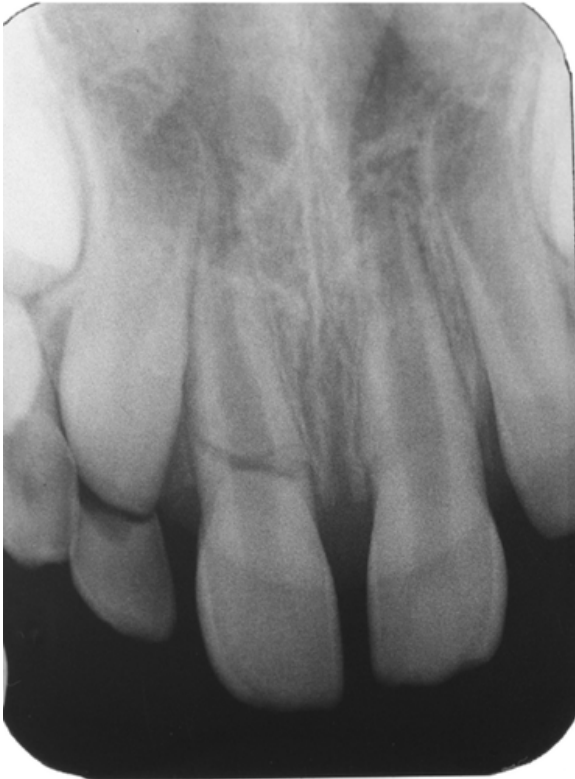

Figure 1 Baseline Radiograph Showing Horizontal Root Fracture on #11

The treatment plan, which comprised splinting of the affected tooth, was discussed with the parent and an informed consent was obtained. Teeth #11 and #21 were splinted by using 0.9 mm monofilament fishing line and composite resin. The patient was instructed on proper hygiene practices and her recall appointments were scheduled. Three weeks later, the patient came with partial detachment of the splint. It was assumed to occur during one of the seizures the patient had. The patient reported slight discomfort with her tooth. Since the mobility continued, the splint was repaired. It was decided to see the patient once a month and keep the splint in place to protect the tooth until the patient's seizures were under control.

At the second month visit, it was observed that the splint was in function. The patient was still having 1 to 2 seizures a day and the tooth presented slight mobility. At the third month, it was learnt that clonazepam was added to her medications. The number of seizures in a day decreased to 1. The splint was completely renewed at the fourth month visit. The seizures were once a day. At the sixth month visit, the periapical radiograph presented no pathological condition despite the seizures that were taking place once in 2 or 3 days. At the ninth month, it was learnt that the frequency of patient's

seizures reduced to once a week and less than once a month at 1-year visit. Clonazepam has been removed from her medication regime and clobazam has been added during these visits. Clinically, the tooth was in function with slight mobility. No pathology was observed in radiographic examination. The splint was left in place.

During a seizure at 16 months, the patient sustained another trauma to her tooth which resulted in complete detachment of the splint. A new splint was made. Another seizure, at 20 months, resulted in the extrusion of the coronal fragment (Figure 2). The tooth was partially attached to the palatal gingiva and became extremely mobile. Treatment alternatives were discussed with the parent: (1) Repositioning of the coronal segment and splinting. (2) Extraction of both apical and coronal fragments. (3) Extraction of only coronal fragment and keeping apical fragment in situ following proper pulp coverage. Repositioning of the coronal segment was not accepted by the parent. However, after explaining the benefit of keeping apical fragment on preserving alveolar bone growth, the parent consented on the third option.

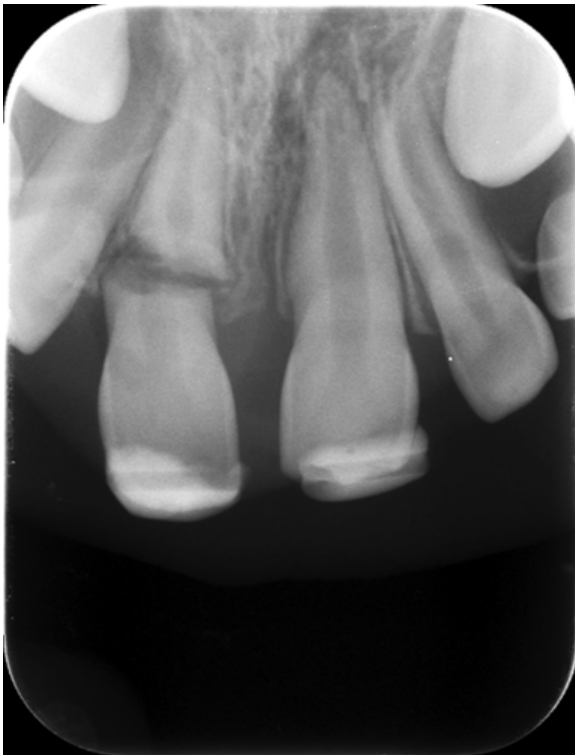

Figure 2 Radiograph Showing Extrusion of Coronal Fragment at 20 Months

As the patient had a surgically repaired ventricular-septal defect, extraction procedure was considered a high risk for infectious endocarditis. Hence, prophylaxis with 1 g amoxicillin (50 mg/kg orally) was administered to the patient 60 minutes prior to the procedure.¹³ The coronal fragment was removed under local anesthesia. It was stored in saline solution at 4°C until it was used to restore esthetics and function. The exposed pulp was covered with mineral trioxide aggregate (MTA Angelus, Londrina, Paraná, Brazil), which was followed by suturing of the gingival tissue over the root.¹⁴ The sutures were removed 1 week later. After complete healing of the gingiva, stainless-steel molar bands (Dentaurum, Ispringen, Germany) were placed on both maxillary first molars and an alginate impression was taken.

Molar bands were transferred into the impression to fabricate a Nance palatal arch comprising original tooth crown.

On a hard plaster model, the extracted crown was reduced to fit. The coronal dentin was removed to approximately 1 mm from the dentinoenamel junction using a high-speed air turbine with water cooling. A modification to Nance appliance was made by bending a round loop over the extraction site for acrylic retention. To copolymerize it with the pink denture resin (Dentaurum, Pforzheim, Germany), the crown was prepared with a microfilled hybrid resin composite material (Spectrum TPH, Shade B2, Dentsply, Konstanz, Germany) using an etch-and-rinse adhesive (Prime&Bond NT, Dentsply, Konstanz, Germany). Following pressurized polymerization, the appliance was removed from the model and roughly polished. After satisfactory try-in and fine polishing, the appliance was cemented with glass ionomer cement (Figures 3 and 4). Suggestions regarding good oral hygiene practices were given and the patient was recalled at 3-month intervals. During these visits, it was noted that the seizures were taking place less than once in a month. Her medications included clobazam in addition to levetiracetam and sodium valproate. The patient seemed to be highly satisfied with the esthetic and functional outcome and reported no discomfort with the use of the appliance. Radiographic examination, at 5-year, displayed healthy alveolar bone surrounding the submerged root (Figure 5).

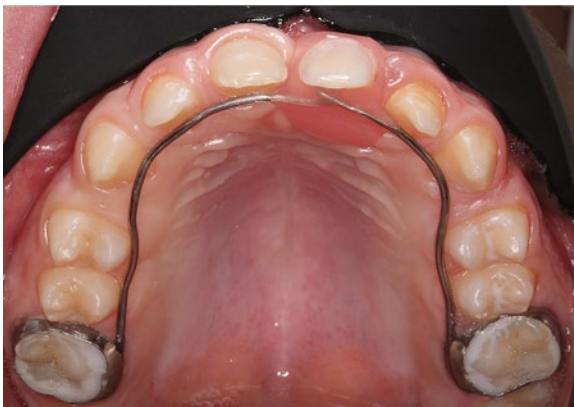

Figure 3 Intraoral Photo from Occlusal View at 5 years

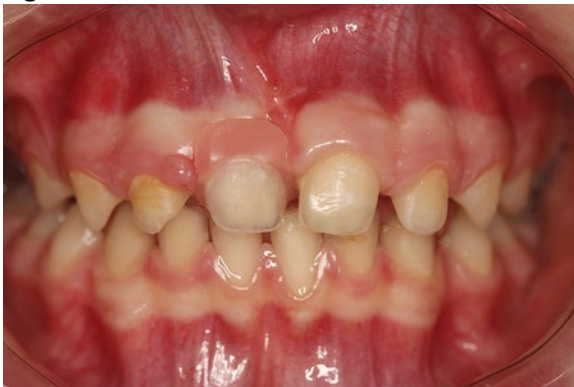

Figure 4 Intraoral Photo at 5 years

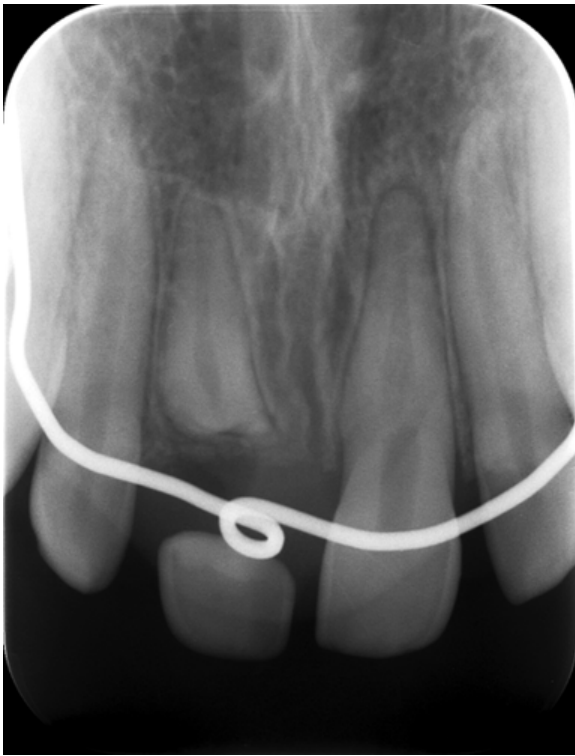


Figure 5 Radiograph of #11 at 5 years

3 DISCUSSION

International Association of Dental Traumatology (IADT) guidelines recommend repositioning of the displaced coronal segment following a root fracture injury.¹⁵ While stabilization with a flexible splint for 4 weeks is the usual suggestion for fractures in apical and mid-root fractures, a longer duration of stabilization (up to 4 months) has been recommended for fractures near the cervical area. A delay in stabilization for a few days does not appear to result in inferior healing.¹⁶ Healing of root-fractured teeth is strongly influenced by the factors such as the patient's age, stage of root development, mobility and dislocation of the coronal fragment, and diastasis between fragments following this kind of injury.¹⁷ Furthermore, the type of healing and location of the fracture are the decisive factors for the long-term survival following root fractures.¹¹ The highest frequency of tooth loss has been reported for teeth with horizontal fractures restricted to the cervical part of the root.¹⁸ In these cases, even minor impacts cause serious luxation injuries due to the pronounced posttreatment mobility.¹⁹ In the presented case, however, in addition to this condition, the recurrent seizures of the patient was assumed to be the major contributor to the unfavorable outcome of extraction of the coronal fragment.

In addition to psychosocial problems, tooth loss leads to damaging developmental and unaesthetic outcomes in a growing child. Following an extraction, the surrounding alveolar process loses height and width²⁰ resulting in narrowing and shortening of the residual ridge.²¹ This compromises the placement of an implant. In order to avoid these adverse outcomes, vital root submergence procedure was performed to support alveolar bone growth until the patient is fully grown.^{12, 14} After this period, the submerged root may be extracted and an implant-supported prosthetic restoration could be realized as a more predictable treatment to maximize the esthetic and functional outcome. As regards the prognosis of the submerged roots, few and insignificant inflammatory changes have been

reported.²² The submerged root in the present case remained vital and displayed healthy surrounding bone after 5-year follow-up.

Replacement of a missing permanent anterior tooth following a traumatic injury in a growing child can be accomplished by means of either fixed or removable appliances (i.e., partial prosthesis). In the presented case, a modified Nance appliance incorporating the patient's natural crown was fabricated to meet the developmental, esthetic, and emotional requirements of the patient. Besides providing the patient with optimum esthetics in terms of color, shape, and size, using natural tooth crown as a pontic may help to increase the patient's tolerance to tooth loss. A fixed appliance, compared to a partial prosthesis, also requires less patient compliance; eliminates compromised esthetics due to the presence of canine clasps and risk of fracture.^{12, 23} In addition, the use of such appliance bears no risk for restriction of maxillary growth and does not interfere with the increase in intercanine width.

The management plan of this case has been directed to help the patient to cope with the consequences of a cervical root fracture. It has offered a long-term provisional solution to a clinical problem with an individualized treatment plan that addressed the developmental, esthetic, and emotional demands of a child patient suffering from epilepsy.

CONFLICTS OF INTEREST

We, hereby, as the authors of this manuscript have no conflict of interest to declare. We state that we do not have any potential sources of conflict of interest. These include all the affiliations with or financial involvement in, within the past 5 years and foreseeable future, any organization or entity with a financial interest in or financial conflict with the subject matter or materials discussed in the manuscript (e.g., employment, consultancies, honoraria, stock ownership or options, expert testimony, grants or patents received or pending, royalties).

REFERENCES

- 1 Chhabra N, Chhabra A, Bansal S. An innovative approach to cessation of thumb-sucking in a child with epilepsy: a case report. *Spec Care Dentist*. 2012; 32: 270- 273.
- 2 Cowan LD, Bodensteiner JB, Leviton A, Doherty L. Prevalence of the epilepsies in children and adolescents. *Epilepsia*. 1989; 30: 94- 106.
- 3 Berg AT, Millichap JJ. The 2010 revised classification of seizures and epilepsy. *Continuum (Minneapolis)*. 2013; 19: 571- 597.
- 4 Asadi-Pooya AA, Nikseresht A, Yaghoubi E, Nei M. Physical injuries in patients with epilepsy and their associated risk factors. *Seizure*. 2012; 21: 165- 168.
- 5 Nonato ER, Borges MA. Oral and maxillofacial trauma in patients with epilepsy: prospective study based on an outpatient population. *Arq Neuropsiquiatr*. 2011; 69: 491- 495.
- 6 Lagunju IA, Oyinlade AO, Babatunde OD. Seizure-related injuries in children and adolescents with epilepsy. *Epilepsy Behav*. 2016; 54: 131- 134.
- 7 Costa AL, Yasuda CL, Franca MC, Jr, Morita ME, Cendes F. Refractory epilepsy is highly associated with severe dentoalveolar and maxillofacial injuries. *Epileptic Disord*. 2011; 13: 61- 64.
- 8 Wirrell EC. Epilepsy-related injuries. *Epilepsia*. 2006; 47(Suppl 1): 79- 86.
- 9 Andreasen JO. Etiology and pathogenesis of traumatic dental injuries. A clinical study of 1,298 cases. *Scand J Dent Res*. 1970; 78: 329- 342.
- 10 Caliskan MK, Pehlivan Y. Prognosis of root-fractured permanent incisors. *Endod Dent Traumatol*. 1996; 12: 129- 136.

- 11 Andreasen JO, Ahrensburg SS, Tsilingaridis G. Root fractures: the influence of type of healing and location of fracture on tooth survival rates—an analysis of 492 cases. *Dent Traumatol.* 2012; 28: 404- 409.
- 12 Keceli TI, Kutlu B, Gungor HC. Preserving alveolar bone growth following cervical root fracture: a case report. *J Can Dent Assoc.* 2013; 79: d158.
- 13 Habib G, Lancellotti P, Antunes MJ, et al. 2015 ESC guidelines for the management of infective endocarditis: the task force for the management of infective endocarditis of the European Society of Cardiology (ESC). Endorsed by: European Association for Cardio-Thoracic Surgery (EACTS), the European Association of Nuclear Medicine (EANM). *Eur Heart J.* 2015; 36: 3075- 3123.
- 14 Johnson BR, Jensen MR. Treatment of a horizontal root fracture by vital root submergence. *Endod Dent Traumatol.* 1997; 13: 248- 250.
- 15 Diangelis AJ, Andreasen JO, Ebeleseder KA, et al. International association of dental traumatology guidelines for the management of traumatic dental injuries: 1. Fractures and luxations of permanent teeth. *Dent Traumatol.* 2012; 28: 2- 12.
- 16 Andreasen JO, Andreasen FM, Mejare I, Cvek M. Healing of 400 intra-alveolar root fractures. 2. Effect of treatment factors such as treatment delay, repositioning, splinting type and period and antibiotics. *Dent Traumatol.* 2004; 20: 203- 211.
- 17 Andreasen JO, Andreasen FM, Mejare I, Cvek M. Healing of 400 intra-alveolar root fractures. 1. Effect of pre-injury and injury factors such as sex, age, stage of root development, fracture type, location of fracture and severity of dislocation. *Dent Traumatol.* 2004; 20: 192- 202.
- 18 Cvek M, Tsilingaridis G, Andreasen JO. Survival of 534 incisors after intra-alveolar root fracture in patients aged 7–17 years. *Dent Traumatol.* 2008; 24: 379- 387.
- 19 Cvek M, Mejare I, Andreasen JO. Healing and prognosis of teeth with intra-alveolar fractures involving the cervical part of the root. *Dent Traumatol.* 2002; 18: 57- 65.
- 20 Ten Heggeler JM, Slot DE, Van der Weijden GA. Effect of socket preservation therapies following tooth extraction in non-molar regions in humans: a systematic review. *Clin Oral Implant Res.* 2011; 22: 779- 788.
- 21 Pinho MN, Roriz VL. Titanium membranes in prevention of alveolar collapse after tooth extraction. *Implant Dent.* 2006; 15: 53- 61.
- 22 Rodd HD, Davidson LE, Livesey S, Cooke ME. Survival of intentionally retained permanent incisor roots following crown root fractures in children. *Dent Traumatol.* 2002; 18: 92- 97.
- 23 Ulusoy AT, Cehreli ZC. Provisional use of a natural tooth crown following failure of replantation: a case report. *Dent Traumatol.* 2008; 24: 96- 99.