

Histol Histopathol (2005) 20: 437-447

<http://www.hh.um.es>

## Histology and Histopathology

Cellular and Molecular Biology

# Administration of L-arginine reduces the delay of the healing process caused by ibuprofen. Implication of COX and growth factors expression

S. Sánchez-Fidalgo<sup>1</sup>, I. Martín-Lacave<sup>2</sup>, M. Illanes<sup>2</sup>, L. Bruseghini<sup>3</sup>, A. Esteras<sup>3</sup> and V. Motilva<sup>3</sup><sup>1</sup>Departament of Pharmacology, Faculty of Pharmacy, University of Seville, Spain, <sup>2</sup>Department of Normal and Pathological Cytology and Histology, Faculty of Medicine, University of Seville, Spain and <sup>3</sup>Zambon Group, Sta. Perpetua de Mogoda, Barcelona, Spain

**Summary.** The objective of the present study has been to advance knowledge of the gastric role played by the amino acid L-Arginine (L-Arg) in the evolution of a chronic gastric ulcer. In order to clarify it, L-Arg alone or together with Ibuprofen have been administrated in an experimental acetic acid chronic ulcer, analysing characteristic parameters of an active curative process, such as PGE<sub>2</sub> production, COX expression, and also angiogenesis, proliferation/apoptosis and growth factors expression. Our results reveal that L-Arg is favourable in the healing process improving the curative course. Ibuprofen caused a delay in ulcer healing, more evident 14 days after ulcer induction; COX-2 expression was increased at the 7<sup>th</sup> day although no signal of protein could be detected after 14 days; PGE<sub>2</sub> production was inhibited in intact and ulcerated areas at both times assayed. In contrast, treatment with L-Arg reduced the delay of the lesion, the increment in COX-2 expression induced by Ibuprofen, and was able to maintain PGE<sub>2</sub> levels similar to the control group after 14 days. Additionally, the histological study showed that the healing effects of L-Arg might be associated with an increased angiogenesis and FGF-2 expression. These actions could be considered key factors in the healing response associated with L-Arg administration. However, the proliferation study assayed with the PCNA-immunostaining method did not reveal significant differences, as the same as the apoptosis analysis. In conclusion, the coupling of L-Arg to Ibuprofen is an attractive alternative to Ibuprofen administration alone because it not only attenuates but also improves the evolution of chronic lesions through mechanisms that implicate endogenous PG and FGF-2-associated pathways, which allow an increase of angiogenesis process.

**Key words:** NSAID, L-Arginine, COX, FGF-2, angiogenesis, chronic gastric ulcer

### Introduction

Nonsteroidal anti-inflammatory drug (NSAID) causes damage in the gastric mucosa and impairment of ulcer healing as unwanted side effects. Although the inhibition of cyclooxygenase (COX), leading to depletion of endogenous prostaglandins (PGs), is a major pathogenic factor, it is unlikely that PGs deficiency alone is sufficient to initiate the process that ultimately results in gastric ulceration. Direct cytotoxicity of NSAIDs may be involved in NSAID-induced gastric lesions (Tomisato et al., 2004). The introduction of highly selective COX-2 inhibitors or the coprescriptions of gastroprotective agents with nonselective NSAIDs have offered strategies to reduce the incidence of gastroduodenal ulceration (James and Hawkey, 2003). However, different data with selective COX-2 inhibitors have shown that they can cause, in some experimental conditions, rates of gastric lesion comparable to those seen with traditional NSAIDs including the delay of chronic gastric ulcers (Berenguer et al., 2002; Villegas et al., 2002).

Other strategies for developing NSAID that spare the gastrointestinal tract from injury have been recently applied, including nitric oxide (NO) releasing NSAID (NO-NSAID) (Takeuchi et al., 2001; Konturek et al., 2003). The rationale behind this strategy is that NO released from these derivatives exerts a beneficial influence on gastric mucosa by enhancing the mucosal defensive ability and preventing pathogenic events resulting from suppression of PG synthesis such as a reduction in gastric microcirculation and the leukocyte-endothelial adherence. The major importance of NO in the prevention of mucosal damage or in preservation of ulcer healing is supported by previous studies showing that NO exerts gastroprotective activity and accelerates

healing mainly by the maintenance of blood flow around the ulcer and the angiogenic process, by attenuation of the oxidative injury and by compensation for PGs deficiency induced by NSAID (Brzozowski et al., 2000, 2001b; Konturek et al., 2003).

L-Arginine (L-Arg) is available as a commercial drug together with Ibuprofen to improve their pharmacokinetic characteristics. L-Arg, amino acid precursor of NO, has shown its protective effects against different experimental models of gastric lesions in rats (Szlachcic et al., 2001; Ohta and Nishida 2001, 2002). In previous studies, our group has observed the capacity of L-Arg to attenuate the acute damage induced by the NSAID Ibuprofen. This drug is considered a classical NSAID with a similar capacity to inhibit both COX-1 and COX-2 enzymes and clinical data show a low profile of gastrointestinal toxicity. The mechanism of the beneficial response of the amino acid was associated with a reduction of the oxidative response (Martín et al., 2001; Jiménez et al., 2004) and also with a protective effect mediated by COX/PG and NOS/NO/GMPc pathways (Jiménez et al., 2002).

The objective of the present study has been to advance the knowledge of the gastric role played by the amino acid L-Arg in the evolution and healing of a chronic gastric ulcer. In order to clarify it, L-Arg alone or together with Ibuprofen were administered to the ulcerated animals, by serosal application of acetic acid, analysing characteristic parameters of an active curative gastric process, such as PGE<sub>2</sub> production, COX expression, and also angiogenesis, proliferation/apoptosis and growth factor expressions.

## Materials and methods

### Animals

Male Wistar rats weighing 180-200 g (Service of Animals, University of Seville, Spain) were used. The rats were fed standard laboratory chow and tap water ad libitum. The animals were deprived of food for 18-20 hours before experiments but had free access to water. On the day of experimentation, all animals were randomly assigned to one of several groups. Experiments followed a protocol by the Ethical Committee for Experimental Research of the Faculty of Pharmacy of the University of Seville. All experiments were in accordance with the recommendations of the European Union.

### Gastric ulcer induction

Chronic gastric ulcers were induced on day 0 using 20% acetic acid, according to the method described previously with slight modifications (Motilva et al., 1996). Fastened rats were anaesthetized by diethyl ether. The abdomen was opened through a 2-cm laparotomy incision and the stomach was exposed and, at the

junction of the corpus and antrum, 50 µl of 20% acetic acid were injected with a micro syringe into the sub-serosal layer of the anterior wall of the stomach. The laparotomy incision was closed in two layers and the animals recovered on a warmed mat with free access to food and water.

Twenty-four hours following ulcer induction, groups of 14-16 rats were randomly allocated to receive one unique dose of the three drugs (L-Arg, Ibuprofen and L-Arg/Ibuprofen groups) or vehicle (control group) daily at first hours in the morning, for 7 or 14 days. In sham animals, the abdomen was opened and closed without injection.

### Drugs and doses assayed

The dose administered by Ibuprofen (Sigma Chemical Co., Mo USA) in all treatments was 100 mg/kg body wt. A similar dose of oral L-Arg (Sigma Chemical Co., Mo USA) plus Ibuprofen, each of them 100 mg/Kg body wt, was administered to another group of rats (L-Arg/Ibuprofen group). A standard group that received an orally similar dose of the amino acid alone, 100-mg/kg-body wt was introduced (L-Arg group).

The drugs were dissolved in water and were administered orally by gavages (1 ml/100 g body weight). Sham groups received the vehicle in a comparable volume. The doses were selected by extrapolation of the clinical human doses and according to studies previously performed in our group of investigation (Jiménez et al., 2002; Sánchez-Fidalgo et al., 2004).

### Analysis of the damage and tissue sample collection

Rats were killed by ether anaesthetization twenty-four hours after the late dose, and their stomachs were excised. The stomachs were cut along its greater curvature and the length and width of the gastric ulcer was measured determining the lesion index, and the degree of severity of the lesions was expressed as percentage of the control group.

Tissue from ulcer area including ulcer margin and the remaining adjacent glandular mucosa -non ulcerated area- were scraped with a glass slide on an ice-cold glass, and frozen immediately in liquid nitrogen before storage at -70 °C until they were used for Western blot, PGE<sub>2</sub> immunoassay and determination of apoptosis.

For the histological study, gastric ulcers were sampled at 7 and 14 days after ulcer induction and fixed in 4% buffered formaldehyde. Small pieces obtained from the stomach wall were dehydrated in cold with shaking by means of a set of alcohols of increasing concentration, from 50° until absolute alcohol. At the end, the tissues were introduced successively in xylene, xylene/paraffin 50%, finishing in paraffin at 60 °C. 24 hours later the blocks were formed and then sectioned with a Leica Ultracut for immunohistochemical analysis.

## Role of L-arginine in healing gastric ulcers

### Western Blot Analysis of Cyclooxygenase Enzyme

Samples of the stomach were taken from all groups treated and were homogenized in buffer containing sodium vanadate and centrifuged at 10000 g, 10 minutes, 4 °C. The supernatant was collected and the Bradford protein assay was carried out. 50 µg of protein were separated on 8% acrylamide gel by sodium dodecyl sulfate-polyacrylamide gel electrophoresis. In the next step, the proteins were electrophoretically transferred to a nitrocellulose membrane and probed with primary antiserum to COX-1 and COX-2 at a final dilution of 1:2000 and 1:400 respectively. The secondary horseradish peroxidase-linked donkey anti-goat immunoglobulin G antibody (Santa Cruz Biotechnology, CA) was used. Immunodetection was performed using enhanced chemiluminescence. The signals were analyzed and quantified by a Scientific Imaging Systems (KODAK 1D Image Analysis Software).

### Assessment of PGE<sub>2</sub> formation

For measurement of COX activity, PGE<sub>2</sub> was determined from gastric tissue samples obtained from sham and control groups but also from gastric samples of animals treated with different drugs. Briefly, gastric mucosa was excised and rapidly rinsed with ice-cold saline. The tissue was weighed and homogenized in 6 ml TEAP buffer (pH 3.24) that contained a COX inhibitor, Inyesprin<sup>®</sup>. The homogenate was centrifuged (3000 rpm, 10 min, 4 °C) and the supernatant was removed and passed through a reverse-phase octadecylsilica C18 Sep Pak cartridge which was washed with 10 ml distilled water, 10 ml 15% ethanol, 10 ml hexane and 10 ml ethylacetate, and the eluate collected. Each fraction with ethylacetate was evaporated, and the dry residue re-dissolved in ethanol. PGE<sub>2</sub> was determined by a competitive enzyme immunoassay kit (Cayman chemical). Results are expressed as pg PGE<sub>2</sub>/mg tissue.

### Immunohistochemistry for vascular endothelial growth factor (VEGF) and basic fibroblastic growth factor (FGF-2)

Formalin-fixed and paraffin-embedded tissue sections (5 µm) were dried in an oven at 55 °C for 1 hour and then deparaffinized in 2 changes of xylene and hydrated from graded alcohols to water.

The staining of VEGF was carried out using a Streptavidin-Biotin-Peroxidase method. A pressure-cooking antigen retrieval system was used in which the slides were boiled in 10 mM Tris (pH 10.0) at maximum pressure for 1 min, followed by cooling at room temperature for 20 minutes. The endogenous peroxidase activity was inhibited and then the sections were incubated in normal horse serum (Vectastain<sup>®</sup> Kit, Vector Laboratories, Inc., Burlingame, CA) for 20 min to reduce non-specific staining, and successively incubated with monoclonal mouse anti-VEGF antibody

(Oncogene<sup>™</sup> Research Products) at dilution 1:20 overnight at 4 °C. Subsequently, slides were treated with anti-mouse IgG antibody (Vectastain<sup>®</sup> Kit, Vector Laboratories, Inc., Burlingame, CA) for 30 min and incubated with the streptavidin-peroxidase complex (Vectastain<sup>®</sup> Kit, Vector Laboratories, Inc., Burlingame, CA) for 30 min, both steps at room temperature.

The immunostaining of FGF-2 was carried out by immunohistochemistry according to the Peroxidase-Anti-Peroxidase (PAP) method. Previously, sections were dipped in a solution of 3% hydrogen peroxide for 20 min at room temperature to inhibit endogenous peroxidase activity. After washing in several changes of phosphate buffered saline (PBS), the sections were treated for 20 min with a protein blocking agent, 3% bovine serum albumin in PBS, at room temperature to block non-specific protein binding sites. Then they were incubated at 4 °C overnight with the polyclonal rabbit anti-FGF-2 antibody (Oncogene<sup>™</sup> Research Products) at dilution 1:20 in PBS. After rinsing in several changes of PBS, the sections were transferred for 30 min to anti-rabbit IgG antibody (Calbiochem<sup>®</sup>) diluted to 1:100 in PBS at room temperature, rinsed in PBS and then were incubated with rabbit PAP complex in the same conditions.

The enzymatic activities were developed with 3,3'-diaminobenzidine (DAB) and the sections were counterstained with haematoxylin. Negative control sections were treated in the same way omitting the primary antibody.

Results were classified as negative, few, intermediate and high number of cells stained and converted by a semi-quantitative scale into 0-3 arbitrary units. Two investigators examined the scores independently. In case of disagreement, a third investigator also examined it. The final outcome was expressed as percentage with respect to the control group.

### Determination of angiogenesis in the granulation tissue

The number of microvessels within chronic ulcer, as an indicator of angiogenesis, was assessed by immunohistochemical analysis for von Willebrand factor (Weidner et al., 1991). The sections were digested with 0.1% trypsin (Difco laboratories, Detroit, MI) in distilled water for 20 min at 37 °C. After inhibition of endogenous peroxidase activity and non-specific protein binding sites, the sections were incubated with the primary antibody, polyclonal rabbit anti-human Factor VIII-Related Antigen (DAKO Corporation, USA) for 1 hour at room temperature and the Streptavidin-Biotin-Peroxidase method was used.

Individual microvessel counts were made. Any positive cells or cell clusters that clearly were separate from adjacent microvessels and other connective tissue elements were considered single, countable microvessels. Occasional immunopositive leukocytes were excluded on morphologic grounds. The vascular

areas immediately adjacent to the normal tissue of the stomach were not considered in the vessel counts. However, these microvessels did serve as internal quality controls for Factor VIII-RA immunostaining. In all of the samples, the number of microvessels identified from five microscopic fields in the ulcer base was averaged.

#### *Immunohistochemistry for proliferating cell nuclear antigen (PCNA) and apoptosis study*

Mucosal cell proliferation was measured by immunostaining for PCNA. Tissue was stained with an anti-PCNA, which recognizes a nuclear antigen expressed in all stages of the cell cycle. The basic methodology used was the same as for VEGF. The buffer used in the pressure-cooking antigen retrieval system was citrate buffer (pH 6.0). Monoclonal mouse anti-PCNA (DAKO) at dilution 1:1000 in PBS and anti-mouse IgG antibody (Vectastain<sup>®</sup> Kit, Vector Laboratories, Inc., Burlingame, CA) were used as primary and secondary antibody.

For each ulcer, the PCNA-positive cells in the ulcer margin and in the granulation tissue were counted as defined by Yamada et al. (1992). The PCNA labelling index (LI) was determined by calculating the ratio of the number of positive cells to the total number of cells. A cell was deemed to be positive only if it showed positive nuclear staining. Three observers made the evaluations independently.

Cytoplasmic DNA fragments, which are an indicator of apoptosis, were measured with a DNA cell death detection enzyme-linked immuno-sorbent assay (ELISA) PLUS KIT (Roche Diagnostics). The assay is based on a quantitative sandwich-enzyme-immunoassay-principle using mouse monoclonal antibodies directed against DNA and histones, respectively. This allows the specific determination of mono- and oligonucleosomes in the cytoplasmic fraction of cell lysates. The values are expressed as mU/g tissue (mU=absorbance  $[10^{-3}]$ ).

#### *Statistical analysis*

The results are expressed as mean  $\pm$  SEM. Statistical comparisons were evaluated by one-way analysis of variance (ANOVA test) followed by Bonferoni test. Statistical analysis was performed using GraphPad Prism 2.01. Values of probability  $p < 0.05$  were considered significant.

## **Results**

#### *Effect of L-Arginine on the healing of the chronic gastric ulcer*

Figure 1A shows the percentage of damage versus control group at 7 or 14 days of the different treatments in the acetic acid model followed.

Well-defined ulcers were developed in the corpus

mucosa 7 and 14 days after application of acetic acid. In the Ibuprofen group the healing of the gastric ulcers was impaired, especially at 14 days, which was significant with respect to the control group ( $p < 0.01$ ). On the contrary, L-Arg administration at the same time as that Ibuprofen resulted in an important reduction of ulcer index calculated at 7 days ( $p < 0.05$  vs. control). On day 14, the presence of the amino acid reduced the gross appearances of acetic acid ulcers observed with the Ibuprofen group ( $p < 0.05$ ), and the result was closer to control-14 days group.

The histological study was carried out at 14 days because this is time enough to observe a significant recuperation of the lesions. In this time, some epithelial cells in the ulcer margin further proliferate and migrate over and into the ulcer crater, which was strongly infiltrated by inflammatory cells, fibroblasts and endothelial cells. Necrotic tissue was also present at this stage, whereas the gastric mucosa around the ulcer crater remained unchanged (Fig. 1B). The *muscularis mucosae* around the ulcer margin was replaced by a granulation tissue. An interesting increase of the thickness of the granulation tissue of the ulcer bed with abundant density of new vessels developing in this area, but also in the submucosa adjacent to the ulcer crater, were strongly detected after treatment with L-Arg (Fig. 1C).

#### *Effect of L-Arginine on cyclooxygenase expression and release of prostaglandins in the evolution of lesions*

We examined the expression of COX-1 and COX-2 protein in gastric tissues by the western-blotting method. No variations in COX-1 expression were observed in samples obtained from sham, ulcerated and non-ulcerated gastric mucosa without or with treatment (data not shown). However, COX-2 protein expression was increased and detectable at 7 days in the ulcer area (Fig. 2) ( $p < 0.05$  vs. sham and non ulcerated area of control groups), although this production was disappearing on time and on day 14 no significant protein expressions were found in any group assayed (data not shown). The treatment with Ibuprofen increased this expression in the samples from ulcerated area and detected in the 7-days period ( $p < 0.01$  vs. ulcerated control group). The signal of COX-2 expression analysed after L-Arg/Ibuprofen administration was significantly less than that from Ibuprofen group ( $p < 0.05$ ).

PGE<sub>2</sub> levels in control and treated groups of both periods (7 and 14 days) and measured in tissue from ulcerated areas and also from areas not damaged are shown in figure 3A and B. At day 7, PGE<sub>2</sub> control group production augmented significantly in tissues proceeding from ulcerated areas ( $p < 0.001$ ). Ulcer samples from animals administrated with L-Arg, Ibuprofen and Ibuprofen/L-Arg treatments showed significant reduction of PGE<sub>2</sub> content ( $p < 0.001$ ) (Fig. 3A). At the 14 day period, PGE<sub>2</sub> production also was augmented in the ulcerated area of the control group ( $p < 0.01$ ) (Fig. 3B). However, only after Ibuprofen treatment the

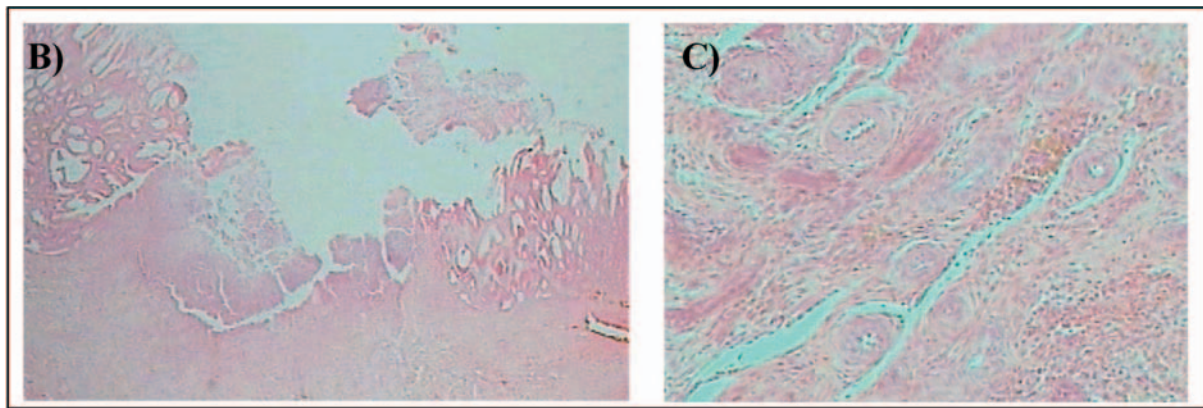
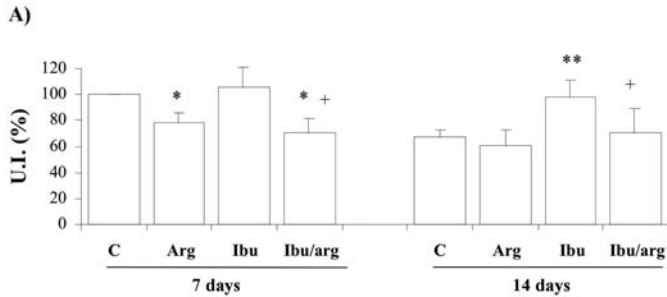


Role of L-arginine in healing gastric ulcers

prostanoid production was significantly inhibited as demonstrated by the results of samples from ulcerated ( $p < 0.05$ ); The presence of L-Arg limited this inhibition, and the  $PGE_2$  levels were close to that observed in the control group (Fig. 3B).

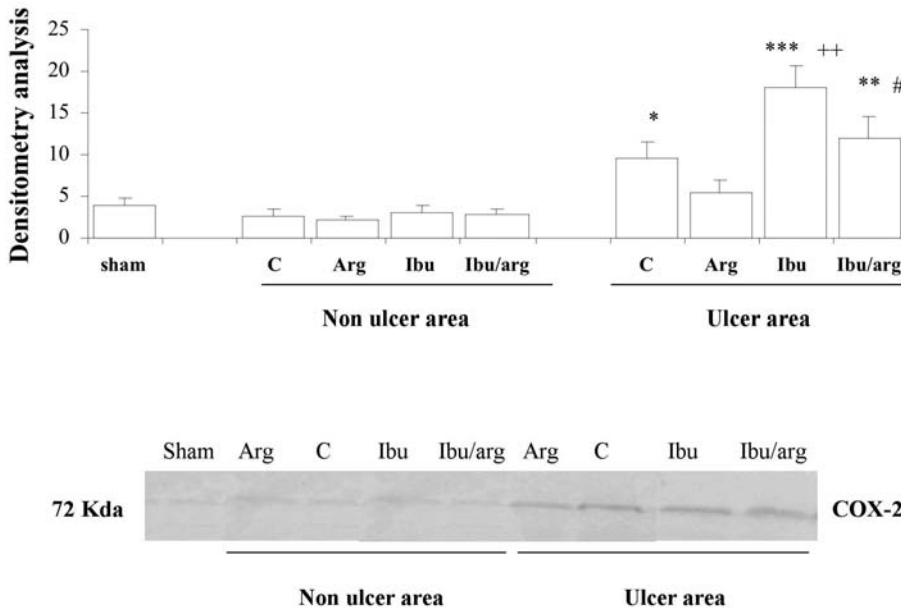
Effect of L-arginine on VEGF and FGF-2 expression and angiogenesis in chronic gastric ulcers

The final outcome of the healing process is a



**Fig. 1.** Effect of amino acid L-Arginine on healing of chronic gastric acetic ulcer. Gastric ulcers were caused by 50  $\mu$ l of 20% acetic acid. Every day the animals were treated with vehicle

(control group), L-Arginine (Arg, 100mg/kg body wt), Ibuprofen (Ibu, 100mg/kg body wt), or L-Arginine with Ibuprofen (Ibu/arg, each of them 100mg/kg body wt), in a unique dose. In sham animals, the abdomen was opened and closed without injection. After 7 and 14 days the animals were killed and the degree of severity of the lesions was expressed as percentage of the control group (A). Values are mean  $\pm$  SEM of 14-16 rats per group. \*  $p < 0.05$  and \*\*  $p < 0.01$  vs. control group; +  $p < 0.05$  vs. Ibuprofen group. The histological study showed a significant recuperation of the lesions. Epithelial cells in the ulcer margin further proliferate and migrate over and into the ulcer crater, which were strongly infiltrated by inflammatory cells, fibroblasts and endothelial cells. Necrotic tissue was also present at this stage, whereas the gastric mucosa around the ulcer crater remained unchanged (B). New vessels developing in granulation tissue were strongly detected after treatment with L-Arginine (C).



**Fig. 2.** Effects of amino acid L-Arginine on COX-2 protein expression in acetic acid gastric ulcer after 7 days of ulcer induction. Gastric ulcers were induced by 50  $\mu$ l of 20% acetic acid. Every day the animals were treated with vehicle (control group), L-Arginine (Arg, 100 mg/kg body wt), Ibuprofen (Ibu, 100 mg/kg body wt), or L-Arginine with Ibuprofen (Ibu/arg, each of them 100 mg/kg body wt), in a unique dose. In sham animals, the abdomen was opened and closed without injection. Tissue from ulcer and non ulcerated area of animals of each group were obtained for western blot analysis. Samples were separated on acrylamide by sodium dodecyl sulfate-polyacrylamide gel electrophoresis, transferred to a nitrocellulose membrane and probed first with anti-COX-2 antibody. A representative blot and the results of densitometry analysis 4 rats per group (expressed in arbitrary units) are shown. Data are expressed as the mean  $\pm$  SEM of number of animals. \*  $p < 0.05$  \*\*  $p < 0.01$  and \*\*\*  $p < 0.001$  vs. sham and non ulcerated control group; ++  $p < 0.01$  vs. ulcerated control group; #  $p < 0.05$  vs Ibuprofen group.

dynamic interaction between the epithelial component from the healing zone at the ulcer margin and the connective tissue component (including microvessels), originating from granulation tissue, with special regulation by FGF-2 and VEGF (Tarnawski et al., 2001). Immunohistochemical studies revealed that VEGF protein, specially expressed in the granulation tissue of control rats and observed in granulocytes, fibroblasts, and smooth muscle, was not modified between the different groups of animals treated (Figs. 4, 5).

The immunoreactivity for FGF-2, detected in regenerative areas of the ulcer margin and in the granulation tissue of the ulcer bed, was also markedly increased. This protein was located in most of the typical fibroblasty cells, granulocytes and smooth muscle cells in the ulcer crater, granulation tissue, and in the stromal cells in the lamina propria on the ulcer margin. This immunopositivity for FGF-2 was especially significant in groups that received L-Arg ( $p < 0.001$ ) (Figs. 4, 5).

Endothelial cells were stained with FVIII antibody in order to detect the growth of new blood vessels. Their

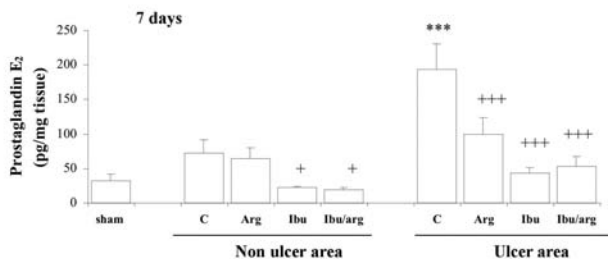
density was higher at the granulation tissue from animals treated with L-Arg (Fig. 6). The Ibuprofen group at the time analysed did not modify the number of microvessels with respect to control group.

#### Effect of L-Arginine on proliferation and apoptosis in chronic gastric ulcers

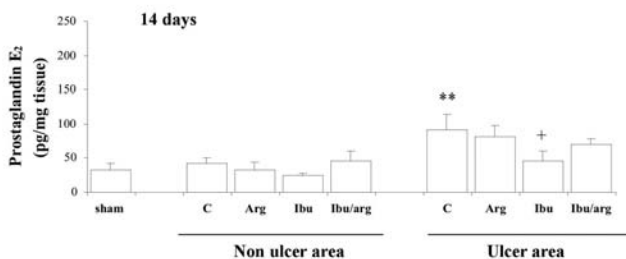
To investigate the effect of L-Arg on proliferation in chronic gastric ulcers, this cell process was quantified by immunostaining. The immunoreaction for PCNA was observed as a dark accumulation of DAB reaction products in the nuclei of the middle and lower parts of the cript in the normal gastric mucosa. In the control ulcerated group, PCNA-positive were augmented respect to sham and distributed in epithelial cells of the ulcer margin and in fibroblastic cells of granulation tissue. Neither treatment modified significantly this parameter with respect to the control group (Fig. 7).

Because gastric mucosal inflammations contribute to cell turnover, we investigated whether apoptosis is altered by chronic gastric ulcers and how these apoptotic effects are affected by L-Arg. In table 1 it can be observed that the apoptotic effect is augmented after acetic acid application and none of the assayed treatment modified it.

A)



B)

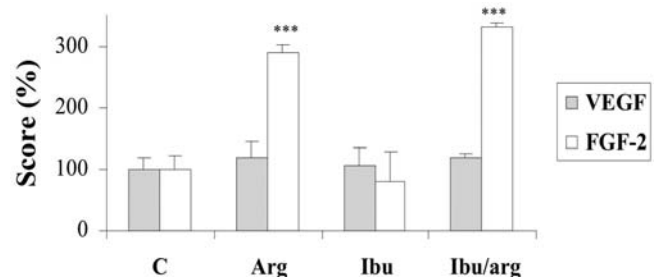


**Fig. 3.** Effects of amino acid L-Arginine on PGE<sub>2</sub> accumulation in chronic gastric ulcers after 7 days (A) and 14 days (B). Gastric ulcers were induced by 50  $\mu$ l of 20% acetic acid. Every day the animals were treated with vehicle (control group), L-Arginine (Arg, 100 mg/kg body wt), Ibuprofen (Ibu, 100 mg/kg body wt), or L-Arginine with Ibuprofen (Ibu/arg, each of them 100 mg/kg body wt), in a unique dose. In sham animals, the abdomen was opened and closed without injection. Tissue from ulcer and non ulcerated area of animals of each group were obtained. PGE<sub>2</sub> level was determined by a competitive enzyme immunoassay kit. Values are mean  $\pm$  SEM of 10 rats. \*\*  $p < 0.01$  and \*\*\*  $p < 0.001$  vs. sham and non ulcerated control group; +  $p < 0.05$  and +++  $p < 0.001$  vs. control group in the same area.

## Discussion

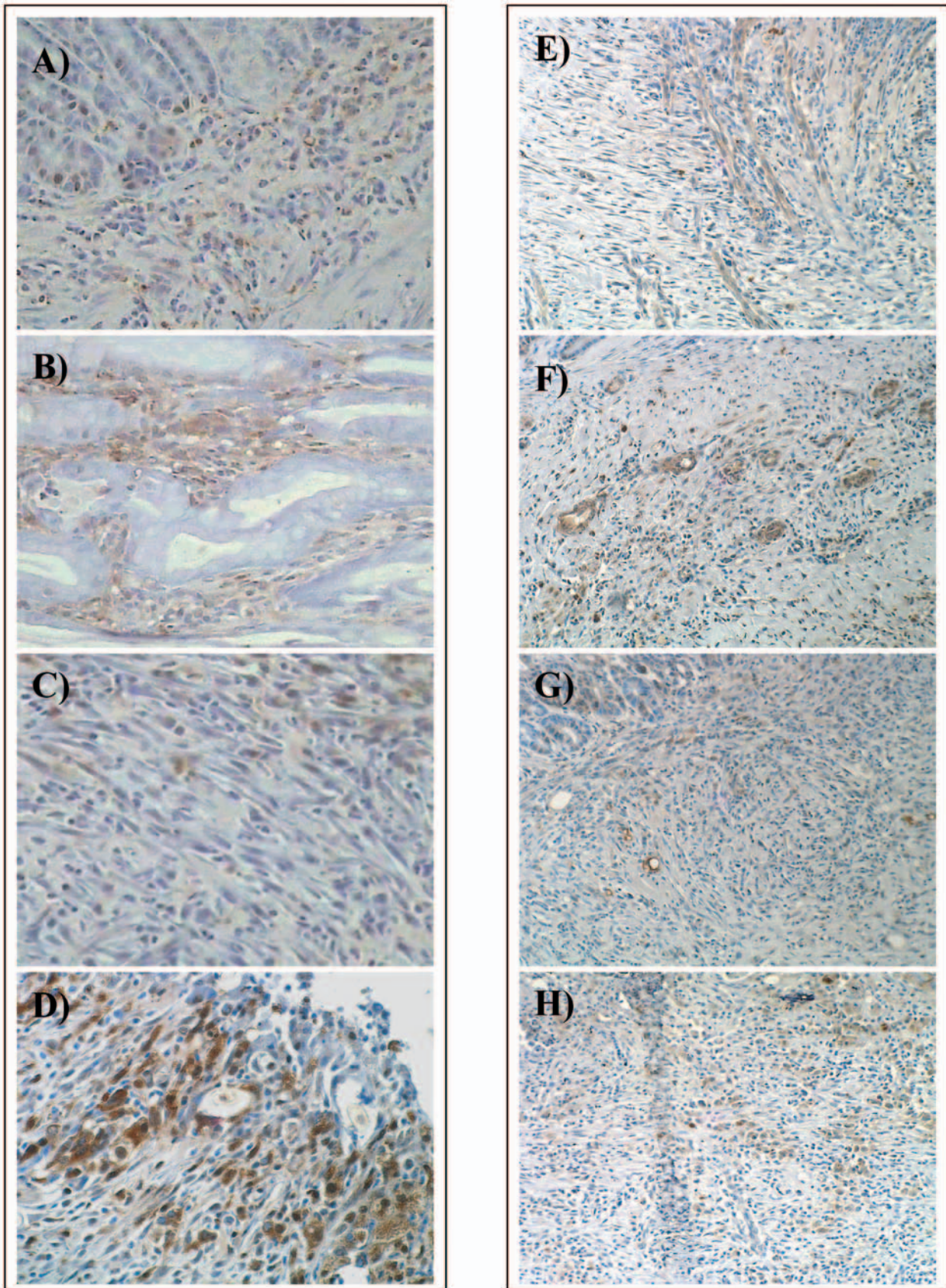
In this study, we examined the role of the amino acid L-Arg in the evolution of the healing process of a chronic gastric ulcer induced by acetic acid and in presence of equal doses of ibuprofen, a classical NSAID COX-1 and COX-2 inhibitor.

Inhibition of COX-1, and the consecutive reduction of PGs and tromboxanes (TX), explained the pharmacological activity of NSAID, but also the side



**Fig. 4.** Effect of amino acid L-Arginine on basic fibroblast growth factor (FGF-2) and vascular endothelial growth factor (VEGF) expression in chronic gastric ulcer after 14 days. The immunostainings for FGF-2 and VEGF were carried out by immunohistochemistry according to the Peroxidase-Anti-Peroxidase (PAP) and Streptavidin-Biotin-Peroxidase method, respectively. The immunostaining was converted by a semiquantitative scale into 0-3 arbitrary units. Data are expressed as the mean  $\pm$  SEM of number of animals. \*\*\*  $P < 0.001$  vs control and Ibuprofen group.

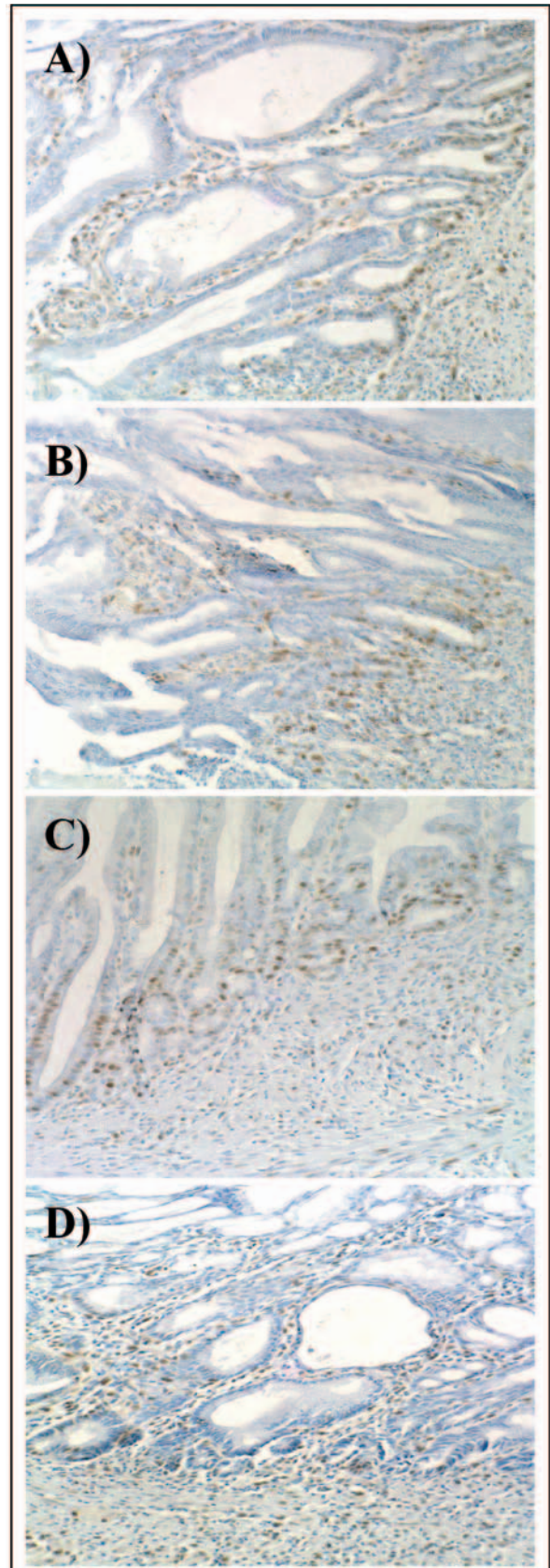
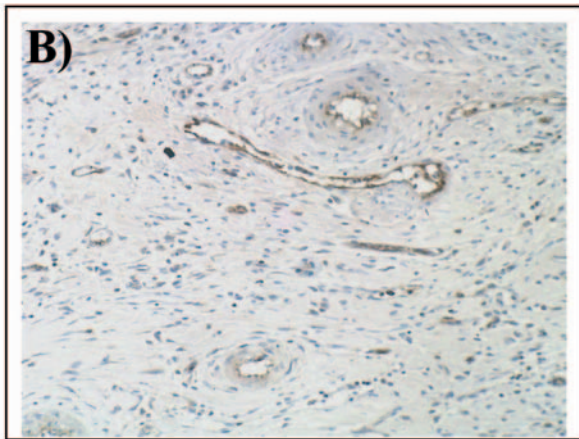
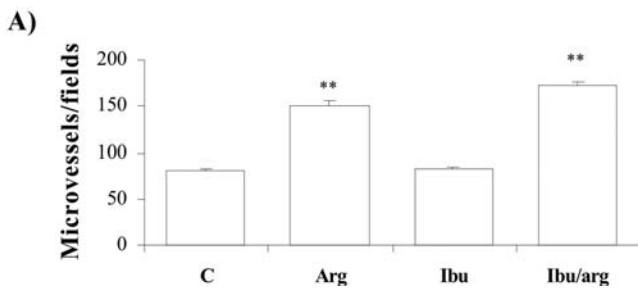




**Fig. 5.** Effect of amino acid L-Arginine on the immunohistochemical staining of basic fibroblast growth factor (FGF-2) and vascular endothelial growth factor (VEGF) expression in chronic gastric ulcer after 14 days. The immunostainings for FGF-2 and VEGF were carried out by immunohistochemistry according to the Peroxidase-Anti-Peroxidase (PAP) and Streptavidin-Biotin-Peroxidase method, respectively. FGF-2 expression in control group (A), in L-Arginine group (B), in Ibuprofen group (C) and L-Arginine with Ibuprofen group (D). VEGF expression in control group (E), in L-Arginine group (F), in Ibuprofen group (G) and L-Arginine with Ibuprofen group (H). Original magnification x 400 and x 200, respectively.



effects associated and especially gastrointestinal ulceration. The discovery of a new isoform, the COX-2, amplified the hypothesis: the constitutive expressed COX-1 is the housekeeping enzyme responsible for physiological activities of PG, while COX-2, whose expression is induced under inflammatory conditions, is responsible for pathological PGs (Crofford, 1997). However, after clinical use, the COX-2 hypothesis turned out to be more complicated than initially thought. Both enzymes have physiological and pathological roles, and COX-2 inhibitors, which improved safety profile in



**Fig. 6.** Effect of amino acid L-Arginine on angiogenesis in chronic gastric ulcers after 14 days. The microvessels were identified by an immunohistochemical method for von Willebrand factor according to the Streptavidin-Biotin-Peroxidase method. The number of microvessels was obtained from five microscopic fields in the ulcer base at x 200 and magnification was averaged (A). Von Willebrand factor expression in L-Arginine with Ibuprofen group (B). Data are expressed as the mean ± SEM of number of animals. \*\* P<0.01 vs control group.

**Fig. 7.** Effects of L-Arginine on Proliferating Cell Nuclear Antigen (PCNA) in chronic gastric ulcers after 14 days. The PCNA-positive cells were identified by immunohistochemistry according to the Streptavidin-Biotin-Peroxidase method. Immunoreactions for PCNA were observed as a dark accumulation of DAB reaction products in the nuclei of cells in ulcer margin and granulation tissue. PCNA expression in control group (A), in L-Arginine group (B), in Ibuprofen group (C) and L-Arginine with Ibuprofen group (D). Original magnification x 200



## Role of L-arginine in healing gastric ulcers

healthy gastrointestinal mucosa, worsen and complicate pre-existing ulcers, and may induce cardiovascular or renal side-effects (Bombardier et al., 2000; Brzozowski et al., 2001a; Berenguer et al., 2002; Sánchez-Fidalgo et al., 2004).

An alternative approach aimed at obtaining safer NSAID is based on the gastroprotective effects of NO. In the stomach, NO plays many important roles including regulation of microcirculation, gastric motility, or mucus and acid secretion (Fisorucci and del Soldato, 2003; Coruzzi et al., 2004; Wallace et al., 2004). Classical NSAID chemically linked to NO-releasing moieties retain the therapeutic efficacy, but not the adverse effects of the parent NSAIDs. On the other hand, NO-NSAID are a highly promising novel class of drugs that may impact several areas of therapeutics and data from different studies indicate that NO-NSAID could be effective in a variety of diseases (del Soldato et al., 1999; Keble and Moore, 2002; Yeh et al., 2004).

L-Arg is a basic amino acid that plays several pivotal roles in cellular physiology. Like any amino acid, it is involved with protein synthesis, but it is also intimately involved with cell signalling through the production of NO. L-Arg has demonstrated its regulative capacity of inflammatory responses by precursor for production of the NO but also for pro-proliferative polyamines (Satriano, 2003).

The results from the present study reveal that L-Arg is favourable in the healing process improving the curative course. Ibuprofen alone caused a delay in ulcer healing, more evident 14 days after ulcer induction; The expression of COX-2 was increased on the 7<sup>th</sup> day although no signal of protein could be detected after 14 days; PGE<sub>2</sub> production was inhibited by the NSAID in intact areas of mucosa as well as in tissue from the ulcerated areas at both times assayed. In contrast, treatment with L-Arg reduced the delay of the lesion, the increment in COX-2 expression induced by Ibuprofen was attenuated, and samples taken after 14 days of ulcer induction showed that L-Arg was able to maintain PGE<sub>2</sub> levels similar to the control group.

Early work showed that L-Arg exerts a protective role in different acute models of experimental gastric damage such as stress, ethanol, or pylorus ligation (Dixit et al., 1999; Nishida et al., 1999; Kalia et al., 2000; Szlachcic et al., 2001; Ohta and Nishida, 2002) and also in chronic gastric studies (Brzozowski et al., 1997). The information obtained concerned NO produced by L-Arg in the vasodilatation and enhancement in mucosal barrier activity (Byrne et al., 1997; Calatayud et al., 1999) although endogenous PGs have also been implicated (Brzozowski et al., 1993; Jiménez et al., 2002). In this line, our group have observed that the mechanism of the protective effect of L-Arg could be explained in different forms although the COX/PG pathway and the NO liberated by a NOS/cGMP pathway were decisive (Jimenez et al., 2002). The present study confirms the favourable effect of L-Arg in the regulation of COX activity, not on its expression, increasing the levels of

PGE<sub>2</sub> up to 14 days after ulcer induction with Ibuprofen presence. The connection between NOS and COX ways may be considered, although contradictory results have been reported (Paya et al., 1997; Brock et al., 2003; Uno et al., 2004). Chemical reactivity of NO would affect both conformation and activity of the COX enzyme; an attack to the COX enzyme directly through the coordination to heme-iron in the prosthetic group of the enzyme, or the reaction with tyrosyl radical located in the active site (Gunther et al., 1997; Salvemini, 1997) although the influences to supply COX substrate have been also proposed (Ma et al., 1996).

Additionally, the histological study showed that the healing effects of L-Arg might be associated with an increased angiogenesis and an augmented expression of the FGF-2. These actions could be considered key factors in the healing response associated with L-Arg administration. However, the proliferation study assayed with the PCNA-immunostaining method did not reveal significant differences, neither did the apoptosis analysis.

Growth factors regulate cell proliferation and also mediate processes such as extracellular matrix formation, cell migration and differentiation, immune regulation, and tissue remodelling (Menard, 2004). In the digestive mucosa, different factors, such as EGF, PDGF, FGF-2, or VEGF, have demonstrated their capacity to accelerate the healing process through the stimulation of angiogenesis, cell proliferation and migration of gastric mucosal cells during the ulcer healing process (Szabo and Vincze, 2000; Tarnawski et al., 2001).

Our results from the immunohistochemical study showed that L-Arg markedly increased the FGF-2 expression and also the angiogenic process in areas of active damage and restoration. These changes were also regulated even in the presence of Ibuprofen. Nevertheless, no variations could be observed in the VEGF expression at this time. These responses are in line with previous studies where the angiogenesis promoted by L-Arg changed in parallel with nitric oxide synthase expression and activity (Brzozowski et al., 1997; Ma and Wallace, 2000). The acceleration of ulcer healing is through mucosal nitric oxide and FGF-2-associated integrated pathways and followed by an increase of angiogenesis and mucosal regeneration (Li and Cho, 1999). However, other explanations must be analysed and based on arginine metabolism. Satriano (2003) proposes that arginine is the precursor for production of NO and the pro-proliferative polyamines, the NO being a key factor in the early phase response, whereas the increased generation of polyamines is requisite for the later repair phase response. The possibility of a third pathway is analyzed where the metabolism of arginine to agmatine by a decarboxylase may have the potential to serve as coordination of the early or later repair pathways in inflammation. Obviously, further studies are necessary for a better understanding of the exact role played by L-Arg in this

process.

In conclusion, the coupling of L-Arg to Ibuprofen is an attractive alternative to Ibuprofen administration alone because it not only attenuates but also improves the evolution of chronic lesions through mechanisms that implicate endogenous PG and FGF-2-associated pathways, which allow an increase of the angiogenic process. These studies support the notion of the potential importance played by the amino-acid in different physiological and pathological processes including inflammation.

---

*Acknowledgements.* This research was funded by grants from Consejería de Educación y Ciencia, Junta de Andalucía, Spain, CTS-259, and also by a grant from Zambón Group, Barcelona, Spain.

---

## References

- Berenguer B., Alarcon de la Lastra C., Moreno F.J. and Martin M.J. (2002). Chronic gastric ulcer healing in rats subjected to selective and non-selective cyclooxygenase-2 inhibitors. *Eur. J. Pharmacol.* 442, 125-135.
- Bombardier C., Laine L., Reicin A., Shapiro D., Burgos-Vargas R., Davis B., Day R., Ferraz M.B., Hawkey C.J., Hochberg M.C., Kvien T.K. and Schnitzer T.J. (2000). Comparison of upper gastrointestinal toxicity of rofecoxib and naproxen in patients with rheumatoid arthritis. VIGOR Study Group. *N. Engl. J. Med.* 343,1520-1528.
- Brock T.G., McNish R.W., Mancuso P., Coffey M.J. and Peters-Golden M. (2003). Prolonged lipopolysaccharide inhibits leukotriene synthesis in peritoneal macrophages: mediation by nitric oxide and prostaglandins. *Prostaglandins Other Lipid. Mediat.* 71, 131-145.
- Brzozowski T., Drozdowicz D., Szlachcic A., Pytko-Polonczyk J., Majka J. and Konturek S.J. (1993). Role of nitric oxide and prostaglandins in gastroprotection induced by capsaicin and papaverine. *Digestion* 54, 24-31.
- Brzozowski T., Konturek S.J., Sliwowski Z., Drozdowicz D., Zaczek M. and Kedra D. (1997). Role of L-Arg, a substrate for nitric oxide-synthase, in gastroprotection and ulcer healing. *J. Gastroenterol.* 32, 442-452.
- Brzozowski T., Konturek P.C., Konturek S.J., Sliwowski Z., Drozdowicz D., Kwiecien S., Pajdo R., Ptak A., Pawlik M. and Hahn E. (2000). Gastroprotective and ulcer healing effects of nitric oxide-releasing non-steroidal anti-inflammatory drugs. *Dig. Liver Dis.* 32, 583-594.
- Brzozowski T., Konturek P.C., Konturek S.J., Sliwowski Z., Pajdo R., Drozdowicz D., Ptak A. and Hahn E.G. (2001a). Classic NSAID and selective cyclooxygenase COX-1 and COX-2 inhibitors in healing of chronic gastric ulcers. *Microsc. Res. Tech.* 53, 343-353.
- Brzozowski T., Kwiecien S., Konturek P.C., Konturek S.J., Mitis-Musiol M., Duda A., Bielanski W. and Hahn E.G. (2001b). Comparison of nitric oxide-releasing NSAID and vitamin C with classic NSAID in healing of chronic gastric ulcers; involvement of reactive oxygen species. *Med. Sci. Monit.* 7, 592-599.
- Byrne C.R., Price K.J., Williams J.M., Brown J.F., Hanson P.J. and Whittle B.J. (1997). Nitric oxide synthase and arginase in cells isolated from the rat gastric mucosa. *Biochim. Biophys. Acta* 1356, 131-139.
- Calatayud S., Sanz M.J., Canet A., Bello R., de Rojas F.D. and Esplugues J.V. (1999). Mechanisms of gastroprotection by transdermal nitroglycerin in the rat. *Br. J. Pharmacol.* 127, 1111-1118.
- Coruzzi G., Menozzi A. and Dobrilla G. (2004). Novel non-steroidal anti-inflammatory drugs: what we have learned from animal studies. *Curr Drug Targets Inflamm. Allergy* 3, 43-61.
- Crofford L.J. (1997). COX-1 and COX-2 tissue expression: implications and predictions. *J. Rheumatol.* 24, 15-19.
- Del Soldato P., Sorrentino R. and Pinto A. (1999). NO-aspirins: a class of new anti-inflammatory and antithrombotic agents. *Trends Pharmacol. Sci.* 20, 319-323.
- Dixit C., Rastogi L. and Dikshit M. (1999). Effect of nitric oxide modulators on pylorus-ligation-induced ulcers in the rat. *Pharmacol. Res.* 39, 33-39.
- Fiorucci S. and Del Soldato P. (2003). NO-aspirin: mechanism of action and gastrointestinal safety. *Dig. Liver Dis.* 35, S9-S19.
- Gunther M.R., Hsi L.C., Curtis J.F., Gierse J.K., Marnett L.J., Eling T.E. and Mason R.P. (1997). Nitric oxide trapping of the tyrosyl radical of prostaglandin H synthase-2 leads to tyrosine iminoxyl radical and nitrotyrosine formation. *J. Biol. Chem.* 272, 17086-17090.
- James M.W. and Hawkey C.J. (2003). Assessment of non-steroidal anti-inflammatory drug (NSAID) damage in the human gastrointestinal tract. *Br. J. Clin. Pharmacol.* 56, 146-155.
- Jimenez D., Martin M.J., Pozo D., Alarcon C., Esteban J., Bruseghini L., Esteras A. and Motilva V. (2002). Mechanisms involved in protection afforded by L-Arginine in ibuprofen-induced gastric damage: role of nitric oxide and prostaglandins. *Dig. Dis. Sci.* 47, 44-53.
- Jimenez D., Martin M.J., Alarcon de la Lastra C., Bruseghini L., Esteras A., Herrerías J.M. and Motilva V. (2004). Role of L-arginine in ibuprofen-induced oxidative stress and neutrophil infiltration in gastric mucosa. *Free Rad. Res.* (in press).
- Kalia N., Bardhan K.D., Reed M.W., Jacob S. and Brown N.J. (2000). L-Arginine protects and exacerbates ethanol-induced rat gastric mucosal injury. *J. Gastroenterol. Hepatol.* 15, 915-924.
- Keeble J.E. and Moore P.K. (2002). Pharmacology and potential therapeutic applications of nitric oxide-releasing non-steroidal anti-inflammatory and related nitric oxide-donating drugs. *Br. J. Pharmacol.* 137, 295-310.
- Konturek P.C., Brzozowski T., Kania J., Konturek S.J. and Hahn E.G. (2003). Nitric oxide-releasing aspirin protects gastric mucosa against ethanol damage in rats with functional ablation of sensory nerves. *Inflamm. Res.* 52, 359-365.
- Li Y. and Cho C.H. (1999). The ulcer healing effect of protamine sulphate in rat stomach. *Aliment. Pharmacol. Ther.* 13, 1351-1362.
- Ma L. and Wallace J.L. (2000). Endothelial nitric oxide synthase modulates gastric ulcer healing in rats. *Am. J. Physiol. Gastrointest. Liver Physiol.* 279, G341-G346.
- Martin M.J., Jimenez M.D. and Motilva V. (2001). New issues about nitric oxide and its effects on the gastrointestinal tract. *Curr. Pharm. Des.* 7, 881-908.
- Menard D. (2004). Functional development of the human gastrointestinal tract: hormone- and growth factor-mediated regulatory mechanisms. *Can. J. Gastroenterol.* 18, 39-44.
- Motilva V., Martin M.J., Luque M.I. and Alarcón de la Lastra C. (1996). Role of polymorphonuclear leukocytes and oxygen-derived free radicals in chronic gastric lesion induced by acetic acid in rat. *Gen. Pharmacol.* 27, 545-550.
- Nishida K., Ohta Y. and Ishiguro I. (1999). Modulation of stress-induced gastric mucosal lesions by exogenous L-arginine. *J. Lab. Clin. Med.* 133, 440-450.



## *Role of L-arginine in healing gastric ulcers*

- Ohta Y. and Nishida K. (2001). Protective effect of L-arginine against stress-induced gastric mucosal lesions in rats and its relation to nitric oxide-mediated inhibition of neutrophil infiltration. *Pharmacol. Res.* 43, 535-541.
- Ohta Y. and Nishida K. (2002). L-arginine protects against stress-induced gastric mucosal lesions by preserving gastric mucus. *Clin. Exp. Pharmacol. Physiol.* 29, 32-38.
- Paya M., Garcia Pastor P., Coloma J. and Alcaraz M.J. (1997). Nitric oxide synthase and cyclo-oxygenase pathways in the inflammatory response induced by zymosan in the rat air pouch. *Br. J. Pharmacol.* 120, 1445-1452.
- Salvemini D. (1997). Regulation of cyclooxygenase enzymes by nitric oxide. *Cell. Mol. Life Sci.* 53, 576-582.
- Sánchez-Fidalgo S., Martín-Lacave I., Illanes M. and Motilva V. (2004). Angiogenesis, cell proliferation and apoptosis in gastric ulcer healing. Effect of a selective COX-2 inhibitor. *Eur. J. Pharmacol.* 505, 187-194.
- Satriano J. (2003). Arginine: at the crossroads of the arginine pathways. *Ann. NY Acad. Sci.* 1009, 34-43.
- Szabo S. and Vincze A. (2000). Growth factors in ulcer healing: lessons from recent studies. *J. Physiol. Paris.* 94, 77-81.
- Szlachcic A., Bilski R., Dziadus-Sokolowska A., Michalski J. and Mroczka J. (2001). The effect of nitric oxide donors and L-Arg on the gastric electrolyte barrier. *J. Physiol. Pharmacol.* 52, 211-220.
- Takeuchi K., Tanaka A., Suzuki K. and Mizoguchi H. (2001). Gastrointestinal sparing anti-inflammatory drugs-effects on ulcerogenic and healing responses. *Curr. Pharm. Des.* 7, 49-69.
- Tarnawski A., Szabo I.L., Husain S.S. and Soreghan B. (2001). Regeneration of gastric mucosa during ulcer healing is triggered by growth factors and signal transduction pathways. *J. Physiol. Paris* 95, 337-344.
- Tomisato W., Tsutsumi S., Hoshino T., Hwang H.J., Mio M., Tsuchiya T. and Mizushima T. (2004). Role of direct cytotoxic effects of NSAIDs in the induction of gastric lesions. *Biochem. Pharmacol.* 67, 575-585.
- Uno K., Iuchi Y., Fujii J., Sugata H., Iijima K., Kato K., Shimosegawa T. and Yoshimura T. (2004). In vivo study on cross talk between inducible nitric-oxide synthase and cyclooxygenase in rat gastric mucosa: effect of cyclooxygenase activity on nitric oxide production. *J. Pharmacol. Exp. Ther.* 309, 995-1002.
- Villegas I., Alarcon de la Lastra C., Martin M.J., Motilva V. and La Casa C. (2002). Gastric damage induced by subchronic administration of preferential cyclooxygenase-1 and cyclooxygenase-2 inhibitors in rats. *Pharmacology* 66, 68-75.
- Wallace J.L., Zamuner S.R., McKnight W., Dickey M., Mencarelli A., del Soldato P. and Fiorucci S. (2004). Aspirin, but not NO-releasing aspirin (NCX-4016), interacts with selective COX-2 inhibitors to aggravate gastric damage and inflammation. *Am. J. Physiol. Gastrointest. Liver Physiol.* 286, G76-G81.
- Weidner N., Semple J.P., Welch W.R. and Folkman, J. (1991). Tumor angiogenesis and metastasis: correlation in invasive breast carcinoma. *N. Engl. J. Med.* 324, 1-8.
- Yamada K., Yoshitake K., Sato M. and Ahnen D.J. (1992). Proliferating cell nuclear antigen expression in normal, preneoplastic, and neoplastic colon epithelium of the rat. *Gastroenterology* 103, 160-167.
- Yeh R.K., Chen J., Williams J.L., Baluch M., Hundley T.R., Rosenbaum R.E., Kalala S., Traganos F., Benardini F., del Soldato P., Kashfi K. and Rigas B. (2004). NO-donating nonsteroidal antiinflammatory drugs (NSAIDs) inhibit colon cancer cell growth more potently than traditional NSAIDs: a general pharmacological property? *Biochem. Pharmacol.* 67, 2197-2205.

Accepted December 2, 2004