

## Long-term Involution of Unilateral Porokeratotic Eccrine Ostial and Dermal Duct Naevus

José Mazuecos<sup>1</sup>, Miguel Ortega<sup>1</sup>, Juan José Ríos<sup>2</sup> and Francisco Camacho<sup>1</sup>

Departments of <sup>1</sup>Medical and Surgical Dermatology and <sup>2</sup>Pathology, Hospital Universitario Virgen Macarena, Avda. Doctor Fedriani s/n. 41009 Sevilla, Spain. E-mail: [camachodp@medynet.com](mailto:camachodp@medynet.com)

Accepted September 16, 2002.

Sir,

Porokeratotic eccrine ostial and dermal duct naevus (PEODDN) is a rare disorder of keratinization with eccrine involvement that histologically presents a cornoid lamella exclusively associated with eccrine ostia and the underlying sweat ducts (1). It is an expression of genetic mosaicism (2) and is characterized by asymptomatic grouped keratotic papules and plaques with a linear distribution, usually located on the acral portion of a limb (3). The lesions are congenital with a tendency to be stable and sometimes progressive.

### CASE REPORT

In February 1977, a 2-year-old girl was evaluated for congenital, linear, erythematous, keratotic lesions on the right half of the body. Physical examination revealed numerous linear keratotic papules and plaques on the right side of the upper back and abdomen, right shoulder, right arm, right palm and volar surface of the fourth and fifth fingers, right thigh and right leg. The morphology of the lesion changed with time, i.e. the more distal, the more verrucous. The lesions were filiform and spinulose on the palm, being most evident in the volar surface of the fourth finger (Fig. 1a). Some scattered keratotic papules were also noted on the right thigh and right leg. A systemic study revealed no skeletal, ocular or neurological abnormalities.

There was neither family history of a similar dermatosis nor other cutaneous or systemic conditions. The histopathological diagnosis from one biopsy of the right palm was compatible with verrucous epidermal naevus. Treatment with 0.05% retinoic acid was suspended by irritation.

In February 2001, at the age of 26, the patient returned to our Department reporting that the lesions on her trunk and limbs had progressively disappeared during her childhood. Only the plaque of the right palm and fingers, with multiple punctate pits with central keratotic plugs resembling comedones, was present (Fig. 1b). The patient did not report subjective symptoms, and sweating was apparently normal. During those years no treatment was prescribed; she had only used topical emollients.

A punch biopsy specimen of the right palm showed a parakeratotic column centred over a dilated acrosyringium. No other epidermal alterations were observed. There was no inflammatory infiltrate in the dermis.

When we reviewed the previous biopsy from 1977, we observed prominent parakeratotic columns arising from epidermal invaginations corresponding to the intraepidermal portion of the eccrine sweat ducts. The underlying granular layer was practically absent. Vacuolated and dyskeratotic cells, surrounding and beneath the cornoid lamella, were seen. A discrete perivascular lymphocytic infiltrate was present in the dermis (Fig. 2a).

Immunohistochemical study was performed on deparaffinized sections of both biopsies using a monoclonal anti-p53 protein antibody (Dako Laboratory, Copenhagen, Denmark). Nuclear immunopositivity stain for p53 was observed in cells beneath the cornoid lamella only in the

first biopsy specimen obtained in 1977 (Fig. 2b), but not in the second biopsy specimen from 2001.

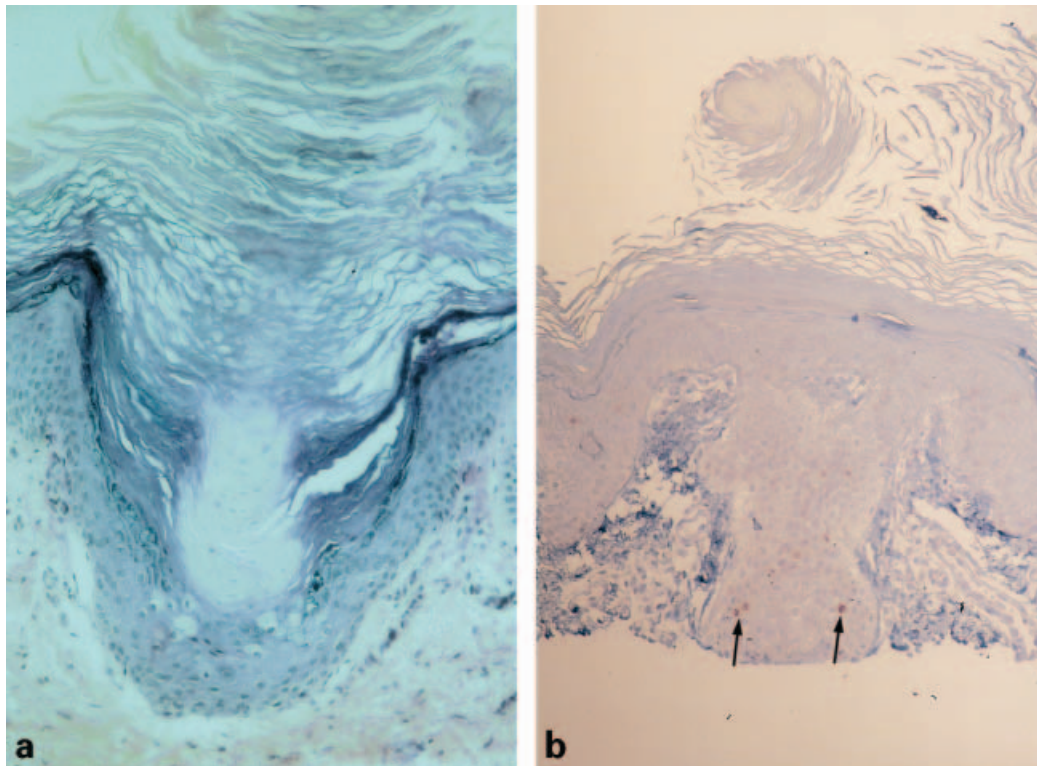
### DISCUSSION

PEODDN is a non-hereditary disorder of the eccrine sweat ducts that clinically presents two types of lesions: multiple punctate pits filled with tiny keratotic plugs resembling comedones, and erythematous keratotic papules and plaques, sometimes with a verrucous aspect. Both distinct clinical lesions can appear at the same time, and similar histopathological findings have been referred in both lesions (4). In our patient, the two clinical images have been observed on the right palm: first, filiform, verrucous, keratotic papules since birth, and subsequently, pits filled with keratotic plugs, probably due to flattening of the previous lesions.

PEODDN reflects genetic mosaicism and is apparently originated from somatic events occurring during

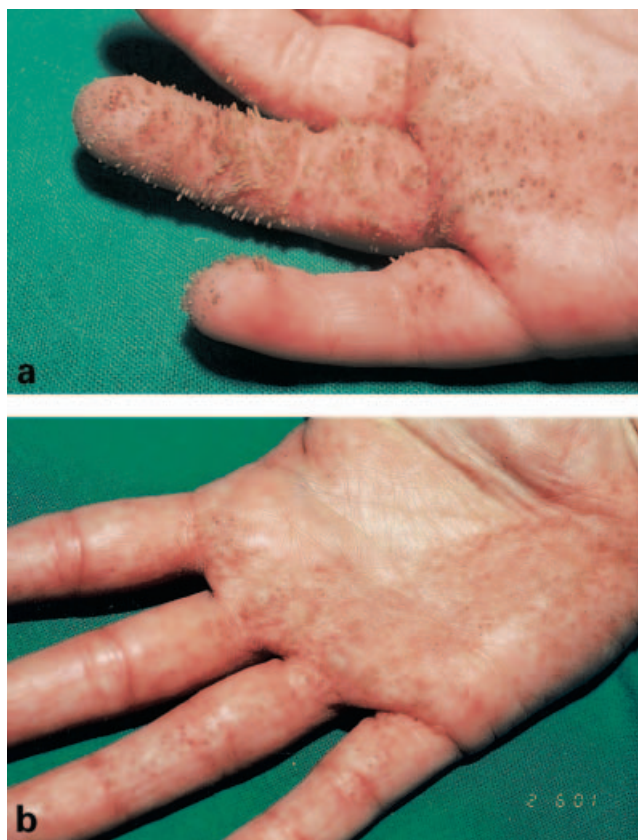

Fig. 1. (a) Numerous verrucous, keratotic papules in linear distribution on the right palm and flexor aspect of the ring and little fingers. (b) Keratotic, comedo-like lesions on the right palm 24 years later.



*Fig. 2.* (a) Parakeratotic column arising over a dilated acrosyringium associated with underlying hypogranulosis and apoptotic keratinocytes. (b) Positive p53 immunostaining confined to keratinocytic nuclei beneath cornoid lamella (arrows).

the embryogenesis (2). The lesions have a linear distribution and predominantly occur on the distal portion of a limb. The most common locations are the palms and soles (3). However, there are also generalized cases, either unilateral and systematized (5, 6) or bilateral and symmetrical (7, 8).

Most cases of PEODDN are present at birth, but there are also late-onset cases (4, 8–10). However, the clinical lesions and distribution are similar in congenital and acquired forms. Pruritus is rarely described (9).

The evolution of PEODDN tends to be stationary, although progressive cases have been reported (5, 8, 11). There is a similar case to the subject of this paper, re-examined 16 years later, where the hyperkeratotic component of the patient's limb lesions had greatly diminished, whereas the palmoplantar lesions remained the same (7). In our patient, the palm and finger lesions had also diminished, but the trunk and limb lesions had thoroughly disappeared during childhood.

It is difficult to explain the significance of our immunohistochemical results, as the p53 staining was positive only in the first biopsy. It is possible that a positive immunostain represents an increase in the synthesis of p53 as a transient protective mechanism in response to DNA impairs. The presence of apoptotic cells beneath the cornoid lamella would sustain this hypothesis. Nevertheless, we cannot demonstrate if the different p53 immunostains from both biopsies are related with the different clinical lesions. p53 overexpression cannot be considered as a p53 gene mutation

(12), and malignant degeneration has not yet been documented in PEODDN.

Good results with CO<sub>2</sub> laser have been obtained in PEODDN, but not with topical keratolytics, topical calcipotriol and cryosurgery (9, 11, 13). Surgical excision is recommended for small lesions. In spite of the fact that this entity tends to persist, the present report illustrates the existence of cases that improve or even disappear with age.

#### REFERENCES

1. Abel E, Read S. Porokeratotic eccrine ostial and dermal duct naevus. *Br J Dermatol* 1980; 103: 435–441.
2. Happle R. What is a nevus? A proposed definition of a common medical term. *Dermatology* 1995; 191: 1–5.
3. Sassmannshausen J, Bogomilsky J, Chaffins M. Porokeratotic eccrine ostial and dermal duct nevus: a case report and review of the literature. *J Am Acad Dermatol* 2000; 43: 364–367.
4. Valks R, Abajo P, Fraga J, Aragues M, Garcia-Diez A. Porokeratotic eccrine ostial and dermal duct nevus of late onset: more frequent than previously suggested? *Dermatology* 1996; 193: 138–140.
5. Bhattacharya SN, Singal A, Bhattacharya G, Singh N. Porokeratotic eccrine ostial and dermal duct nevus as nevus unius lateris in an Indian girl. *J Dermatol* 1998; 25: 682–684.
6. Murata Y, Nogita T, Kawashima M, Hidano A. Unilateral, systematized, porokeratotic eccrine ostial and dermal duct nevi. *J Am Acad Dermatol* 1991; 24: 300–301.

7. Aloï FG, Pippione M. Porokeratotic eccrine ostial and dermal duct nevus. *Arch Dermatol* 1986; 122: 892–895.
8. Cobb MW, Vidmar DA, Dilaimy MS. Porokeratotic eccrine ostial and dermal duct nevus: a case of systematized involvement. *Cutis* 1990; 46: 495–497.
9. Del Pozo J, Martínez W, Vereá MM, Yebra-Pimentel MT, García-Silva J, Fonseca E. Porokeratotic eccrine ostial and dermal duct naevus: treatment with carbon dioxide laser. *Br J Dermatol* 1999; 141: 1144–1145.
10. Stoof T, Starink T, Nieboer C. Porokeratotic eccrine ostial and dermal duct nevus: report of a case of adult
11. Leung CS, Tang WY, Lam WY, Lo KK. Porokeratotic eccrine ostial and dermal duct naevus with dermatomal trunk involvement: literature review and report on the efficacy of laser treatment. *Br J Dermatol* 1998; 138: 684–688.
12. Ninomiya Y, Urano Y, Yoshimoto K, Iwahana H, Sasaki S, Arase S, et al. p53 gene mutation analysis in porokeratosis and porokeratosis-associated squamous cell carcinoma. *J Dermatol Sci* 1997; 14: 173–178.
13. Roustán-Gullón G, Sánchez-Yus E, Simón-Merchan A. Nevo poroqueratósico del ostio y del conducto dérmico