

Treatment of Exudative Age-Related Macular Degeneration with a Designed Ankyrin Repeat Protein that Binds Vascular Endothelial Growth Factor: a Phase I/II Study

ERIC H. SOUIED, FRANÇOIS DEVIN, MARTINE MAUGET-FAÏSSE, PETR KOLÁŘ, UTE WOLF-SCHNURRBUSCH, CARSTEN FRAMME, DAVID GAUCHER, GIUSEPPE QUERQUES, MICHAEL T. STUMPP, AND SEBASTIAN WOLF, FOR THE MP0112 STUDY GROUP

- **PURPOSE:** To evaluate the safety, tolerability and bioactivity of ascending doses of MP0112, a designed ankyrin repeat protein (DARPin) that binds with high affinity to vascular endothelial growth factor-A (VEGF-A), in treatment-naïve patients with exudative age-related macular degeneration (AMD).
- **DESIGN:** Phase I/II, open-label, multicenter, dose-escalation study.
- **METHODS:** Patients were to receive a single intravitreal injection of MP0112 at doses ranging from 0.04 to 3.6 mg and be monitored for 16 weeks for safety, efficacy, pharmacokinetics, and dose response.
- **RESULTS:** Altogether, 32 patients received a single injection of MP0112. The maximum tolerated dose was 1.0 mg because of a case of endophthalmitis in the 2.0 mg cohort. Drug-related adverse events were reported by 13 (41%) of 32 patients; they included ocular inflammation in 11 patients (7 mild, 4 moderate in severity). Visual acuity scores were stable or improved compared with baseline for ≥ 4 weeks following injection; both retinal thickness and fluorescein angiography leakage decreased in a dose-dependent manner. Rescue therapy was administered to 20 (91%) of 22 patients who received 0.04–0.4 mg MP0112 compared with 4 of 10 (40%) patients who received 1.0 or 2.0 mg. Of patients in the higher-dose cohorts who did not require rescue treatment, 83%

(5/6) maintained reductions in central retinal thickness through week 16.

- **CONCLUSIONS:** A single injection of 1.0 or 2.0 mg MP0112 resulted in mean decreases in retinal thickness and leakage area despite ocular inflammation. Larger-scale studies are warranted to confirm these observations. (Am J Ophthalmol 2014;158:724–732. © 2014 The Authors. Published by Elsevier Inc. All rights reserved. This is an open access article under the CC BY-NC-ND license (<http://creativecommons.org/licenses/by-nc-nd/3.0/>).

AGE-RELATED MACULAR DEGENERATION (AMD) IS A leading cause of irreversible central vision loss in people 65 years of age or older.^{1–4} The disease can be subdivided into 2 categories: nonexudative and exudative.⁵ Nonexudative AMD is caused by the loss of photoreceptors through the atrophy of retinal pigment epithelium in advanced stages of the disease. Exudative AMD, also termed neovascular AMD, is caused by proliferation of choroidal neovascularization (CNV), leading to bleeding and loss of photoreceptors through fibrovascular scarring. CNV and related manifestations (subretinal hemorrhage, detachment of the retinal pigment epithelium, and fibrovascular disciform scarring) are the most common causes of severe vision loss resulting from AMD.⁵ Untreated, exudative AMD can lead to progressive and substantial loss of central vision and a reduction in quality of life.

The relationship between vascular endothelial growth factor-A (VEGF-A) and AMD pathogenesis has led to the development of anti-VEGF therapies that inhibit CNV leakage and reduce vessel permeability.⁶ Several VEGF antagonists have been developed, including monoclonal antibodies (ranibizumab and bevacizumab); receptor fragments (aflibercept); and other molecules (pegaptanib, a DNA aptamer).^{7–13} These agents have radically altered the management of neovascular AMD and have become the current standard of care. Anti-VEGF agents are injected directly into the vitreous cavity. Although treatment has evolved from monthly dosing to individualized regimens, the best results are achieved with injections every

Accepted for publication May 27, 2014.

From the Department of Ophthalmology, Hôpital Intercommunal de Créteil, Créteil, France (E.H.S., G.Q.); Centre d'ophtalmologie Monticelli-Paradis, Marseille, France (F.D.); Centre Ophtalmologique Rabelais, Lyon, France (M.M.-F.); Eye Clinic of University Hospital Brno, Masaryk University Brno, Brno, Czech Republic (P.K.); Bern Photographic Reading Center, Inselspital, Bern University Hospital, Bern, Switzerland (U.W.-S.); Department of Ophthalmology, Inselspital, Bern University Hospital, Bern, Switzerland (C.F., S.W.); Service d'ophtalmologie des Hôpitaux Universitaires de Strasbourg, Nouvel Hôpital Civil, Université Louis-Pasteur, Strasbourg, France (D.G.); Molecular Partners, Zurich-Schlieren, Switzerland (M.T.S.).

Dr Framme is now at the University Eye Hospital, Medical School Hannover, Hannover, Germany.

Inquiries to Sebastian Wolf, Department of Ophthalmology, Inselspital, Bern University Hospital, Bern, Switzerland; e-mail: Sebastian.Wolf@insel.ch

4–8 weeks in order to maintain improvement in central vision, placing a considerable burden of treatment on patients, physicians and healthcare systems.^{7,14}

MP0112 is a recombinant protein of the designed ankyrin repeat protein (DARPin) family. DARPins are small, single-domain proteins that can selectively bind to a target protein with high affinity and specificity.¹⁵ These genetically engineered antibody-mimetic proteins show greater stability and at least equal affinity with immunoglobulins, making them effective investigational and therapeutic tools.¹⁶ The *in vitro* and *in vivo* effectiveness has been demonstrated in areas that include preclinical tumor targeting and diagnostics.^{17–22}

In vitro, MP0112 has been shown to act as a highly potent antagonist to all VEGF-A isoforms (KD of 1–4 pM; data on file; Molecular Partners, Zurich-Schlieren, Switzerland). Animal studies have demonstrated the high efficacy of MP0112 to inhibit abnormal neovascularization (data on file, Molecular Partners). In a rabbit model of ocular pharmacokinetics with vascular leakage inhibition as read-out, MP0112 was fully active for at least 30 days, whereas ranibizumab did not show activity after 30 days due to faster clearance (data on file, Molecular Partners). Good laboratory-practice toxicology studies were performed and revealed that inflammation can result from potential toxicity in patients (data on file, Molecular Partners).

The mechanism of action of MP0112 is similar to that of ranibizumab, pegaptanib and aflibercept (ie, inhibition of VEGF-A by binding without receptor interaction via the Fc region), and MP0112 has shown a number of advantages compared with the current standard of care: high potency (ie, IC₅₀ in the low pM range); very long ocular half-life (about 2 weeks)¹⁷; and very low systemic exposure (data on file, Molecular Partners). Compared with ranibizumab, MP0112 has greater binding affinity to VEGF-A and is retained in the vitreous for a substantially longer time.²³ The evidence suggests, therefore, that MP0112 has the potential to reduce the frequency of intravitreal injections. A recent study has demonstrated the potential of DARPins compared with currently available agents in DME.²³ The current study was designed to assess the safety, tolerability and preliminary efficacy of intravitreal injections of MP0112 for the treatment of exudative AMD and was performed in parallel with the DME study.

METHODS

THIS PHASE I/II, OPEN-LABEL, NONCONTROLLED, DOSE-escalation trial was conducted in 8 ophthalmologic centers in France, Switzerland and the Czech Republic. The study and data accumulation were carried out with approval from the following ethics committees: CPP Ile de France III, Kantonale Ethikkommission Bern, Ethics Committee of Central Military Hospital, Ethics Committee of Faculty

Hospital Brno, and Ethics Committee of Faculty Hospital Olomouc. The study adhered to the guidelines of the Declaration of Helsinki, and the protocol and consent forms were approved by a local investigational review board. Each subject provided written consent to participate in this research study. The study is registered at ClinicalTrials.gov under the identifier: NCT01086761.

- **STUDY POPULATION:** Male and female patients 50 years of age or older who had clinical signs and angiographic evidence of active primary progressive subfoveal CNV, including juxtafoveal lesions that affected the fovea on fluorescein angiography (FA) in the study eye and that were at least 50% of the total lesion area, were eligible for enrollment. Patients were also required to meet the Early Treatment Diabetic Retinopathy Study (ETDRS) best-corrected visual acuity (BCVA) of 70 to 25 letters (Snellen equivalent of 20/40 to 20/320) in the study eye at 4 meters.

Patients with any of the following were excluded from the study: any prior treatment for neovascular AMD in the study eye; a total lesion size of >20 mm²; subretinal hemorrhage either ≥50% of the total lesion area or with ≥2.54 mm² blood under the fovea; scar or fibrosis ≥50% of the total lesion in the study eye; or scar, fibrosis or atrophy involving the center of the fovea. Patients with other causes of CNV or ocular surgery (including cataract extraction) in the study eye within 3 months of enrollment were also not eligible to participate.

- **STUDY DESIGN:** The primary study objective was to assess the safety and tolerability of intravitreal doses of MP0112. Secondary objectives were to assess the preliminary efficacy of MP0112 based on changes in BCVA, central retinal thickness (CRT) as measured by optical coherence tomography (OCT), and CNV leakage as measured by FA. Additionally, the systemic pharmacokinetic profile and immunogenicity of intravitreally administered MP0112 were assessed.

The study was designed in 2 stages. Part A consisted of a dose-escalation design in which 6 cohorts received a single MP0112 dose of 0.04 mg, 0.15 mg, 0.4 mg, 1.0 mg, 2.0 mg, or 3.6 mg. Patients were enrolled into the study sequentially. The first patient in each dose cohort received a single intravitreal injection of MP0112 in 1 eye. If no severe or serious ocular adverse event (AE) that was considered to be drug related occurred within 2 weeks of administration, the remaining 5 patients in the dose cohort were recruited and dosed. Dose escalation proceeded only (1) after all patients in a dose cohort had received the specified dose; (2) if moderate ocular toxicity, as defined by the protocol, affected no more than 2 of 6 patients within the dosing cohort after a minimum follow-up of 1 week; and (3) if the Medical Review Committee had approved the dose escalation.

- **STUDY TREATMENTS AND PROCEDURES:** MP0112 was administered as a single intravitreal injection (0.05 mL)

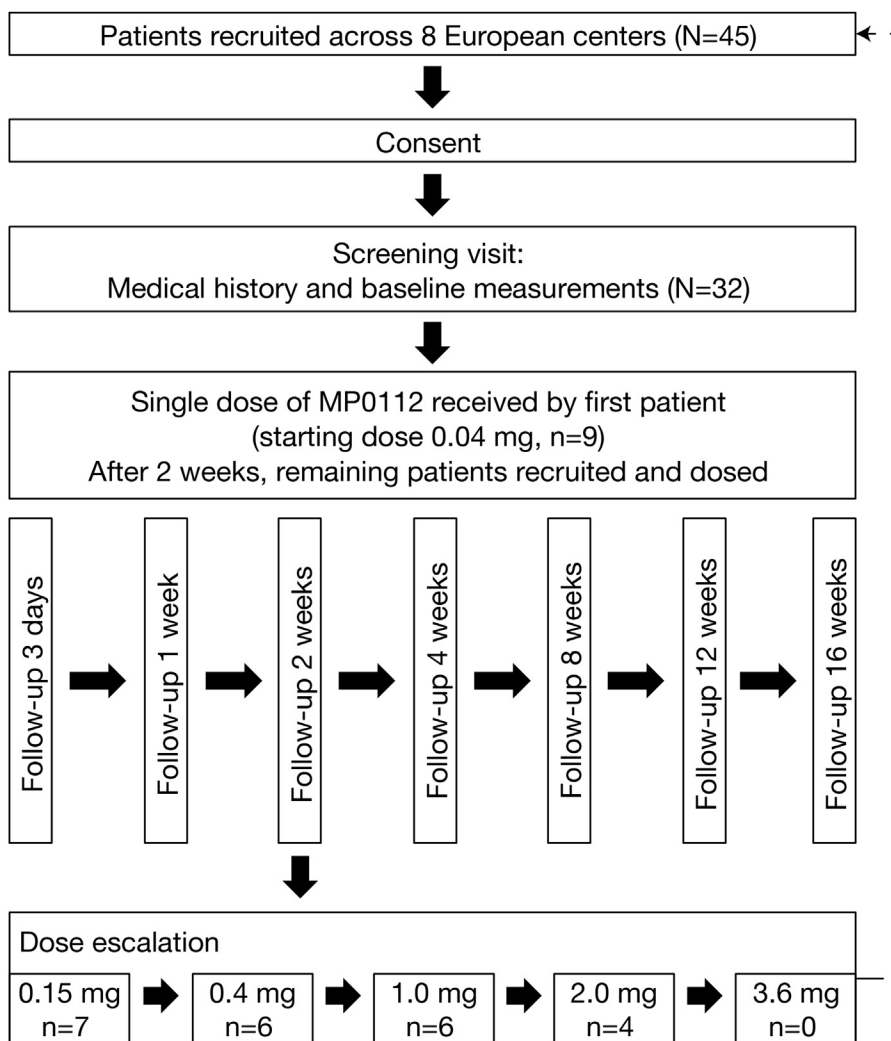


FIGURE 1. Schema of the phase I/II multicenter dose-escalation trial of MP0112 in patients with exudative age-related macular degeneration (AMD) from recruitment to follow-up.

using a 30-gauge needle and standard techniques, including the use of a lid speculum, topical anesthesia and 5% povidone-iodine. All patients remained under observation in the clinic for up to 5 hours after dosing. Patients were examined before and after injection and received a safety follow-up call the day after dosing, with referral to an ophthalmologist if required. Follow-up visits were made 3 days, and 1, 2, 4, 8, 12, and 16 weeks after treatment. At day 3, patients underwent a complete eye exam (including slit-lamp biomicroscopy and indirect ophthalmoscopy) and pharmacokinetic assessment. At each study visit, patients were assessed for AEs, concomitant medications, pharmacokinetics (until week 12), complete eye exams, BCVA and OCT. FA was assessed at baseline and week 4 (Figure 1).

At the investigators' discretion, patients could be given rescue therapy with standard-of-care treatments from 2 weeks after administration of MP0112. The criteria for

initiation of rescue therapy differed slightly by region: in the Czech Republic and France, patients were eligible for rescue therapy if they experienced at least 1 of the following: visual acuity (VA) deterioration of ≥ 6 letters from baseline; an increase in lesion size or leakage; the formation of new lesions; or an increase in subretinal fluid. In Switzerland, rescue therapy applied to patients who experienced VA deterioration of ≥ 6 letters from baseline or a decrease in CRT of $< 50 \mu\text{m}$ from baseline. All patients, including those who received rescue therapy, were followed for 16 weeks.

Optical coherence tomography. OCT was performed at each study site using Stratus OCT 3 (Carl Zeiss Meditec, Jena, Germany) and Spectralis OCT (Heidelberg Engineering, Heidelberg, Germany), if available. The same OCT unit was used for all visits for a given patient so as to allow for comparison among visits. Stratus OCT data

were used for comparison across all sites because Spectralis OCT data were not available for all patients. The central subfield thickness, which is the average thickness within the central 1 mm of the fovea, was used as a measure of CRT for all OCT devices. Scans were acquired using the fast macular scan protocol on Stratus (Carl Zeiss Meditec), which consists of 6-line B-scans (each consisting of 128 A-scans per line), each 6 mm long, centered on the fixation point and spaced 30 degrees apart around a circle. Scans were acquired using the high-speed spectral-domain OCT volume mode on the Heidelberg Spectralis, which consists of 25 horizontal-line B-scans (each consisting of 512 A-scans per line; the line scans were saved for analysis after 9 frames and averaged) covering a total area of 20 × 20 degrees of the macula with a distance of 240 μm between the horizontal lines. OCT images were analyzed and graded by the Central Reading Center (Bern Photographic Reading Center, Bern, Switzerland).

Fluorescein angiography. Digital images at the 30- to 40-degree setting (depending on the device) were taken using the Heidelberg HRA System (Heidelberg Engineering); MRP OphthaVision (MRP Group, Waltham, Massachusetts, USA); Ophthalmic Imaging Systems (OIS) WinStation (Sacramento, California, USA); Topcon IMAGENet (Capelle a/d Ijssel, Netherlands); or Zeiss Visupac digital systems (Carl Zeiss Meditec). The fluorescein angiogram contained stereoscopic views of 2 fields at specified times (up to 10 minutes) after fluorescein injection. These fields included the macula (ETDRS Field 2) of both eyes and the disc field (ETDRS Field 1M) of the study eye. Stereoscopic red-free photographs were taken of ETDRS Field 2 in each eye prior to the injection of the fluorescein dye. FA images were analyzed and graded by the Central Reading Center (Bern Photographic Reading Center).

Statistical analysis. No formal significance or analytic testing was performed due to the small sample size. Continuous variables were summarized using descriptive statistics, and categorical variables were described using counts and percentages.

RESULTS

• **BASELINE PATIENT CHARACTERISTICS:** Of the 45 patients screened, 32 met the inclusion/exclusion criteria and received a single intravitreal injection of MP0112 in the study eye (0.04 mg, 9 patients; 0.15 mg, 7 patients; 0.4 mg, 6 patients; 1.0 mg, 6 patients; 2.0 mg, 4 patients). All 32 patients completed the study. The baseline characteristics of the study population are summarized in [Table 1](#).

TABLE 1. Baseline Characteristics for 32 Patients with Age-Related Macular Degeneration Who Received a Single Intraocular Injection of MP0112 Across 5 Dose Cohorts in the Phase I/II Dose-Escalation Study

MP0112 (n = 32)	
Age (years)	
Mean ± SD	78.3 ± 5.3
Range	65, 87
Gender, n (%)	
Male	11 (34%)
Female	21 (66%)
Ethnicity, n (%)	
Caucasian/white	31 (97%)
Ocular measures	
Classic CNV, n (%) ^a	8 (25%)
Occult CNV, n (%) ^a	29 (91%)
VA score, mean ± SD (range)	58.7 ± 11.6 letters (32–72)
CRT, mean ± SD (range)	351.5 ± 107.8 μm (191–790)

CNV = choroidal neovascularization; CRT = central retinal thickness; SD = standard deviation; VA = visual acuity.
^aOne patient could not be graded, and another patient could not be graded for classic CNV.

TABLE 2. Treatment-Related Ocular Adverse Events in the Study Eye Reported for at Least 2 Patients with Age-Related Macular Degeneration in a Single-Dose Cohort*

	MP0112 Dose Cohort				
	0.04 mg n = 9	0.15 g n = 7	0.4 mg n = 6	1.0 mg n = 6	2.0 mg n = 4
Vitritis	0	1 (14%)	0	2 (33%)	1 (25%)
Anterior chamber inflammation	0	1 (14%)	1 (17%)	2 (33%)	1 (25%)
Anterior chamber cell flare	0	0	1 (17%)	0	2 (50%)

*Patients received a single intraocular injection of MP0112.

• **SAFETY:** AEs that were considered to be drug related were reported in 13 of 32 (41%) patients and included anterior chamber inflammation (5/13 patients); vitritis (4/13 patients); anterior chamber cell flare (3/13 patients); and endophthalmitis (1/13) ([Table 2](#)). Ocular inflammation resolved without consequence in all eyes; in 36% (4/11), this occurred without treatment, and all others received local anti-inflammatory medication (betamethasone, dexamethasone, tropicamide, or dexamethasone-tobramycin).

One serious AE (3%) was reported during the study: a patient who received 2.0 mg MP0112 developed severe ocular inflammation with hypopyon, initially classified as endophthalmitis. The patient received a 2-day course of intravenous vancomycin and ceftriaxone, oral prednisolone,

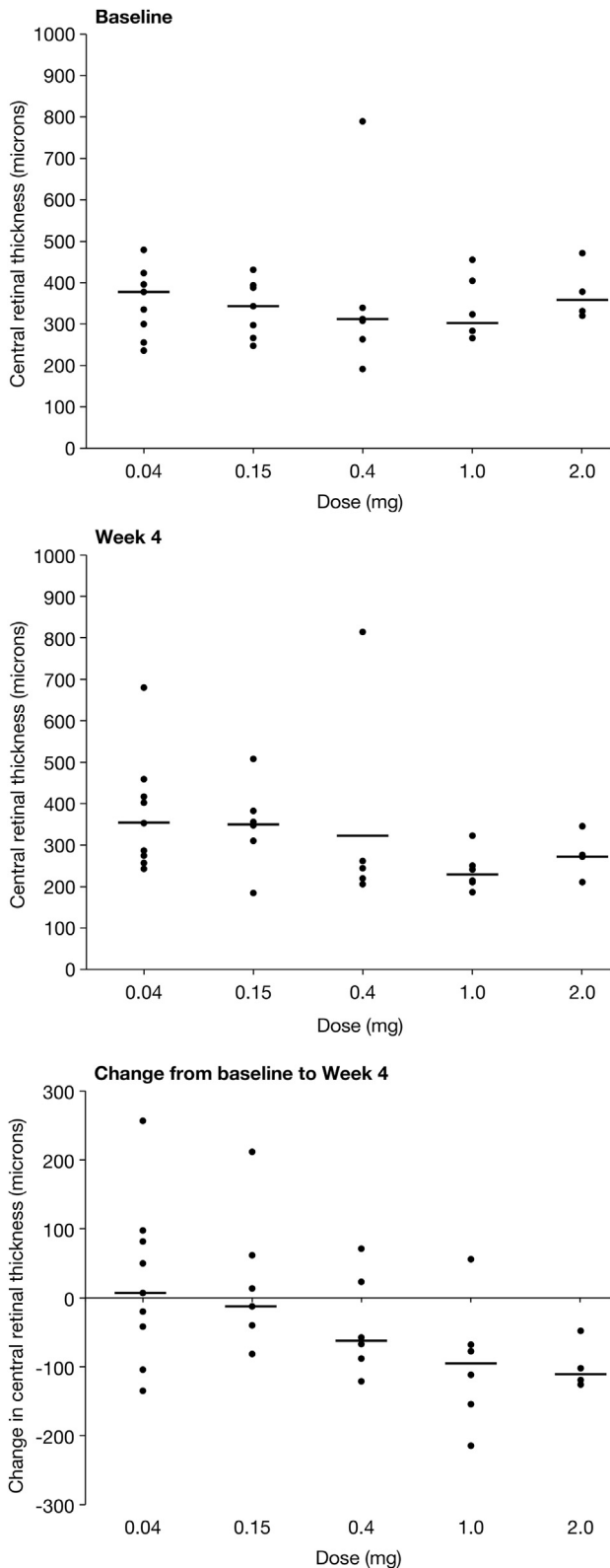


FIGURE 2. Overall change in central retinal thickness (CRT) from baseline to week 4, as measured by optical coherence tomography, after a single injection of MP0112 in 5 study cohorts with age-related macular degeneration (AMD). (Top) Median baseline CRT measured at screening or on day 0, if

and Kefzol eye drops. The hypopyon was completely resolved within 3 days from onset. No Gram staining or cultures were performed, but the mild course and response to steroids suggest that sterile endophthalmitis had occurred. Based on this severe ocular inflammation, the maximum tolerated dose was determined to be 1.0 mg. A second stage of the study that was planned to evaluate repeat doses of MP0112 was not initiated because ocular inflammation was observed and was attributed to impurities in the investigative product.

AEs noted by the investigator to be related to the procedure were reported in 3 of 32 (9%) patients (conjunctival hemorrhage, vitreous detachment and hypertension, each occurring in 1 patient).

Antidrug antibodies were detected in the serum of 8 patients. No further characterization of these was performed.

• **EFFICACY:** *Optical coherence tomography.* The mean and median CRTs at baseline were 352 μm and 334 μm, respectively (standard deviation, 107.8 μm; range, 191–790) (Table 1). Generally, the higher-dose cohorts experienced a greater decrease in CRT during the 4-week study period (Figure 2). Patients who received 1.0 and 2.0 mg of MP0112 showed the greatest median reductions at week 4 of –95 μm and –111 μm, respectively, compared with 7 μm, –12 μm, and –62 μm in patients who received 0.04 mg, 0.15 mg, and 0.4 mg, respectively. The overall change in CRT across the dosing cohorts is shown in Figure 2.

The initial reduction in CRT observed at week 1 was maintained and further reduced at week 4 in the higher-dose cohorts. Patients receiving 1.0 mg showed median reductions in CRT of –51 μm and –95 μm at weeks 1 and 4, respectively. The median reduction at week 1 in patients receiving 2.0 mg was –6.5 μm. This compared with a median reduction of –111 μm at week 4. In contrast, the CRT of lower-dose cohorts increased or stabilized after an initial decline (Figure 2, center). Patients who received 0.04 mg or 0.15 mg MP0112 had median changes of –33 μm and 7 μm (week 1) or –11 μm and –12 μm (week 4), respectively.

available, prior to a single intraocular injection of MP0112 in patients with AMD: 0.04 mg (n = 9); 0.15 mg (n = 7); 0.4 mg (n = 6); 1.0 mg (n = 6); or 2.0 mg (n = 4). The mean baseline CRT of the study eye was 351.5 μm (SD ± 107.8 μm), and all patients had definite macular thickening. (Center) Median CRT measured 4 weeks after injection of MP0112 in patients with AMD across 5 dose cohorts. CRT decreased as early as week 1 and was maintained in patients in the higher-dose cohorts. (Bottom) Median change in CRT from baseline to week 4 for all patients by dose cohort. Patients who received 1.0 or 2.0 mg of MP0112 showed the greatest mean reductions at week 4 (95 μm and 99 μm, respectively), compared with patients from the lower-dose cohorts.

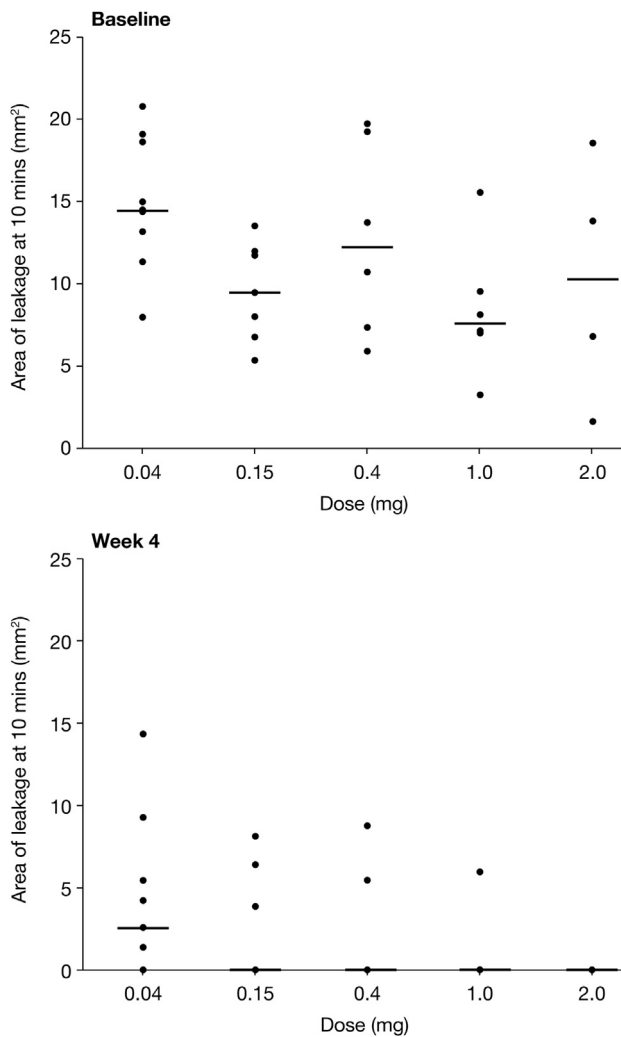


FIGURE 3. Overall change in leakage area from baseline to week 4, as measured by fluorescein angiography, after a single injection of MP0112 in 5 study cohorts with age-related macular degeneration (AMD). (Top) Median baseline leakage area measured 10 minutes after fluorescein injection at screening prior to a single intraocular dose of MP0112 in patients with AMD: 0.04 mg (n = 9); 0.15 mg (n = 7); 0.4 mg (n = 6); 1.0 mg (n = 6); or 2.0 mg (n = 4). Mean baseline leakage area of the study eye was 11.5 mm² (SD ± 5.1 mm²); range, 8.4–15.0 mm² across treatment groups. (Bottom) Median leakage area decreased 4 weeks after administration of MP0112 across all dose cohorts to 0 mm² (range, 0–14.3). Mean area was 2.4 mm (SD ± 3.8). One patient in the 2.0 mg cohort had images that could not be assessed due to poor quality.

Visual acuity. The VA remained stable (defined as loss of <15 letters compared with baseline) and did not vary from baseline in all dosing cohorts across the study period. Up to 100% of patients experienced either no loss in VA or a gain from baseline in letters on the ETDRS charts at each time point (94%, 97%, 94%, 91%, 91%, and 100% of patients at weeks 1, 2, 4, 8, 12, and 16, respectively). Of 32 patients, 4

(12.5%) experienced reversible loss of ≥15 letters secondary to inflammation at various time points.

Fluorescein angiography. At initial screening, FA showed that patients had both mean and median leakage areas of 11.5 mm² (±5.1; range, 1.6–20.8) across dose cohorts. At week 4, the mean and median leakage areas had decreased to 2.4 mm² and 0 mm², respectively (±3.8; range, 0–14.3) (Figure 3). FA also demonstrated a mean decrease in lesion size from 11.1 mm² (median, 10.9 mm²) at baseline to 7.6 mm² (median, 7.3 mm²) at week 4. Dose dependency was observed (Figure 3, bottom).

Rescue therapy. Ranibizumab 0.5 mg (Lucentis; Genentech, San Francisco, California, USA) was administered as rescue therapy between weeks 4 and 16 to 20 of 22 patients (91%) who received 0.04, 0.15, or 0.4 mg of MP0112 and to 4 of 10 patients (40%) who received 1.0 or 2.0 mg MP0112 (Table 3) (Figure 4). The median time to rescue therapy was longer in higher-dose than in lower-dose cohorts (9.6–10.1 vs 5.1–6.9 weeks, respectively) (Table 3) (Figure 4). The majority of patients who were stable on MP0112 treatment maintained reductions in CRT to week 16. OCT did not demonstrate any improved benefit of rescue therapy on CRT in patients from the 1.0 and 2.0 mg MP0112 cohorts.

Pharmacokinetics. Patients who received single intravitreal doses of 0.04, 0.15 or 0.4 mg had no quantifiable serum concentrations of MP0112. All samples in these cohorts were below the lower limit of quantification (LLOQ) of 0.3 nM. Of the patients, 50% (3/6) in the 1.0 mg MP0112 cohort had systemic MP0112 levels above the LLOQ, with maximum levels being reached 3 days post dose (0.3–0.5 nM). After week 1, all patients in this cohort had serum levels below the LLOQ. All patients who received 2.0 mg MP0112 had systemic levels of MP0112 above the LLOQ (0.5–1.0 nM) during days 3–7. Serum levels remained above the LLOQ in half of these patients at week 2. From week 4 onward, all patients in this cohort had serum levels below the LLOQ.

DISCUSSION

THE ASSOCIATION OF VEGF-A WITH AMD PATHOGENESIS has led to the development of anti-VEGF therapy via intraocular injection. Many studies have demonstrated the efficacy of VEGF antagonists in inhibiting CNV leakage, and such therapies have become the current standard of care.^{9–13} Best results are obtained with injections every 4–8 weeks, although the frequency of intraocular injection varies among patients according to individual needs. Therapies providing a longer duration of VEGF

TABLE 3. Summary of Rescue Therapy Administered to Patients with Age-Related Macular Degeneration Who Received a Single Dose of MP0112*

	MP0112 Dose Cohort					
	0.04 mg (n = 9)	0.15 mg (n = 7)	0.4 mg (n = 6)	1.0 mg (n = 6)	2.0 mg (n = 4)	All (N = 32)
Patients receiving rescue therapy, n (%)	8 (89%)	7 (100%)	5 (83%)	2 (33%)	2 (50%)	24 (75%)
Time to first rescue therapy (weeks)						
Mean (SD)	5.4 (1.3)	8.1 (3.0)	6.8 (2.4)	9.6 (8.3)	10.1 (8.5)	7.2 (3.6)
Median	5.1	6.9	5.9	9.6	10.1	5.9
Range	4, 8	4, 12	5, 10	4, 15	4, 16	4, 16

SD = standard deviation.

*Patients were eligible for rescue therapy from 4 weeks after injection of MP0112 at the study investigator's discretion.

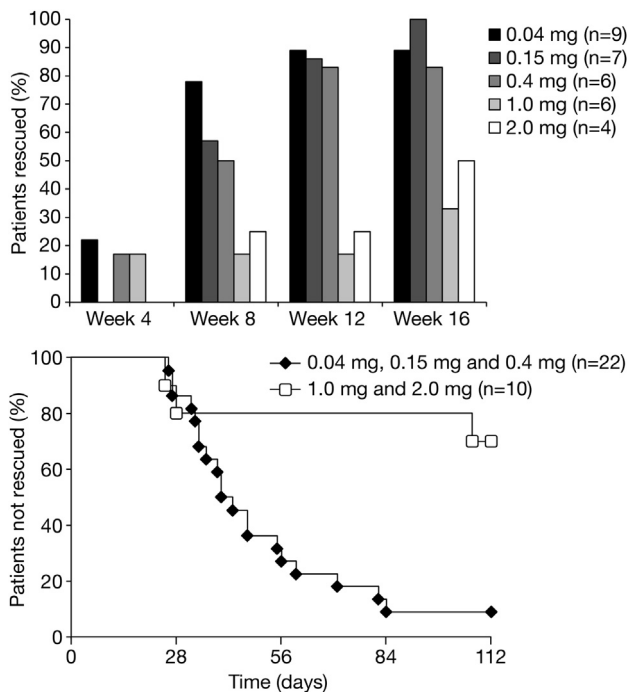


FIGURE 4. Administration of standard-of-care rescue therapy in patients with age-related macular degeneration (AMD) between weeks 4 and 16 after a single intraocular injection of MP0112. (Top) Percentage of patients with AMD who required rescue therapy per protocol differed among dose cohorts. Patients were eligible for rescue therapy 4 weeks after administration of the study drug at the discretion of the investigator. Overall, 75% of patients received rescue therapy between weeks 4 and 16. Between 83% and 100% of patients who received 0.04, 0.15 or 0.4 mg MP0112 were given rescue therapy compared with 33% and 50% of patients who received 1.0 and 2.0 mg MP0112, respectively. (Bottom) Time to rescue therapy in patients with AMD who received 0.04–0.4 mg MP0112 (lower-dose cohorts) compared with those who received 1.0 or 2.0 mg MP0112. The time to rescue therapy was higher in patients who received 1.0 or 2.0 mg MP0112 compared with those in the lower-dose cohorts: 9.6–10.1 vs 5.1–6.9 weeks, respectively.

suppression would reduce the burden of treatment on patients, physicians, and healthcare systems. MP0112 was developed to achieve longer duration of VEGF suppression in the eyes of patients. The results of a single-dose, dose-escalation study of MP0112 in patients with exudative AMD are reported here, showing that promising efficacy and long duration were achieved at the highest doses tested.

The primary objective of this study was to assess the safety and bioactivity of intravitreal injection of MP0112 in patients with exudative AMD. No systemic safety concerns were identified. Ocular inflammation was expected to be the dose-limiting AE, based on observations in rabbits. Similar ocular inflammation was observed in an MP0112 study in patients with DME.²³ An improved purification process has subsequently been developed; it removes proinflammatory impurities, as confirmed by rabbit studies (data on file, Molecular Partners), and the new investigational product (now called AGN-150998) is currently being evaluated in a phase II trial in patients with neovascular AMD.

The small patient numbers (n = 32 in 5 dose cohorts) involved in this study, as well as the single-dose, open-label design, prevent any definitive conclusions from being drawn. Future repeat-dose studies with appropriate comparators will be needed to confirm the efficacy and duration of action of MP0112. Initial observations, however, suggest a potential benefit to patients, as demonstrated by the stabilization and improvement of VA and the dose-dependent reductions seen in CRT and leakage. Patients in the higher-dose cohorts (1.0 and 2.0 mg) showed tendencies to experience greater mean reductions in CRT, which were maintained beyond week 4, as well as reduced needs for rescue therapy compared with patients in the lower-dose cohorts (0.04, 0.15 and 0.4 mg). Indeed, OCT did not demonstrate any improved benefit of rescue therapy for CRT in patients in the higher-dose cohorts. This is in line with the pharmacokinetic data of the DME trial, in which patients achieved very high ocular MP0112 levels with very low systemic exposure to MP0112.²³ With the exception of 1 subject, all patients who received 1.0 and

2.0 mg MP0112 and did not require rescue therapy maintained reduction in CRT through week 16. This is in clear contrast to the vast majority (91%) of patients in the lower-dose cohorts who received rescue therapy from week 4 onward. This points to a potential dose response and underlines the potential of MP0112 for less frequent dosing. It is notable that spectral-domain OCT was not performed in all patients in this study. Further studies using spectral-domain OCT would likely provide more detailed results. Another limit of the study is the lack of antidrug antibody analysis.

DARPin are a novel class of therapeutic molecules that exhibit significant advantages over monoclonal antibodies.

They bind with high affinity and specificity to their targets, like monoclonal antibodies, but in addition show increased potency and longer ocular pharmacokinetics. MP0112 has significant potential to positively impact the treatment of ocular disease.¹⁵

The pharmacokinetic characteristics of MP0112 have been reported previously.²³ The prolonged duration of action observed using OCT (3–4 months at ≥ 1.0 mg) in this trial indicate the possibility of extending the duration of effect by prolonging suppression of VEGF. Larger clinical trials, with the new purified investigational product, are needed to confirm these findings and quantify the effects of the drug.

ALL AUTHORS HAVE COMPLETED AND SUBMITTED THE ICMJE FORM FOR DISCLOSURE OF POTENTIAL CONFLICTS OF INTEREST, and the following were reported. Dr Souied receives consulting fees or honoraria from Allergan, Bayer and Novartis and fees for participation in review activities from Allergan, Bayer and Novartis and holds board membership with Allergan, Bausch & Lomb, Bayer, and Novartis. Travel/accommodation/meeting expenses unrelated to activities listed – Allergan, Bayer, Novartis. Dr Devin holds board membership with Alcon, Allergan, Bayer, and Novartis; consults with Alcon, Allergan, Bayer, Novartis, Ophthotech, and Thea; receives payment for lectures, including service on speakers' bureaus, from Alcon, Allergan, Bayer, and Novartis; and receives payment for development of educational presentations from Alcon, Allergan, Bayer, and Novartis. Dr Mauget-Fajÿsse receives consulting fees or honoraria, with fees going to the institution, from Molecular Partners and support for travel to meetings for the study of other purposes from Molecular Partners. Relevant financial activities outside the submitted work include board membership in Bayer and Novartis; payment for lectures, including service on speakers' bureaus, with fees going to the institution; from Bayer, Heidelberg, Novartis, and Thea; travel/accommodation/meeting expenses unrelated to activities listed, with fees going to the institution from Bayer, Heidelberg, Novartis, and Thea. Dr Kolár receives consulting honoraria from Molecular Partners. Relevant financial activities outside the submitted work include consultancy with Alcon, Bayer, and Novartis and payment for lectures, including service on speakers' bureaus, from Alcon, Bayer and Novartis. Dr Wolf-Schnurrbusch work under consideration for publication: payment for gradings to institution. Dr Framme holds board membership with Allergan, Bayer and Novartis, is a consultant for Bayer, and receives payment for lectures, including service on speakers' bureaus, from Bayer, Heidelberg and Novartis. Dr Gaucher holds board membership in Allergan, Bayer and Novartis and receives payment for development of educational presentations, with fees going to the institution, from Novartis; and receives travel/accommodation/meeting expenses unrelated to activities listed from Alcon, Bausch & Lomb, Bayer, and Novartis. Dr Querques receives consulting fees or honoraria from Molecular Partners; holds board membership in Alimera, Allergan and Bayer; and is a consultant to Alcon, Alimera, Allergan, Bayer, Bausch & Lomb, Molecular Partners, Novartis, and Ophthotech. Dr Stumpp holds employment, patents and stock/stock options in Molecular Partners. Dr Wolf has received a grant, with fee to the institution, from Molecular Partners; consulting fees or honoraria, with fees to the institution, from Molecular Partners; support for travel to meetings for the study of other purposes from Molecular Partners; is a board member of EURETINA; receives consultancy fees that go to the institution from Allergan, Bayer, Heidelberg Engineering, Novartis, and Optos; and receives fees for expert testimony, with fees going to the institution, from Bayer. Molecular Partners AG, Zurich, Switzerland, provided support for the study and participated in study design; conducted the study; and provided data collection, management and interpretation. The study is registered at ClinicalTrials.gov under the identifier: NCT01086761. Conception and design of study (E.S., M.S., S.W.); Analysis and interpretation of data (E.S., U.W., C.F., G.Q., M.S., S.W.); Preparation of manuscript (E.S., M.S., S.W.); Critical revision of manuscript (E.S., C.F., G.Q., M.S., S.W.); Final approval of manuscript (E.S., F.D., M.M., P.K., U.W., C.F., D.G., G.Q., M.S., S.W.); Data collection (U.W., C.F., S.W.); Provision of materials, patients, or resources (E.S., F.D., M.M., P.K., U.W., C.F., D.G., G.Q.). The authors thank Fiona Powell, Facilitate Ltd, Brighton, UK, for editorial assistance in the production of this manuscript.

REFERENCES


1. Klein R. Overview of progress in the epidemiology of age-related macular degeneration. *Ophthalmic Epidemiol* 2007; 14(4):184–187.
2. Munoz B, West SK, Rubin GS, et al. Causes of blindness and visual impairment in a population of older Americans: the Salisbury Eye Evaluation Study. *Arch Ophthalmol* 2000; 118(6):819–825.
3. Klein R, Peto T, Bird A, Vannewkirk MR. The epidemiology of age-related macular degeneration. *Am J Ophthalmol* 2004; 137(3):486–495.
4. Klein R, Klein BE, Jensen SC, Meuer SM. The five-year incidence and progression of age-related maculopathy: the Beaver Dam Eye Study. *Ophthalmology* 1997;104(1):7–21.
5. Nowak JZ. Age-related macular degeneration (AMD): pathogenesis and therapy. *Pharmacol Rep* 2006;58(3): 353–363.
6. Ciulla TA, Rosenfeld PJ. Antivascular endothelial growth factor therapy for neovascular age-related macular degeneration. *Curr Opin Ophthalmol* 2009;20(3):158–165.
7. Stewart MW. Clinical and differential utility of VEGF inhibitors in wet age-related macular degeneration: focus on aflibercept. *Clin Ophthalmol* 2012;6:1175–1186.
8. Rofagha S, Bhisitkul RB, Boyer DS, Sadda SR, Zhang K. Seven-year outcomes in ranibizumab-treated patients in ANCHOR, MARINA, and HORIZON: a multicenter cohort study (SEVEN-UP). *Ophthalmology* 2013;120(11): 2292–2299.
9. Kaiser PK, Brown DM, Zhang K, et al. Ranibizumab for predominantly classic neovascular age-related macular degeneration: subgroup analysis of first-year ANCHOR results. *Am J Ophthalmol* 2007;144(6):850–857.
10. Brown DM, Michels M, Kaiser PK, Heier JS, Sy JP, Ianchulev T. Ranibizumab versus verteporfin photodynamic therapy for neovascular age-related macular degeneration:

- two-year results of the ANCHOR study. *Ophthalmology* 2009; 116(1):57–65.
11. Rosenfeld PJ, Brown DM, Heier JS, et al. Ranibizumab for neovascular age-related macular degeneration. *N Engl J Med* 2006;355(14):1419–1431.
 12. Gragoudas ES, Adamis AP, Cunningham ET Jr, Feinsod M, Guyer DR. Pegaptanib for neovascular age-related macular degeneration. *N Engl J Med* 2004;351(27):2805–2816.
 13. Heier JS, Brown DM, Chong V, et al. Intravitreal aflibercept (VEGF trap-eye) in wet age-related macular degeneration. *Ophthalmology* 2012;119(12):2537–2548.
 14. Stewart MW. The expanding role of vascular endothelial growth factor inhibitors in ophthalmology. *Mayo Clin Proc* 2012;87(1):77–88.
 15. Stumpp MT, Binz HK, Amstutz P. DARPins: a new generation of protein therapeutics. *Drug Discov Today* 2008; 13(15–16):695–701.
 16. Forrer P, Stumpp MT, Binz HK, Pluckthun A. A novel strategy to design binding molecules harnessing the modular nature of repeat proteins. *FEBS Lett* 2003;539(1–3):2–6.
 17. Binz HK, Stumpp MT, Forrer P, Amstutz P, Pluckthun A. Designing repeat proteins: well-expressed, soluble and stable proteins from combinatorial libraries of consensus ankyrin repeat proteins. *J Mol Biol* 2003;332(2):489–503.
 18. Theurillat JP, Dreier B, Nagy-Davidescu G, et al. Designed ankyrin repeat proteins: a novel tool for testing epidermal growth factor receptor 2 expression in breast cancer. *Mod Pathol* 2010;23(9):1289–1297.
 19. Zahnd C, Kawe M, Stumpp MT, et al. Efficient tumor targeting with high-affinity designed ankyrin repeat proteins: effects of affinity and molecular size. *Cancer Res* 2010;70(4): 1595–1605.
 20. Munch RC, Muhlebach MD, Schaser T, et al. DARPins: an efficient targeting domain for lentiviral vectors. *Mol Ther* 2011;19(4):686–693.
 21. Seeger MA, Mittal A, Velamakanni S, et al. Tuning the drug efflux activity of an ABC transporter in vivo by in vitro selected DARPins binders. *PLoS One* 2012;7(6): e37845.
 22. Stahl A, Stumpp MT, Schlegel A, et al. Highly potent VEGF-A-antagonistic DARPins as anti-angiogenic agents for topical and intravitreal applications. *Angiogenesis* 2013; 16(1):101–111.
 23. Campochiaro PA, Channa R, Berger BB, et al. Treatment of diabetic macular edema with a designed ankyrin repeat protein that binds vascular endothelial growth factor: a phase I/II study. *Am J Ophthalmol* 2013;155(4): 697–704.



Biosketch

Professor Eric H. Souied is head of the Department of Ophthalmology at the Hôpital Intercommunal de Créteil, France. He earned his MD and PhD degrees between 1990 and 2006 at Université Paris Est Créteil. He also completed a post-doctoral fellowship at the Jules Stein Eye Institute, UCLA, Los Angeles. Professor Souied has contributed to more than 210 peer-reviewed articles in the field of medical retina (AMD, inherited macular and retinal dystrophies).



Biosketch

Sebastian Wolf MD, PhD is director of the Department of Ophthalmology at the Inselspital, University of Bern, Switzerland. His main areas of scientific interest are age-related macular degeneration, retinal vascular disease, imaging, and vitreo-retinal surgery. Dr Wolf has authored over 150 publications in peer-reviewed journals and serves on the editorial board of several journals. He has been appointed as ARVO Gold Fellow and has been elected as General Secretary of the EURETINA.