

familial cases than to find severely affected parents with normal children.

REFERENCES

1. KISTENMACHER ML, PUNNETT HH: Comparative behavior of ring chromosomes. *Am J Hum Genet* 22:304-318, 1970.
2. BURDEN M, LUPASCU E, MARGINEANU L: A familial case of 17R ring shaped chromosome of group E with transmission from father to son. *Revista Medico-Chirurgicală a Societății de Medici și Naturaliști din Iași* 77:353-357, 1973.
3. CHRISTENSEN KR, FRIEDRICH U, JACOBSEN P, ET AL: Ring chromosome 18 in mother and daughter. *J Ment Defic Res* 14:49-67, 1970.
4. PALMER CG, HODES ME, REED T, ET AL: Four new cases of ring 21 and 22 including familial transmission of ring 21. *J Med Genet* 14:54-60, 1977.
5. ZDANSKY R, BUHLER EM, VEST M, ET AL: Familiäres Mosaik mit G-ring. *Humangenetik* 7:275-286, 1969.
6. MOORHEAD PS, NOWELL PC, MELLMAN WJ, ET AL: Chromosome preparations of leukocytes cultured from human peripheral blood. *Expl Cell Res* 20:613-616, 1960.
7. SEABRIGHT M: A rapid banding technique for human chromosomes. *Lancet* 2:971-972, 1971.
8. BERGSMA D (exec ed): *Birth Defects: Original Article Series. Number 7: Paris Conference (1971): Standardization in Human Cytogenetics*, vol 8. New York, The National Foundation-March of Dimes, 1972.
9. FRAISSE J, LAURAS B, OOGHE MJ, ET AL: A propos d'un cas de chromosome 9 en anneau. Identification par dénaturation ménagée. *Ann Génét* 17:175-180, 1974.

Dominantly Inherited Amyotrophic Lateral Sclerosis (Motor Neuron Disease)

LOUISE E. WILKINS, *Graduate Assistant, Department of Human Genetics*

ROBIN M. WINTER, M.B., M.R.C.P., *Postdoctoral Fellow, Department of Human Genetics*

EDWIN C. MYER, M.D., *Assistant Professor, Department of Pediatric Neurology*

WALTER E. NANCE, M.D., Ph.D., *Professor, Department of Human Genetics, Pediatrics and Medicine*

The term amyotrophic lateral sclerosis (ALS) was first introduced by Charcot to describe cases with mixed upper and lower motor neuron signs without

sensory impairment.¹ Later, the syndromes of progressive bulbar palsy (PBP) and progressive muscular atrophy (PMA) were recognized to be variations of the same pathological process, and ALS was used as an inclusive term to refer to these syndromes as well. Although some authors reserve the term ALS for the specific syndrome of mixed upper and lower motor neuron lesions and use the term "motor neuron disease" to refer to the constellation of syndromes, most

This is paper #46 from the Department of Human Genetics of the Medical College of Virginia and was supported in part by Grant #C-187 from the National Foundation-March of Dimes.

Correspondence and reprint requests to Louise E. Wilkins, Box 33, Medical College of Virginia, Richmond, Virginia 23298.

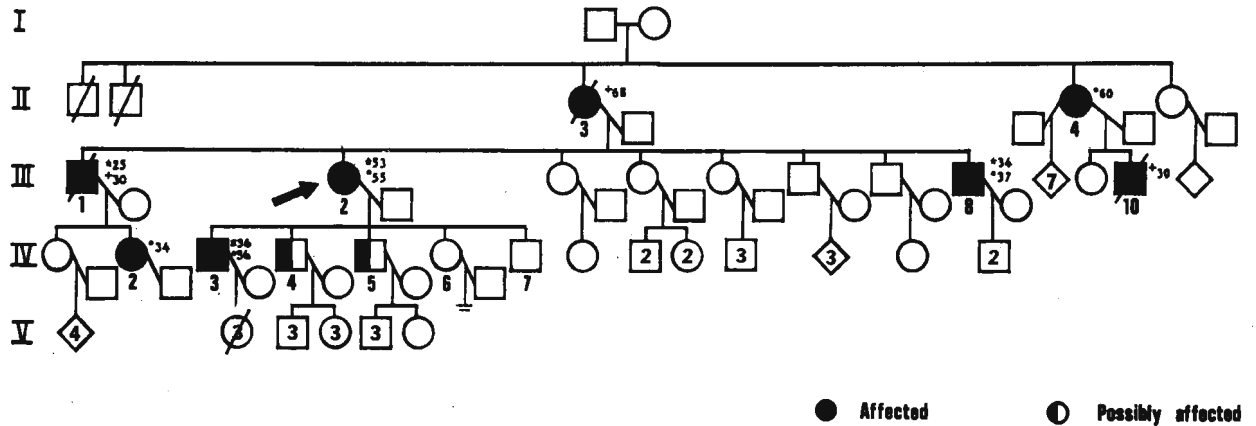


Fig 1—Pedigree of proband and family members.

- * = Age at diagnosis
- = Present age
- + = Age at death

of the literature on familial cases uses ALS as a generic title. We will adhere to this convention.

Initially, the disease was thought to be sporadic, with a stable incidence of 1 in 100,000 population per year. In the early 1950s, reports appeared of a high incidence of ALS in the Chamorro Micronesians of Guam and on the Kii Peninsula in Japan.²⁻⁵ Studies suggested that at least some of the cases of ALS among Chamorros might be familial, and at about the same time familial cases began to be reported in Caucasian populations.

Case Report

Proband: The proband (Fig 1, III-2) is a 55-year-old white female with known maturity-onset diabetes, hypothyroidism, hypertension, and hepatosplenomegaly diagnosed as cirrhosis with fatty infiltration on liver biopsy, who presented with a three-year history of progressive weakness in her legs, causing difficulty in walking upstairs and rising from a chair. For one year, weakness increasingly impaired her ability to pick up objects, and her writing had become illegible. There had been no episodes of acute exacerbation or remissions.

On examination, wasting and fasciculations of the tongue were noted, and her speech was slow and slurred, and the jaw jerk was hyperactive. There was weakness and wasting in the legs, and all reflexes were brisk with sustained ankle clonus, bilateral Hoffman signs, and bilateral positive Babinski responses. Sensation was normal in all modalities. VDRL, serum B₁₂, cerebrospinal fluid (CSF), myelogram, and computerized axial tomography (CT) scans were all normal. An electromyogram (EMG) showed changes consistent with ALS, especially in the C₅ and T₁ nerve root distributions.

Other Family Members: It can be seen from the pedigree (Fig 1) that the proband's mother (II-3), maternal

aunt (II-4), cousin (III-10), niece (IV-2), and two brothers (III-1, III-8) have all been diagnosed as having ALS. The age at onset has been variable, as has the duration of the disease in the different family members.

The offspring of the proband are presently under investigation. The eldest son (IV-3) has definite upper motor neuron signs in the legs with brisk reflexes and bilateral Babinski responses which, combined with the family history, are highly suggestive of ALS. Two offspring (IV-4 and IV-5) show minimal signs of muscle wasting and slightly brisk reflexes. The diagnosis of ALS here is less certain, but the possibility exists that these two brothers are also affected. The two youngest children (IV-6 and IV-7) show no sign of the disease. EMG studies may help establish a definite diagnosis in those family members at risk.

Discussion

Evidence for Heterogeneity in ALS

There are three recognizable clinical forms of classical, sporadic ALS. In progressive bulbar palsy (PBP), muscles innervated by the medulla are primarily affected. The presenting symptoms are dysarthria and dysphagia of insidious onset. The tongue atrophies and shows conspicuous fasciculations. Palatal involvement is indicated by progressive speech difficulties and regurgitation of food through the nose. Whereas PBP is the result of a lower motor neuron (LMN) lesion, it is frequently accompanied by upper motor neuron (UMN) involvement of the cranial nerves leading to "pseudobulbar palsy." Here the tongue is again small but tends to be spastic, and the jaw, palatal, and pharyngeal reflexes are exaggerated. In addition, there is marked emotional lability with attacks of inappropriate laughing or crying.

In a second form of the disease, muscles in-

nervated by the spinal nerves are primarily affected and UMN signs accompany those resulting from the lesions of the LMNs. Isolated UMN lesions are indicated by spasticity and brisk reflexes with bilateral Babinski responses, whereas isolated LMN lesions present with muscle wasting, weakness, and fasciculations with depressed or absent reflexes. The actual physical signs depend on the relative preponderance of UMN or LMN degeneration.

In a third form, LMN lesions predominate resulting in progressive muscular atrophy, but UMN lesions may occasionally be present. The symptoms and signs of LMN lesions are as described above and usually start in the hands and forearms.

Although these three clinical presentations can be distinguished, all are thought to be variations of the same process. Sensory impairment is not found, although patients may complain of muscle cramps or abnormal sensations resulting from muscle fasciculations.

The diagnosis is usually made on clinical grounds, although the EMG shows characteristic patterns of denervation with fibrillation, fasciculation, and giant action potentials indicating spontaneous activity.

Pathologically, extensive neuronal loss is evident with astrocytic gliosis of the UMNs and LMNs as well as the lower cranial nuclei. Cytoplasmic and nuclear shrinkage occurs with excessive accumulation of lipofuscin. In Guamanian cases, additional features include neurofibrillary degeneration of the orbital gyrus, Ammon horn, and basal ganglia. Granulovascular bodies are almost always present in the

pyramidal cells of Ammon horn where eosinophilic crystalloid inclusion bodies are also seen.⁶

Although reports of familial adult-onset ALS constitute only about 5% to 10% of the reported cases,⁷ at least 30 Caucasian families have been described in which there appears to have been a dominant mode of inheritance.⁸⁻¹⁶

Among the Chamorros, nearly 50% of all reported cases are familial;¹⁷ however, extensive studies have failed to define a clear pattern of inheritance.⁷ It is possible that there may be a genetic predisposition to an environmental agent.

It is still uncertain whether these three entities, sporadic, Guamanian, and familial ALS, represent one or several etiologically different diseases. All three present with indistinguishable symptoms of muscular atrophy, lateral sclerosis, and bulbar palsy. Dementia, often seen in affected Chamorros, also occurs in both familial and sporadic cases.¹⁸ Involvement of the posterior columns has been described in a small number of inherited ALS cases¹⁹ but not with enough consistency to be distinctive.

Other parameters may permit a clear distinction of the three types (Table 1).

Sporadic ALS typically has a late onset in the early 50s; the first signs usually appear in the upper extremities, and the disease has a short duration leading to death within five years. In contrast, a review of 30 published Caucasian pedigrees indicates that familial cases more often have an onset in the early forties beginning in the lower extremities with a longer duration. Chamorro cases resemble familial ALS in onset and duration but are similar to sporadic

TABLE 1
Comparison of Sporadic, Guamanian, and Familial ALS

Based on	Sporadic		Guamanian		Familial	
	Parameter value	Number of cases	Parameter value	Number of cases	Parameter value	Number of cases
Age of onset, yrs	52.7 ± 2.7	100	46.1 ± 13.1	62	42.7 ± 11.1	98
Onset under 30 yrs	1%	100	8%	62	13.3%	98
Duration, yrs	2.5	86	4	70	4.3	83
Duration > 5 yrs	8.1%	86	34.3%	70	36.5%	83
Initial Site		100		62		70
Bulbar	25%		13%		18%	
Upper extremity	41%		64%		26%	
Lower extremity	30%		20%		56%	
Other	4%		3%		0%	
Sex ratio: male:female	1.86:1	186	1.94:1	132	1.13:1	98

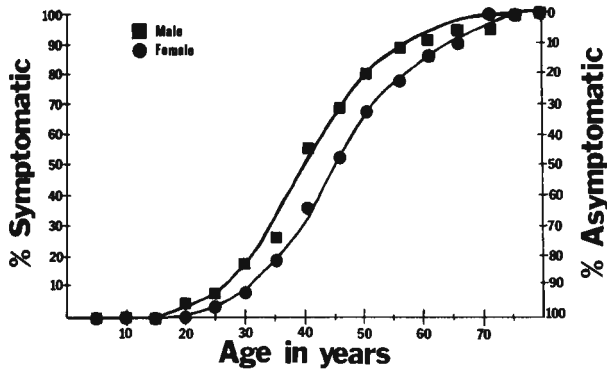


Fig 2—Cumulative distribution of age at onset in familial ALS.

ALS in sex ratio and site of initial involvement.^{17,20} The Chamorro population on Guam appears to be intermediate in many respects between the familial and sporadic types. However, until the etiology of ALS is known, it will not be possible to classify these diseases with certainty.

Genetic Counseling

In this family, the pedigree suggests autosomal dominant transmission with complete penetrance, but in the absence of male-to-male transmission, a sex-linked dominant inheritance cannot be excluded. The genetic advice given to family members (consultands) will depend on the presence or absence of signs of the disease and their relationship to individuals known to be affected.

For example, a 47-year-old man, whose father has been diagnosed as having ALS, wants to know if he too will become affected and what is his risk of having an affected child. His a priori risk of having inherited the gene from his father is one half because of the dominant transmission of ALS. From a review of published familial cases, ALS appears to be a

strongly penetrant trait with nonpenetrance occurring in only 3% of the cases.^{18,21} Figure 2 depicts a cumulative distribution of the age of onset of familial ALS in 52 males and 46 females culled from the literature. Patients who do carry the gene have only a one-fourth probability of reaching the age of 47 without manifesting the disease. The posterior or final probability that the consultand, age 47 with an affected father but no symptoms himself, will develop ALS is one fifth or 20% (Table 2).²² The practical implication for genetic counseling is that the longer the consultand lives and is symptom free, the lower will be his risk of carrying the gene.

Conclusion

Familial conditions, such as ALS, Huntington chorea, dystrophia myotonica, polyposis coli, and the presenile dementias, in which individuals who carry the abnormal gene may not develop symptoms until late in the reproductive period, present difficult problems for the genetic counselor. Modification of the a priori probabilities by consideration of the age of the consultand, as described above, can make a considerable difference to risk estimates.

REFERENCES

1. GOLDBLATT D: Motor neuron disease: Historical introduction, in Norris FH Jr, Kurland LT (eds): *Motor Neuron Disease*. New York, Grune and Stratton Inc, 1969, pp 3-11.
2. KOERNER DR: Amyotrophic lateral sclerosis on Guam: A clinical study and review of the literature. *Ann Intern Med* 37:1204-1220, 1952.
3. TILLEMA S, WIJNBERG CJ: 'Endemic' amyotrophic lateral sclerosis on Guam; epidemiological data. *Doc Med Geogr Trop (Austria)* 5:366-370, 1953.
4. ARNOLD A, EDGRUM DC, PALLADINO VS: Amyotrophic lateral sclerosis: 50 cases observed on Guam. *J Nerv Ment Dis* 117:135-139, 1953.
5. MULDER DW, KURLAND LT: Amyotrophic lateral sclerosis in Micronesia. *Proc Mayo Clin* 29:666-670, 1954.
6. HIRANO A, MALAMUDI N, KURLAND LT, ET AL: A review of the pathologic findings in ALS in motor neuron disease, in Norris FH Jr, Kurland LT (eds): *Motor Neuron Disease*. New York, Grune and Stratton Inc, 1969, pp 51-60.
7. ESPINOSA RE, OKIHIRO MM, MULDER DW, ET AL: Hereditary amyotrophic lateral sclerosis: A clinical and pathologic report with comments on classification. *Neurology (Minneapolis)* 12:1-7, 1962.

TABLE 2
Bayesian Approach to Estimation of Genetic Risk

Probability	Inherited the disorder	Not inherited the disorder
A priori	1/2	1/2
Conditional	1/4	1
Joint	1/8	1/2
Posterior probability the consultand is affected	$= \frac{1/8}{1/8 + 1/2} = 1/5$	

8. MYRIANTHOPOULOS NC, BROWN IA: A genetic study of progressive spinal muscular atrophy. *Am J Hum Genet* 6:387-411, 1954.
9. AMICK LD, NELSON JW, ZELLWEGER H: Familial motor neuron disease, non-Chamorro type: Report of kinship. *Acta Neurol Scand* 47:341-349, 1971.
10. METCALF CW, HIRANO A: Amyotrophic lateral sclerosis. Clinicopathological studies of a family. *Arch Neurol* 24:518-523, 1971.
11. TAKAHASHI K, NAKAMURA H, OKADA E: Hereditary amyotrophic lateral sclerosis: Histochemical and electron microscopic study of ayaline inclusions in motor neurons. *Arch Neurol* 27:292-299, 1972.
12. PINSKY L, FINLAYSSEN MH, LIBMAN I, ET AL: Familial amyotrophic lateral sclerosis with dementia: A second Canadian family. *Clin Genet* 7:186-191, 1975.
13. THOMSON AF, ALVAREZ FA: Hereditary amyotrophic lateral sclerosis. *J Neurol Sci* 8:101-110, 1968.
14. KURLAND LT, MUDLER DW: Epidemiologic investigations of amyotrophic lateral sclerosis. 2. Familial aggregations indicative of dominant inheritance, Part I. *Neurology (Minneapolis)* 5:182-196, 1955.
15. ENGEL WK, KURLAND LT, KLATZO I: An inherited disease similar to amyotrophic lateral sclerosis with a pattern of posterior column involvement. An intermediate form? *Brain* 82:203-220, 1959.
16. POSER CM, JOHNSON M, BUNCH LD: Familial amyotrophic lateral sclerosis. *Dis Nerv Sys* 26:697-702, 1965.
17. MULDER DW: The clinical syndrome of amyotrophic lateral sclerosis. *Staff Meet Mayo Clin* 32:427-436, 1957.
18. FINLAYSSEN MH, GUBERMAN A, MARTIN JB: Cerebral lesions in familial amyotrophic lateral sclerosis and dementia. *Acta Neuropathol* 26:237-246, 1973.
19. HIRANO A, KURLAND LT, SAYRE GP: Familial amyotrophic lateral sclerosis. *Arch Neurol* 16:232-243, 1967.
20. HIRANO A, ARUMUGASAMY N, ZIMMERMAN HM: Amyotrophic lateral sclerosis: A comparison of Guam and classical cases. *Arch Neurol* 16:357-363, 1967.
21. ATLER M, SCHAUMANN B: Hereditary amyotrophic lateral sclerosis. A report of two families. *Eur Neurol* 14:250-265, 1976.
22. MURPHY EA, CHASE GA: *Principles of Genetic Counseling*. Chicago, Year Book Medical Publishers Inc, 1975, pp 70-74.

A Case of Saethre-Chotzen Syndrome

CATHERINE McKEON-KERN, *Graduate Assistant, Department of Human Genetics*
 PETER MAMUNES, M.D., *Professor of Pediatrics and of Human Genetics*

Saethre-Chotzen syndrome was described independently by the Norwegian psychiatrist, Saethre,¹ and the German psychiatrist, Chotzen,² in the 1930s;

Correspondence and reprint requests to Catherine McKeon-Kern, Box 33, Medical College of Virginia, Richmond, Virginia 23298.

since that time many cases have been reported, some using the terms acrocephalosyndactyly, type III, and craniooculodental syndrome. Clinically, the syndrome is characterized by premature closure of the cranial sutures, low-set hairline, nasal septum deviation, brachydactyly, and ptosis.³ It is inherited as an autosomal dominant with complete penetrance and