

Evaluation of Thyroid Nodules—Hot and Cold*

MELVIN J. FRATKIN, M.D.

Assistant Professor, Departments of Radiology and Medicine, Medical College of Virginia, Health Sciences Division of Virginia Commonwealth University, Richmond, Virginia

Thyroid nodules occur frequently, are more common in women, and the incidence increases with age for both sexes. Clinically normal thyroid glands commonly contain nodules in autopsy series. In 20- to 50-year-old females, as high as 50% of the thyroid glands are nodular, whereas in males the incidence approaches 30% (1). When the prevalence of clinically palpable thyroid nodules was the objective of the Framingham population researchers, Vander et al (2) detected nodules in 6.4% of females and 1.5% of males aged 30–50 years. Even with diligent, thorough examination of the neck, only about one tenth of pathologically nodular thyroid glands can be detected. However, the number of palpable nodules is significant, and determination of the pathology of the nodule or goiter, once found, rests with the patient's physician. Unfortunately, a detailed history and physical examination frequently does not provide all the necessary information needed to make a definite etiologic or pathologic diagnosis. Knowledge of the type of goiter is mandatory for proper treatment of the various disorders of the thyroid gland.

The various types or causes of goiters are shown in Table 1. Goiters may be divided clinically into diffuse or nodular; hyperthyroid, euthyroid, or hypothyroid. It is readily apparent that several pathologic entities may be diffuse or nodular in addition to altering thyroid function. Hyperthyroid patients may have a diffuse goiter, solitary nodule, or a multinodular gland. Graves' disease usually presents no diagnostic problems, but, rarely, a toxic

diffuse goiter may be caused by excessive pituitary thyroid-stimulating hormone (TSH) from hypothalamic thyrotropin-releasing hormone (TRH) stimulation or pituitary tumor. Subacute nonsuppurative thyroiditis may be focal or diffuse and cause transitory hyperthyroidism. The hyperthyroid phase of this disease is associated with a low or blocked radioactive iodine uptake (RAIU) and usually a painful, hard gland. The hyperthyroid adenomatous goiter produces the usual findings of thyrotoxicosis and, clinically, a multinodular goiter. Evaluation of a toxic adenoma will be discussed later.

Euthyroid diffuse goiters, with the exception of thyroiditis, represent compensatory enlargement of the gland in an attempt to maintain normal hormone production. Patients with dietary iodine deficiency have an elevated RAIU that is suppressible with supraphysiologic doses of thyroid hormone (our standard procedure is to give 150 μ g daily of triiodothyronine for seven days). Excessive iodine intake is associated with a suppressed or blocked RAIU. Diffuse goiter from congenital thyroidal enzyme deficiency, that is, peroxidase deficiency, results in an initially elevated RAIU with discharge of radioiodine from the gland following potassium perchlorate administration. The early adenomatous goiter often feels diffuse rather than nodular. The RAIU usually is normal, but the scan often shows nonuniform distribution of radioactivity within the gland. Subacute thyroiditis may diffusely involve the gland, and the patient may be euthyroid when seen. Chronic thyroiditis (Hashimoto's thyroiditis) is a painless, firm goiter frequently with high titers of antithyroid antibodies present in the serum. Any of the diffuse goiters may be accompanied by hypothyroidism, but low thyroid function is more com-

* Presented by Dr. Fratkin at the Postgraduate Course in Nuclear Medicine, February 27, 1975, in Williamsburg, Virginia.

TABLE 1
Types of Goiters

DIFFUSE	NODULAR
HYPERTHYROID	
Graves' Disease	Adenomatous
Excess TSH	Adenoma
Thyroiditis	Thyroiditis
EUTHYROID	
Iodine Deficiency	Carcinoma
Iodine Excess	Adenoma
Enzymatic Defects*	Colloid Cyst
Adenomatous	Adenomatous
Thyroiditis*	Thyroiditis

* May be associated with hypothyroidism

monly seen with congenital enzymatic deficiency goiters and Hashimoto's thyroiditis.

Patients with nodular goiter (as mentioned earlier) may be hyperthyroid or, rarely, hypothyroid, but are usually euthyroid. The euthyroid patients with nodular goiter, and especially those with a solitary nodule, represent the greatest diagnostic problem, for thyroid carcinoma must always be considered and excluded. Since one cannot differentiate a benign from a malignant tumor with certainty by palpation alone, further diagnostic tests are indicated (Fig. 1). The thyroid scan will determine whether the nodule is functioning (Fig. 2) or nonfunctioning (Fig. 3). The pathology of functioning (hot) and nonfunctioning (cold) nodules is shown in Table 2. The demonstration of a hot nodule with scanning essentially excludes the probability that the lesion is a carcinoma. However, if the nodule is cold, one can only make a statistical guess concerning the pathology. Further diagnostic work-up can be pursued prior to surgical exploration (Fig. 1). Nonfunctioning, solitary nodules may be separated into cystic and solid with ultrasonography, and recent reports (3, 4) suggest that cystic thyroid nodules represent 20% of cold nodules and are benign. Additional procedures have been performed in an attempt to non-invasively exclude thyroid carcinoma. Sonography (5), in addition to distinguishing cystic from solid lesions, demonstrates a characteristic echo pattern in malignancy that may prove to be diagnostic if substantiated by additional reports. Thyroid scanning of cold nodules with other radiopharmaceuticals such as ^{67}Ga -citrate (6) and ^{75}Se -methionine (7, 8) may be positive in cases of thyroid cancer, but false negatives (^{67}Ga) and false positives (^{75}Se) are frequent. Thermography (9) has been tried, but the number

of lesions studied are too few to reach any conclusions. According to an oral communication from J. Frable, MD, in January, 1975, thin-bore needle aspiration can yield a positive diagnosis of papillary adenocarcinoma, but cannot differentiate follicular adenoma from adenocarcinoma. I might sum up by saying that the solitary, nonfunctioning and especially the solid thyroid nodule is malignant until proven otherwise by surgical exploration. The results of sonography are exciting and promising, but further studies are indicated before the role of ultrasound can be established in the evaluation of thyroid nodules (Fig. 4).

The thyroid nodule that concentrates radioiodine may be a follicular adenoma, adenomatous nodule, normal thyroid tissue such as a lingual thyroid, or residual hyperplastic thyroid tissue following a subtotal thyroidectomy. The triiodothyronine suppression test will differentiate the autonomously functioning thyroid nodule from other types of functioning nodules (Fig. 5). Treatment of suppressible functioning thyroid nodules with thyroid hormone results usually in no further enlargement and frequently in disappearance clinically of the nodule.

The typical autonomously functioning thyroid nodule is illustrated in Figure 2. Although the patient is euthyroid, the nodule has suppressed the function of the normal thyroid tissue and is not suppressible with administration of triiodothyronine (Cytomel®). Administration of thyroid-stimulating hormone, 10 units daily for three days, may be used to demonstrate the presence of normal but suppressed thyroid tissue. Treatment with 25 millicuries of radioactive iodine resulted in ablation of the nodule, appearance of the previously suppressed normal thyroid gland, and continuation of a euthyroid state.

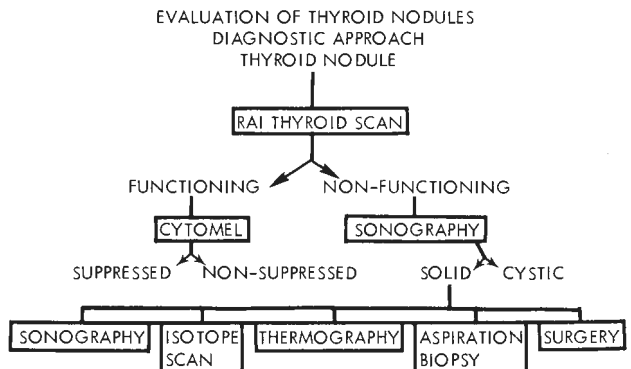


Fig. 1—Sequential diagnostic approach in evaluation of thyroid nodules.

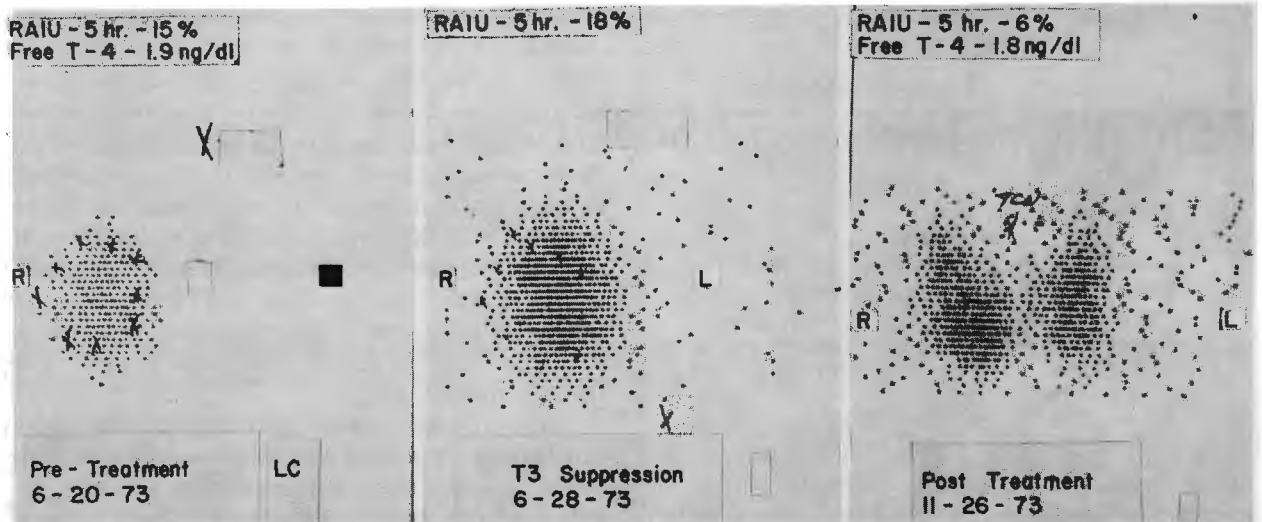


Fig. 2—*Left*. Functioning 4 × 3 cm right thyroid nodule with normal RAIU and serum free thyroxine concentration; no radioiodine uptake in area of left lobe. *Center*. Triiodothyronine (T-3) administration produced no decrease in RAIU or nodule uptake. *Right*. Following radioiodine treatment, nodule has been ablated; right and left lobes concentrate radioiodine; overall thyroid function remains normal.

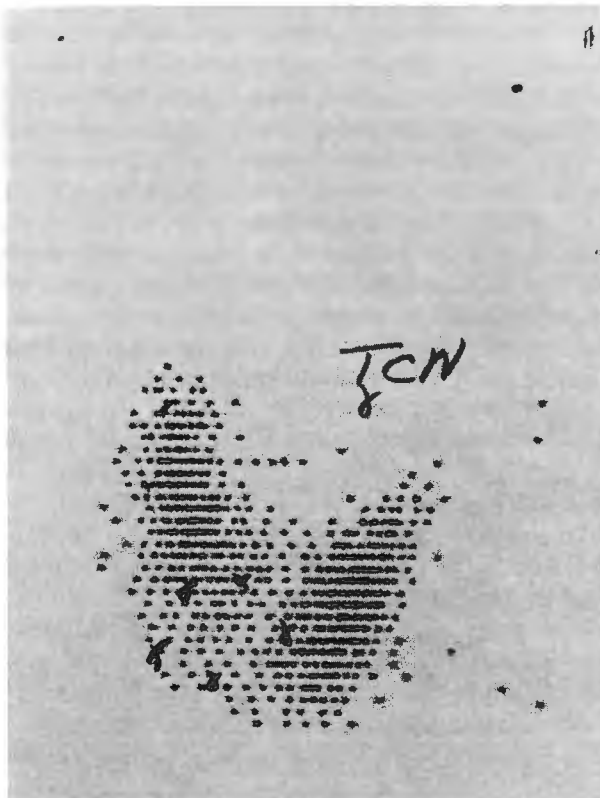
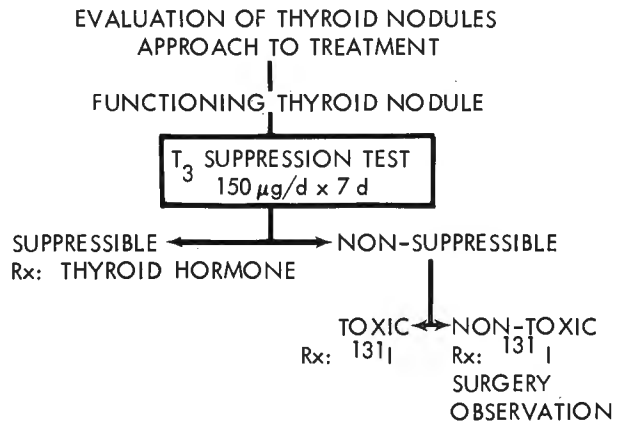
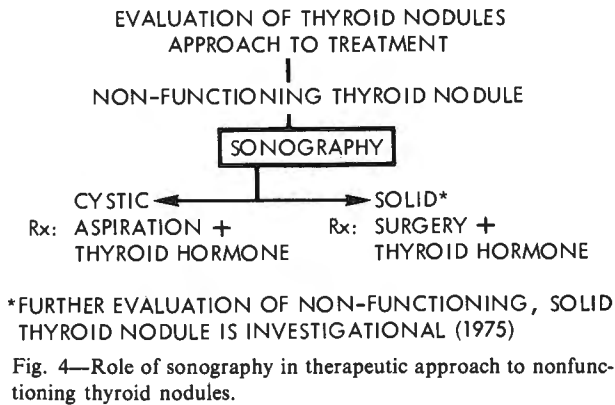


Fig. 3—Nonfunctioning thyroid nodule in lower pole of right lobe. Pathologic diagnosis was follicular adenoma.

The question arises, though, should a nontoxic, autonomously functioning nodule be treated at all? What is the natural history of a functioning follicular adenoma? There are case reports of nontoxic nodules progressing to toxic nodules which then require treatment because of the development of clinical hyperthyroidism. Such a course of events is shown in Figure 6. Patient W. W. first noted a goiter 15 years ago, but was advised that no treatment was necessary. In 1969, his protein-bound iodine (PBI) was normal, and his nodule had gradually increased in size. When seen in 1973, he was hyperthyroid. Treatment with radioiodine achieved a euthyroid state but little to no reduction in the size of the nodule. It can be assumed that he had an autonomously functioning nodule from the onset that progressed in size over the years, achieving a sufficient mass to produce excessive amounts of thyroid hormone and hyperthyroidism.

TABLE 2
Pathology of Thyroid Nodules

HISTOLOGIC DIAGNOSIS	FUNCTIONING		NONFUNCTIONING	
	NO.	PERCENT	NO.	PERCENT
Adenomatous	53	70	107	58
Adenoma	11	15	31	17
Carcinoma	0	0	24	13
Hyperplasia	5	7	0	0
Thyroiditis, Chronic	0	0	7	4
Unclassified	6	8	15	8
Total	75		184	



Is this case the exception or the rule? Horst and associates (10) and later Ferraz et al (11) suggest that the natural history of a nontoxic but autonomously functioning thyroid nodule is one of progression to hyperthyroidism. They based their conclusions on data demonstrating toxic nodules being larger than nontoxic ones, and the rather continuous spectrum of functional activity from euthyroidism to overt hyperthyroidism. Similarly, Hamburger and Meier (12) noted that those patients who were hyperthyroid

were older and had larger nodules than euthyroid patients with nonsuppressible functioning nodules. In their prospective study of 28 nontoxic patients with autonomously functioning nodules followed one to ten years (majority followed less than six years), none became hyperthyroid, but four glands increased in size. A retrospective study by McCormack and Sheline (13) revealed 1 out of 14 nontoxic untreated

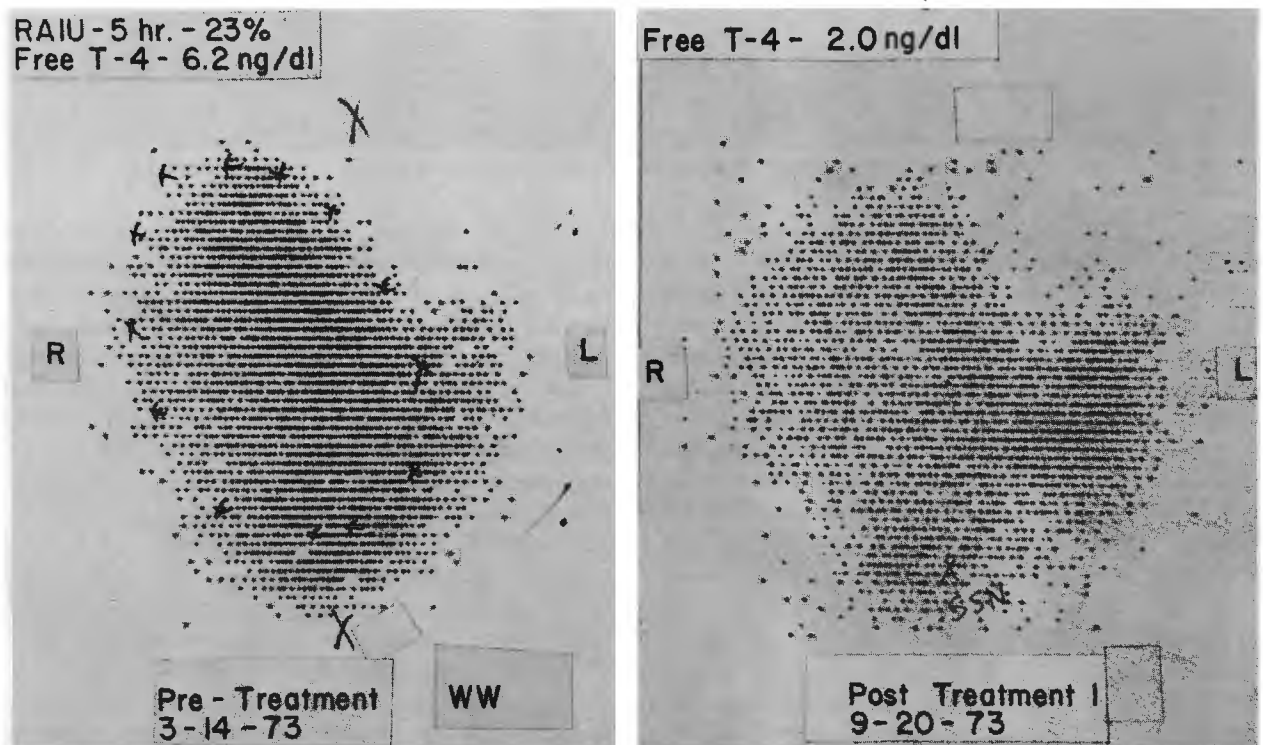


Fig. 6—Left. Large 9 × 6 cm toxic nodule with high RAIU and serum free thyroxine concentration. Right. Establishment of normal function, but persistence of nodule following radioiodine treatment.

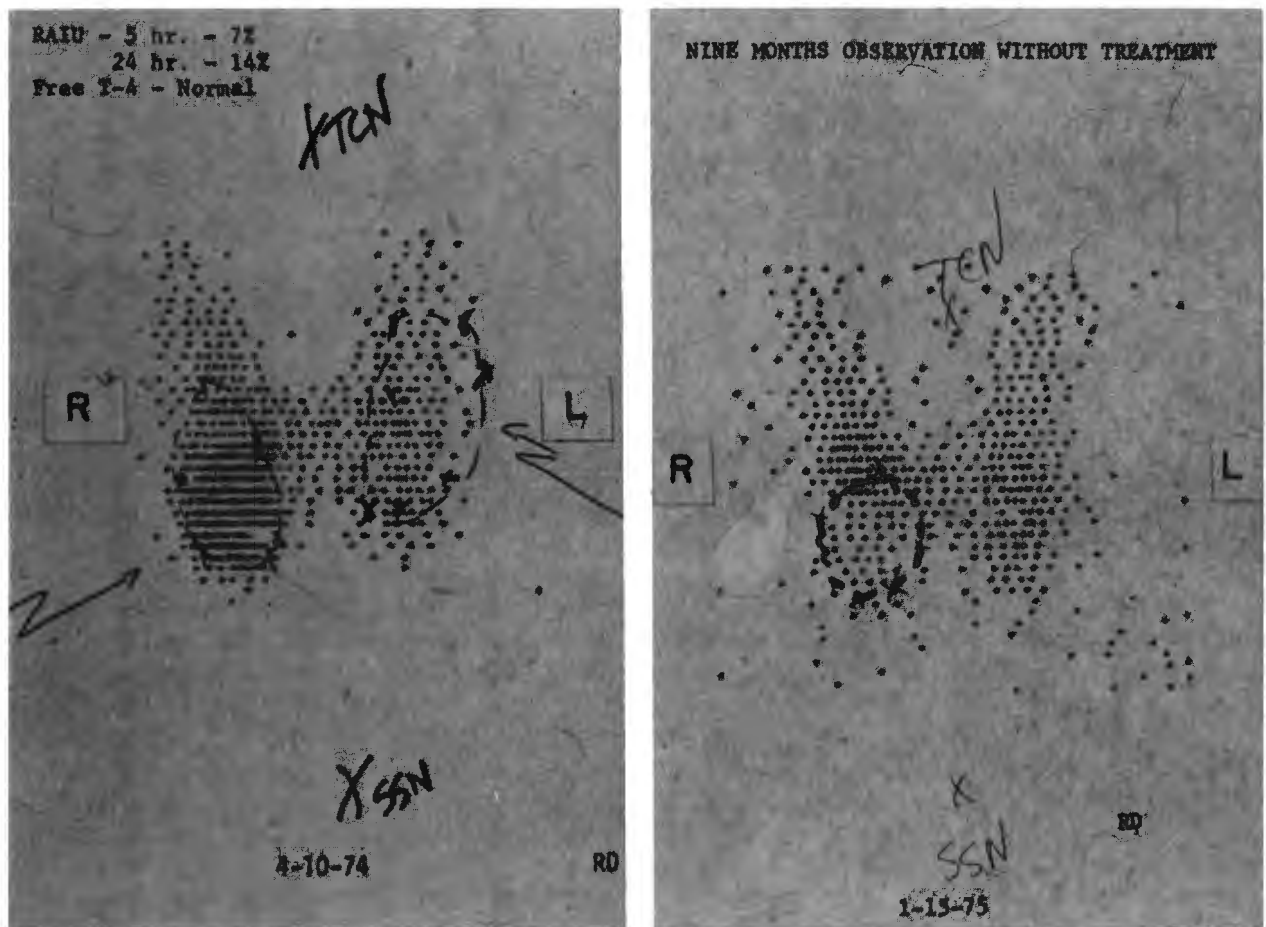


Fig. 7—*Left.* Functioning thyroid nodule in lower right lobe with partial suppression of the remainder of the gland. *Right.* Loss of function in outlined nodule.

patients developed hyperthyroidism. The longest follow-up was 8½ years with a mean of about 4 years. The available data suggest circumstantially that non-toxic, autonomously functioning thyroid nodules progress to toxicity, but usually not within the first eight to ten years from the initial diagnosis.

The next case (Fig. 7) illustrates the opposite natural history—spontaneous disappearance of function from a hot nodule. The initial scan shows a functioning nodule with partial suppression of the remaining gland. Treatment with triiodothyronine, 150µg daily for seven days, resulted in a RAIU of 1%, and no specific therapy was instituted. The patient became concerned about the small but visible mass in her neck. When she returned nine months later, the nodule had lost its ability to take up radioiodine. Surgical exploration revealed a follicular adenoma.

Our experience and that of others (10, 13) reveal

that large doses of radioiodine (20–40 millicuries) are necessary to ablate autonomously functioning thyroid nodules, that euthyroid function is achieved, and that hypothyroidism does not develop following treatment when the normal thyroid tissue is protected by endogenous and/or exogenous thyroid hormone. On occasion, a residual but nonfunctioning nodule may persist following radioiodine therapy. Surgery, although equally effective therapy (13), adds unnecessary additional cost and morbidity for the patient with an autonomously functioning thyroid nodule.

In summary, functioning but suppressible thyroid nodules may be treated successfully with thyroid hormone (Fig. 5). Completely or partially autonomously functioning nodules are benign follicular adenomas. This type of nodule may progress in size to produce hyperthyroidism or may lose its ability to concentrate iodine. Radioiodine is a safe,

efficient treatment for autonomously functioning thyroid nodules and should be considered the treatment of choice.

REFERENCES

1. MORTENSEN JD, WOOLNER LB, BENNETT WA: Gross and microscopic findings in clinically normal thyroid glands. *J Clin Endocrinol Metab* 15:1270-1280, 1955.
2. VANDER JB, GASTON EA, DAWBER TR: The significance of nontoxic thyroid nodules. *Ann Intern Med* 69:537-540, 1968.
3. BLUM M, GOLDMAN AB, HERSKOVIC A, ET AL: Clinical applications of thyroid echography. *N Engl J Med* 287:1164-1169, 1972.
4. MISKIN M, ROSEN IB, WALFISH PG: B-mode ultrasonography in assessment of thyroid gland lesions. *Ann Intern Med* 79:505-510, 1973.
5. CROCKER EF, McLAUGHLIN AF, KOSSOFF G, ET AL: The gray scale echographic appearance of thyroid malignancy. *J Clin Ultrasound* 2:305-306, 1974.
6. KAPLAN WD, HOLMAN BL, SELENKOW, H. A., ET AL: ^{67}Ga -citrate and the nonfunctioning thyroid nodule. *J Nucl Med* 15(pt 1):424-427, 1974.
7. THOMAS CG JR, PEPPER FD, OWEN J: Differentiation of malignant from benign lesions of the thyroid gland using complementary scanning with ^{76}Se selenomethionine and radioiodide. *Ann Surg* 170:396-408, 1969.
8. WEINSTEIN MB, ASHKAR FS, CARON CD: ^{76}Se Selenomethionine as a scanning agent for the differential diagnosis of the cold thyroid nodule. *Semin Nucl Med* 1:390-396, 1971.
9. SAMUELS BI: Thermography: a valuable tool in the detection of thyroid disease. *Radiology* 102:59-62, 1972.
10. HORST W, RÖSLER H, SCHNEIDER C, ET AL: 306 cases of toxic adenoma: clinical aspects, findings in radioiodine diagnostics, radiochromotography and histology; results of ^{131}I and surgical treatment. *J Nucl Med* 8:515-528, 1967.
11. FERRAZ A, MEDEIROS-NETO GA, TOLEDO AC, ET AL: Autonomous thyroid nodules: I. A Clinical classification and the use of a diagnostic index. *J Nucl Med* 13(pt 2):733-737, 1972.
12. HAMBURGER JI, MEIER DA: Nontoxic autonomously functioning thyroid adenomata-therapeutic considerations, abstracted. *J Nucl Med* 14:404, 1973.
13. MCCORMACK KR, SHELINE GE: Long-term studies of solitary autonomous thyroid nodules. *J Nucl Med* 8:701-708, 1967.