

The Adult Respiratory Distress Syndrome: Clinical Features, Factors Influencing Prognosis and Principles of Management*

THOMAS L. PETTY, M.D., F.C.C.P.

Associate Professor of Medicine and Head, Division of Pulmonary Diseases, University of Colorado Medical Center, Denver, Colorado

DAVID G. ASHBAUGH, M.D.

Associate Professor of Surgery, University of Colorado Medical Center, Denver, Colorado

The adult respiratory distress syndrome (ARDS) is an important and common medical emergency and is likely to occur in all hospitals dealing in respiratory care. The syndrome occurs from a variety of diffuse pulmonary injuries which are either direct or indirect attacks on the lung parenchyma. Once lung damage occurs, exudation of fluid and loss of surfactant activity leads to impaired gas exchange and reduced pulmonary compliance. The syndrome presents clinically as marked respiratory distress, tachypnea, cyanosis, refractory hypoxemia, high inflation pressure requirements during ventilatory support, diffuse alveolar infiltrates on chest roentgenograms and postmortem pulmonary congestion, hyperemia and hyaline membrane formation. Principles of management include adequate support of oxygen transport, ventilation, and circulation employing volume respirators with positive end-expiratory pressure (PEEP). During the support phase, further pulmonary injury in terms of fluid overload, oxygen toxicity, or infection, must be prevented or treated. When these principles of

management are followed, recovery often occurs in spite of severe pulmonary injury as indicated by the first two illustrative cases.

Recent experience has indicated that a variety of direct or indirect pulmonary insults can lead to a clinical picture of marked respiratory distress, diffuse pulmonary infiltration on x-ray examination, impaired effective pulmonary compliance, marked impairment in oxygen transport¹ in spite of ventilatory assistance, pulmonary congestion, and hyaline membrane formation (1). This clinical picture, which arises from unrelated pulmonary insults, has been termed the adult respiratory distress syndrome (ARDS) (1). The response of the lung to a variety of pulmonary insults has been the subject of a recent conference sponsored by the National Academy of Sciences. It is apparent on reviewing the conference proceedings that this clinical syndrome is encountered frequently in both civilian and military hospitals (9).

This report redescribes the adult respiratory distress syndrome and discusses factors which in-

* Presented by Dr. Petty at the Symposium on Respiratory Failure, May 25, 1972, at Richmond, Virginia. Reprinted with permission from *Chest*, Volume 60, pp. 233-239, September, 1971. Reprint requests to Thomas L. Petty, M.D., 4200 East Ninth, Denver, Colorado 80220.

¹ Impaired oxygen transport is defined as an increased inspired-arteriolar oxygen tension difference (similar to increased alveolar-arterial tension difference). Normally this is approximately 50 mm Hg (difference between inspired and arterial tensions with an adequate alveolar ventilation for CO₂).

fluence prognosis and presents principles of management.

The Clinical Syndrome. Patients with this syndrome suddenly develop marked tachypnea, dyspnea, and cyanosis which is refractory not only to nasal oxygen but also to intermittent positive pressure breathing (1, 2). Chest x-ray films show diffuse alveolar infiltration, usually with a normal cardiac silhouette (see x-ray films of three illustrative cases). The difference between inspired and arterial oxygen tensions is markedly increased (1, 2) (often 200 to 500 mm Hg) representing a large right to left shunt (20). It must be stressed that the original injury leading to this problem may be direct chest trauma, indirect trauma such as shock associated with abdominal wounds, ruptured spleen, drug ingestions, massive aspiration pneumonia, and acute pancreatitis with shock (1). Similar clinical entities include the syndrome of prolonged cardiopulmonary bypass (4), congestive atelectasis (6), viral pneumonia (17), and massive fat embolism (3).

In addition, this clinical syndrome has been equated with oxygen toxicity (16) or use of a ventilator *per se*, and the unfortunate term "respirator lung" has been added to the already confusing literature concerning the subject (7).

In spite of marked pulmonary damage and impaired oxygen transport, however, modern management has proved to be effective in certain patients². Fatalities are usually a result of septic com-

² See illustrative case examples. Our total series will be the subject of a subsequent report.

plications including pneumonia with gram-negative organisms, lung abscess, and occasional septicemia. The outcome is dependent upon the nature and degree of the original pulmonary injury and the presence or absence of further superimposed pulmonary damage (1, 2).

Case Reports. The following three illustrative cases represent two basic types of clinical response which may occur, that is, rapid resolution with recovery or progressive pulmonary insufficiency leading to interstitial fibrosis and death.

Case 1. The patient, a 21-year-old student, became ill following a bout of heavy drinking which led to unconsciousness after he attempted to prepare some food by cooking on a gas stove. The patient later awakened in a smoke filled room and vomited. He became extremely short of breath with a cough productive of reddish purulent sputum. Because of progressive difficulty with breathing, the patient entered the emergency room. No industrial exposure was reported by relatives. On examination the patient was in marked respiratory distress with tachypnea, cyanosis, and moderate supraclavicular retractions. His pulse was 110, respirations 38, temperature 38.8°C, and blood pressure 103/70. The chest was symmetrical and moist coarse rales were heard throughout both lung fields with some decrease in breath sounds. The results of cardiac examination were normal. The chest x-ray picture revealed diffuse bilateral infiltrates (fig. 1). (Note that in each figure factors of oxygen administration, that is, nasal O₂ liter flow or oxygen tension on a ventilator—P_IO₂—are compared to simul-

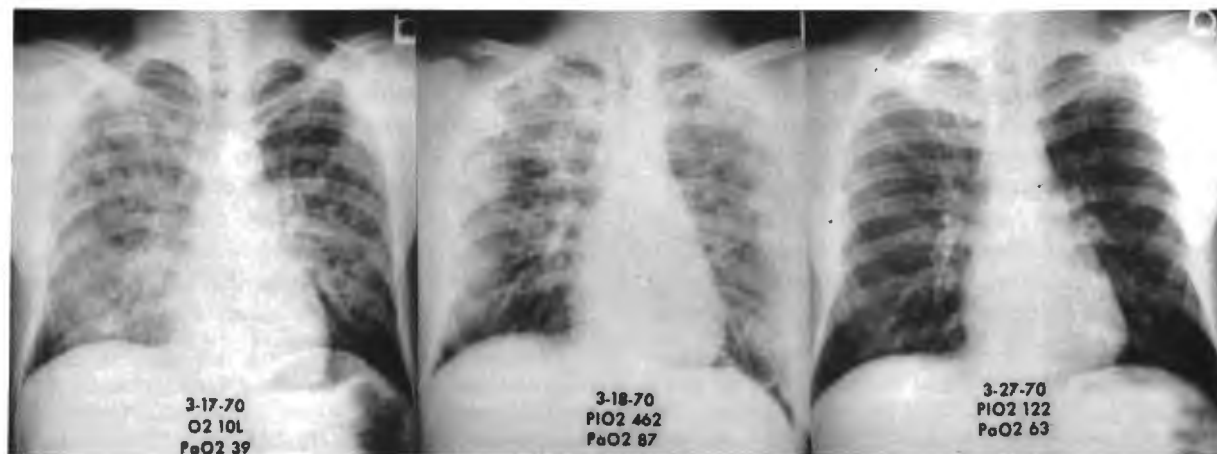


Fig. 1 (left)—Chest roentgenograms on admission. Note oxygen liter flow with concomitant arterial oxygen tensions (Case 1). Fig. 2 (center)—X-ray clearing on second hospital day. High inspired oxygen tension (462) required for adequate arterial oxygenation (Case 1). Fig. 3 (right)—Further x-ray clearing and near normal oxygen transport (Case 1).

taneous arterial oxygen tensions— $P_{a_{O_2}}$). The difference between $P_{i_{O_2}}$ and $P_{a_{O_2}}$ is an index of impaired gas transport across the lung (10) (see Discussion). Initial arterial analyses revealed $P_{a_{O_2}}$, 33 mm; carbon dioxide tension ($P_{a_{CO_2}}$) 35 mm and pH 7.435, breathing air (Table 1). With 10 liters of nasal oxygen the $P_{a_{O_2}}$ increased only to 38.5. The hematocrit was 52%,³ white cell count was 21,000.

The clinical impression was smoke inhalation and possible aspiration pneumonia. In view of the profound hypoxemia which was refractory to nasal oxygen, an endotracheal tube was placed and a tracheostomy performed. With 80% inspired oxygen fraction the $P_{a_{O_2}}$ increased to 88 mm Hg (Table 1). On the next day $P_{a_{O_2}}$ was 87 with 80% inspired oxygen fraction. The x-ray picture showed slight clearing (fig. 2). With 10 cm positive end-expiratory pressure (PEEP) $P_{a_{O_2}}$ elevated to 119⁴ (Table 1). This allowed the inspired oxygen fraction to be reduced to 70% providing a $P_{a_{O_2}}$ of 85 and later in the afternoon 104, indicating improved oxygen transport (Table 1). In addition to the ventilatory management, the patient also received nafcillin, 8 g daily, hydrocortisone 600 mg intravenously daily, and kanamycin 500 mg twice daily in view of the possibility of aspiration pneumonia. On the following day, the patient's $P_{a_{O_2}}$ was 92 with an inspired fraction of 60% via the ventilator. Rapid clearing of the pulmonary infiltrates occurred by the third hospital day and the patient made an uneventful recovery (data in Table 1 indicates marked improvement in the $P_{i_{O_2}}$ - $P_{a_{O_2}}$ difference which became nearly normal on March 27, 1970; figure 3: normal $P_{a_{O_2}}$ is 65 to 75 mm Hg).

Comment. This case represents diffuse pulmonary injury from smoke inhalation and aspiration of gastric contents. Corticosteroid drugs are generally considered desirable to combat the chemical pneumonitis from aspiration of gastrointestinal content (12) and are also considered useful in smoke inhalation. The antibiotics were used in the belief that some bacterial infection may have been present. Following initial refractory cyanosis, the patient could be adequately oxygenated with a high oxygen fraction (70%) and positive end-expiratory pressure on exhalation (see Discussion). An uneventful recovery

³ Upper normal for Denver although in this case this value may be representative of some degree of hemoconcentration.

⁴ Ohio 560 Respirator, Ohio Medical Products, Madison, Wisconsin.

TABLE 1.
INSPIRED AND ARTERIAL BLOOD GAS TENSIONS
DURING MANAGEMENT (CASE 1)

	Admission	3 Hr*	24 Hr*	2 Days*	7 Days
Oxygen	10 L	80%	80%	60%	20.9%
$P_{i_{O_2}}$		460	462	353	121
$P_{a_{O_2}}$	39	88	119	92	59
$P_{a_{CO_2}}$	35	38	40	38	37

* Ventilatory assistance with PEEP—See text.

followed and the patient remains well five months after the original pulmonary insult.

Case 2. Patient 2, a 34-year-old white woman, was admitted via the emergency room with a history of ingestion of an unknown quantity of phenobarbital and chlordiazepoxide along with tablets composed of aspirin and phenacetin some 30 hours before admission. The patient had vomited and aspirated according to her husband. She had a history of drug overdose on two occasions in the past.

On physical examination she was found to be semi-stuporous and deeply cyanosed. Her blood pressure was 110/70, temperature 38.2°C, respirations 30 and labored. Examination of the chest revealed scattered bilateral rales in both axillary areas. Cardiac examination was normal. No edema was present. Chest x-ray picture (fig. 4) revealed extensive bilateral pulmonary infiltrates. Initial blood gas values revealed $P_{a_{O_2}}$ (on air) 34.5, $P_{a_{CO_2}}$ 23.5, pH 7.51; with 10 liters of oxygen (Table 2), $P_{a_{O_2}}$ 40, $P_{a_{CO_2}}$ 23, pH 7.49.

In addition, hematocrit was 32%, white cell count 21,300 with 95% polymorphonuclear leukocytes, BUN 13 mg% and creatinine 1.3%. The patient was managed in the intensive care unit following tracheostomy with a volume cycled ventilator and initially required oxygen fractions of 80% to

TABLE 2.
INSPIRED AND ARTERIAL BLOOD GAS TENSIONS
DURING MANAGEMENT (CASE 2)

	Admission	1 Hr*	3 Hr*	2 Days	4 Days	7 Days
Oxygen	10 L	100%	80%	50%	30%	20.9%
$P_{i_{O_2}}$		585	468	294	176	121
$P_{a_{O_2}}$	40	70	116	159	92	75
$P_{a_{CO_2}}$	23	33	37	30	26	30

* Ventilatory Assistance with PEEP—See text.

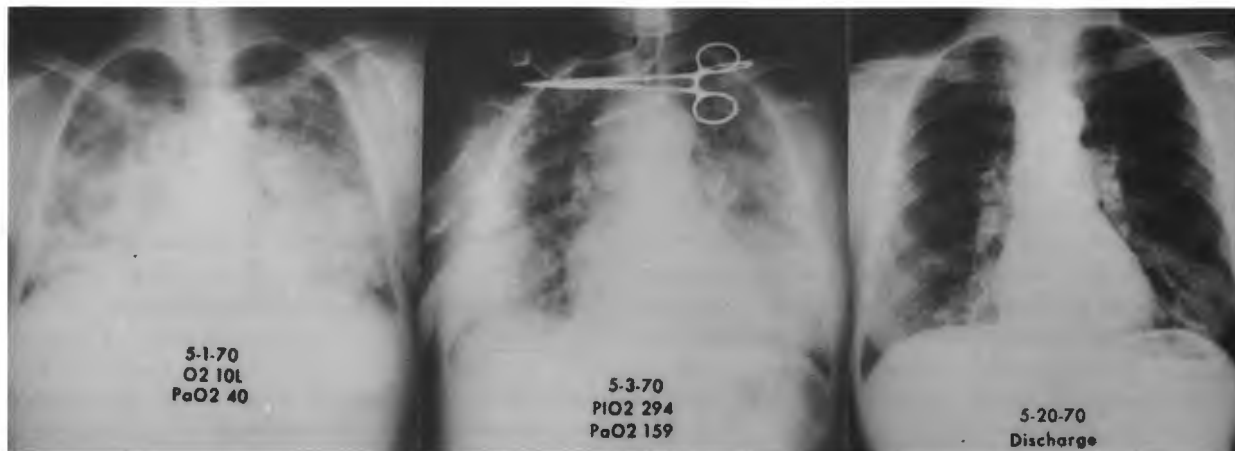

Fig. 4 (left)—Bilateral pulmonary infiltration on admission. Severe hypoxemia— PaO_2 , 40 in spite of 10 L nasal oxygen flow (Case 2). Fig. 5 (center)—Clearing pulmonary infiltrate and evidence of improved oxygen transport (PiO_2 , 294; PaO_2 , 159) (Case 2). Fig. 6 (right)—Normal chest x-ray on discharge (Case 2).

100% to effect an adequate arterial oxygen tension (Table 2). In addition, she received intravenous hydrocortisone 100 mg three times daily; cephalosporin and kanamycin were given for presumed aspiration pneumonia. Her temperature elevated to 39.2°C on the first hospital day. On the second hospital day elevated arterial oxygen tensions were produced by an oxygen fraction of 50% (PiO_2 , 294—Table 2), and the oxygen fraction was lowered to 30%. Marked improvement was noted upon x-ray examination along with improved oxygen transport (fig. 5). Thereafter an uneventful recovery occurred over the next four days. The ventilator was discontinued on the fifth hospital day, and the patient made further progress and was discharged on the 20th hospital day (fig. 6).

Comment. Factors of pulmonary injury included aspiration of gastric contents following drug ingestion. The diffuse pulmonary damage presented the picture of pulmonary edema. A longer period of impaired oxygen transport was present than in case 1, and at times 100% oxygen was needed to effect an adequate arterial oxygen tension. Evidence of improved gas transport occurred, and a complete recovery was achieved nonetheless.

Case 3. This patient, a 34-year-old man, was transferred to Colorado General Hospital by air evacuation from a resort community. The patient had been found comatose on the floor of his rooming house, having vomited and was hospitalized in a local hospital with extensive bronchopneumonia

as well as numerous rib fractures from unexplained chest trauma. Numerous bruises of the chest were found. A tracheostomy was performed and *Staphylococcus aureus*, coagulase positive was isolated from the sputum. The patient was initially managed in the community with a pressure cycled respirator on oxygen, which presumably provided high oxygen fractions (10). It was also believed, by a careful scrutiny of input and output records, that fluid overload had occurred. The patient was managed with furosemide which produced a brisk diuresis. Because of a worsening chest x-ray picture, high fever, and difficulty providing adequate arterial oxygenation, the patient was transferred to Colorado General Hospital seven days after admission to the community hospital. On admission, the patient was alert and cooperative and followed commands well. His blood pressure 150/85, pulse 120, temperature 40°C , respirations controlled at 20. Chest examination revealed coarse rhonchi and scattered rales throughout. No cardiac abnormalities were present. A cardiac gallop rhythm was not observed. The chest x-ray film (fig. 7) showed diffuse bilateral alveolar infiltration.

Initial arterial blood gases (Table 3) on the respirator revealed PaO_2 , 49, produced by an inspired oxygen fraction of 70% (simultaneously PaO_2 , 32, pH 7.42). With use of 10 cm positive end-expiratory pressure by artificial ventilator, the pulmonary oxygen transport improved as evidenced by PaO_2 , 72, 24 hours later at the same inspired oxygen fraction (70%). These values are representative of numerous

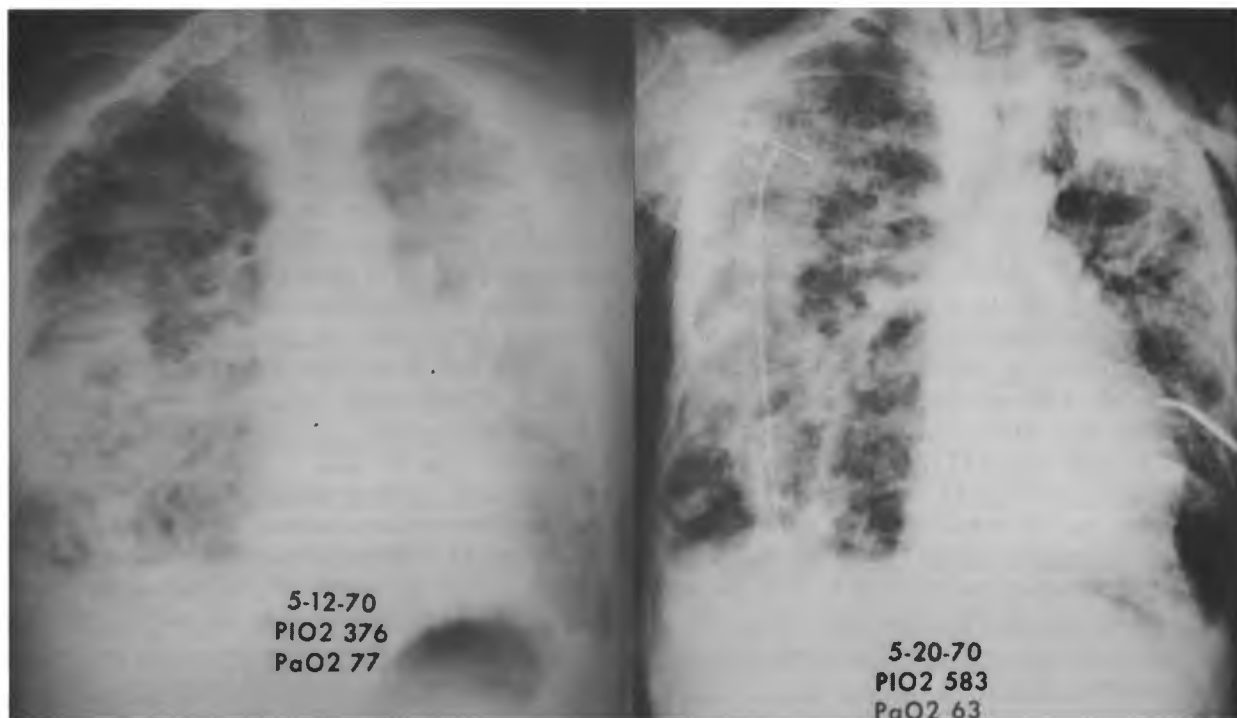


Fig. 7 (left)—Massive bilateral pulmonary infiltrations on admission with severe impairment in oxygen transport (P_{iO_2} , 376; P_{aO_2} , 77) (Case 3). Fig. 8 (right)—Terminal chest x-ray film shows diffuse pulmonary fibrosis and evidence of right-sided pneumothorax and tube placement.

gas tensions and fractions observed throughout the day. Arterial oxygen tensions as high as 86 were initially achieved.

Antibiotics were continued (ampicillin and kanamycin) and large doses of corticosteroid drugs were given (see Discussion). Strict avoidance of fluid overload was practiced. In spite of continued respiratory support, a severe impairment of oxygen transport across the lung remained, and on the fifth hospital day, or 12 days after the original pulmonary injury, 65% inspired oxygen fraction was

still required to provide a P_{aO_2} of 77 mm Hg in spite of positive end-expiratory pressure (Table 3).

The chest x-ray film (fig. 8) did not show resolution, and just before death, 100% oxygen was required to provide an acceptable P_{aO_2} of 63. The patient died following a pneumothorax (fig. 8).

Comment. The original injury was pneumonia, presumably bacterial, but also aspiration pneumonia was a possibility. Further injury may have been high oxygen ventilation in the original hospital as well as fluid overload (see Discussion).

At no time in our institution did excessive arterial oxygenation occur, and all efforts were made to minimize the inspired oxygen tension that would still provide adequate arterial oxygenation. Nonetheless, the patient's course was one of progressive pulmonary infiltration, increasing pressure requirements on the ventilator (up to 75 cm inflation pressure⁵) for a tidal volume of 700 ml (effective compliance 9 ml per centimeter normal; 40 to 60 ml per centimeter). Permission for postmortem exami-

TABLE 3.
INSPIRED AND ARTERIAL BLOOD GAS TENSIONS
DURING MANAGEMENT (CASE 3)

	Admission	24 Hr*	5 Days*	12 Days*
Oxygen	70%	70%	65%	100%
P_{iO_2}	405	404	376	583
P_{aO_2}	49	72	77	63
P_{aCO_2}	37	38	44	46

* Ventilatory Assistance with PEEP—See text.

⁵ Ohio 560 Respirator, Ohio Medical Products, Madison, Wisconsin.

nation was not obtained. The x-ray picture and markedly reduced effective compliance suggested the development of pulmonary fibrosis, a response which commonly occurs in fatal forms of this syndrome.

Theories of Pathogenesis. It appears from our clinical experience of over 40 cases, as well as the three illustrative cases cited in this report, that the adult respiratory distress syndrome is basically a nonspecific response to a variety of pulmonary injuries. The injury may be direct chest trauma or the pulmonary effects of other injurious agents as well as shock (9). After damage to the alveolar capillary membrane, very likely, exudation of fluid occurs into the alveolar spaces (8). This causes interference with surfactant activity (8). It is likely a combination of alveolar and/or interstitial fluid as well as the effects of decreased surfactant activity leads to poor effective compliance demonstrated by high pressure requirements for an adequate tidal volume as illustrated by case 3, and a problem common to all three illustrative cases.

The ultimate outcome is dependent upon three factors: a) the degree of original injury, b) the effectiveness of respiratory support and c) the prevention of further pulmonary injury. The majority of patients can be adequately supported by the use of constant volume ventilators through use of the controls described below. It is likely that fluid overload may compound the problem. Once the alveolar capillary barrier is injured, and vascular integrity lost, expansion of the circulating blood volume may allow outpouring of fluid into alveolar spaces with resulting pulmonary edema and impairment in oxygen transport.

An additional contributing factor in the development of progressive stiff lungs is the possibility of oxygen toxicity (11, 19). All of the facts on oxygen toxicity are not known at the present time; however, the weight of evidence suggests that long-term exposures of oxygen in fractions higher than 40% to 50% in certain cases, may be harmful (11, 19). On the other hand, our experience, as well as that of others, has shown that in states of profound hypoxemia, 100% oxygen inspired fraction may be required for periods of several days with recovery. Questions remain concerning the nature of the damaging effects of high oxygen and whether this is a function of alveolar or arterial oxygen tension. Recent evidence suggests that at atmospheric pressures high alveolar oxygen tensions are potentially

damaging (15). In principle, one should minimize the inhaled oxygen fraction as much as possible (see below).

Superimposed infection represents a common and serious complication of acute respiratory distress. Sepsis from burn wounds or peritonitis may precipitate respiratory distress, and if the infection cannot be controlled, death may occur even though respiratory failure is adequately treated. In patients surviving for longer periods of time, secondary bacterial pneumonias are likely to occur, and these are often due to resistant gram-negative organisms such as *Pseudomonas aeruginosa* and *Klebsiella-Aerobacter* species.

While this problem continues to be a major obstacle in the care of patients, it can be minimized by proper precautions and use of antibiotics. Careful and repeated cultures of sputum, urine, stool, and wounds alert the physician to early changes in flora and provide sound data for the selection of appropriate antibiotics. Narrow spectrum highly specific antibiotics are preferred over broad spectrum antibiotics. The latter will often eradicate normal flora and allow secondary invasion of highly resistant organisms. Attempts at isolation of these patients are of little value since the organisms causing pulmonary infection are almost always of endogenous origin from another infected site.

Principles of Management. Principles of management are listed in Table 4. Management includes support of ventilation and gas exchange, minimizing further pulmonary damage, and ancillary therapeutic maneuvers.

We have learned that high tidal volume ventilation with both inspiratory plateau and positive end-expiratory pressure (PEEP) improves oxygen transport across the lung (see figure 9 for pressure wave form of inspiratory plateau and PEEP compared

TABLE 4.

MANAGEMENT PRINCIPLES IN ARDS

1. Prevent alveolar collapse and maintain oxygenation
 - a. Tracheostomy
 - b. Volume respirator
 - c. Oxygen control
 - d. Positive end-expiratory pressure (PEEP)
2. Prevent further injury
 - a. Oxygen control
 - b. Fluid restriction
 - c. Antibiotics for specific infections
 - d. Corticosteroid drugs

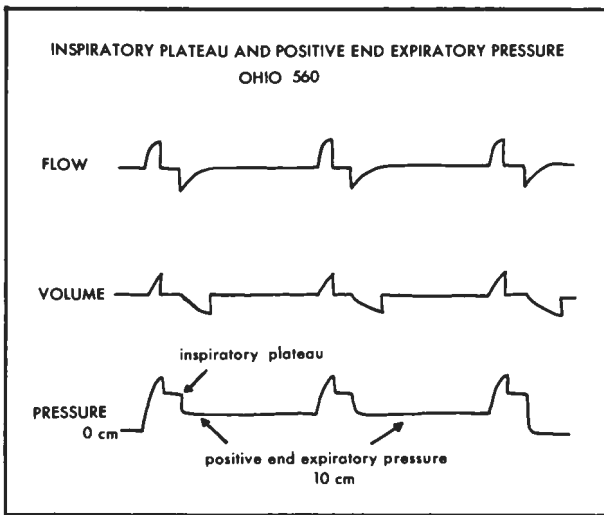


Fig. 9—Modified pressure wave forms showing inspiratory plateau and positive end-expiratory pressure (arrows).

to normal pressure wave form, figure 10). The effects of inspiratory plateau and positive end-expiratory pressure are additive in certain patients; this is demonstrated in Table 5.

Our clinical (1, 2) and laboratory experience

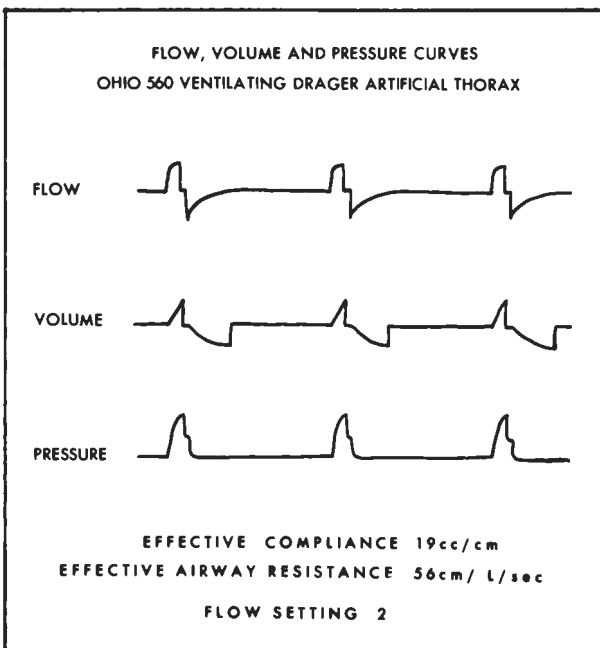


Fig. 10—Flow and pressure wave forms using Ohio 560 ventilator and artificial thorax. Note square wave form (flow); volume signal electrically integrated from flow signal. Inspiratory flow wave oriented upward and expiratory flow wave downward.

TABLE 5.
ADULT RESPIRATORY DISTRESS SYNDROME
(IMPROVED OXYGEN TRANSPORT WITH INSPIRATORY
PRESSURE* AND POSITIVE END-EXPIRATORY
PRESSURE—PEEP)

44-year-old man—multiple trauma, liver laceration 40 units whole blood, 8 liters Ringer's lactate

	2 P.M. in OR	4 P.M. Vol Resp 1000 ml TV	4:30 P.M. + Insp Plateau 2 sec	5 P.M. + Insp Hold Positive End-exp Plateau 10 cm
P _I O ₂	570	345	345	345
P _a O ₂	81	82	101	151
P _a CO ₂	27	25	23	25

* Courtesy of D. Boyd Bigelow, M.D., Chief of Respiratory Diseases, St. Anthony's Hospital, Denver, Colorado.

(20) indicates that PEEP⁶ is fundamental in improving oxygenation by decreasing the alveolar arterial oxygen tension difference. The inspiratory plateau may have similar value, but this has provided a lesser improvement in oxygenation than PEEP in our recent experience. This ventilator capability is only available as a standard feature on one machine in common use today⁷.

PEEP will allow improved oxygen transport of lower inspired oxygen fractions on most occasions (1, 2). It is likely that the use of high pressure constant volume ventilation, inspiratory plateau, and end-expiratory pressure all provide local tamponade of circulation to areas of poor ventilation, and these techniques maintain alveolar stability by preventing alveolar collapse on expiration (8, 14). It is clear that PEEP increases the functional residual capacity and reduces right to left shunting (13, 14, 20). End-expiratory pressures of 5 to 15 cm H₂O are used, and in clinical situations no apparent adverse effect on venous return and cardiac output can be noticed. It is likely that this small back pressure is dissipated across the stiffened lung and therefore is not "felt" in the pulmonary circulation (20).

⁶ PEEP has also been termed CPPB (continuous positive pressure breathing) in earlier reports. We now believe CPPB is a confusing term since this designation was first advanced to refer to breathing against a fixed pressure head, and did not originally refer to both positive inspiratory and expiratory pressures by a ventilator (5).

⁷ Ohio 560 Respirator, Ohio Medical Products, Madison, Wisconsin.

In addition, the possibility of fluid overload should be minimized by recognizing the tendency toward fluid retention during artificial ventilation and the possibility of transudation of fluid into alveolar spaces in the face of an expanded circulatory volume (18).

Clinical experience indicates the use of corticosteroid drugs is highly beneficial in patients with the adult respiratory distress syndrome. Evidence supporting the use of corticosteroid drugs is based both on theoretic considerations and clinical observations. Corticosteroid drugs are known to combat the effect of fat found in the lungs in the respiratory distress syndrome associated with massive trauma (9). Corticosteroids have been shown to be effective both clinically and in laboratory models of fat embolism (3, 21). Also, evidence that corticosteroid drugs inhibit adherence of leukocytes to the pulmonary vascular bed in hemorrhagic shock has recently been presented (22). Adherent leukocytes may cause pulmonary damage by the release of proteolytic enzymes. Finally, corticosteroids may enhance the secretion of surfactant, which is invariably absent in lungs with the adult respiratory distress syndrome (1) and which is needed to maintain alveolar stability (8).

Specific pulmonary and other infections must be managed with appropriate antibiotics. We believe corticosteroids are effective in aspiration pneumonia probably by correcting the inflammatory effects of acid gastric juices on the lung (12). Penicillin is effective against mouth organisms and is probably the antibiotic of choice. Kanamycin is effective against a broad spectrum of gram-negative organisms.

REFERENCES

1. ASHBAUGH, D. G., BIGELOW, D. B., PETTY, T. L., *et al.* Acute respiratory distress in adults. *Lancet* 2:319, 1967.
2. ASHBAUGH, D. G., PETTY, T. L., BIGELOW, D. B., *et al.* Continuous positive pressure breathing (CPPB) in adult respiratory distress syndrome. *J. Thorac. Cardiovasc. Surg.* 57:31, 1969.
3. ASHBAUGH, D. G. AND PETTY, T. L. The use of corticosteroids in the treatment of respiratory failure associated with massive fat embolism. *Surg. Gynec. Obstet.* 23:655, 1966.
4. BAER, D. M. AND OSBORN, J. J. The post perfusion pulmonary congestion syndrome. *Amer. J. Clin. Path.* 34:442, 1960.
5. BARACH, A. L., MARTIN, J., AND ECKMAN, M. Positive pressure respiration and its application to the treatment of acute pulmonary edema. *Ann. Intern. Med.* 12:754, 1938.
6. BERRY, R. E. L. AND SANISLOW, C. A. Clinical manifestations and treatment of congestive atelectasis. *Arch. Surg. (Chicago)* 87:153, 1963.
7. Case Records of the Massachusetts General Hospital. *New Eng. J. Med.* 276:401, 1967.
8. CLEMENTS, J. A. Pulmonary surfactant. *Amer. Rev. Resp. Dis.* 101:984, 1970.
9. EISEMAN, B. AND ASHBAUGH, D. G. (eds.) Pulmonary effects of nonthoracic trauma. *J. Trauma* 8:624, 1968.
10. HARRIS, T. M., GRAY, M., AND PETTY, T. L. Monitoring inspired oxygen pressure during mechanical ventilation. *JAMA* 206:2885, 1968.
11. HYDE, R. W. AND RAROSON, A. J. Unintentional iatrogenic oxygen pneumonitis-response to therapy. *Ann. Intern. Med.* 71:517, 1969.
12. LEWINSKI, A. Evaluation of methods employed in the treatment of the chemical pneumonitis of aspiration anesthesiology. *J. Anesth.* 26:37, 1965.
13. MCINTYRE, R. W., LAWS, A. K., AND RARNACHANDRAN, P. R. Positive expiratory pressure plateau: Improved gas exchange during mechanical ventilation. *Canad. Anaesth. Soc. J.* 16:477, 1969.
14. McMAHON, S. M. Modification of pulmonary shunting by end-expiratory pressure application in humans. Presented at the 13th Aspen Emphysema Conference, Aspen, Colorado, 1970.
15. MILLER, W. W., WALDHAUSEN, J. A., AND RASHKIND, W. J. Comparison of oxygen poisoning of the lung in cyanotic and acyanotic dogs. *New Eng. J. Med.* 282:943, 1970.
16. NASH, G., BLENNERHASSETT, J. B., AND PONTOPPIDAN, H. Pulmonary lesions associated with oxygen therapy and artificial ventilation. *New Eng. J. Med.* 276:368, 1967.

17. PETERSDORF, R. G., FASCO, J. J., HARTER, D. H., *et al.* Pulmonary infections complicating Asian influenza. *Arch. Intern. Med.* 103:262, 1959.
18. SLADIN, A., LAVER, M. B., AND PONTOPPIDAN, H. Pulmonary complications and water retention in prolonged mechanical ventilation. *New Eng. J. Med.* 279:448, 1968.
19. SOLOWAY, H. B., CASTILLO, Y., AND MARTIN, A. M. Adult hyaline membrane disease: relationship to oxygen therapy. *Ann. Surg.* 168:937, 1968.
20. UZAWA, T. AND ASHBAUGH, D. G. Continuous positive pressure breathing in acute hemorrhagic pulmonary edema. *J. Appl. Physiol.* 26:427, 1969.
21. WERKSBERGER, J. T. AND PELTIER, L. F. Fat embolism: The effect of corticosteroids on experimental fat embolism in the rat. *Surgery* 64:134, 1968.
22. WILSON, J. W. Leukocyte changes in the pulmonary circulation (a mechanism for acute pulmonary injury from various stimuli). Presented at the 13th Aspen Emphysema Conference, Aspen, Colorado, 1970.