



Trauma Resulting in Respiratory Failure*

JAMES W. BROOKS, M.D.

*Professor of Surgery, Thoracic and Cardiovascular,
Medical College of Virginia, Health Sciences Division of
Virginia Commonwealth University, Richmond, Virginia*

Respiratory failure may occur secondary to thoracic trauma. Several important conditions develop as a result of chest injuries and may occur singly, or in combination, in patients with injuries from any cause. Unrecognized and therefore without proper management, the results are necessarily poor. If recognized and their mode of production is understood, treatment may be simple. These conditions are:

- 1) Retention of bronchial secretions with inadequate pulmonary aeration caused by:
 - a. Severe chest wall pain
 - b. Abnormal mobility of the chest wall
 - c. Pulmonary contusion
 - d. Depression of the cough reflex, through
 1. Unconsciousness
 2. Excessive opiates
- 2) Open chest wall with "sucking wound" phenomenon
- 3) Flail chest wall
- 4) Pneumothorax, simple or tension
- 5) Hemothorax
- 6) Hemopneumothorax
- 7) Ruptured diaphragm
- 8) Ruptured bronchus
- 9) Non-pulmonary injuries causing marked ventilation problems

Ribs are the most frequently injured structures in the chest area and must be taken into consideration with nearly all thoracic trauma cases.

The presence or absence of preexisting pulmonary disease and the extent of injury will govern the amount of difficulty encountered after chest injury. A small injury may cause marked derangement of pulmonary function in the patient

having preexisting chronic pulmonary disease. Since adequate treatment of these conditions will correct the resulting cardio-respiratory disturbances and thereby aid in resuscitation of the patient, each condition will be discussed in some detail.

Chest wall pain may have serious consequences in injuries which otherwise would be of no great importance. Pain may effectively immobilize the chest wall, thereby making cough ineffectual. This results in retention of tracheobronchial secretions and/or aspirated material. The accumulation of such material in the bronchi interferes with pulmonary ventilation and leads to atelectasis and perhaps even to suppurative pneumonia. If inadequately treated, such patients may actually go on to asphyxiation. Recognition of such a situation is not difficult. Cough is ineffectual and auscultation reveals moist rales and/or rhonchi widely distributed over both lungs. Dyspnea and cyanosis may develop.

Treatment is directed toward relief of the chest wall pain and cleaning the airway of secretions. Adhesive strapping is inadvisable since it leads to poor ventilation, retained secretions, atelectasis, and pneumonia. Mild analgesics or cautious administration of narcotics is helpful. Voluntary, periodic cough and breathing exercises should be encouraged and advised. Added to these is the routine use of intermittent positive pressure breathing apparatus to assist full lung ventilation. Frequent position change will aid the normal drainage of the bronchi.

Patients with retained secretions should have immediate and repeated aspiration by nasotracheal catheter (fig. 1). Tracheal suction is easily done, and physicians treating patients with thoracic injuries must familiarize themselves with its technique. Using a fairly stiff, slightly curved,

* Presented by Dr. Brooks at the Symposium on Respiratory Failure, May 26, 1972, at Richmond, Virginia.

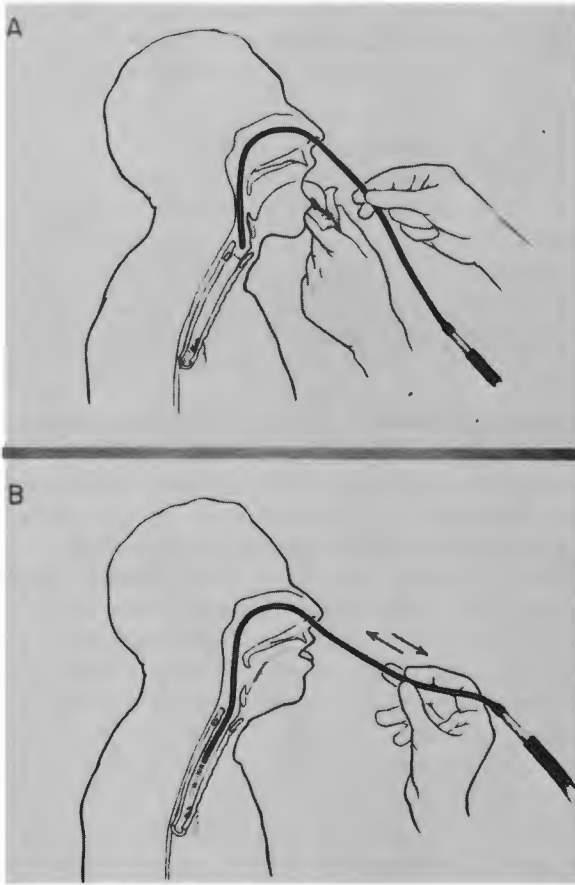


Fig. 1—A. Illustration of nasotracheal suction as an effective stimulus to cough. B. Suction is applied to the catheter for removal of resultant secretions.

catheter (#16-18 French), the patient is placed in the sitting or semi-sitting position with the back supported and the head and neck dorsally extended. The lubricated catheter is quickly passed through the nose into the pharynx without suction attached. The patient is instructed to take a deep breath and during inspiration the catheter is passed into the trachea. Success is signified by violent coughing and hoarseness. Suction is applied intermittently as the catheter is passed into the tracheobronchial tree.

In some patients effective aspiration can be accomplished only by means of the bronchoscope.

Oxygen is administered as an aid to these measures used to clean the airway of secretions but cannot serve as a substitute.

It should be stressed that opiates must be used with particular care in patients with exces-

sive bronchial secretions, especially in those who have difficulty in evacuating these secretions. Opiates reduce the cough reflex and slow or stop cilia action. They also slow or prevent patient activity, thus promoting stasis.

The importance of an open, adequate airway cannot be overemphasized. The temporary use of an orotracheal or nasotracheal tube (up to 72 hours) may be necessary and advisable in the early management of chest trauma cases. In patients with serious cervical or facial injury, or in any condition where suction or bronchoscopy is not feasible, or where excessive irritation has been produced by gas or smoke, it is advisable to perform a tracheostomy so that catheter aspiration can be adequately accomplished.

Open chest injuries produce profound disturbances in intrathoracic physiology. Because of the opening in the chest wall, negative intrapleural pressure is replaced by atmospheric pressure. A number of factors determine the severity of the effects on cardio-respiratory physiology, the most

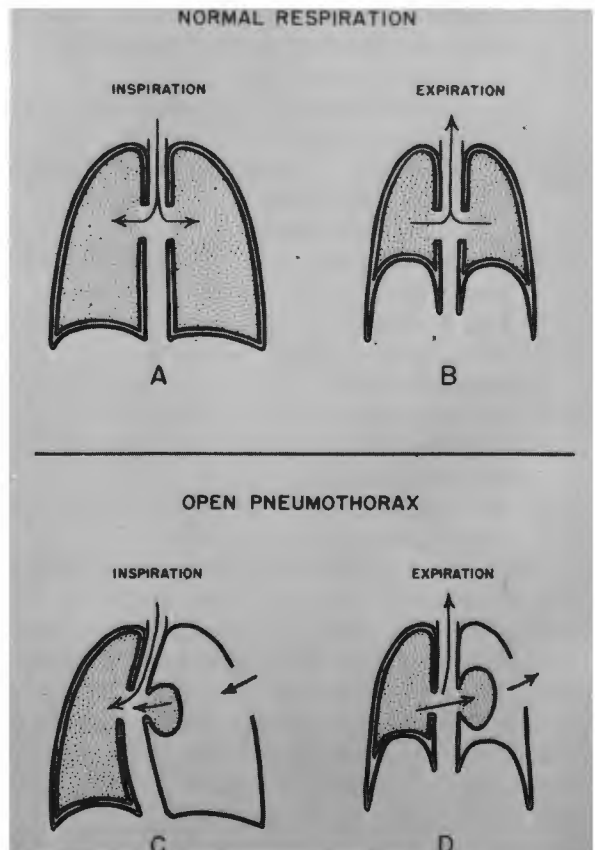


Fig. 2—Diagram of adverse effects of open pneumothorax.

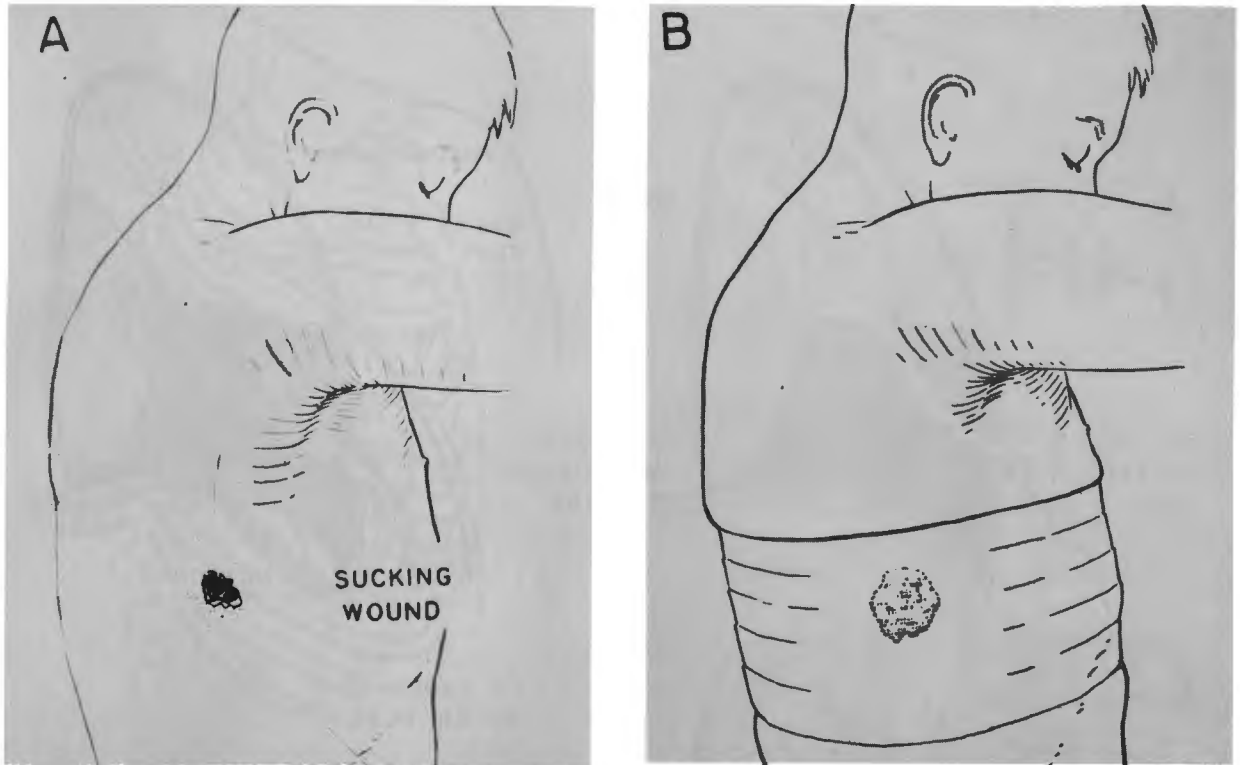


Fig. 3—A. Open thoracic wound. B. Emergency closure to stop sucking of air into pleural space.

important being the size of the opening in the chest wall. Small openings are, in general, tolerated better than large ones. If the size of the opening approaches or exceeds the size of the trachea, the patient may get into serious difficulty. Other important factors are the type of wound and the mobility of the mediastinum. If the wound allows air to enter the pleural space but does not permit it to escape, the patient's condition deteriorates more rapidly. Since the mediastinum is usually quite mobile, open pneumothorax generally leads to a shift of the mediastinum to the opposite side with compression of the contralateral lung as well as the lung on the side of injury. The swing of the mediastinum with each respiratory cycle causes poor air exchange and also interferes with the return of venous blood to the heart (fig. 2).

Open wounds must be effectively closed as soon as possible. As an emergency measure, a simple occlusive dressing of vaseline gauze is adequate (fig. 3). When the patient has been removed to a location where facilities are adequate, the wound is debrided and an airtight,

pleuro-muscular closure is done. A large catheter is inserted through an intercostal space into the pleural cavity and is connected to a water-seal arrangement (figs. 4 and 5).

If one or more ribs are broken in two or

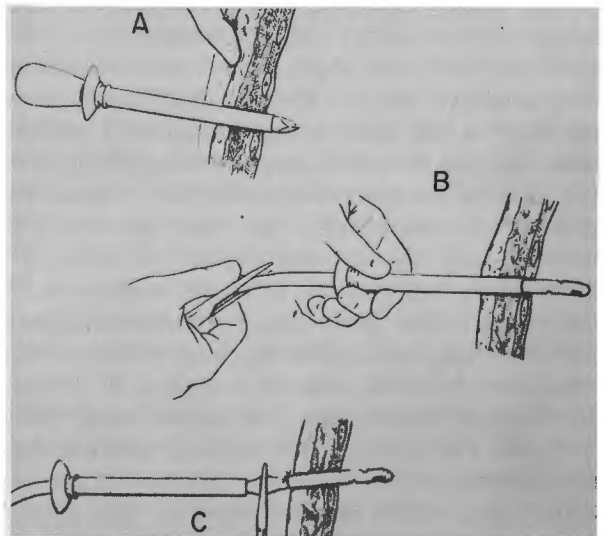


Fig. 4—Trochar method of inserting chest drainage tube.

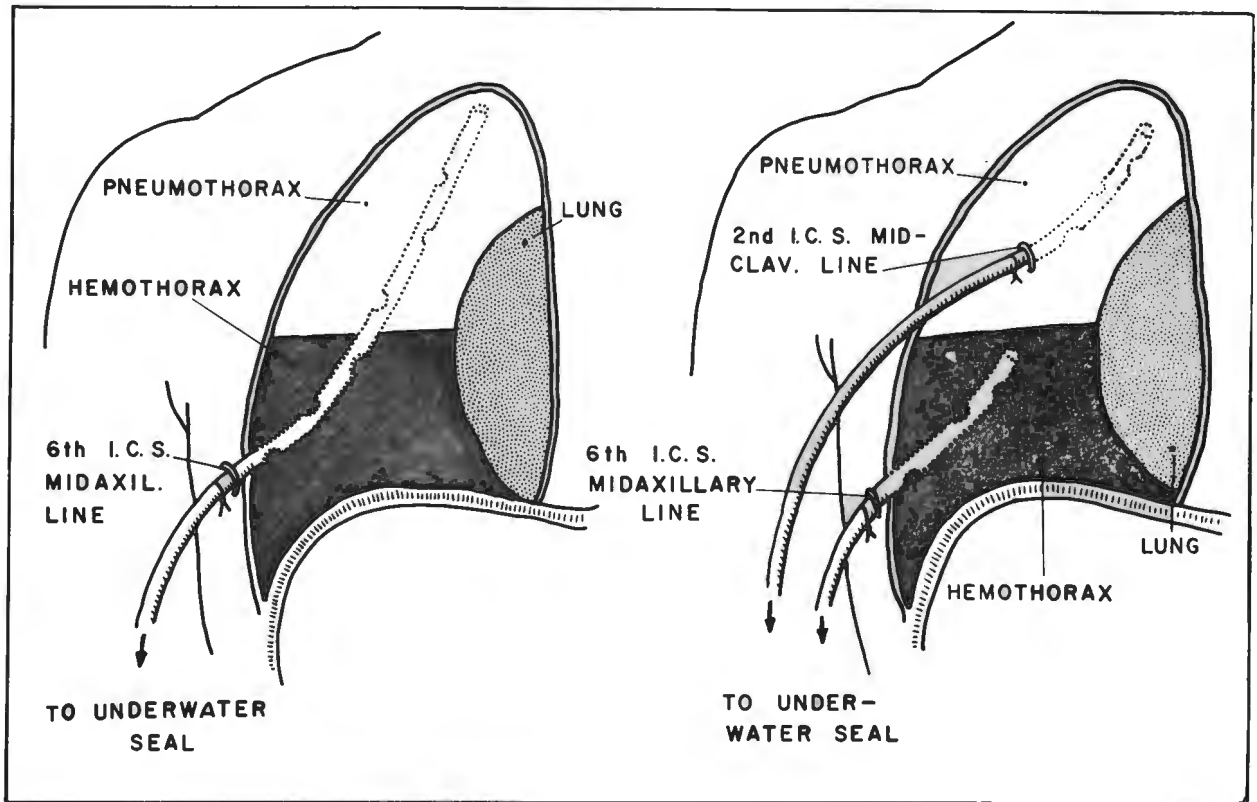


Fig. 5—Single tube and double tube drainage of air and fluid from the pleural space.

more places (fig. 6), the stability of the chest wall is interfered with and a "flail chest wall" results (fig. 7). This "flail" area results in paradoxical chest wall motion with respiration. The amount of respiratory difficulty resulting from an area of "flail" will depend upon the preexisting lung condition and the size of "flail." Small areas of "flail" in the chronic lung patient with emphysema may be most devastating. During inspiration, the unstable portion of chest wall will become depressed preventing fresh air from entering that area of lung involved and expressing "stale air" (low in O_2 and high in CO_2) to other areas of both lungs, thus preventing full access of fresh air to all lung areas. The opposite occurs during expiration, with the outward protrusion of the unstable chest wall section. This draws more "stale air" into the affected area of lung and prevents full exhaling of the "stale air." Not only are respiratory problems present with a "flail chest," but the swinging back and forth of a virgin mediastinum alters and slows blood flow into the right

side of the heart, in some cases bringing about shock due to poor inflow to the heart and thus poor outflow from the left ventricle. Paradoxical chest wall motion may be temporarily managed with a bulky dressing to stop paradoxical motion but is most effectively treated by tracheostomy and assisted ventilation with an intermittent positive pressure apparatus (figs. 8, 9, and 10).

Pneumothorax resulting from injury to the lung parenchyma allows escape of air through the visceral pleura into the pleural space and may cause severe, sudden respiratory distress. Traumatic collapse of lung is far more significant in bringing about respiratory failure in the individual with preexisting lung disease than in the healthy individual with no previous lung disease. This air should be promptly removed by the insertion of an intercostal drainage tube and connection to underwater suction drainage (fig. 11). In the post-traumatic patient, aspiration of pneumothorax which is greater than 15 to 20% is generally not satisfactory because it is not as com-

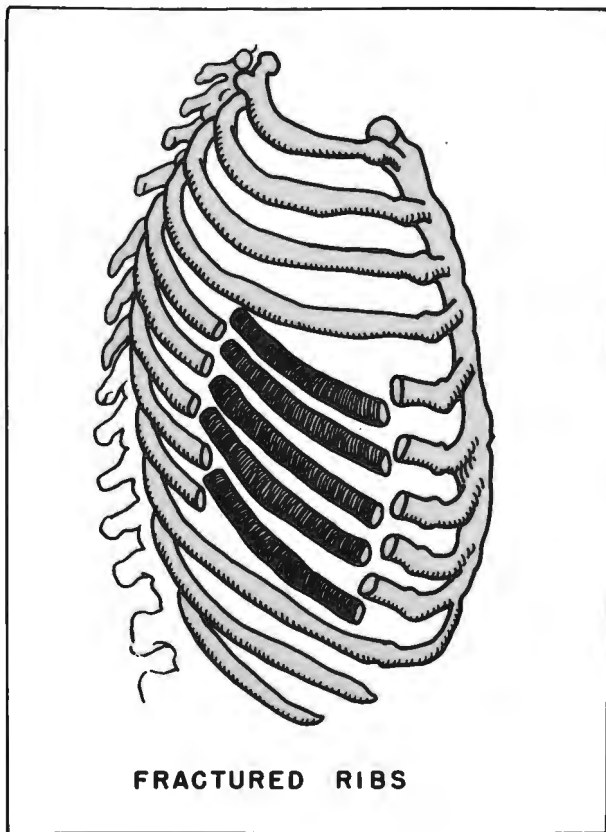


Fig. 6—Illustration of unstable section of chest wall due to multiple rib fractures.

plete, continuous, or efficient as the insertion of a tube for 24 to 72 hours. If the pneumothorax is bilateral, immediate prompt attention to the re-expansion of the lungs is essential. Tension pneumothorax results when a ball valve type of injury to the lung parenchyma occurs. Air can readily escape into the pleural space but not pass back and forth through the opening. Thus, positive pressure is built up in the side of injury such that there is total collapse of the ipsilateral lung, widening of the intercostal spaces, depression of the diaphragm, and displacement of the mediastinum causing further embarrassment to the more normal contralateral lung. Immediate relief of this tension is essential to prevent respiratory failure. Temporary benefit can be achieved using a large bore needle until the chest tube is assembled and inserted. Not only are the respiratory effects of tension pneumothorax most devastating but so are the circulatory effects with torsion of the great veins in the mediastinum diminishing flow of blood to the right heart and thus influencing out-

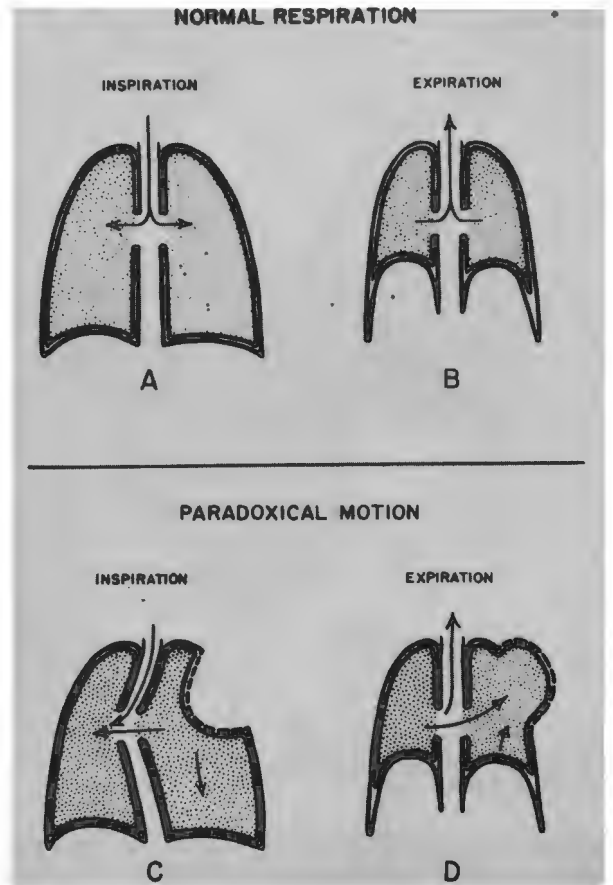


Fig. 7—Diagram showing effect flail chest wall.

flow from the left ventricle and shock because of poor output.

Loss of blood into the pleural space giving rise to a hemothorax may also cause the same problem as pneumothorax. The blood loss brings about peripheral circulatory problems, but in addition, the collapsed lung may lead to respiratory failure. The blood must be removed continuously to prevent pulmonary difficulties and replaced by transfusion for the circulatory effect (fig. 12). If blood loss exceeds 1,500 to 2,000 cc in an hour or two after the injury, thoracotomy is frequently necessary to bring about hemostasis and prevention of continued respiratory difficulties. If the blood from the pleural space is not properly, adequately, and efficiently removed, a coagulum will form over the collapsed lung causing its entrapment and possible need for decortication (fig. 13). Therefore, prompt removal is important for the immediate as well as long-term respiratory benefit.

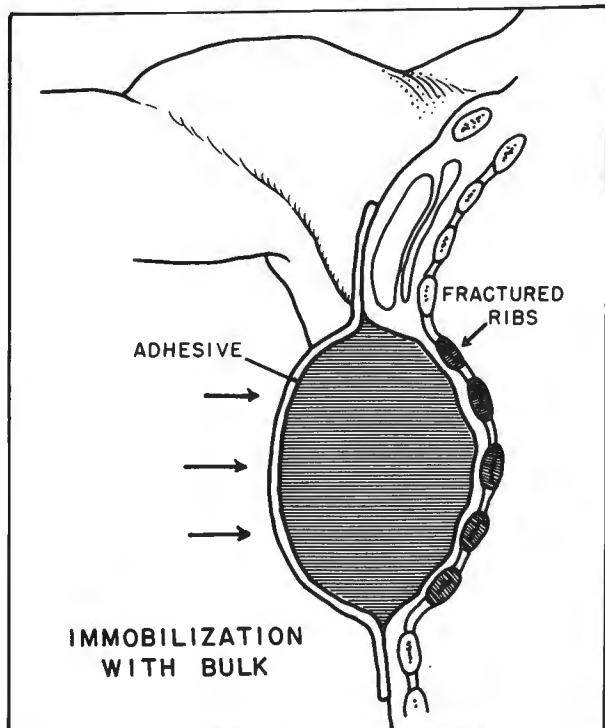


Fig. 8—Diagram of temporary bulky chest dressing to stabilize flail chest wall.

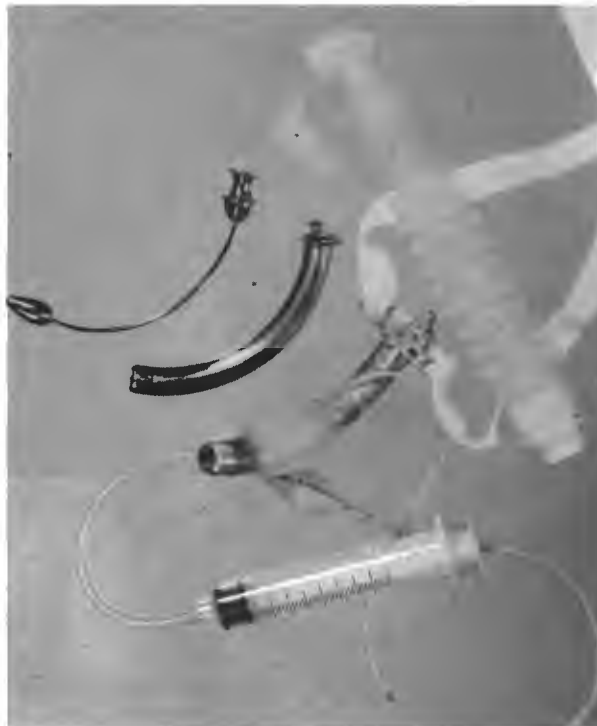

Fig. 9—Cuffed tracheostomy tube and apparatus necessary for connections to assisting intermittent positive pressure machine.

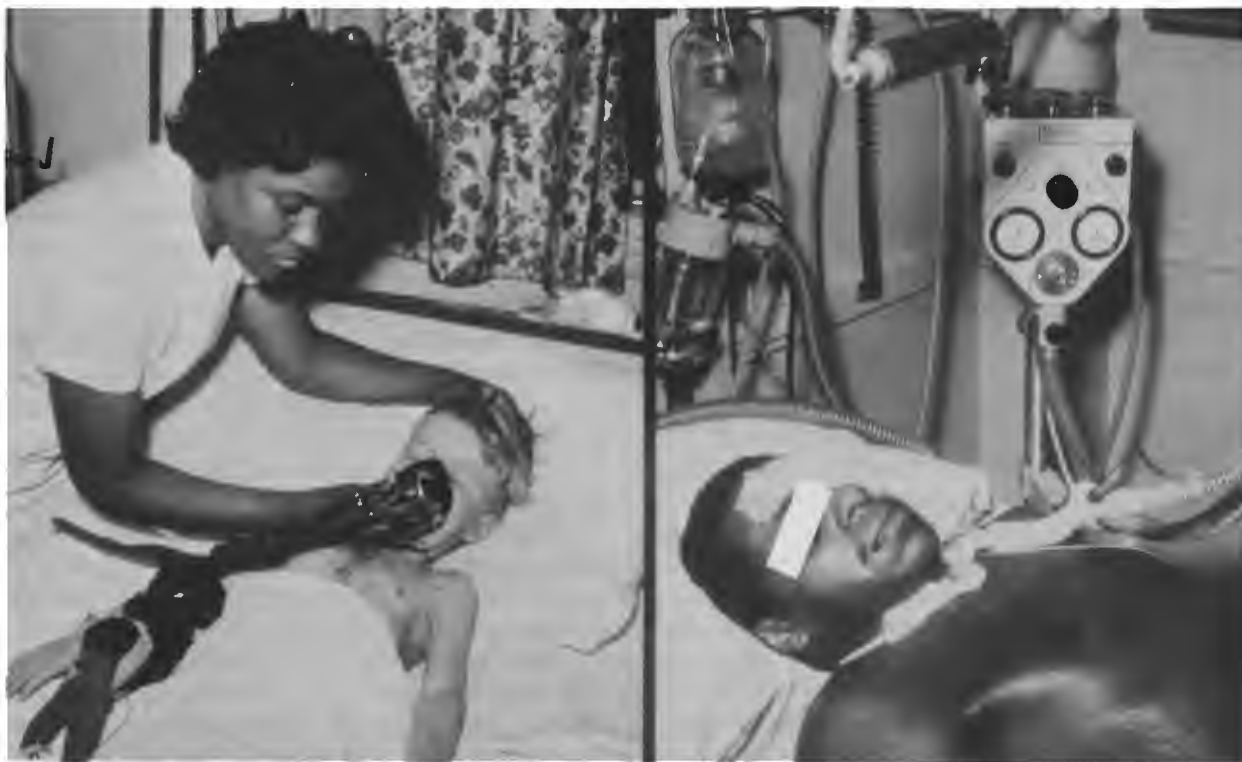

Fig. 10—Patients with face mask and tracheostomy attachments using intermittent positive pressure machines.

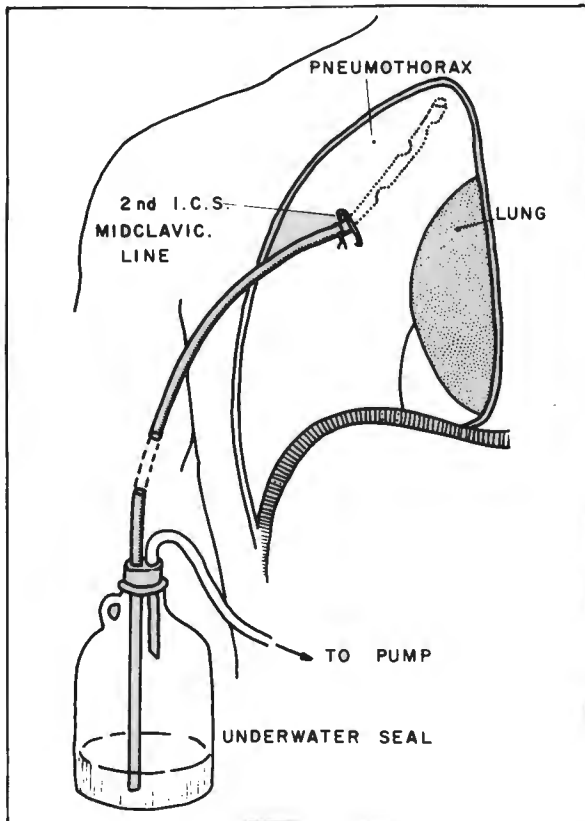


Fig. 11—Chest tube inserted for drainage pneumothorax.

Patients with massive trauma may have a ruptured bronchus. Such injury leads to extravasation of air into the mediastinum and pleural space with marked dyspnea and hemoptysis. The presence of mediastinal, pleural, and subcutaneous air in a patient with hemoptysis at the time of massive injury strongly suggests the possibility of a ruptured bronchus. Prompt diagnosis and repair is essential. The diagnosis can be made by bronchoscopy, and this examination should be done promptly after the suspicion of the possibility of such an injury. Once the diagnosis has been made, prompt operative exposure and closure of the defect is essential.

Massive blunt trauma may rupture the diaphragm. The left diaphragm tends to rupture far more frequently than the right. Under these circumstances, intestinal contents from the positive pressure peritoneal cavity are forced into the negative pressure pleural space bringing about collapse of the ipsilateral lung tissue and shift of the

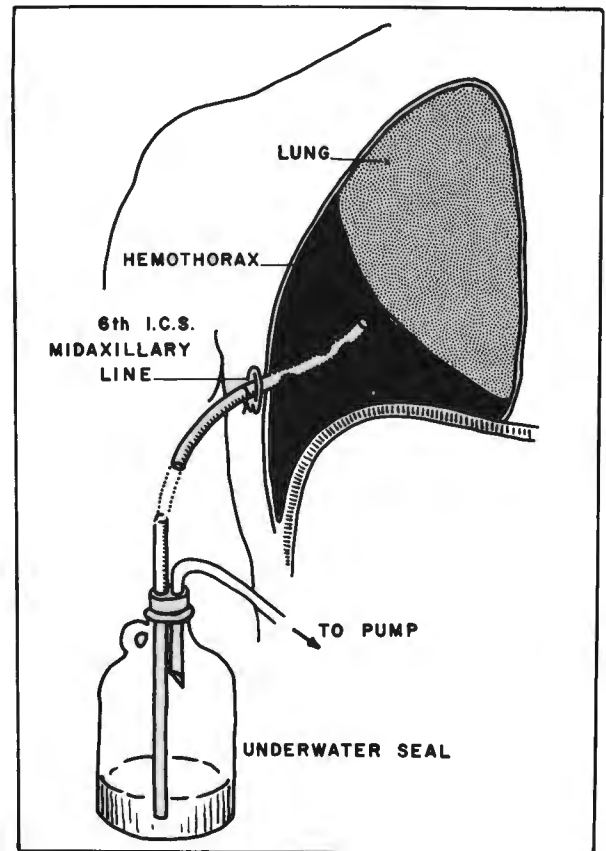


Fig. 12—Chest tube inserted for drainage hemothorax.

mediastinum and heart to the opposite side. The amount of respiratory embarrassment is proportional to the amount of peritoneal contents in the pleural space and the antecedent lung condition. Prompt recognition of this problem is essential, and operative repair must be carried out promptly if the ruptured diaphragm leads to respiratory embarrassment.

Non-pulmonary injuries may effect the lung itself. Of great importance in this area is the presence in the orthopedic injury of possible fat emboli to the lungs. If such a diagnosis is made, pulmonary assistance is essential to the maintenance of the patient after injury even with support from tracheostomy and positive pressure breathing apparatus. Other areas distant from the lung which may give severe respiratory embarrassment are spinal cord injuries which will effect diaphragm and intercostal action. Severe brain damage may so effect the respiratory activity that the patient's problems will be mainly in the area of the lung.

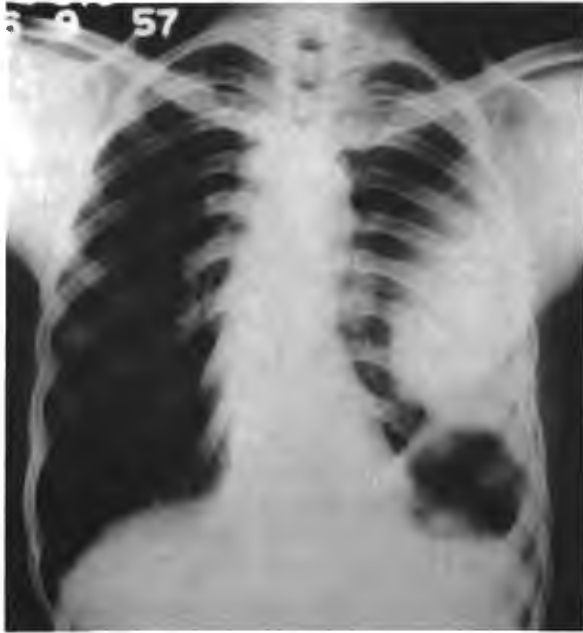

Fig. 13—X-ray of post-traumatic chest with retained blood in left chest requiring decortication.

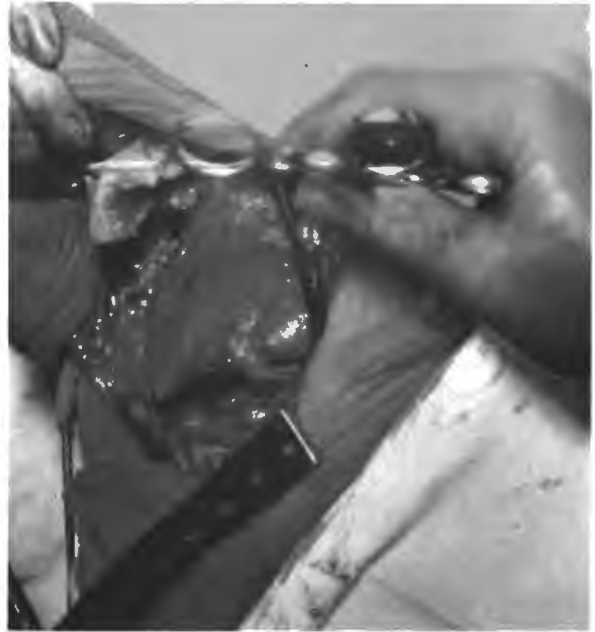


Fig. 14—Decortication of post-traumatic chest (see fig. 13).

In the case of brain damage good airway may be sustained with an endotracheal tube for several days and then replaced with tracheostomy. Facial, jaw or sinus injuries may so crowd the upper respiratory passages that tracheostomy is essential to prevent asphyxia. Severe neck injuries

causing pressure on the trachea must be managed carefully to provide for an adequate, continuous airway. Extensive injuries immobilizing the patient in bed for long periods of time must be carefully observed in order to prevent atelectasis, pneumonia, and respiratory failure.