

# Some Common and Less Common Aspects of Orthoptics

ELIZABETH E. PORTER, D.B.O.

*Instructor of Ophthalmology, Medical College of Virginia, Health Sciences Division of Virginia Commonwealth University, Richmond, Virginia*

Orthoptics (derived from the Greek "orthos"—straight and "ops"—vision) has been in use for centuries at various stages of sophistication and has been applied to the treatment of visual anomalies not amenable to other medical approaches. However, today's orthoptic evaluation and treatment techniques date back only about 50 years, with continuous refinements in both knowledge and technical equipment. Orthoptic treatment is primarily directed towards restoring normal binocular vision; whereas, pleoptic treatment is aimed at regaining monocular vision. Thus, although the art of orthoptics is in the final analysis an ancient one (fig. 1), its scientific application has been greatly enhanced and placed on more solid scientific grounds, especially in the last decade.

An orthoptic examination consists of a complete muscle work-up, testing of visual acuity, and the diagnosis of the patient's binocular function. Orthoptic treatment is essentially a process of mental training consisting of reeducative exercises. Thus, it must be diagnostic before it can be therapeutic. It is only possible to reeducate the binocular functions to a stage reached in their development before the onset of the eye deviation. Orthoptic treatment does not take the place of surgery, although some cases may be corrected by orthoptics alone. Other cases may require both pre- and postoperative treatment in order to attain a functional result. Cases without any potential for binocular vision may have surgery for a cosmetic result only, as orthoptic treatment could cause intractable diplopia where no fusion exists.

Most of the patients referred for an orthoptic evaluation are children. Thus, it is essential that

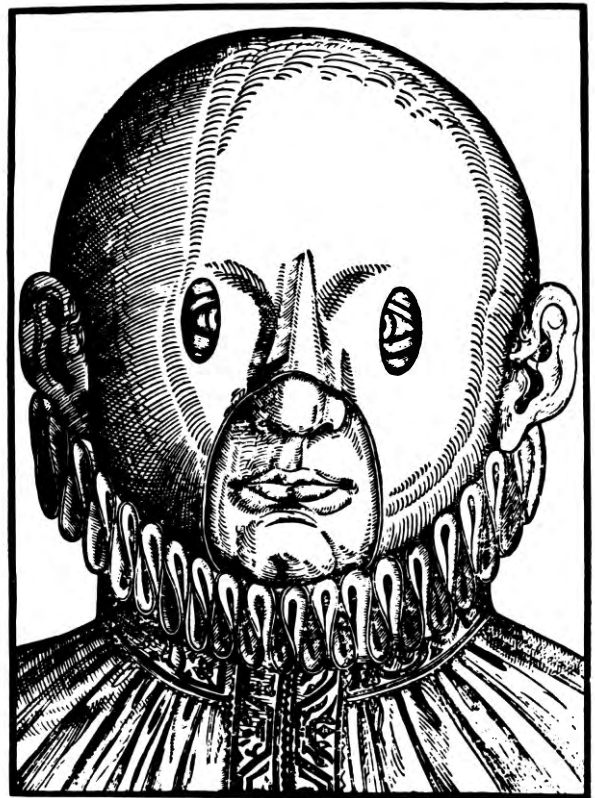


Fig. 1—Mask for the treatment of strabismus from George Bartisch's *Augendienst*, 1583.

both the examination and the treatment are made interesting and that the child enjoys the visits as much as possible. Adult cases include congenital and acquired muscle paresis, latent strabismus with symptoms, convergence insufficiency, and accommodative spasm and fatigue.

Pleoptic treatment presents a challenge when foveal fixation has been lost and the final outcome is speculative, even though treatment is based on scientific evaluations and predictions.

In this paper some daily orthoptic and pleoptic activities are discussed, and examples of more unusual and experimental approaches which have proved of benefit are presented.

Amblyopia (from the Greek "amblyus"—blunt and "ops"—vision) represents a condition of reduced vision which is not traceable to a specific disease or injury and which cannot be corrected by optical means, that is, glasses or contact lenses. In suppression amblyopia the retinal function is normal, but because of "faulty alignment," that is, visual representation on non-corresponding areas of the two eyes, double vision would be experienced. Although the morphology and function of the involved retina can be considered to be normal, the elicited experience activates a central, that is, cortical inhibition of the transferred stimuli, and suppression is the result (figs. 2 and 3).

The goal for orthoptic treatment is the re-establishment of single binocular vision, although retinal rivalry may persist without any form of spatial distortion. The objective for pleoptic treatment is improvement in visual acuity.

In summary, it should be understood that orthoptics and pleoptics represent non-surgical means by which the eyes are trained to function normally and to overcome previous disease entities which might have been instrumental in causing the

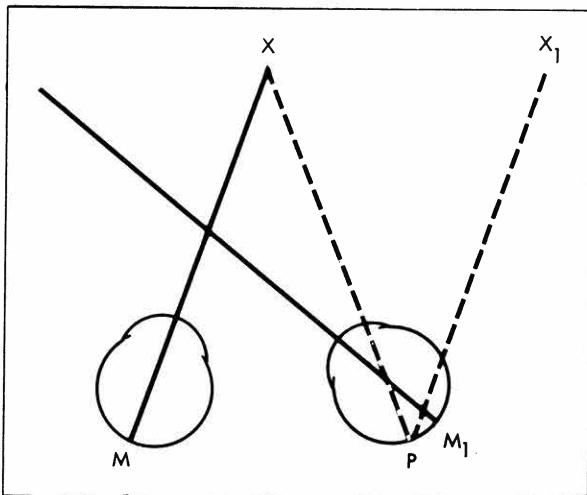


Fig. 2—Diagram to show homonymous or uncrossed diplopia in a right esotropia.

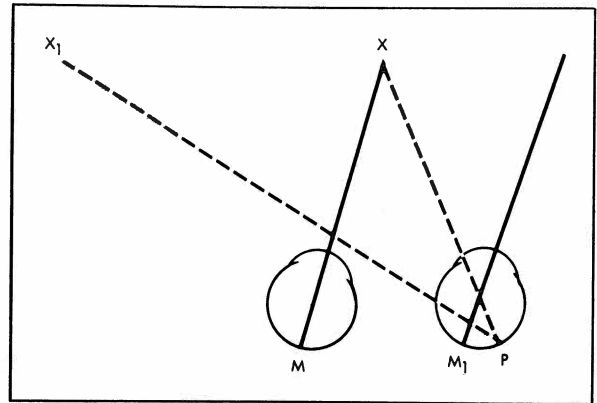


Fig. 3—Diagram to show heteronymous or crossed diplopia in a right exotropia.

existing condition. One of the more common problems encountered in orthoptic treatment is suppression amblyopia. A general approach to deal with this condition is demonstrated in a randomly selected case report. Though loss of vision due to suppression amblyopia is still too frequently found, the public is gradually becoming more aware of its existence, but until the urgency of strabismus is fully realized, vision will continue to be needlessly lost.

There are two kinds of suppression amblyopia: strabismic amblyopia and anisometropic amblyopia. In the former, the fovea of the deviating eye is suppressed to avoid confusion (that is, seeing a different image from that of the fixing eye), and a peripheral retinal point is suppressed to avoid diplopia. In the latter, there is suppression of the image seen by the eye with the greatest refractive error, but in this instance the foveal suppression is of the same image.

Over the years various methods of treatment have been tried and successes claimed for all of them. Treatment in every case is directed to the usage of the fovea, and it is designed to restore functional superiority of the fovea and to maintain the improved visual acuity once gained. The most frequently used method is occlusion of the eye with the better visual acuity. This method, combined with exercises which require visual skills such as dot drawings and jigsaw puzzles, often shows marked improvement in the vision of the amblyopic eye. An older child will, however, find it more difficult both to regain good visual acuity and to wear an occluder. Compromises have had to be made; for instance, part-time occlusion combined with an

hour per day spent doing some intricate close work, such as the Weiss exercise sheets (figs. 4, 5, and 6).

A different color is chosen for each symbol, and the child colors, for example, the "E" as far down the chart as it can be identified. Then another symbol is chosen, and the exercise is repeated. The Weiss sheets are also printed in red, and when combined with the use of a red filter over the dominant eye instead of total occlusion, even more effort is required of the amblyopic eye. Red filter occlusion can be used with any game or craft requiring acute vision where colors in the red/orange range predominate.

Occlusion of the fixing eye can be obtained by the use of atropine drops in that eye. This method has been chosen most often in the treatment of very young children when occlusion with an eye patch was not tolerated. Recently, this method of occlusion has been combined with the use of a miotic in the amblyopic eye. The miotic creates a pinhole effect, therefore, visual acuity is slightly im-

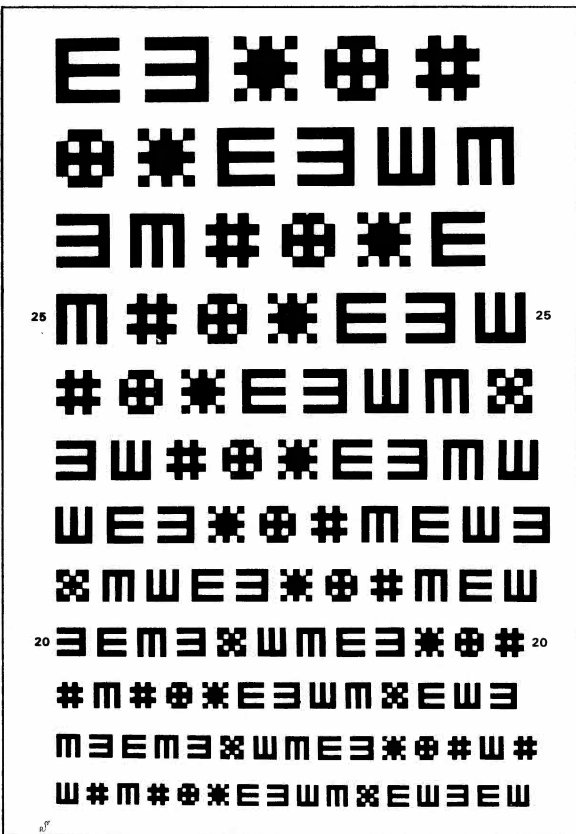

Fig. 4—Weiss exercise sheet containing eight different symbols.




Fig. 5—Weiss labyrinth exercise.

proved. Unless the patient is myopic, the eye under the influence of the miotic is used in preference to the dilated eye for close work. A recent study in England reports successful results using this method, even in cases where foveal fixation had been lost. The miotic used was phospholine iodide 0.06%, and the cycloplegic was atropine 1%. Treatment was continued for as long as 20 months and included children up to 13 years of age. The advantage of this treatment is that the embarrassment of wearing a patch is avoided; consequently, both the parents and the child are happier.

Low vision optical aids can also be helpful in the treatment of amblyopia. There are two types of telescopes which may be used. For patients with very low visual acuity, there is a 6x magnifying monocular telescope; however, the field of vision is small, and much skill is required for its use. The 2½x telescopic lens has the advantage of being able to be clipped on to glasses and also permits a




Fig. 6—Weiss labyrinth exercise.

larger field of vision. Part-time occlusion for one or two hours per day is necessary, and during that time active seeing is required for both near and distance. The treatment may sometimes be long and requires the effort and cooperation of both the child and the parents.

In 1953, Bangerter of St. Gallen, Switzerland, introduced pleoptic treatment of amblyopia, and Cuppers designed the visuscope for the diagnosis of amblyopia with eccentric fixation and the euthyscope for its treatment. Bangerter's method of treatment uses light to alternately dazzle the retina while

sparing the fovea, followed by light stimulation of the fovea. It is very time consuming and requires above average cooperation of the patient. This is also true of Cuppers' treatment which utilizes after images and the Haidinger brush phenomenon.

Suppression is difficult to eradicate completely. For instance, a patient may demonstrate 20/20 vision in the previously amblyopic eye when tested monocularly, but when tested under binocular conditions with polaroid glasses and the vectograph slide, visual acuity may be considerably reduced in that eye. Ideally then, treatment should be continued until visual acuity is the same whether tested monocularly or binocularly (fig. 7).

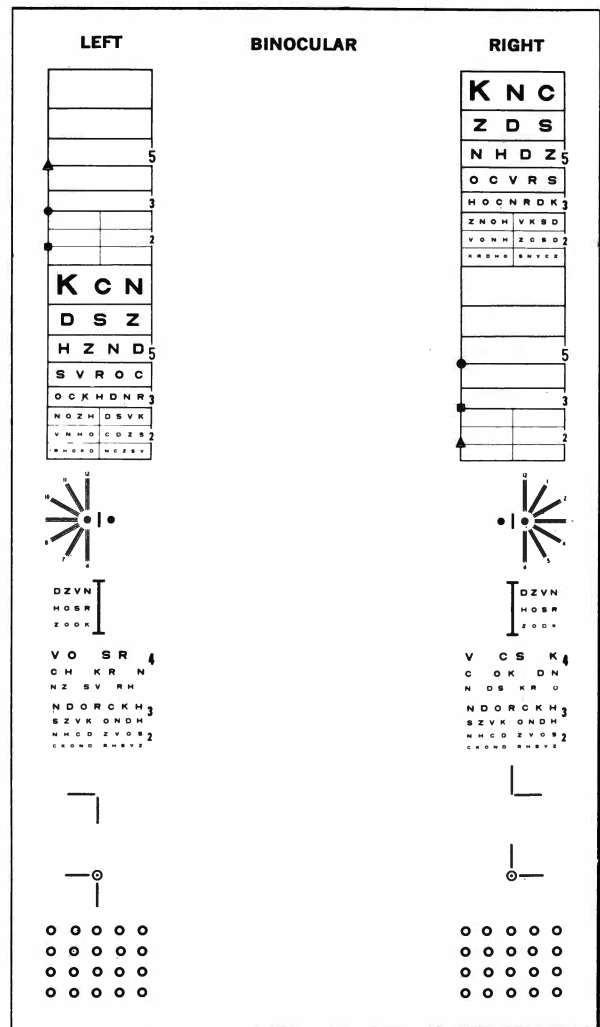


Fig. 7—Vectograph slide, a test for monocular visual acuity under binocular conditions. (Courtesy of American Optical Corporation.)

Major amblyoscope measurements:

Fixing Right Eye			Fixing Left Eye		
To patient's right		To patient's left	To patient's right		To patient's left
+4 <sup>LH1Δ</sup>	+2 <sup>LH1Δ</sup>	+2 <sup>LH1Δ</sup>	+3 <sup>LH1Δ</sup>	+4 <sup>LH2Δ</sup>	+4 <sup>LH1Δ</sup>
+8 <sup>LH8Δ</sup>	+6 <sup>LH5Δ</sup>	+6 <sup>LH5Δ</sup>	+8 <sup>LH8Δ</sup>	+10 <sup>LH12Δ</sup>	+10 <sup>LH13Δ</sup>
+8 <sup>LH16Δ</sup>	+10 <sup>LH15Δ</sup>	+10 <sup>LH10Δ</sup>	+18 <sup>LH17Δ</sup>	+10 <sup>LH14Δ</sup>	+10 <sup>LH14Δ</sup>

Treatment of amblyopia should always be selected according to its severity and to the age and temperament of the patient. If one method does not prove to be satisfactory, others should be tried, as the improvement of visual acuity is a very worthwhile goal.

Some of the more unusual conditions requiring orthoptic evaluation are presented in the following case reports.

A 57-year-old secretary was referred to the Orthoptic Clinic in October, 1968, with a complaint of a gradual onset of diplopia. The patient presented a history of rheumatoid arthritis of long duration which had severely affected the hands and feet. No

scleral or conjunctival involvement was noted. The orthoptic evaluation at that time revealed 12 prism diopters of left hypertropia by prism cover test. The chin was depressed, and the head was turned towards the right. Diplopia was present on level and on down gaze with the greatest vertical separation of images on dextro-depression, that is, with the eyes looking down and to the right.

The Hess screen test revealed a weakness of the left superior oblique and left inferior rectus muscles (fig. 8).

It was possible to join the diplopia on level gaze with a 6<sup>a</sup> prism, and a clip-on prism was prescribed. The patient was comfortable with the

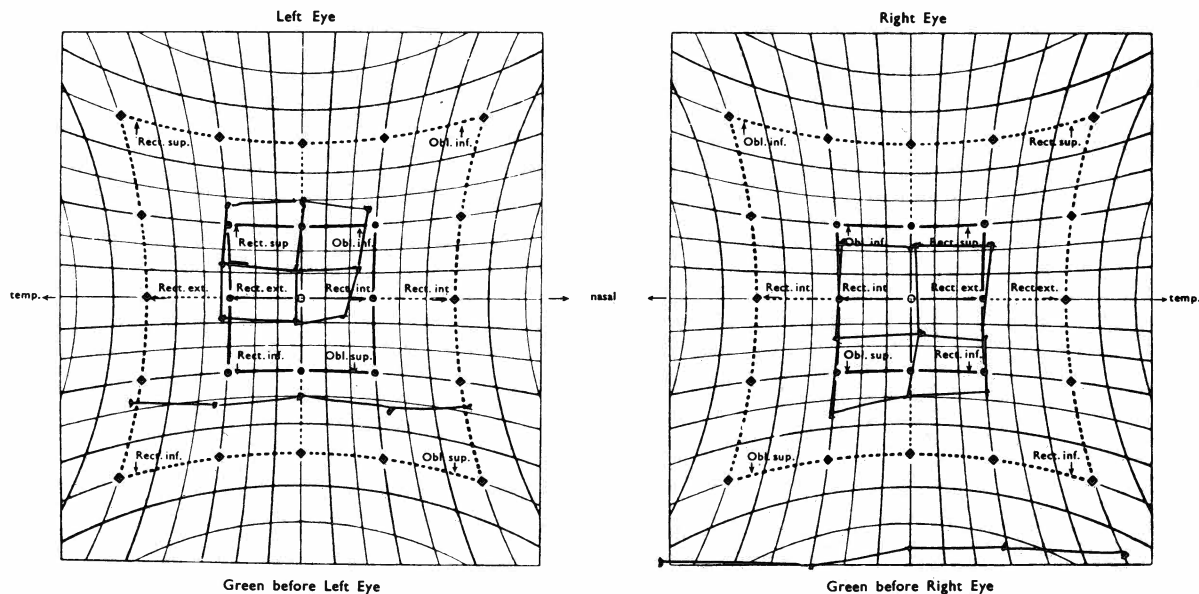


Fig. 8—Hess screen chart, October, 1968.

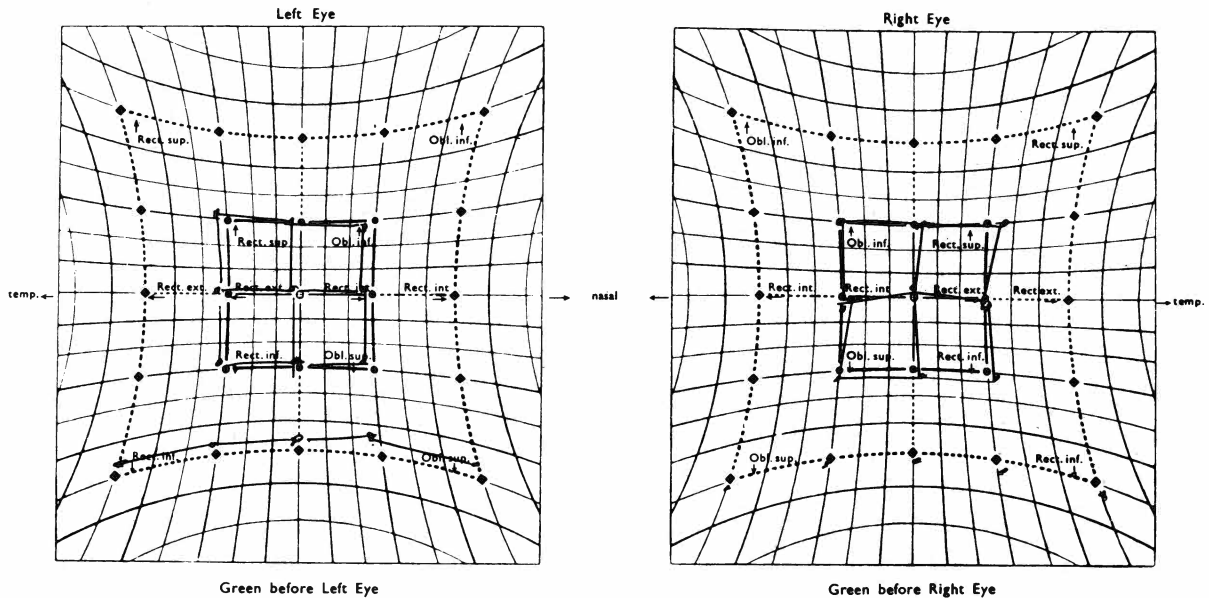


Fig. 9—Hess screen chart, September, 1971.

prismatic correction which was later incorporated into her refractive lenses. The prescription given was: O. D. - 2.75 - 0.50 × 150 ⊂ 3<sup>Δ</sup> base up; O. S. - 2.00 sphere ⊂ 3<sup>Δ</sup> base down with a +2.00 diopter spherical addition for near work. In September, 1972, the patient returned to the Orthoptic Clinic for reevaluation. She stated that the diplopia was quite variable and at times could be overcome with or without the glasses. The orthoptic

findings were as follows: On level gaze there was a left hyperphoria for near and distance; on down gaze a left hypertropia and a left esotropia existed. The head posture was fairly straight, but the head was still held down at times. Diplopia was present on down gaze and most marked on laevo depression. The Hess screen test showed only a slight under action of the left superior oblique muscle (fig. 9).

Major amblyoscope measurements September, 1972:

<i>Fixing Right Eye</i>			<i>Fixing Left Eye</i>		
To patient's right		To patient's left	To patient's right		To patient's left
+4 <sup>Δ</sup>	+4 <sup>Δ</sup>	+2 <sup>LH1Δ</sup>	0 <sup>LH1Δ</sup>	0 <sup>LH1Δ</sup>	-8 <sup>LH1Δ</sup>
L. Ex 10°	L. Ex 10°	L. Ex 10°	L. Ex 10°	L. Ex 10°	L. Ex 10°
+8 <sup>LH2Δ</sup>	+6 <sup>LH2Δ</sup>	+4 <sup>LH2Δ</sup>	+6 <sup>LH2Δ</sup>	+6 <sup>LH2Δ</sup>	+2 <sup>LH2Δ</sup>
L. Ex 10°	L. Ex 10°	L. Ex 10°	L. Ex 10°	L. Ex 10°	L. Ex 10 <sup>Δ</sup>
+24 <sup>LH2Δ</sup>	+30 <sup>LH2Δ</sup>	+30 <sup>LH7Δ</sup>	+20 <sup>LH2Δ</sup>	+20 <sup>LH6Δ</sup>	+20 <sup>LH10Δ</sup>
L. Ex 10°	L. Ex 10°	L. Ex 10°	L. Ex 20°	L. Ex 20°	L. Ex 20°

L. Ex = Left Ex cyclophoria  
 Fusion on level gaze at 0<sup>Δ</sup> and on down gaze at 18<sup>Δ</sup>.

Major amblyoscope measurements:

<i>Fixing Right Eye</i>			<i>Fixing Left Eye</i>		
To patient's right		To patient's left	To patient's right		To patient's left
-44 <sup>LH8Δ</sup>	-42 <sup>LH6Δ</sup>	-40 <sup>LH8Δ</sup>	-34 <sup>LH8Δ</sup>	-34 <sup>LH8Δ</sup>	-30 <sup>LH6Δ</sup>
R. In 5°	R. In 5°	R. In 5°	R. In 10°	R. In 10°	R. In 10°
-44 <sup>LH10Δ</sup>	-44 <sup>LH2Δ</sup>	-42 <sup>LH4Δ</sup>	-36 <sup>LH4Δ</sup>	-36 <sup>LH4Δ</sup>	-32 <sup>LH5Δ</sup>
R. In 5°	R. In 5°	R. In 5°	R. In 10°	R. In 10°	R. In 10°
-46 <sup>RH6Δ</sup>	-44 <sup>RH5Δ</sup>	-40 <sup>LH3Δ</sup>	-46 <sup>RH5Δ</sup>	-42 <sup>RH4Δ</sup>	-42 <sup>RH4Δ</sup>
R. In 10°	R. In 10°	R. In 10°	R. In 10°	R. In 10°	R. In 10°

R. In = Right Incyclotropia

Sandford-Smith (1969) and Sims (1971) have reported cases of patients suffering from rheumatoid arthritis who also had diplopia due to abnormalities of the superior oblique muscle. It appears possible that in this case there may also be a connection between the disease and the defective muscle or the tendon or muscle sheath. This possibility is supported by the frequent extensive pathology of the sclera which may occur in this disease entity.

Another patient, a 40-year-old timber merchant, suffered a III nerve paresis following a car accident in December, 1971. He had severe contusions and multiple injuries involving the right side of the body. The right eye showed a fixed dilated pupil, and there was retrograde amnesia of several months preceding the accident. In March, 1972, the patient was referred to the Orthoptic Clinic for evaluation. He was wearing an eye occluder over the injured eye to prevent diplopia. An orthoptic work-up in this case revealed the following findings: The prism cover test showed an exotropia of 45 prism diopters with a left hypertropia of 8 prism diopters. There was a marked weakness of the right internal rectus and a weakness of the right superior and right inferior recti muscles. Heteronymous and vertical diplopia were present with the greatest separation of images on dextro-depression (fig. 10). The Hess screen chart showed marked weakness of the right internal rectus and an overaction of the right external rectus, the smaller field belonging to the eye with the parietic muscle (fig. 11).

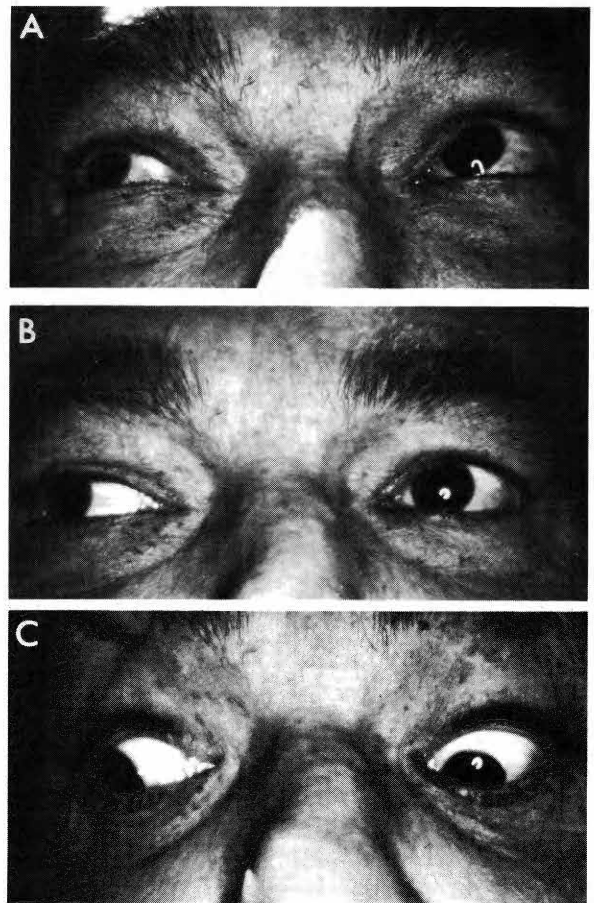


Fig. 10—A. shows limitation of right eye on dextro elevation; B. shows right exotropia on level gaze; C. shows right exotropia with right hypertropia on down gaze.

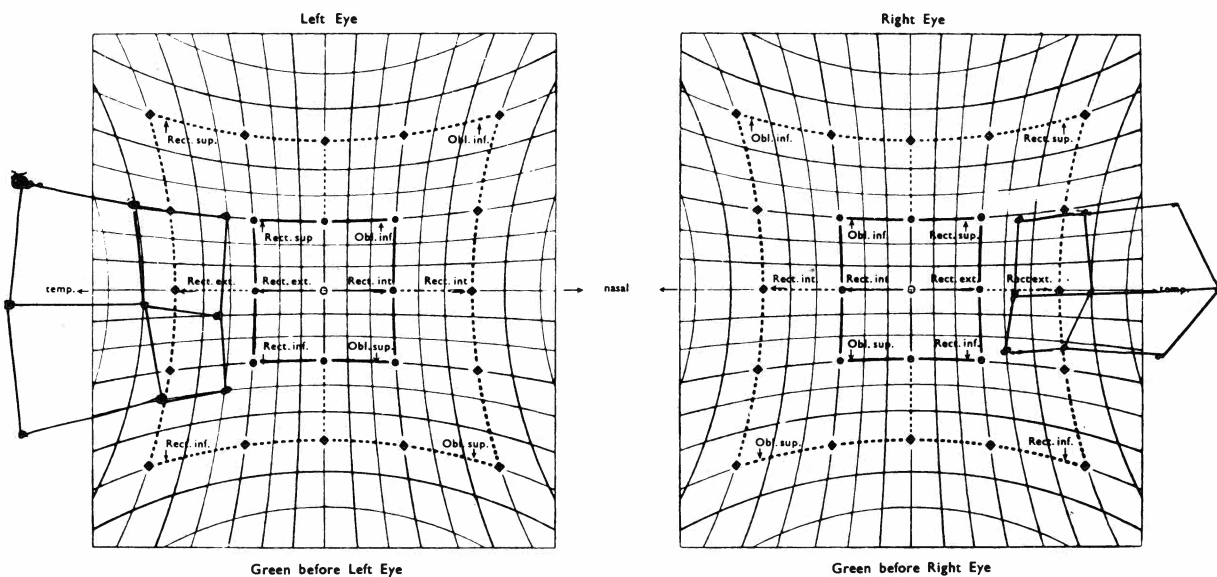


Fig. 11—Hess screen chart, March, 1972.

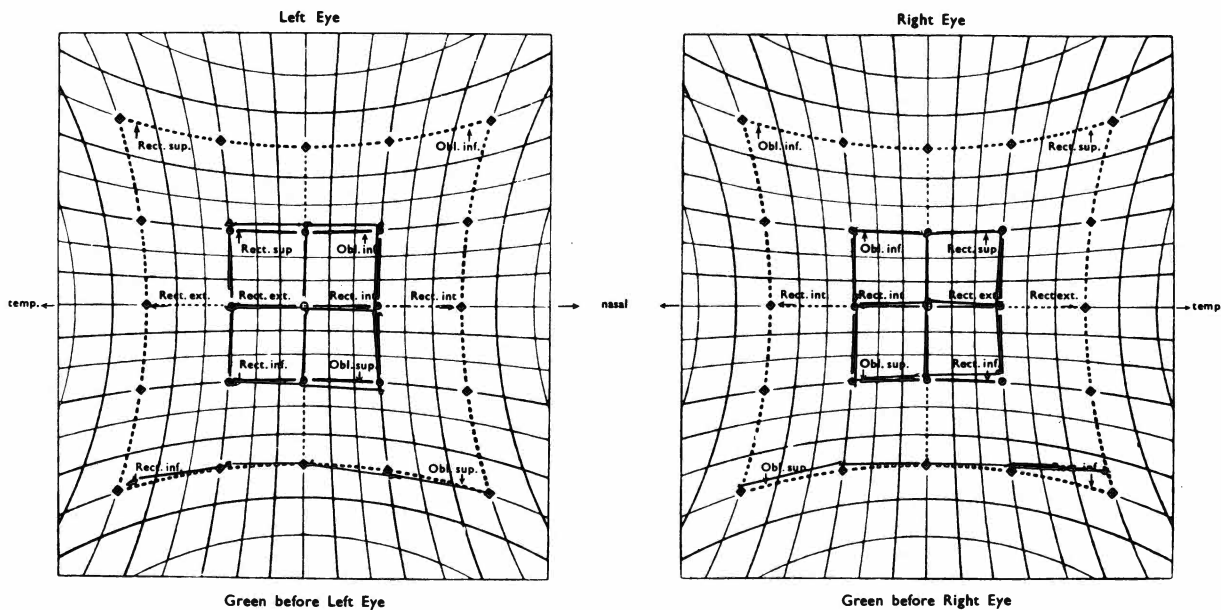


Fig. 12—Hess screen chart, August, 1972.



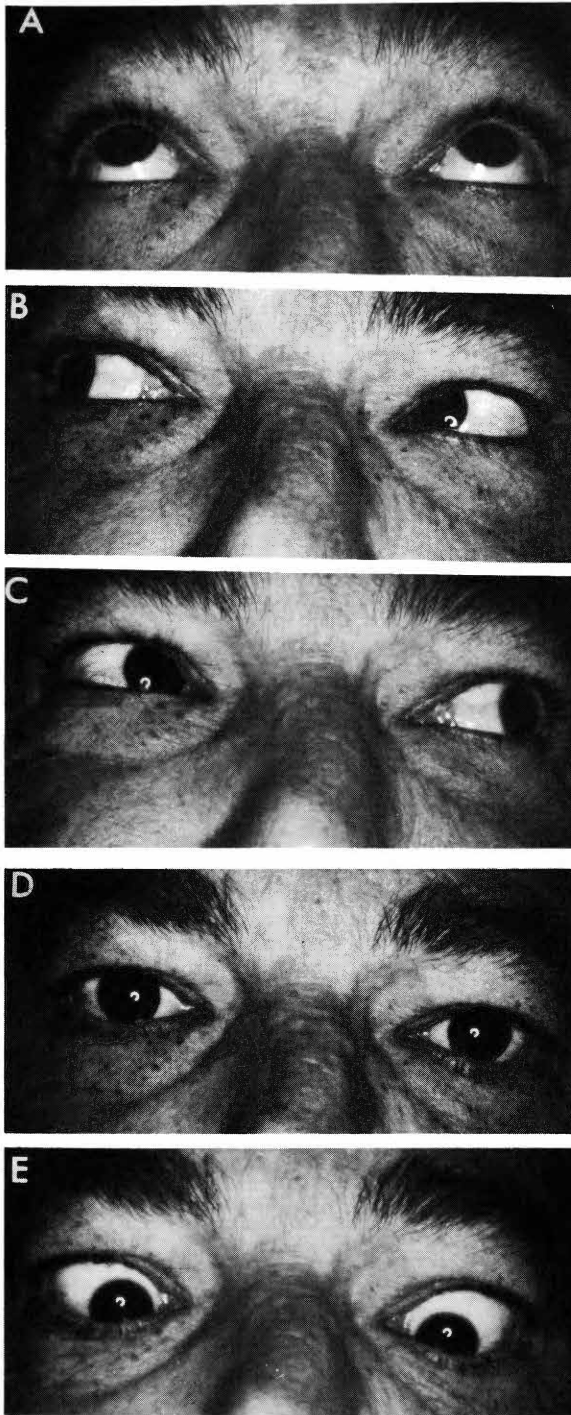


Fig. 13—A. up gaze; B. dextro version; C. laevo version; D. straight ahead; E. voluntary convergence, August, 1972.

On the second visit a week later it was possible for the patient to fuse the two images on level gaze with the aid of a  $40^{\Delta}$  prism base in over the right eye. Treatment was given on the major amblyoscope to improve fusional amplitudes, so that later it would be possible to reduce the amount of prism required to maintain single vision. The patient was given a prism bar with prism strength gradated from  $1^{\Delta}$  to  $40^{\Delta}$  for daily home exercises. He was asked to refrain from wearing the occluder as much as possible so that some attempt could be made to join the diplopia. The occluder, when worn, was transferred to the unaffected eye, as it was now possible to do so without causing proprioceptive difficulties. This enabled the right eye to be used instead of remaining in a divergent position behind the occluder.

At the end of that month it was possible to join the diplopia; however, this required an excess amount of accommodation, so that distance binocular visual acuity was reduced to 20/70. Treatment with the prism bar was then changed to base out exercises, with the result that prism convergence improved to  $40^{\Delta}$ . Convergence exercises were given on the major amblyoscope, and control of the deviation was helped by teaching physiological diplopia exercises using stereograms. There was still some difficulty on up gaze and on down gaze due to weakness of the superior and inferior recti muscles. The field of binocular vision was increased by attempting to keep an object "one" in all cardinal fields. The patient's difficulty in judging distance persisted, and he felt the loss of depth perception, although on testing it was present.

Treatment was continued, and by August, 1972, there was a marked improvement. At that time the Hess screen test showed only a slight weakness of the right inferior rectus muscle (fig. 12).

Major amblyoscope measurements showed an angle of deviation of  $2^{\Delta}$  of exophoria with a left hyperphoria of  $1^{\Delta}$ . Fusion existed at  $0^{\circ}$  with adduction to  $30^{\Delta}$ , and depth perception was present.

Involuntary convergence was present to 6 cm, and the patient had the ability to converge voluntarily. Binocular visual acuity at that time measured 20/15. The only area where there was some difficulty was on extreme depression, but this was not sufficient to cause discomfort in everyday life (fig. 13).

The scope of orthoptics is wide, but it must be remembered that orthoptic treatment of eye devia-

tions is only part of the overall treatment. Medications and/or surgical treatment may be necessary, frequently in a combined effort with orthoptic treatment, for visual rehabilitation of the individual patient.

#### BIBLIOGRAPHY

DUNLAP, EDWARD A. Symposium: Current aspects of amblyopia. *Am. Orthopt. J.* 21:5-6, 1971.

NOORDEN, GUNTER K. VON, SPRINGER, FLORENCE, ROMANO, PAUL, AND PARKS, MARGARET. Home therapy for amblyopia. *Am. Orthopt. J.* 20:46-50, 1970.

POPE, L. J. Treatment of eccentric fixation without occlusion. *Brit. Orthopt. J.* 28:77-82, 1971.

SANDFORD-SMITH, J. H. Intermittent superior oblique tendon sheath syndrome. *Brit. J. Ophth.* 53:412, 1969.

SIMS, J. Acquired apparent superior oblique tendon sheath syndrome. *Brit. Orthopt. J.* 28:112-115, 1971.

SMITH, J. G. Treatment of Amblyopia with Low-Vision Aids. In *Orthoptics: Proceedings of the Sec. Inter. O. Congress (Amsterdam)*, 11-13, May, 1971. *Excerpta Medica*, Amsterdam, 1972, edited by Mein, J., Bierlaagh, J. J. M., and Brummelkamp-Dons, T. E. A.

WEISS, J. B. Amblyopie á fixation excentrique et occlusion. *Arch. Ophth.* 23:176-177, 1963.