



Cytomegalovirus Infection of the Eye in a Case of Renal Homotransplantation

G. E. MADGE, M.D.

*Associate Professor of Ophthalmology and Pathology,
Medical College of Virginia, Health Sciences Division of
Virginia Commonwealth University, Richmond, Virginia*

Ocular involvement in cytomegalic inclusion disease, a viral infection usually seen in infants, is rarely seen in adults (4) except as a terminal infection complicating diseases such as malignant lymphoma and leukemia (1). In infants, chorioretinitis and the frequent finding of intracranial calcification make clinical differentiation from toxoplasmosis difficult (5). This report presents a case of cytomegalic inclusion disease involving the eyes of an adult who had received a renal homotransplant.

Case History. An 18-year-old white man was treated at another hospital in March for chronic renal failure. Renal biopsy revealed chronic glomerulonephritis. Serum calcium was low to normal, and inorganic phosphorus was elevated. Treatment consisted of vitamin D 200,000 units b.i.d. and calcium gluconate 1½ grains t.i.d. Three months later extensive calcification of major vessels was detected radiographically. Serum calcium was 17 mg per 100 ml. In August, the patient was admitted to Medical College of Virginia Hospital. His blood pressure was 160/104, the pulse 104, the respirations 20, the temperature 99°F, and the weight 103 pounds. The hemoglobin was 9.8 g per 100 ml, the creatinine clearance 0.5 ml per minute, the total protein 5.8, the albumin 2.9, and the globulins 2.9 g per 100 ml. Radiographs showed demineralization of all bones. Hemodialysis was performed. Cystoscopic examination revealed an anomalous left ureteral orifice. In October, the patient underwent bilateral ureteronephrectomy, posterior bladder neck resection, and splenectomy. A kidney taken from his father was transplanted. Azathioprine 175 mg, prednisone 60 mg, and actinomycin D 200 mg per day were given.

Urine excretion was adequate. Urine culture yielded *S. aureus*, coagulase positive, which responded to antibiotics. In November, a low grade fever began which progressed to a spiking pattern and persisted until death. Blood cultures were sterile. Numerous antibiotics, and Mycostatin® had no effect. On December 15, a chest radiograph showed pulmonary infiltration. The peripheral white cell count was abnormally low, and azathioprine was discontinued. One week before death the serum urea nitrogen reached its minimum value of 19 and creatinine 0.8 mg per 100 ml. There was no clinical evidence of ocular disease. The patient was thought to have "transplantation" pneumonia and died in December, approximately nine months after his admission. The autopsy findings included chronic pyelonephritis, nephrolithiasis, bacterial microabscesses of pancreas, heart, and kidneys as well as cytomegalic inclusion disease of the lungs.

Gross and Histologic Examination of Eyes.

Each globe measured 25 × 24 × 24 mm and was cut in the vertical plane and showed no gross lesions. Microscopically the ciliary body and iris showed no lesions. The retina of the posterior segment was involved by a few small white plaques in a few places. The lesion was most prominent in the choriocapillaris and vascular layer of the choroid, but it did extend to Bruch's membrane in several areas. In these areas the infiltrate was sparse and consisted of plasma cells, a few neutrophils, pigment laden macrophages, and nuclear debris. Cellular composition was similar in all nodules, but some were distinctly related to small vessels in the choriocapillaris and the vascular layer of the choroid. These areas did not contain un-

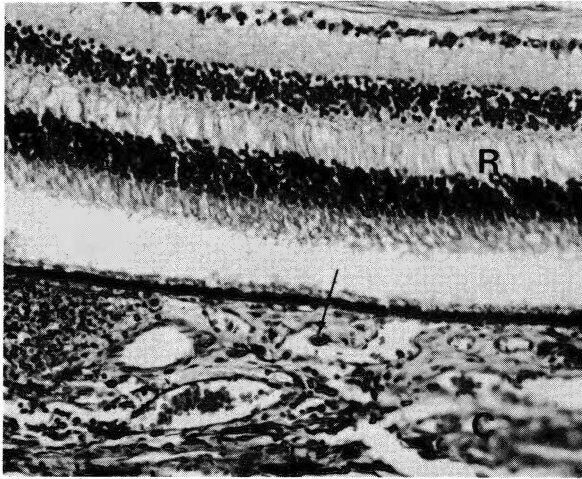


Fig. 1—The focal area of necrosis in the choroid (C) extends to Bruch's membrane. The overlying retina is uninvolved in this area. Notice the nuclear inclusion at arrow (H&E 250 \times).

equivocal inclusion bodies. However, there were typical basophilic inclusions surrounded by a halo in swollen endothelial cells of the choroid (figs. 1 and 2). Many smaller basophilic inclusions were seen in the cytoplasm of the endothelial cells. In a few areas the necrosis extended into the retina between the outer plexiform and inner nuclear layers, and in some they involved the entire thickness of the retina. The optic nerve contained many similar areas of necrosis, but the optic nerve head was uninvolved (fig. 3).

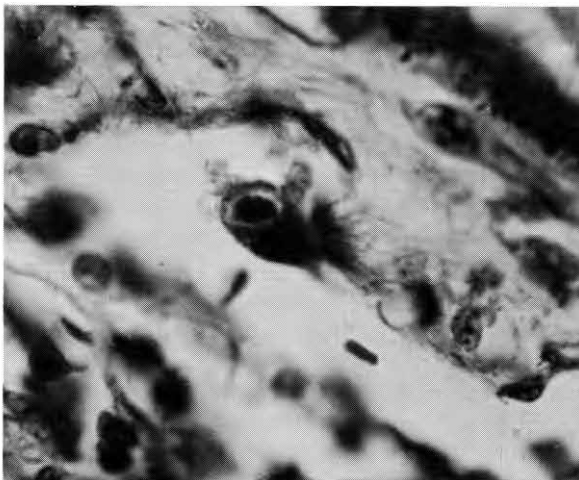

Fig. 2—Intranuclear inclusion with prominent halo in swollen endothelial cell (H&E 500 \times).

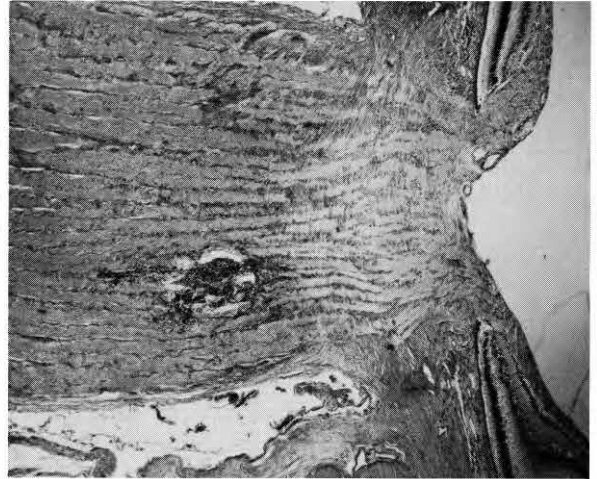


Fig. 3—Focal area of coagulative necrosis in optic nerve (H&E 30 \times).

Comment. Bilateral chorioretinitis caused by cytomegalovirus was seen in this patient. Immunosuppressive therapy necessary for his kidney transplant seemed a contributory factor to the disease. As described by de Venecia and co-workers, the ophthalmoscopic appearance of cytomegalic inclusion disease is distinctive (2). This patient had no symptoms referred to the eyes. While certainly not unexpected in view of the pulmonary cytomegalovirus pneumonia, this seems to be a rare development in the eyes of transplant patients. The incidence of ocular cytomegalovirus in transplant patients may be higher, however, since the eyes are not routinely removed at autopsy. The optic nerve showed lesions in the present case. These were similar to those seen in the choroid. Schneck (3) described probable cytomegalovirus infection which showed similar nodules in the brains of 12 of 34 patients who expired following renal transplantation. In 2 of these 12 cases intranuclear inclusions were found.

Ocular lesions in infants were described by Smith as peripheral involvement of choroid and retina (5). However, retinal involvement in adult cytomegalic inclusion disease was usually described at the posterior pole. The lesions in this case were in this location but mainly damaged the choroid with relatively slight destruction of the retina.

Intranuclear inclusions were difficult to find. This is not unusual. The reason is not clear but perhaps related to the extensive necrosis. The endothelial cells of the vessels of the choroid were swollen, and several contained basophilic intranuclear inclu-

sions. In spite of the fairly extensive focal areas of necrosis, the patient had no symptoms referable to the eyes.

In summary, an adult who had a renal homograft transplantation died of cytomegalovirus pneumonia. Examination of the eyes showed a chorio-retinitis with typical cells and inclusion bodies.

REFERENCES

1. BODEY, G. P., WERTLAKE, P. T., AND DOUGLAS, G., *et al.* Cytomegalic inclusion disease in patients with acute leukemia. *Ann. Intern. Med.* 62:899-906, 1965.
2. DE VENECIA, G., ZU RHEIN, G. M., AND PRATT, M. V., *et al.* Cytomegalic inclusion in an adult. *Arch. Ophth.* 86:44-57, 1971
3. SCHNECK, S. A. Neuropathological features of human organs transplantation. *J. Neuropath. Exper. Neur.* 24/3: 415-429, July, 1965.
4. SMITH, M. E. Retinal involvement in adult cytomegalic inclusion disease. *Arch. Ophth.* 72:44-49, 1964.
5. SMITH, M. E., ZIMMERMAN, L. E., AND HARLEY, R. D. Ocular involvement in congenital cytomegalic inclusion disease. *Arch. Ophth.* 76:694-699, 1966.