

# Cryocautery and Aqueous Humor Dynamics\*

HERBERT WIESINGER

*Department of Ophthalmology, Medical College of Virginia, Richmond*

During the past decade the application of low temperatures to selected tissues has become an important and fascinating tool in various surgical fields. Numerous systems have been designed to facilitate cryo-applications to various organs. The first instruments devised to produce localized freezing of ocular tissues were crude, and consisted primarily of metallic cylinders filled with various low-temperature mixtures. One such device was used as early as 1933 by Bietti (1933; 1934) and Deutschmann (1933; 1935) in the treatment of retinal detachments. While Bietti used a mixture of solid carbon dioxide and acetone in a metal probe, Deutschmann applied carbon dioxide snow directly to the sclera, both modes of application resulting in the production of an adhesive chorioretinitis.

Bietti (1950) was the first to apply freezing techniques to the ciliary body as antiglaucomatous treatment. He reported tonometric results in both experimental animals and humans following the application of solid carbon dioxide to the

sclera over the ciliary body. No further reports have appeared in the literature until recently when Polack and de Roeth (1964) reported their studies on the effect of freezing of the ciliary body. These authors used a conically-tipped copper vessel filled with dry ice and alcohol which they applied repeatedly over the ciliary body area of rabbit eyes. Tonographic results of these experiments showed a lowering of intraocular pressure averaging 4 mm Hg with a concomitant reduction of outflow facility and aqueous flow.

This study was undertaken primarily for the purpose of obtaining data for statistical evaluation of the effects of ciliary body freezing on aqueous humor dynamics. Such data is not presently available in the ophthalmic literature. Another objective has been to measure temperatures in various ocular structures during cryo-application and to study histologically eyes subjected to cyclocryocautery.

## Methods

The first technique employed was to freeze the entire ciliary body with a cryo-applicator ring built in our laboratory. This consisted of brass tubing, the ring diameter corresponding to the rab-

---

\* Supported by the National Society for the Prevention of Blindness, Inc. and the A. D. Williams Fund at MCV.

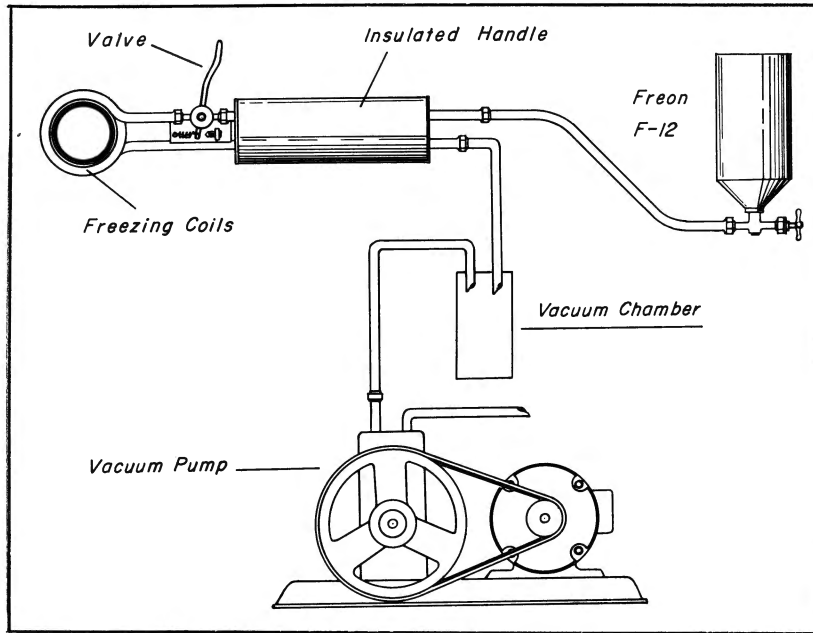


Fig. 1—Schematic diagram of freezing apparatus using ring-type applicator.




Fig. 2—Handle with Freon regulating valve: ring-type freezing applicator.

bit ciliary body area (18 mm for most mature chinchilla rabbits). The brass tubing was attached to a closed system which was fed continuously with Freon gas. The ring was attached to an insulated handle which also contained a gas regulating valve. The used gas was discharged into a vacuum pump (figs. 1 and 2). The circulating Freon gas cooled the brass ring to a temperature of  $-23^{\circ}\text{C}$ . When this ring was applied to the ciliary body area, freezing was almost instantaneous and extended grossly about 1.5 mm on either side of the applicator. Since in the rabbit eye the ciliary body is located close to the limbus (Sheppard, 1961), freezing of the peripheral cornea and the chamber angle was unavoidable by this technique. After using this technique on a number of rabbit eyes, certain disadvantages became obvious. Immediately following cyclocryocautery by this technique a substantial rise in intraocular pressure occurred in all eyes. The intraocular pressure rose an average of about 15 mm Hg, and tonography immediately following thawing showed a greatly reduced facility of outflow. This rise in intraocular pressure was thought to be due to obstruction of aqueous outflow channels by freezing, similar to that reported by Gazala et al. (1965) following circumferential experimental limbal diathermy. After 24 hours the intraocular pressure in these animals returned to preoperative values, followed by a lowering of intraocular pressure and reduction of aqueous flow in some eyes. Histological examination of rabbit globes following this mode of cryo-application also showed a number of undesirable side effects, primarily disruption of the chamber angle structure which would in all probability nullify any effect of reduced aqueous production by the ciliary body. It could also be shown that many of the small vessels surrounding the limbus were permanently occluded by a process of endarteritis obliterans, whereas larger

channels remained patent. Similar findings were recently reported by Dan and Priestley (1965) on newly formed conjunctival and corneal vessels. Consequently it was felt that this procedure would be too traumatic for human application. In all subsequent studies interrupted cryo-applications have been employed.

At this time I became aware of the commercial availability of the Kelman Cryostylet (Frigitronics, Inc., Bridgeport, Connecticut). All further experiments were carried out with this instrument (fig. 3). The instrument utilizes the Peltier effect to produce low temperatures (Kelman, 1964). A number of modules (electric current passing through two dissimilar metals) are connected in series. The heat produced at the terminals of the modules is cooled by a coolant, and the cold produced at the junction is used for freezing (fig. 4). The handle of this instrument carrying the freezing tip also has a micro switch accessible to the surgeon's index finger, which activates a heating coil, thus allowing for termination of the freezing process within 3 to 5 sec (figs. 5 and 6). While this instrument was primarily designed for use in cataract surgery, it can easily be used for ciliary body freezing when somewhat lower temperatures are used.

Freezing was carried out with the Cryostylet by applying the tip of the instrument firmly over the conjunctiva for 1 min 1 mm from the limbus. Two applications were made in each quadrant. The frozen surface was slightly larger than the tip of the instrument, measuring about 4 to 5 mm in diameter. With the reservoir temperature of the coolant (saturated salt solution and ice) at  $-2^{\circ}$  to  $-4^{\circ}\text{C}$ , the temperature of the tip was  $-40^{\circ}\text{C}$ . Since the ciliary processes of the rabbit eye extend to the posterior surface of the iris, complete freezing of all processes was not obtained. All rabbits used were mature chinchilla, weighing from 2.5 to 3.5 kg. All




Fig. 3—Kelman Cryostylet consisting of power supply, cooling reservoir, and freezing applicator tip with handle.

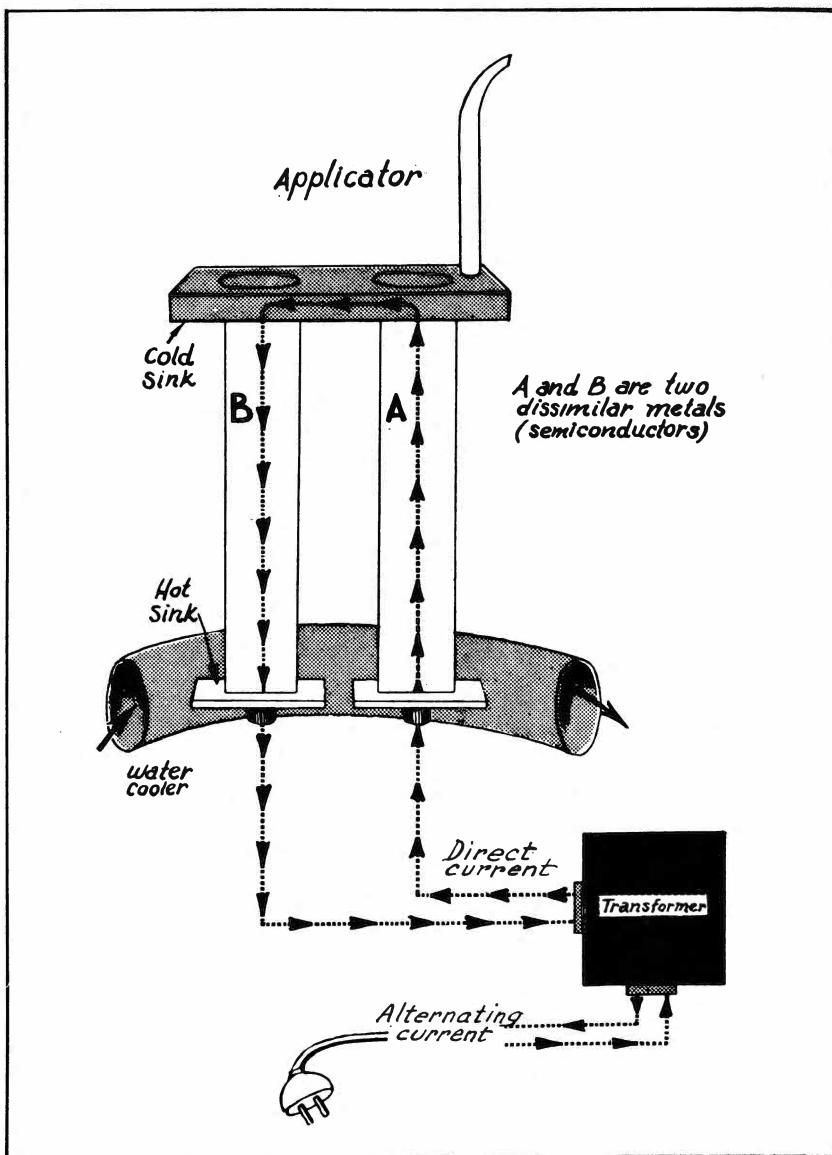


Fig. 4—Schematic diagram of thermoelectric module, the principle of the Cryostylet (courtesy Frigitronics, Inc., Bridgeport, Conn.).

eyes had tonograms before cryo-application and at varying periods afterwards. A total of 60 eyes were treated. Twenty eyes were enucleated for histological studies at various intervals; 40 eyes were observed clinically and tonographically for a total of 12 weeks. Immediately following withdrawal of the freezing tip from the conjunctiva, hyperemia of the surrounding tissue and occasionally subconjunctival hemorrhages were observed. On a few

occasions a small part of the peripheral cornea became slightly hazy, but cleared completely after 24 hours. During cryocautery of the ciliary body miosis ensued, lasting for about 30 min. Slight turbidity of the aqueous was observed on the slit lamp immediately following eight cryosurgical applications, but this also cleared in all instances after 48 hours. After one week the gross and slit lamp appearance of all eyes was normal.

Only results of the two-per-quadrant applications will be discussed, since this mode gave the most consistent results in a small pilot study.

### Results of Tonographic Study

All mature chinchilla rabbits were anesthetized with intravenous Sodium Pentothal and locally with two drops of 0.4% Dorsacaine. Tonographic tracings were obtained on all rabbits before the study with

TABLE 1

Tonographic values in rabbit eyes before, 2, 4, and 12 weeks after cyclocryocautery

Before freezing				After 2-4 weeks				After 12 weeks		
		PO	C.	F.	PO	C.	F.	PO	C.	F.
A243	OD	27	.23	3.51	21	.26		26	.24	
	OS	28	.40	8.40	20	.28		28	.38	
A286	OD	24	.23	3.22	21	.30	3.30			
	OS	28	.26	3.68	30	.39	3.80			
A328	OD	17	.17	1.19				9	.15	
	OS	22	.24	2.68				16	.33	1.98
A329	OD	17	.17	1.19	15	.37	1.85			
	OS	17	.19	1.33	16	.33	1.98			
A360	OD	24	.27	3.78	20	.24	2.40	21	.24	2.64
	OS	24	.20	2.80	19	.17	1.53	18	.17	1.37
A361	OD	24	.20	2.80	19	.17	1.53	18	.17	1.36
	OS	24	.27	3.78	20	.24	2.40	21	.24	2.64
A362	OD	22	.20	2.40				21	.30	3.30
	OS	22	.40	4.80				17	.40	2.80
A363	OD	21	.18	1.98	22	.19	3.28			
	OS	19	.17	1.53	21	.24	2.64			
A364	OD	24	.35	4.90	12	.20	.40	19	.23	1.37
	OS	22	.32	3.84	15	.20	1.00	16	.26	1.56
A365	OD	24	.27	3.78				21	.24	2.64
	OS	27	.30	5.10				21	.10	1.98
A366	OD	21	.24	2.64	19			22	.13	1.56
	OS	19	.23	2.07	17			21	.24	2.64
A367	OD	19	.29	2.61	6			6		
	OS	17	.22	1.54	7			7		
A371	OD	19	.23	2.07	12	.15	.30	14	.25	1.00
	OS	21	.24	2.64	16	.21	1.26	16	.26	1.56
A372	OD	24	.38	5.47	19	.23	2.07	17	.32	2.24
	OS	22	.40	4.96	17	.32	2.24	15	.28	1.40
A373	OD	22	.27	3.34	19			15	.28	1.40
	OS	24	.35	5.04	20			19	.38	3.42
A374	OD	29	.41	7.79				19	.42	3.78
	OS	24	.44	6.33				21	.55	5.05
A375	OD	24	.44	6.33	21	.30	3.30			
	OS	24	.44	6.33	22	.32	3.84			
A376	OD	26.6	.39	6.25	21	.30	3.30			
	OS	26.6	.39	6.25	22	.32	3.84			
A377	OD	26	.39	6.24	19			21	.30	3.30
	OS	26	.33	5.28	19			22	.32	3.84
A378	OD	27	.30	5.10	19	.17	1.53	21	.24	2.64
	OS	29	.33	6.27	19	.23	2.07	22	.25	3.00
A483	OD	33	.18	2.64	20			29		
	OS	36	.24	5.40	17			29		
A484	OD	23	.25	2.25	17	.33	4.55			
	OS	22	.41	4.92	17	.54	3.78			

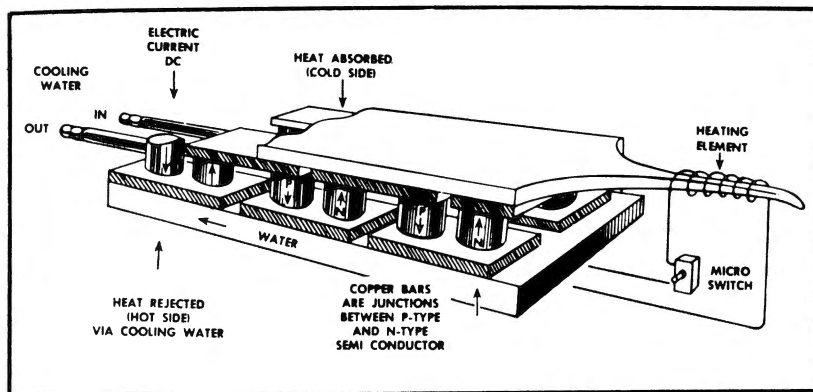


Fig. 5—Schematic diagram of Cryostylet freezing handle showing thermoelectric modules connected in series. A micro switch allows for defrosting of tip by a heating element (courtesy Frigitrionics, Inc., Bridgeport, Conn.).

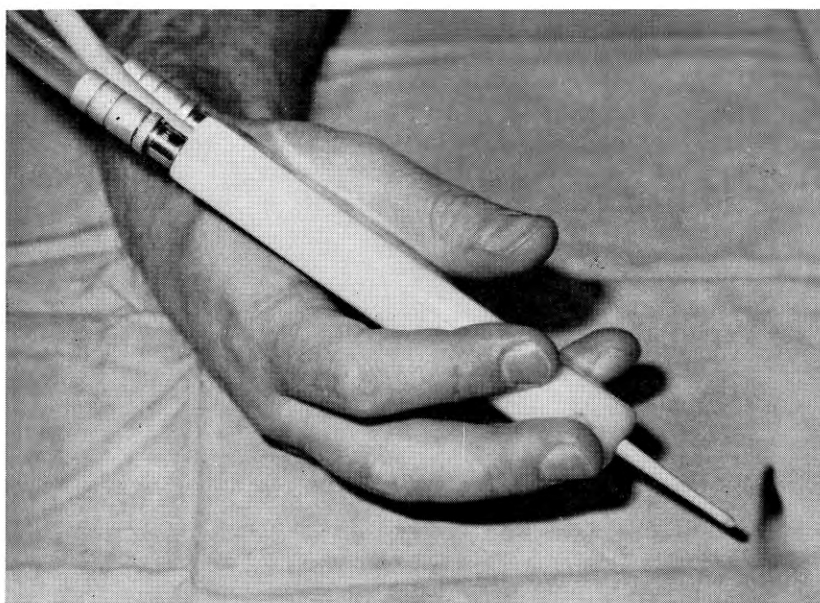


Fig. 6—Freezing handle of cryostylet. The surgeon's middle or index finger can activate a micro switch to defrost tip and disconnect the tip from frozen tissue after application with minimal trauma.

a Mueller electronic tonometer and recorder. The values for PO (opening intraocular pressure in mm Hg), F (rate of aqueous flow) and C (facility of outflow) were calculated using the tonographic tables by Schimek (1964). I was fully cognizant that the calculation of aqueous production from tonographic recordings is inaccurate and that constants used for the human eye cannot be used for the rabbit. Since my primary interest, however, was a relative change rather than absolute values, I felt that an adequate means of evaluating aqueous dynamic changes could be found by this method. This also makes it easier to compare results with those of other investigators who applied the same formula for their experimental tonographic findings (Polack and de Roeth, 1964; Bietti, 1950). Tonographic tracings on all treated animals were repeated at one- to two-week intervals following the procedure.

### *Intraocular Pressure*

Immediately following the completion of the cryocautery there was usually a slight rise of intraocular pressure (5 to 8 mm Hg), but in some instances there was a slight drop. In no instance did the rise reach the proportions previously described using the ring-type applicator. Since this did not occur in the human, it is probable that in the rabbit the closeness of the application to the limbus is responsible for the pressure rise.

After one week the intraocular pressure in 42 eyes fell an average of 8.52 mm Hg. Only two of the 42 eyes showed a slight rise in intraocular pressure. The drop of the PO ranged from 2 to 19 mm Hg. When the findings were subjected to a statistical analysis using the "t" test for paired observations,

$$\text{the } t^* \left( t^* = \frac{\bar{x} \sqrt{n}}{\hat{\sigma}} \right)$$

was found to be 10.456, giving a

TABLE 2

Summary of tonographic study following cyclocryocautery

Weeks after cyclocryocautery	1	2	4	8	12
Average decrease in PO (mm Hg)	8.52	4.89	4.62	5.77	4.75
Significance $p <$	.0001	.001	.001	.001	.01
Average decrease in F ( $\mu\text{l}/\text{min}$ )		1.78			1.36
Significance $p <$		.001			.001
Average change in C	No definite trend demonstrable				

significant P value of less than .0001.

The PO values at the end of the second week were subjected to a similar analysis. The average drop in PO after two weeks was 4.89 mm Hg. Four out of 38 eyes showed a slight rise in pressure, while the decrease in PO ranged from 2 to 12 mm Hg.  $t^*$  was calculated to be 6.21 for a P value of  $< .0001$ . This is also statistically significant.

Further analysis after four weeks showed an average decrease of intraocular tension of 4.62 mm Hg. Four of 34 eyes showed a slight rise in pressure, and in two eyes it was impossible to get a technically acceptable tracing. The drop in intraocular tension ranged from 1 to 10 mm Hg. Values for  $t^*$  were 4.204 and  $P < .001$ .

After eight weeks the situation was essentially the same with an average PO drop of 5.7 mm (from 1 to 10 mm Hg) and a  $t^*$  of 7.816, giving a significant P value of  $< .001$ . Before the animals were killed (at the end of 12 weeks), tonographic tracings were repeated, and the average drop of intraocular pressure at that time was 4.75 mm Hg. Six of 34 eyes showed increases from 1 to 4 mm Hg, while the decrease in the PO ranged from 3 to 13 mm Hg. Statistical evaluation still showed a significant level of  $< .01$  for the P value.

#### *Rate of Aqueous Flow*

Calculated values for F before cyclocryocautery were compared to F values 12 weeks after treatment. Values for forty eyes thus obtained were paired. In 10 eyes the F values either remained the same or increased slightly. In 30 eyes the F value decreased. The average F value before treatment was 4.22  $\mu\text{l}/\text{min}$  and after treatment, 2.85  $\mu\text{l}/\text{min}$ . When subjected to a statistical analysis, a  $t^*$  value of 5.112 was obtained, giving a highly significant P of  $< .001$ .

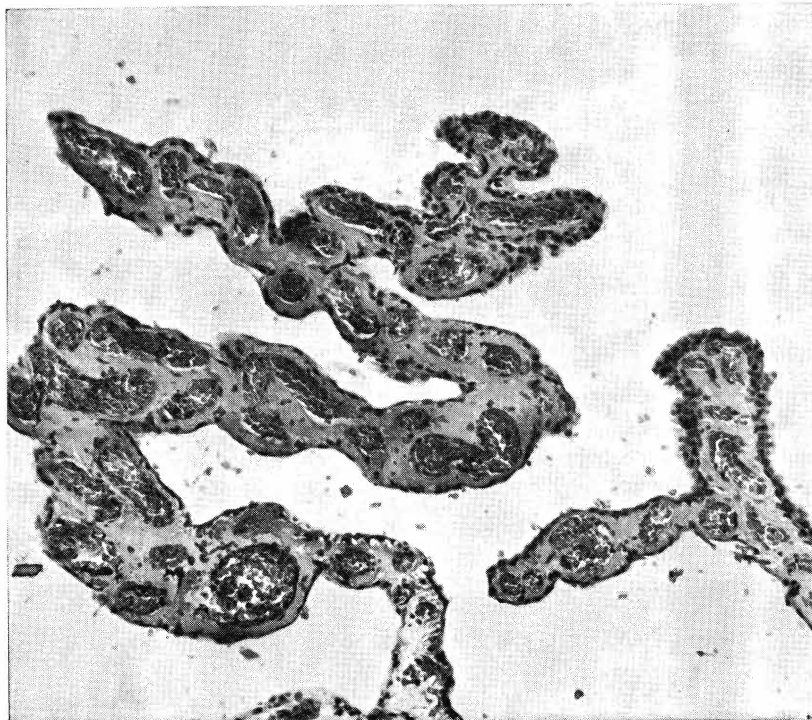


Fig. 7—Ciliary processes 12 hours after freezing showing hyperemia, hemorrhages, and endothelial changes of small vessels.

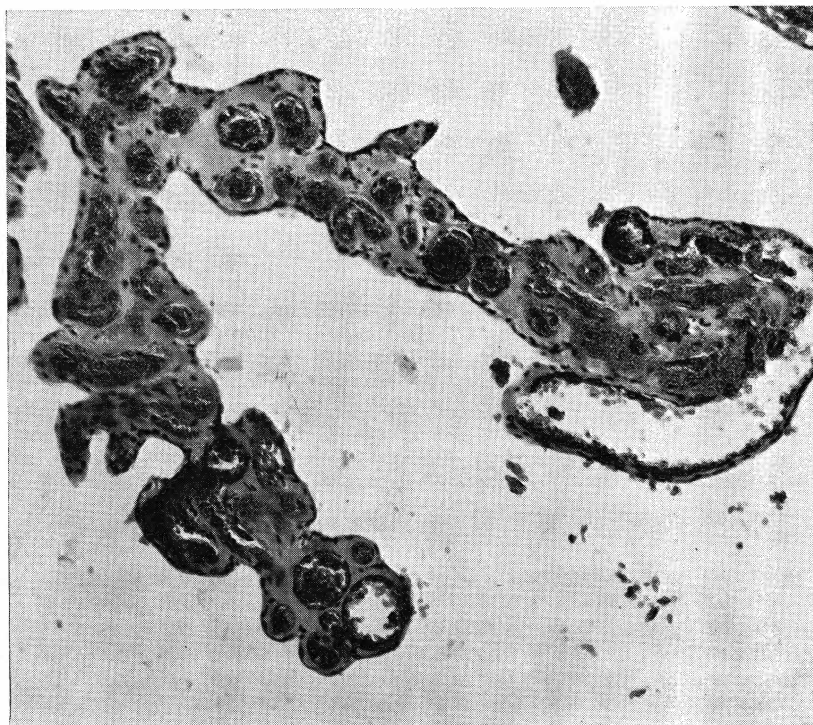


Fig. 8—Intraepithelial cyst 12 hours after freezing: hyperemia and hemorrhages into stroma.



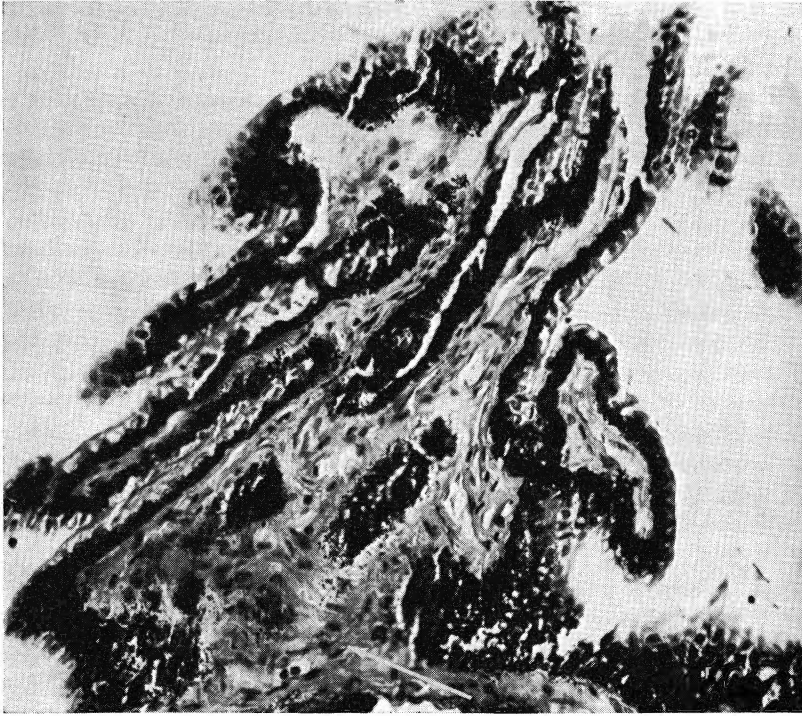


Fig. 9—Hyalinization of ciliary processes three weeks after freezing.

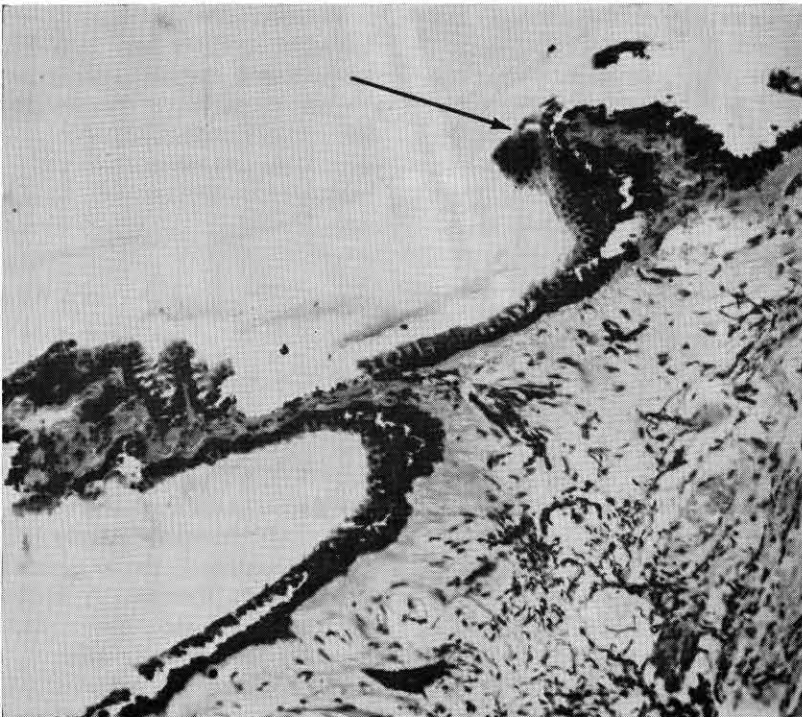


Fig. 10—Hyalinization of ciliary processes, partial atrophy, and areas of hyperplasia of pigment epithelium four weeks after freezing.

### *Facility of Outflow*

Calculated values for C were paired like the values for F before and 12 weeks after cryocautery. No definite trend in C values could be established. C values were greater in 21 eyes at the end of observation, and less or equal in 19 eyes at the end of the observation period. C values calculated at various times of the 12-week observation period likewise showed no definitely established trend. Tonograms for individual eyes both before, in the middle, and at the end of the 12-week period will illustrate the findings discussed above (table 1). Table 2 summarizes the results of the tonographic study.

### *Histology*

Sections of globes enucleated six to 12 hours after freezing showed swelling of the ciliary processes due to hyperemia, edema, and hemorrhages into the stroma (fig. 7). There was an apparent alteration of the endothelium of some small and medium-sized ciliary vessels. In most ciliary processes the non-pigmented epithelium was absent, except in those globes where ciliary processes continued on to the posterior surface of the iris. Such processes appeared fairly normal. Edema caused the formation of cystic spaces between the epithelial layers in some processes (fig. 8). A variable amount of pigmented epithelium was also destroyed, although in most sections some pigmented cells remained, covering the congested ciliary process. The hyperemia also involved the iris root, causing some thickening. Some edematous changes were also present in the chamber angle of most globes, but no fibrin or blood was observed in the anterior chamber.

After 48 hours most edematous changes in the ciliary processes, as well as in the chamber angle, had

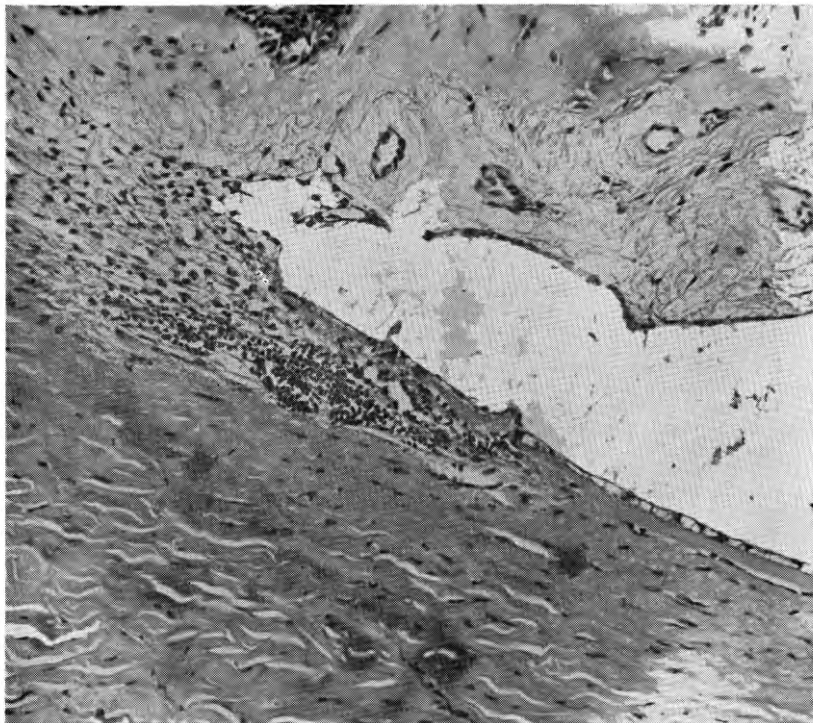


Fig. 11—Chamber angle of rabbit four weeks after freezing appears normal.

subsided. Hyperemia and hemorrhages persisted and there were seen free pigment granules in the posterior chamber surrounding the processes and an occasional fine vitreous strand, suggesting some alteration of its structure as a result of the freezing process.

In globes observed one to two weeks after freezing, the pigmented epithelium had regenerated. The only histological changes of significance were the deposition of hyaline-like substance around some blood vessels, a decrease in smaller vessels, and a general increase in the amount of connective tissue within the individual processes. These changes persisted over the observation period. After 12 weeks, in some globes there was an apparent decrease in the number of processes, and a number of ciliary processes appeared atrophic and fibrinous, but still were covered with ciliary epithelium (figs. 9 and 10). No permanent changes following this method of ciliary-body freezing were observed in either

cornea, sclera, or chamber angle (fig. 11). A similar observation was made by others (Polack and de Roeth, 1964).

The histologic changes observed were in good accord with those found by Polack and de Roeth (1964) who reported edema and hemorrhages followed by hyalinization and hyperplasia of pigment epithelium and an increase in connective tissue. They also observed more severe anterior chamber reactions and alterations in the vitreous which were largely absent in our study. The fact that these authors used a freezing tip with a temperature of  $-79^{\circ}\text{C}$ , probably accounts for the greater severity of changes, although the decrease in PO reported was less than that observed in our study. The same authors showed also that regeneration of the ciliary epithelium takes place most actively from 24 to 48 hours after freezing. They used radioautographs of the ciliary body labeled with tritiated thymidine to show the active regeneration of the

ciliary epithelium at this stage of the reparative process.

#### Measurement of Intraocular Temperatures During Cryo-application

Some measurement of freezing temperatures at the various tissues of the globe was felt desirable to select the temperatures best suited for the desired result and, at the same time, to leave unaffected other structures of the eye, notably the chamber angle, lens, and vitreous. For these measurements HT Ultra-Miniature Thermocouple probes of copper constantan with stainless steel sheathing material for a total diameter of .008 inch are well suited. These probes feature fast, accurate temperature response, with minimal disturbance of the environment. The read-out device for these experiments consisted of a Keithley Milli-microvolt meter and a Photovolt Varicord recorder.

When the Kelman Cryostylet was operated in the manner recommended by the manufacturer for cryogenic cataract extractions, the temperature of the applicator tip was measured at  $-12^{\circ}\text{C}$ . All measurements were taken on anesthetized rabbits with the eye in its normal position so as to not alter the physiological conditions of blood flow. The surface temperature of the sclera in the palpebral fissure area with the fissure held open was  $+32.9^{\circ}\text{C}$ . The miniature thermo-couple probes were placed in various parts of the globe (fig. 12), and temperature measurements taken before, during, and after removal of the cold probe until tissues returned to normal temperatures. As expected, the temperature drop was fastest and most pronounced in the superficial scleral lamellae, dropping to  $-9.2^{\circ}\text{C}$  in this experiment. In the deep sclera the temperature was  $-6.6^{\circ}\text{C}$ . With the tip temperature at  $-12^{\circ}\text{C}$ , no other freezing temperatures could be measured anywhere else in the globe. The temperature



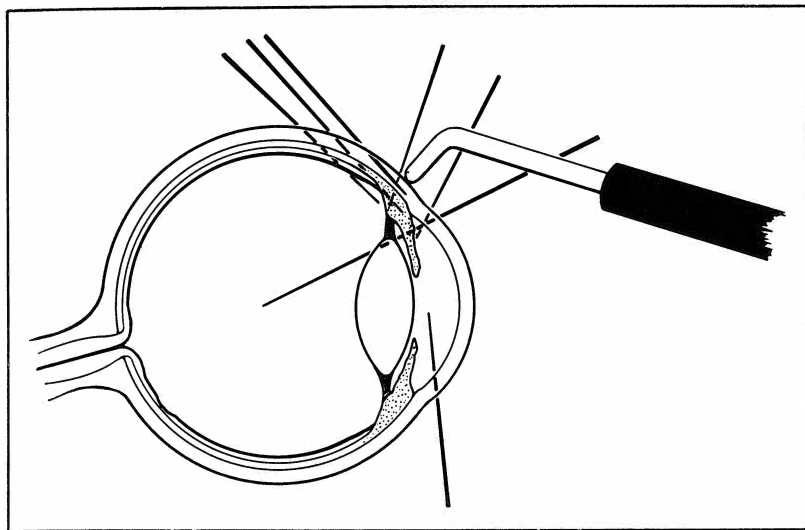


Fig. 12—Position of micro-thermocouples for intraocular temperature measurement during cyclocryocautery.

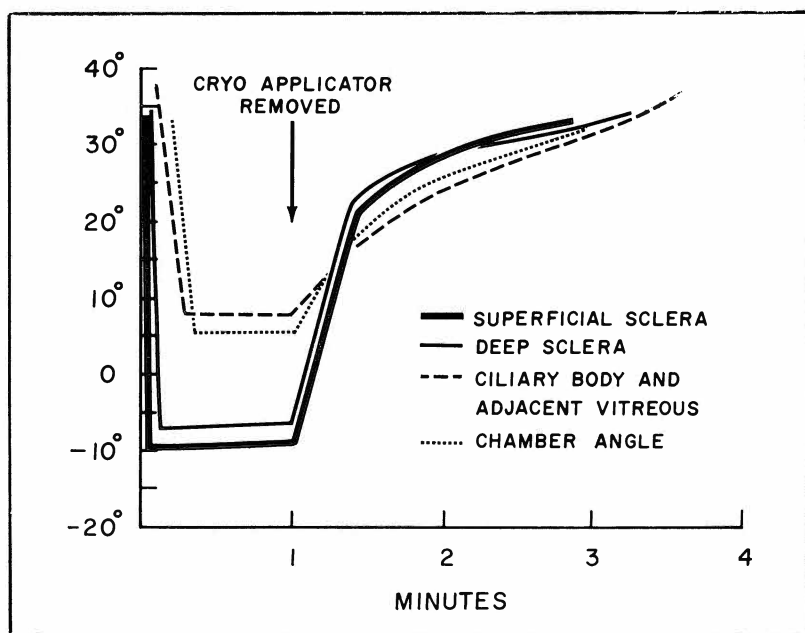


Fig. 13—Intraocular temperatures at various levels with applicator tip at temperature of  $-12^{\circ}\text{C}$ .

in the ciliary body dropped more slowly to  $+7.9^{\circ}\text{C}$ , and the same reading was taken in the peripheral vitreous adjacent to the ciliary body where a temperature of  $38^{\circ}$  was measured just before cryo-applications. The temperature recorded in the chamber angle was  $+5.3^{\circ}$ , whereas midway between the iris and pupillary margin a temperature of  $+13.2^{\circ}$  was recorded in the anterior chamber during cryo-applications. It was obvious that the temperature of the applicator tip was insufficient to bring about freezing of the ciliary body. Following removal of the probe all temperatures returned to pre-application levels within  $2\frac{1}{2}$  min, the sharpest rise occurring during the first 15 to 20 sec, after which a more gradual rise to normal temperatures took place. Figure 13 illustrates the temperature response of miniature thermo-couple probes at four different positions to cryo-applications over the ciliary body area with a tip temperature of  $-12^{\circ}\text{C}$ .

The experiment was repeated with the temperature of the applicator tip at  $-40^{\circ}\text{C}$ , a temperature found sufficient in previous animal experiments for the desired result, yet causing a minimum of undesirable side effects. During this experiment the temperature in the superficial and deep sclera dropped to  $-37^{\circ}$  and  $-32^{\circ}\text{C}$ , respectively, while in the ciliary body and adjacent vitreous, temperatures of  $-25^{\circ}$  to  $-19^{\circ}\text{C}$  were recorded. An even slight movement of the thermo-couple tip in this area during the experiment caused a change in temperature of several degrees. This was thought to be due to the varied character of the ciliary body structure containing connective and muscle tissues and a rich vascular network. In the anterior chamber angle sub-zero temperatures were recorded; however, midway between the pupillary margin and chamber angle the temperature did not fall below  $+5^{\circ}\text{C}$ . Following removal of the freezing tip, all tem-

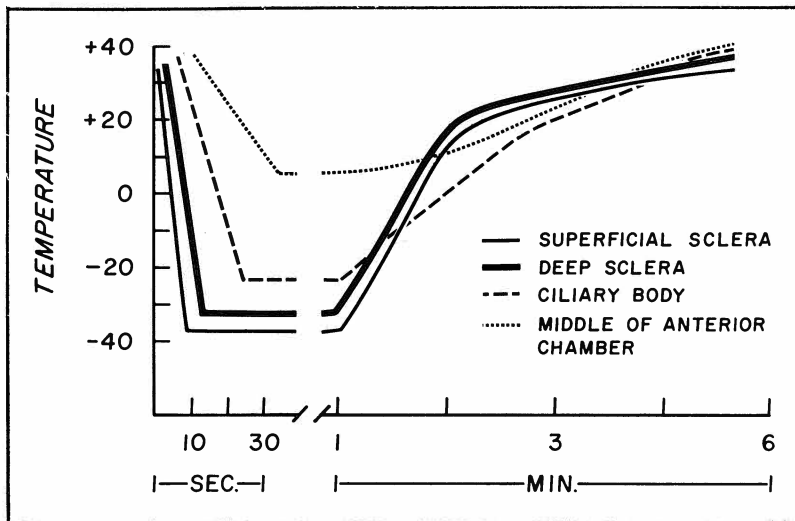


Fig. 14—Intraocular temperatures at various levels with applicator tip temperature of  $-40^{\circ}\text{C}$ .

peratures rose rapidly during the first 30 sec. In this experiment it took 6 min for the temperatures to reach starting levels. Figure 14 illustrates the temperature-time relationship during cryo-application with an applicator temperature of  $-40^{\circ}\text{C}$ .

#### Influence of Angio-cryocautery of Long Posterior Ciliary Arteries on Intraocular Pressure

As early as 1890, Wagenmann, in a treatise on the influence of retinal and choroidal circulation upon the nutrition of the eye, studied and described the effect of severing the long posterior ciliary arteries in rabbits. Since a reliable tonometer was not available at this time, his findings went largely unnoticed. In 1944, Guerry reported his findings on angiodyathermy of these vessels in a detailed study. He concluded that electrocoagulation of one long posterior ciliary artery reduced the intraocular pressure in both rabbits and humans for about two weeks and was relatively harmless. Coagulation of both long posterior ciliary arteries in the rabbits resulted in phthisis bulbi in 50% of the animals.

We have conducted a limited number of preliminary experiments to study the effect of cryocautery of one or both long posterior ciliary arteries on the tonographic tracings of rabbit eyes. A conjunctival incision was made about 5 mm from the limbus from the horizontal meridian, followed by incision of Tenon's capsule and identification of the artery after retraction of the rectus muscle with a strabismus hook. Cryo-coagulation for periods of 3 to 5 min was then carried out just anterior to the entrance of the vessel into the sclera, using a tip temperature of  $-40^{\circ}\text{C}$ . Immediately following the withdrawal of the tip the surrounding sclera was white, and numerous hemorrhages appeared. In six eyes one artery was so treated. This was followed by a mean drop in intraocular pressure of 6.2 mm Hg. The flow values and C values showed inconsistent changes. Six days following treatment the mean decrease in the PO was 2.4 mm; after 12 days the pressure in all but one eye had returned to pre-operative levels or slightly above. The one eye with decrease in pressure showed only a 2 mm Hg change which was thought to be

insignificant. Similar results were obtained when both arteries were treated with the cryocautery. Intraocular pressure fell on the average of 5.8 mm Hg in six eyes. Flow rates increased slightly and C values were increased also. After six days the intraocular pressure change was still an average of 5.5 mm Hg lower, but at the end of two weeks the intraocular pressure of all eyes had returned to pre-treatment levels. During this period slit lamp examinations revealed none of the corneal and anterior chamber reactions reported by Guerry (1944) for diathermy coagulation of these vessels. After two weeks the conjunctival and Tenon incisions were reopened, and the arteries inspected. There was no visible change in the vessel wall, and when it was severed, all vessels bled freely. It was felt that interruption of blood in large vessels by cryocautery was not practical or feasible. However, one important lesson can be learned from these experiments. The inadvertent electro-coagulation of one or both of these vessels during retinal detachment surgery is a dreaded complication, especially in cases where retinal breaks are located in the horizontal meridian.

In such cases the use of cryocautery to produce adhesive chorioretinitis as advocated by Deutschmann (1933; 1935) and presently advocated by Lincoff et al. (1964) and Kelman and Cooper (1963) will avoid this complication.

#### Clinical Cases

Since the animal experiments have shown cyclocryocautery to be a safe procedure and one that is effective in reducing intraocular pressure in a significant number of animals, we felt justified in using the procedure on a number of selected human cases. The following routine was followed in human cryo-coagulations. All eyes were prepared and draped, using the standard technique followed at

MCV. Ophthaine and 2% Xylocaine were used for surface anesthesia, akinesia, and retrobulbar injection. The applications were made with the Kelman reservoir temperature at  $-1^{\circ}$  to  $-3^{\circ}\text{C}$ , the tip temperature at approximately  $-40^{\circ}$ , through the conjunctiva 3 to 5 mm posterior to the limbus, using a total of eight to 12 applications and avoiding the meridians of the recti muscles. Immediately following the procedure the only effects noted were conjunctival congestion and subconjunctival hemorrhages at the application sites.

The most recent patients were treated in the same fashion except that the Freon operated Cryosurgical unit manufactured by Frigatronics was used. Tip temperatures of  $-40^{\circ}$  to  $-45^{\circ}\text{C}$  were used with this instrument also.

A total of eight patients with various forms of glaucoma (secondary glaucoma due to central retinal occlusion, advanced chronic open angle glaucoma, secondary glaucoma following trauma and hyphema) were tested by the method described above. In six patients the pressure was normalized and remained normotensive in the observation period of from 3 to 10 months. In two cases the intraocular pressure rose again to pre-treatment levels after two and four weeks, respectively. Retreatment was successful in one case; in the second case of traumatic glaucoma the second procedure succeeded in lowering the pressure from pretreatment levels of about 45 mm Hg to 32 mm Hg, but could not be lowered any further.

## Discussion

This study has shown that freezing of the ciliary body can reduce the intraocular pressure of experimental animals. Tonographic evidence suggests the mechanism by which this is brought about to be a reduction of aqueous production. Histologic evidence of this study and previous reports by other

authors on this subject suggest a slight, but permanent, alteration in the ciliary processes as the cause of the reduced aqueous flow. It is not clear at present whether the epithelial or stromal changes in the processes are primarily responsible for the decrease in their function. Further experiments to elucidate this point are planned for the near future. Our study on intraocular temperature measurement indicated that a tip temperature of  $-40^{\circ}\text{C}$  is sufficient to bring about the desired result. Experiments by other investigators with much lower temperatures have shown no enhanced effect and that their use might conceivably lead to extensive destruction of neighboring structures, especially the vitreous.

A pilot study on a limited number of animals suggests that a permanent reduction of intraocular pressure by freezing one or both long posterior ciliary arteries cannot be achieved. Histologic evidence points to the fact that only small vessels and capillaries can be permanently occluded by freezing through a process of endarteritis obliterans. While freezing of the long posterior ciliary arteries could not be recommended as a glaucoma procedure except in such cases where only a temporary reduction of pressure is desirable or as a preliminary procedure before intraocular surgery as suggested by Guerry (1944), it would seem that its use would be indicated in retinal detachment surgery, where retinal breaks are located in the horizontal meridian to obviate permanent accidental closure of these vessels by electro-diathermy.

The primary indication of cyclocryocautery in the human is in cases of hemorrhagic glaucoma where other intraocular surgery is extremely hazardous. The procedure, however, is completely free of complications and side effects and could be tried in such cases as congenital glaucoma or chronic simple glaucoma where previous filtering procedures have failed, or

where extremely constricted visual fields make such operations undesirable. Cryocautery has the advantage of not altering the anatomy of the ocular structures appreciably and, therefore, not making any further procedures more difficult. Its advantage over cyclodiathermy or cycloelectrolysis seems to lie in the fact that it is extremely unlikely to result in a phthisis bulbi. Deliberate attempts to over-treat some rabbit globes have not resulted in permanent damage other than a somewhat longer lasting anterior chamber reaction than was encountered in the routine treatment cases.

Reports from other cryo-surgeons (de Roeth, 1965, unpublished data) indicate a similar experience of absence of complications. Recently, however, Harrison (1965, unpublished data) made the statement that cyclocryocautery "can be overdone," and lists complications such as massive conjunctival chemosis, posterior synechiae, complicated cataract, and iris atrophy following treatment. It is my opinion that the excessively low temperatures of  $-106^{\circ}\text{C}$ , used in these experiments for long periods of time, are responsible for the undesirable side effects, and add little to the efficacy of the procedure. Permanent corneal opacities have been reported, but are extremely unlikely to occur, as at temperatures of  $-80^{\circ}\text{C}$ , it requires freezing of 60% of the cornea, according to Chi (1965, unpublished data), to result in permanent damage. Similar experiments by Kaufman (Kaufman, Capella and Robbins, 1964) have demonstrated the remarkable ability of the cornea to repair damage from freezing.

While my series of patients is small, it indicates that the procedure was successful in six out of eight cases of glaucoma which would otherwise have had a very poor prognosis. The immediate rise in intraocular pressure which was observed to a marked degree in the rabbit experiments, using a ring

TABLE 3

	Preoperative		Postoperative	
	C.	F.	C.	F.
Case 1	.008	2.64	0.21	1.05
Case 3	0.22	12.32	0.33	5.94
Case 5	0.13	3.64	0.12	0.60

type applicator and to a lesser degree when the Cryostylet was used, was not observed in the human eyes. This phenomenon is probably caused by the fact that applications over the ciliary body of man were carried out 4 to 5 mm behind the limbus, thus largely avoiding even temporary occlusion of aqueous outflow channels and freezing of chamber angle structures. In those three eyes where comparative tonographic studies were possible before and after the procedure, the C values increased materially in two and remained steady in the third. In all three eyes flow rates were materially reduced also. These figures are summarized in table 3.

### Summary

1. A method of cyclocryocautery, using the Kelman Cryostylet, is described. On rabbit eyes this brings about a statistically significant lowering of intraocular pressure and reduction of aqueous flow over an observation period of three months. The effects upon the facility of outflow are variable. Side effects are minimal.
2. The intraocular temperature was measured at various points during and after cryocautery. An applicator temperature of about  $-40^{\circ}\text{C}$  was found sufficient for the desired result with minimal side effects.
3. Angiocryocautery of one or both long posterior ciliary vessels resulted only in a temporary reduction of intraocular pressure, as permanent obliteration of these vessels was not possible by this method.

4. In a small series of eight patients with primary and secondary glaucomas, the procedure described was effective in six cases. Possible indications in other forms of glaucoma are discussed.

### Acknowledgement

I wish to acknowledge the help and guidance of Dr. DuPont Guerry, III, professor of ophthalmology at MCV, in the critical evaluation of this study and of R. C. Williams, R. S. Ruffin, and Dr. S. F. Cleary of the department of biophysics in technical problems and statistics.

### References

- BIETTI, G. Chorioretinitis adesiva da crio applicazioni episclerali. 14th Concilium Ophthalmologicum. Spain, 1933.
- BIETTI, G. Criocausticazioni episclerali come mezzo di terapia nel distacco retinico. *Boll. d'Ocul.* 13: 576-617, 1934.
- BIETTI, G. Surgical intervention on the ciliary body. *J. Am. Med. Assoc.* 142: 889-897, 1950.
- CHI, L. Symposium on Cryosurgery. New York Eye and Ear Infirmary, March, 1965 (unpublished data).
- DAN, L. R., AND B. W. PRIESTLY. Cryocautery in ophthalmology. *Am. J. Ophthalmol.* 59: 259-264, 1965.
- DE ROETH, A. Symposium on Cryosurgery. New York Eye and Ear Infirmary, March, 1965 (unpublished data).
- DEUTSCHMANN, R. Die Behandlung der Netzhautablösung mit Jodtinktur und Kohlensäureschnee. *Klin. Monatsbl. f. Augenh.* 94: 349, 1935.

DEUTSCHMANN, R. Über zwei Verfahren bei Behandlung der Netzhautablösung nebst-Bemerkungen zur Genese des Netzhauttrisses und seines Verhältnisses zur Entstehung der Ablösung. *Klin. Monatsbl. f. Augenh.* 91: 450-456, 1933.

GAZALA, J. R., W. J. GEERAETS, AND D. GUERRY, III. Angiocautery of the aqueous outflow channels in the rabbit eye—tonographic study. *Am. J. Ophthalmol.* 60: 247-255, 1965.

GUERRY, D., III. Angiodiathermy of the long posterior ciliary arteries and its use in the treatment of glaucoma. *Am. J. Ophthalmol.* 27: 1376-1393, 1944.

HARRISON, R. Symposium on Cryosurgery. New York Eye and Ear Infirmary, March, 1965 (unpublished data).

KAUFMAN, H. E., J. A. CAPELLA, AND J. E. ROBBINS. A study of enzyme activity in corneal repair. *Invest. Ophthalmol.* 3: 34-46, 1964.

KELMAN, C. D. Cryosurgery for cataract extraction and the treatment of other eye diseases. *Highlights Ophthalmol.* 7: 181-209, 1964.

KELMAN, C. D., AND I. S. COOPER. Cryosurgery of retinal detachment and other ocular conditions. *Eye, Ear, Nose, Throat Monthly* 42: 42-46, 1963.

LINCOFF, H. A., J. M. MCLEAN, AND H. NANO. Cryosurgical treatment of retinal detachment. *Trans. Am. Acad. Ophthalmol. Otolaryngol.* 68: 412-432, 1964.

POLACK, F. M., AND A. DE ROETH, JR. Effect of freezing on the ciliary body (cyclocryotherapy). *Invest. Ophthalmol.* 3: 164-170, 1964.

SCHIMEK, R. A. *Simplified Tonography* (pamphlet). Chicago: V. Mueller & Co., 1964.

SHEPPARD, L. B. The anatomy and histology of the normal rabbit eye with special reference to the ciliary zone. *Arch. Ophthalmol.* 66: 896-904, 1961.

WAGENMANN, A. Experimentelle Untersuchungen über den Einfluss der Circulation in den Netzhaut- und Aderhautgefäßen auf die Ernährung des Auges, insbesondere der Retina, und über die Folgen der Sehnervendurchschneidung. *Arch. Ophthalmol.* 36: 1-36, 1890.