



# Clinicopathological Conference: Abnormal Sex Characteristics and Intracranial Mass

Discussants:

CLARK T. RANDT, M.D., *professor of neurology, New York University, and director of the neurological service, New York University Medical Center*

GERALD A. GILDERSLEEVE, M.D., *assistant professor, department of radiology, Medical College of Virginia*

JULIO H. GARCIA, M.D., *assistant professor, department of pathology, Medical College of Virginia*

## Clinical History

A 21 year old white, right handed male was admitted 1/29/65 with complaints of weakness, anorexia and vomiting of 16-18 months' duration. The first symptoms were nocturia (two to three times per night), pain in the right lower quadrant, postprandial vomiting, and weight loss of 16 lbs. A gastrointestinal series in 1963 was negative. In July, 1963, he was admitted to another hospital. The examination revealed his weight to be 108 lbs. There was absence of beard and chest hair and sparse axillary hair. Pubic hair was of female distribution. His voice was high pitched, his arms long, shoulders narrow, hips broad, muscle mass poorly developed, and the external genitalia were small.

In 1954 the patient underwent operative correction of bilateral cryptorchidism. Two years later, bilateral gynecomastia was treated surgically. In 1961, a buccal smear was done and revealed a male sex chromatin pattern. The patient was started on intramuscular testosterone and over the next four months gained approximately 16 lbs.

In October, 1964, he noted the onset of polydipsia and polyuria. Urine specific gravity was 1.007; sugar and protein determination on the urine was negative. He con-

tinued to gain weight and remained on testosterone therapy by injections and sublingual tablets, and in April, 1964, his weight was 140 lbs. He had abundant axillary hair, and psychologically he was markedly improved. Despite continuation of the testosterone, by July, 1964, he had lost 10 lbs., had recurrent vomiting and was feeling tired. A gastrointestinal series revealed a duodenal polyp. The vomiting responded to six bland feedings per day. Through the fall of 1964 episodes of vomiting recurred and the patient developed increasing weakness, intolerance to cold and weight loss. He weighed 110 lbs in December, 1964.

On admission to the Medical College of Virginia Hospital his weight was 103 lbs, and his vital signs were a blood pressure of 90/60, pulse 52 per minute, respiration 18 breaths per minute and temperature 98 F. His general appearance was that of a thin, pale, listless, young male who appeared older than his stated age, chronically ill and in no acute distress. There was a surgical scar on each breast. The skin appeared to be warm and dry. There was a female distribution of pubic hair and the testicles were soft and small. Neurological examination revealed a staggering gait which appeared more

*Beginning with this issue, the QUARTERLY will publish selected clinicopathological conferences presented at the Medical College of Virginia. Transcriptions of these teaching exercises are prepared and edited by R. Page Hudson, M.D., department of pathology, and John Moon, M.D., department of medicine. Discussants include members of the faculty of the school of medicine and, on occasion, invited guests.—Ed.*

related to weakness than to ataxia. He was well oriented, and aside from the listlessness appeared to be alert. Cranial nerve examinations were not remarkable except for a loss of upward gaze. Visual fields were normal, the fundi negative, and the pupils equal and reactive to light and accommodation. There was no sensory deficit. Motor function was intact, but muscles were hypotonic and weak throughout. Deep tendon reflexes could be elicited bilaterally but were markedly depressed. Cerebellar functions appeared to be within the performance of a chronically ill individual.

*Laboratory data:* Hemoglobin 13.0 gm per 100 ml, white cell count 9,600 per mm<sup>3</sup> (polymorphonuclears 70%, lymphocytes 29% and monocytes 1%). The urine was negative for protein and sugar, and had a specific gravity of 1.004. The BUN was 15 mg, calcium 9.8 mg, and phosphorus 4.25 mg per 100 ml. The alkaline phosphatase was 3.0 Bessey-Lowry units (normal 2.9 units). Serum sodium was 143 mEq, chlorides 105 mEq, potassium 4.4 mEq and CO<sub>2</sub> 24.3 mEq per liter. Seventeen-hydroxy steroids excretion was less than 1 mg per 24 hours (normal 3–10 mg per 24 hours) and 17 ketosteroids were also less than 1 mg per 24 hours (normal 8–20 mg

per 24 hours). Urinary FSH—6 units per 24 hours (normal 10–50 mouse uterine units per 24 hours). There was no alteration in the urinary 17-ketosteroids or 17-hydroxy steroids following Metopirone, but following a standard intravenous ACTH test there was a two-fold increase in both 17-ketosteroids and 17-hydroxy steroids within 24 hours, and a four-fold increase within 72 hours. Protein bound iodine could not be done because of a recent cholecystogram, but a T-3 red cell uptake revealed a 31% uptake. EEG was read as showing an abnormal record with diffuse slowing as well as a specific slow wave abnormality in the right frontal area. This record was interpreted as suggestive of a destructive lesion in the deep right frontal Sylvian region. A brain scan with radioactive mercury revealed an area of increased uptake in the right frontal area. Lumbar puncture revealed normal pressure, protein of 56 mg per 100 ml, with 9 red cells and 46 lymphocytes per mm<sup>3</sup>.

A chest film showed a small heart with slight demineralization of the bony thorax. Skull series revealed no abnormality. The pineal body was in the midline. The sella appeared smaller than normal. A left carotid arteriogram and a right

retrobrachial arteriogram showed no displacement of the vessels and no tumor stain.

After admission the patient continued to vomit, had an urinary output which was slightly higher than his intake, and complained of extreme lethargy and weakness. He was treated with intravenous fluids, and following the studies reported above, was started on replacement therapy with cortisone acetate, 12.5 mg every six hours, Cytomel, 25 micrograms each day, and desiccated thyroid two grains daily. Within 24 hours of starting the replacement therapy, the urinary output was 6,000 cc and from then on the patient required Pitressin for control of his urinary output. His general condition improved rapidly, his appetite was restored, and he was able to sit up without his previous syncopal attacks. He complained more and more of headache and on 2/25/65 a pneumoencephalogram was performed.

#### Clinical Discussion

*Dr. Clark T. Randt:* This case presents a formidable endocrinological problem. In preparation for this discussion I have learned a number of things and I hope that I shall be able to transmit some of them to you.

This history is of a 21-year-old man whose difficulties began approximately a year and a half prior to his admission to this hospital in January, 1965. His illness started in a nonspecific way with weakness, anorexia, weight loss and vomiting. It is worthy of note that some 21 months prior to this last admission he developed nocturia times two or three and some pain in the right lower quadrant of his abdomen, as well as postprandial vomiting associated with weight loss. On the first hospital admission 18 months prior to January, 1965, it was noted that the patient had absence of the secondary sexual characteristics. He had a eunuchoid configuration and hypoplastic genitalia. He had inability to concentrate his urine (at least on the specimen reported) and there was no sugar in his urine. His symptoms of nocturia some six months prior to this might have signalled the onset of diabetes insipidus. Testosterone therapy benefited him with a significant increase in weight and an increase in the amount of axillary hair. He was also said to be psychologically improved. However, he again began to lose weight and had recurrent vomiting with easy fatiguability. He developed increasing weakness and intolerance to cold. The latter symptom suggests, that in addition to hypogonadism, he had also developed hypothyroidism. The weakness and weight loss might be early signs of adrenal insufficiency. The operation for cryptorchidism at age 10 suggests an association with the subsequent hypogonadism, but, at that age, one could not be certain about gonadal deficiency. At the age of 12 he developed bilateral gynecomastia which was treated surgically. In the absence of liver disease or starvation, one would assume that the interstitial cells of his testes were secreting more estrogens than androgens. The appearance of gynecomastia at puberty is certainly not an unusual event and is thought to be due to a disturbance in the ratio of estrogen to androgen secretion. Again we would

not, at that point, be led to a diagnosis of hypogonadism. However, five years later at the age of 17, the patient had definite delayed puberty. A testicular biopsy was done to investigate the possibility of primary hypogonadism. I would assume that Klinefelter's syndrome was suspected and, in light of this, a buccal smear was done. It is reported that the patient had a male sex chromatin pattern. The possibility still remains that he might have a chromatin negative Klinefelter's syndrome. We are not provided with an estimate of his gonadotrophins nor the results of the testicular biopsy which would be necessary to enable us to make such a diagnosis.

At the time of his most recent admission, the patient was found to have a pulse of 52 per minute which, in the absence of evidence of increased intracranial pressure and in the presence of sensitivity to cold, suggests hypothyroidism. He appeared chronically ill and his skin was dry, which also suggests this diagnosis.

The neurological examination was positive only in that the patient had a paralysis of upward gaze. This is known as Parinaud's sign and has a high degree of localizing value. In ablation experiments in animals and in the clinical-pathologic correlation in man, this particular sign has a high correlation with lesions in the region of the superior colliculi in the rostral portion of quadrigeminal plate. The laboratory data again suggested diabetes insipidus since there was no urinary concentration above a specific gravity of 1.010.

He had normal serum sodium and chloride. I mentioned the possibility of hypoadrenalism. In secondary hypoadrenalism findings of normal sodium and chloride might well be due to the fact that aldosterone secretion is routinely affected, but this is not true in secondary hypoadrenalism. The 17-hydroxy- and 17-ketosteroids were markedly reduced, indicative of adrenal insufficiency. Gonadal insufficiency

will also cause a reduction in the 17-ketosteroid determination. A Metopirone test was done. Metopirone inhibits the enzyme 11  $\beta$ -hydroxylase necessary for the formation of hydrocortisone. The decreased elaboration of adrenal hormone in turn allows an increased secretion of adrenocorticotrophic hormone from the pituitary gland. If this is the case, the urinary ketosteroids should be increased at least two-fold following the administration of Metopirone. It is noteworthy here that there was no alteration in the secretion of the urinary 17-ketosteroids and 17-hydroxy steroids following the administration of Metopirone. This was corroborated by an ACTH test which produced two-fold increase in the 17-keto- and 17-hydroxy steroid secretion. This latter result is indicative of the functional integrity of the adrenal cortex. These tests make it clear that the previously postulated hypoadrenalism was secondary due to pituitary failure, rather than a primary failure of the adrenal gland. The T-3 uptake was 31%, within normal limits for this laboratory.

He had an abnormal EEG with diffuse slowing in the record and a focal slow wave abnormality in the right frontal area. It would be of interest to me to know how much slowing. Slowing below four cycles per second is usually associated with more or less superficial disease, whereas focal slowing to four to seven cycles is more likely to mean a deep seated lesion in the brain. The brain scan corroborated the focal finding in the EEG in that it showed an increased uptake deep in the right frontal area. The chest x-rays showed a small heart which would be compatible with hypoadrenalism. Skull x-rays showed the sella turcica not to be enlarged which militates against a pituitary tumor. The pineal was observed to be in the midline. Bilateral carotid angiography failed to reveal evidence of a space-occupying lesion.

The patient's course in the hospital was characterized by markedly

beneficial response to replacement therapy with cortisone, tri-iodothyronine and desiccated thyroid. His general condition improved rapidly and he was able to sit up and cooperate better than previously. It is noteworthy that his syncopal attacks were seemingly relieved. Syncopal attacks may occur in a wide variety of neurological diseases, but in this particular case having a strong suggestion of hypoadrenalism, I think it would be reasonable to assume that the syncope was related to small blood volume and cerebral anemia due to deficient cerebral circulation and oxygenation. It is noted that he complained increasingly of headache and a pneumoencephalogram was performed. I would like very much to see the films of this patient before proceeding to expose you to my differential diagnoses of his multiple problems.

*A brief videotape was shown.*

*As can be seen in figure 1, the patient was a slender individual with female hair distribution and with a healing surgical scar on his head.*

*Dr. Gerald A. Gildersleeve:* Skull films show midline calcification representing the pineal gland, which measures 1 cm in width. This is within the upper limits of normal in size, within normal limits of position in the lateral views. The frequency of pineal calcification varies with age. Twenty percent of people at age 20 have pineal calcification of varying extent. Calcification of the gland is rarely seen in infants and small children. If one sees pineal calcification under 12 years of age, or calcification more extensive than 1 cm in diameter, one should strongly consider pinealoma. Cystic changes within the pineal structure can make the otherwise normal gland appear enlarged.

Views from the pneumoencephalogram study demonstrate the lateral ventricles to be larger than normal (fig. 2). Many attempts actually to visualize the region of the aqueduct were unsuccessful. Air did pass in quantity into the lateral

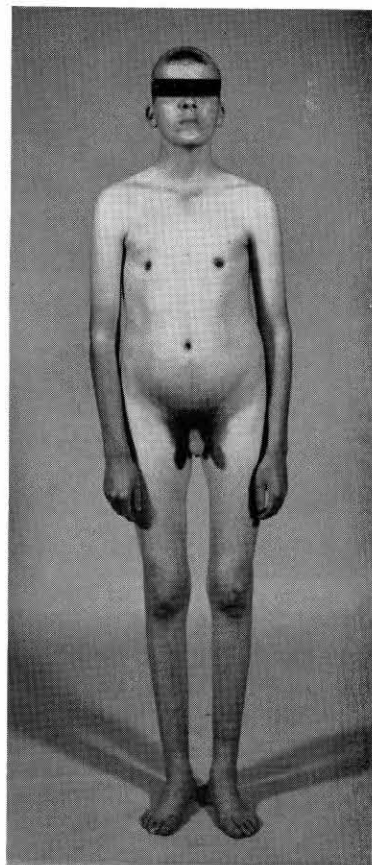


Fig. 1—Picture of patient four months after surgery showing asthenic habitus, female escutcheon, poor regrowth of scalp hair.

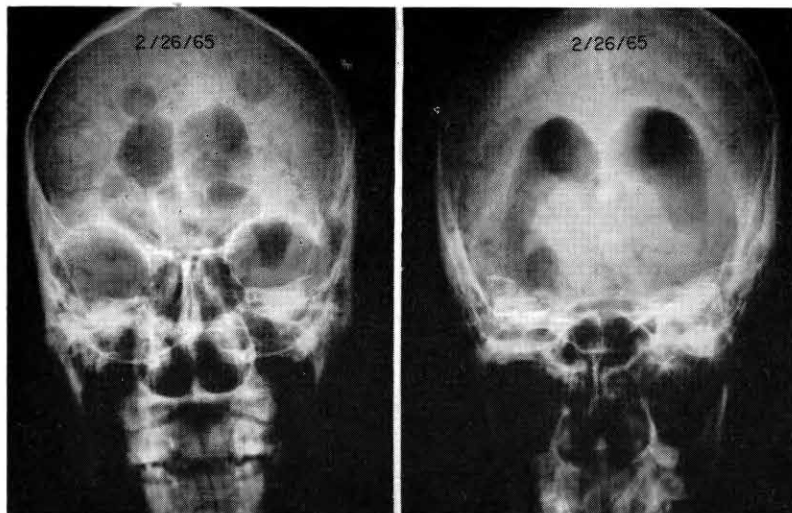


Fig. 2—Pneumoencephalogram showing enlarged lateral ventricles. The aqueduct does not suggest extrinsic pressure. A normal suprapineal recess appears as an air shadow above the pineal calcification.

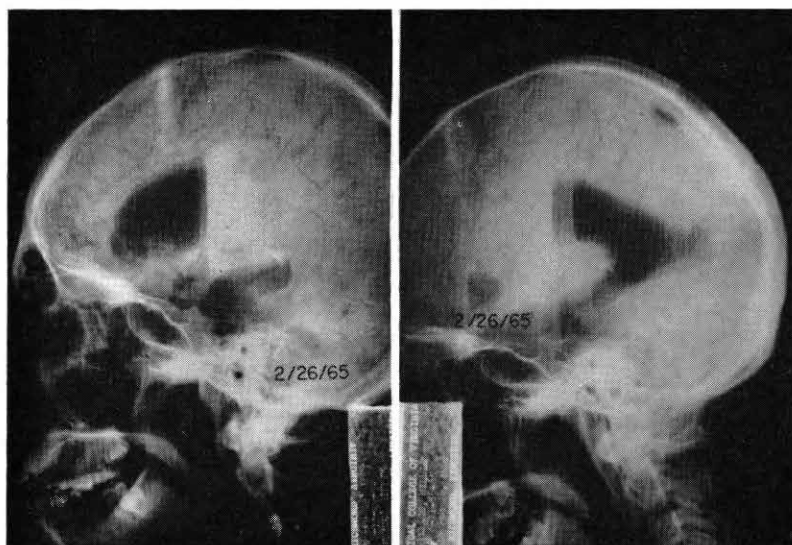


Fig. 3—Pneumoencephalograms representing "brow-up" and "brow-down" positions respectively. Air is noted in the substance of the right frontal lobe, beneath the anterior horn. A mass is suggested in the anterior part of the suprasellar cistern. The inferior aspect of the right anterior horn is encroached upon.

ventricles, and the failure to visualize the aqueduct may have been fortuitous or perhaps due to some narrowing from extrinsic pressure. A normal suprapineal recess appears as a small collection of air above the calcification. If this is a communicating false cavity representing the necrotic center of a tumor mass, it is nevertheless in normal position for the suprapineal recess and has very smooth walls. In the substance of the right frontal lobe, beneath the anterior horn of the right lateral ventricle, there is a rounded slightly irregularly margined collection of air seen in both "brow-up" and "brow-down" positions (fig. 3). In addition there is a posterior margin of an associated mass in the anterior part of the suprasellar cistern. The anterior part of the third ventricle does not seem to be enlarged in proportion to the middle and posterior portions of the ventricle, and this could indicate narrowing due to extrinsic pressure. The inferior aspect of the right anterior horn of the lateral ventricles is distorted by encroachment of the mass.

So there is a right frontal tumor mass close to the midline with a cavity centrally contained, communicating with the ventricular system. Beyond this no definite evidence of a mass lesion is defined. There is questionable extrinsic pressure on the anterior aspect of the third ventricle, and it is certainly possible that the enlargement of the lateral ventricles and portions of the third ventricle could be due to partial obstruction of the aqueduct. *Dr. Randt:* I generally approach neurological problems from two points of view: first, the localization; and second, the etiology. This patient poses complicated neurologic and endocrine problems. Parinaud's sign (the paralysis of upward gaze) has a high degree of localizing value to the region of the superior colliculi in the rostral portion of the quadrigeminal plate. Very often along with paralysis of upward gaze one finds dilatation of the pupils which are often unequal and

lack a reaction to light but react to accommodation. These individuals may have some truncal ataxia with a tendency to fall, in the anterior-posterior plane. Occasionally one finds a bilateral decrease in hearing presumably because of extension of the lesion from the superior colliculi to the inferior colliculi, thus interrupting the auditory pathways. Cerebellar signs, as produced by involvement of the cerebellar outflow over the brachium conjunctivum, and, sometimes pyramidal tract signs including spasticity, also accompany lesions in this area. The evidence for a lesion in the suprapineal recess adjacent to the superior colliculi is convincing. There is considerable evidence to indicate hypothalamic involvement with the diabetes insipidus due to interruptions of the supraoptico-neurohypophysial tract in the hypothalamus proper. Stalk section or ablation of the pituitary does not cause persistent diabetes insipidus. This evidence places the lesion in the hypothalamus.

Hypogonadism might be related to a hypothalamic lesion. In animal ablations one finds that destructive lesions in the posterior portion of the median eminence and the basal tuberal region are likely to produce manifestations of hypogonadism. In man, hypoadrenalism from hypothalamic lesion is poorly localized although it has been reported that the stimulus for the elaboration of ACTH from the pituitary was selectively depressed in a case of sarcoidosis involving the hypothalamus. Localization of the area in the hypothalamus responsible for stimulating the anterior hypophysis to elaborate ACTH remains not well localized. This lack of hypothalamic localization is also true of the control of thyroid-stimulating hormone elaborated by the anterior pituitary. Bilateral lesions of the ventromedial hypothalamus give rise to adiposity, whereas lesions in lateral portions of the midhypothalamus may produce cachexia. The cachexia here may well be related to such hypothalamic involvement or may be

secondary to the hypoadrenalism, which the patient showed.

One of the most interesting features of this case to me is the question of whether the patient had secondary hypogonadism or primary hypogonadism. I mentioned the possibility of a chromatin-negative Klinefelter's syndrome earlier, and the finding here of a normal FSH (follicle-stimulating hormone) level of 6 units suggests to me that the hypogonadism was primary.

As regards the EEG, I believe that the indications are of a superior collicular midbrain lesion extending into the hypothalamus. The EEG and the increased radioactive mercury uptake in the right frontal area probably indicate extension into the deep portion of the right frontal lobe. There were no clinical manifestations that one could identify to corroborate this, but that is not unusual since the non-dominant frontal lobe is a silent area.

As far as the etiology is concerned, I would think that a chromophobe adenoma would be extremely unlikely. The presence of midbrain signs with Parinaud's sign and the normal appearance of the sella turcica by x-ray, probably exclude this diagnosis. A craniopharyngioma is unlikely for the same reasons, plus the fact that about 85% of craniopharyngiomas would be expected to show some suprasellar calcification. These are the two most common tumors to produce endocrine disturbances with secondary effects in the gonads, the thyroid and the adrenals. The dogma is that the gonads are the first involved and the thyroid and the adrenal follow. In this instance I believe there is an exception to that rule in that it is likely that primary hypogonadism will be demonstrated. The localization is better in the pineal recess and adjacent regions. Lesions residing in this location are the pinealoma, pineoblastoma, teratomas and gliomas of the astrocytic variety. Of these four, I would think that the extension into the hypothalamus and into the deep portion of the

right frontal lobe would be more in favor of pineoblastoma. The findings of 46 lymphocytes per mm<sup>3</sup> in the cerebrospinal fluid would suggest this variety of pineal neoplasm. The pineoblastoma may give rise to implants at distant sites, so one may, indeed, have cells which look very much like lymphocytes introduced into the cerebrospinal fluid and misidentified. In any case, lymphocytes may be attributed to some irritative process close to the ventricular surface or close to the subarachnoid space. Here our attention centers on the intraventricular area. This would account for the pleocytosis in the cerebrospinal fluid. The pineoblastoma is one of the few tumors found exclusively in the brain which have a tendency to disseminate in the subarachnoid space or throughout the ventricular system.

#### *Clinical Diagnosis*

1. Klinefelter's syndrome
2. ? Pineal tumor
3. Pituitary tumor

#### *Dr. Randt's Diagnosis*

1. Pineoblastoma
2. ? Chromatin negative Klinefelter's syndrome

#### *Pathological Discussion*

*Dr. Julio H. Garcia:* We have been able to obtain and review tissue from earlier surgery and biopsies. In the breast there was hyperplasia of the ductal epithelium with periductal edema and lymphocyte infiltrates, all considered to result from estrogen stimulation. The testicular biopsy revealed hyalinization of seminiferous tubules, absence of germinal cells, and a relative hyperplasia of interstitial cells. The changes were consistent with those expected with the Klinefelter syndrome. The original buccal smear for sex chromatin study was reported on your protocol as negative, that is "male," or "XY." This is how it was reported from another hospital where it was done. On reviewing their slide and our new

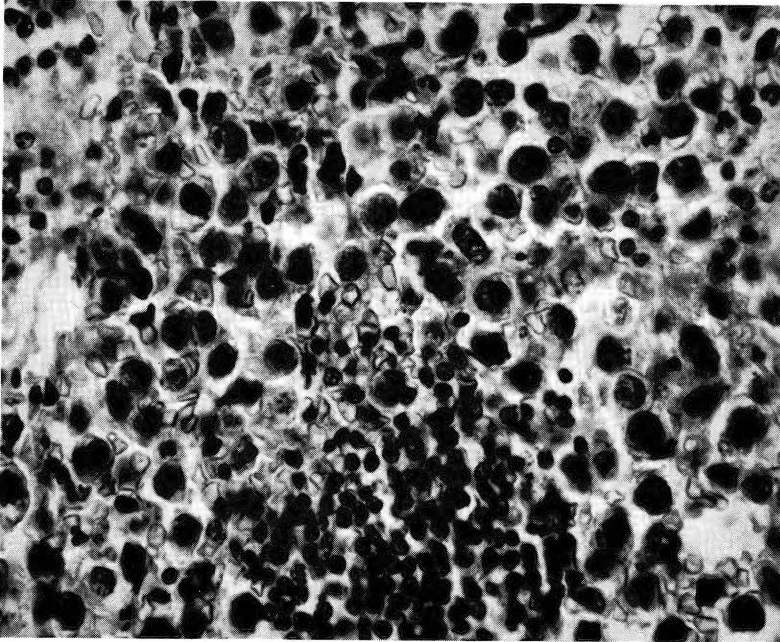


Fig. 4—Typical microscopic field of the pineal tumor showing the two cell types (400X).

ones, it was determined the patient was actually chromatin positive or "female," that is, genotype XX or XXY probably, although chromosome studies have not yet been done. You will recall that Barr and co-workers (1949, 1950 and 1951) noted that the nuclei in cells from females usually contained a mass that distinguished them from the cells of males. This was a startling and valuable discovery.

Dr. Randt has related well the clinical signs and symptoms with his concept of the brain lesions. He referred to the comparable or analogous experimentally-induced lesions in laboratory animals. I shall attempt to correlate briefly clinical abnormalities observed in our patient with similar abnormalities in animals reproducible by stimulation and/or destruction of hypothalamic nuclei.

1. Diabetes insipidus has been experimentally obtained by destruction of paraventricular and supra-

optic nuclei (Bailey and Bremer, 1921).

2. Dysgonadism, by which I mean the coexistence of male somatic features with high estrogen levels producing gynecomastia, testicular atrophy, etc., could perhaps be equated with the continuous estrus noted in rodents with destruction of the median eminence (Hilarp, 1949).

3. Appetite disturbance, that is anorexia and other eating disturbances, are symptoms that can be reproduced through excitation of lateral hypothalamic nuclei in monkeys and other animals (Delgado and Anand, 1953).

4. Paralysis of upward gaze is well known to occur with compressive lesions of the superior colliculi (Kulenbeck, 1949).

5. Headaches, projectile vomiting and syncopal attacks are more difficult to account for on the basis of a single morphological abnormality, but, in my opinion, may result from increased intracranial pressure, perhaps secondary to intermittent occlusion of the Sylvian aqueduct.

We can, therefore, arrive at the conclusion, as Dr. Randt did, that we are dealing with a mass that, from the clinical and radiological points of view, extends from the quadrigeminal plate, affects the hypothalamic nuclei and reaches the right frontal lobes (ventricular cavity), since this is the area from which the biopsy was obtained.

Microscopic examination of the tissue revealed neoplastic structure basically composed of two cell types (fig. 4); one a small cell that closely resembles lymphocytes, and larger cuboidal cell elements that display hyperchromatic nuclei, frequent atypical mitotic figures, and a scanty clear cytoplasm with well-defined cell membranes. Vascular and connective tissue stroma are very abundant and no argyrophilic fibers can be demonstrated. The overall appearance of groups of these cells in this tumor has been referred to as a mosaic pattern.

We have designated this neoplasm, pineal teratoma (atypical),

TABLE 1

Presenting Signs and Symptoms with Pinealomas (58 Patients)\*

1. Disturbance of vision, papilledema	90%
2. Headaches, nausea and vomiting	70%
3. Paralysis of upward gaze	50%
4. Diabetes insipidus	26%
5. Obesity and/or dysgonadism	18%
6. Precocious puberty	5%

\*Modified from: W. O. Russell and E. Sachs, *Arch. Path.*, 35: 869, 1943.

according to the classification of tumors of the pineal body area offered by Russell and Rubenstein (1963).

From a report by Russell and Sachs (1943), in which 58 cases of patients with a similar histological diagnosis are analyzed, we have extracted data expressing the frequency of signs and symptoms percent of the total number (table 1).

Following the craniotomy, our patient has experienced some improvement, particularly of his visual acuity. Much of the evidence of intracranial pressure has disappeared but most of the other symptoms and signs remain to some degree. At home with his parents, he is ambulatory and able to take care of himself.

*Pathological Diagnosis*

1. Pineal teratoma (atypical)
2. Klinefelter's syndrome

References

BAILEY, P. AND F. BREMER. Experimental diabetes insipidus. *Arch. Int. Med.* 28: 773-803, 1921.

BARR, M. L. AND E. G. BERTRAM. A morphological distinction between neurones of the male and female, and the behavior of the nucleolar satellite during accelerated nucleoprotein synthesis. *Nature* 163: 676-677, 1949.

— AND E. G. BERTRAM. The behavior of nuclear structures during depletion and restoration of nissl material in motor neurons. *J. Anat.* 85: 171-181, 1951.

—, L. F. BERTRAM, AND H. A. LINDSAY. The morphology of the nerve cell nucleus, according to sex. *Anat. Rec.* 107: 283-292, 1950.

DELGADO, J. M. R. AND B. K. ANAND. Increase of food intake induced by electrical stimulation of lateral hypothalamus. *Amer. J. Physiol.* 172: 162-168, 1953.

HILLARP, N. A. Studies on localization of hypothalamic centres controlling gonadotrophic function of hypophysis. *Acta Endocr.* 2: 11-23, 1949.

KUHLENBECK, H. AND R. N. MILLER. The pretectal region of the human brain. *J. Comp. Neurol.* 91: 369-407, 1949.

RUSSELL, D. S. AND L. J. RUBENSTEIN. *Pathology of Tumors of the Nervous System.* Baltimore: Williams & Wilkins Co., 1963, pp. 173-183.

RUSSELL, W. O. AND E. SACHS. Pinealoma, a clinicopathologic study of seven cases with a review of the literature. *Arch. Path.* 35: 869-888, 1943.