

2015

MRI Evaluation of Lumbar Disc Degenerative Disease

Pokhraj Suthar
S.S.G. Hospital

Rupal Patel
Virginia Commonwealth University

Chetan Mehta
S.S.G. Hospital

Narrotam Patel
S.S.G. Hospital

Follow this and additional works at: http://scholarscompass.vcu.edu/orthop_pubs

 Part of the [Orthopedics Commons](#)

Copyright © 2015 Journal of Clinical and Diagnostic Research

Downloaded from

http://scholarscompass.vcu.edu/orthop_pubs/2

This Article is brought to you for free and open access by the Dept. of Orthopaedic Surgery at VCU Scholars Compass. It has been accepted for inclusion in Orthopaedic Surgery Publications by an authorized administrator of VCU Scholars Compass. For more information, please contact libcompass@vcu.edu.

MRI Evaluation of Lumbar Disc Degenerative Disease

POKHRAJ SUTHAR¹, RUPAL PATEL², CHETAN MEHTA³, NARROTAM PATEL⁴

ABSTRACT

Introduction: Lower back pain secondary to degenerative disc disease is a condition that affects young to middle-aged persons with peak incidence at approximately 40 y. MRI is the standard imaging modality for detecting disc pathology due to its advantage of lack of radiation, multiplanar imaging capability, excellent spinal soft-tissue contrast and precise localization of intervertebral discs changes.

Aims and Objective: To evaluate the characterization, extent, and changes associated with the degenerative lumbar disc disease by Magnetic Resonance Imaging.

Study Design: Cross-sectional and observational study.

Materials and Methods: A total 109 patients of the lumbar disc degeneration with age group between 17 to 80 y were diagnosed & studied on 1.5 Tesla Magnetic Resonance Imaging machine. MRI findings like lumbar lordosis, Schmorl's nodes, decreased disc height, disc annular tear, disc herniation, disc bulge, disc protrusion and disc extrusion were observed. Narrowing of the spinal canal, lateral recess and neural foramen with compression

of nerve roots observed. Ligamentum flavum thickening and facet arthropathy was observed.

Result: Males were more commonly affected in Degenerative Spinal Disease & most of the patients show loss of lumbar lordosis. Decreased disc height was common at L5-S1 level. More than one disc involvement was seen per person. L4 – L5 disc was the most commonly involved. Annular disc tear, disc herniation, disc extrusion, narrowing of spinal canal, narrowing of lateral recess, compression of neural foramen, ligamentum flavum thickening and facet arthropathy was common at the L4 –L5 disc level. Disc bulge was common at L3 – L4 & L4 – L5 disc level. Posterior osteophytes are common at L3 - L4 & L5 –S1 disc level. L1- L2 disc involvement and spondylolisthesis are less common.

Conclusion: Lumbar disc degeneration is the most common cause of low back pain. Plain radiograph can be helpful in visualizing gross anatomic changes in the intervertebral disc. But, MRI is the standard imaging modality for detecting disc pathology due to its advantage of lack of radiation, multiplanar imaging capability, excellent spinal soft-tissue contrast and precise localization of intervertebral discs changes.

Keywords: Degenerative disc disease, Intervertebral disc, Sciatica pain

INTRODUCTION

Lower back pain secondary to degenerative disc disease is a condition that affects young to middle-aged persons with peak incidence at approximately 40 y. With respect to radiologic evidence of lumbar disc degenerative disease, the prevalence of disc degeneration increases with age, but degenerated discs are not necessarily painful. Low back pain secondary to degenerative disc disease affects men more than women. The main symptom of disc degeneration after low back pain is sciatica. Sciatica pain occurs mostly on one side of the body. It is a sharp shooting type of pain. Mild tingling sensation, dull ache, or burning sensation can occur. Pain may radiate to the calf or sole of the foot. Sciatic pain aggravates on standing, walking, bending, straining and coughing. In severe case, patient becomes unable to move around [1,2]. Patients with lumbar disc degenerative disease can be presented with sensory disturbances in legs, claudication and relief of pain with bending forwards.[3] There are many risk factors associated with the lumbar disc degenerative disease like advancing age, smoking, obesity, trauma, heavy weight lifting, height, genetic factors[4] and hereditary factors. Certain occupations like machine drivers, carpenters and office workers are also associated with it [5].

The basic purpose of conducting this study is to evaluate the relation between different aspects of lumbar degenerative disc disease and their MRI findings. Antero-posterior (AP) and lateral views of the plain X-ray can be helpful in visualizing gross anatomic changes in the intervertebral disc. It is best visualized on lateral view of X-ray. However, MRI is the standard imaging modality for detecting disc pathology due to its advantage of lack of radiation, multiplanar imaging capability, excellent spinal

soft-tissue contrast and precise localization of intervertebral discs changes [6,7].

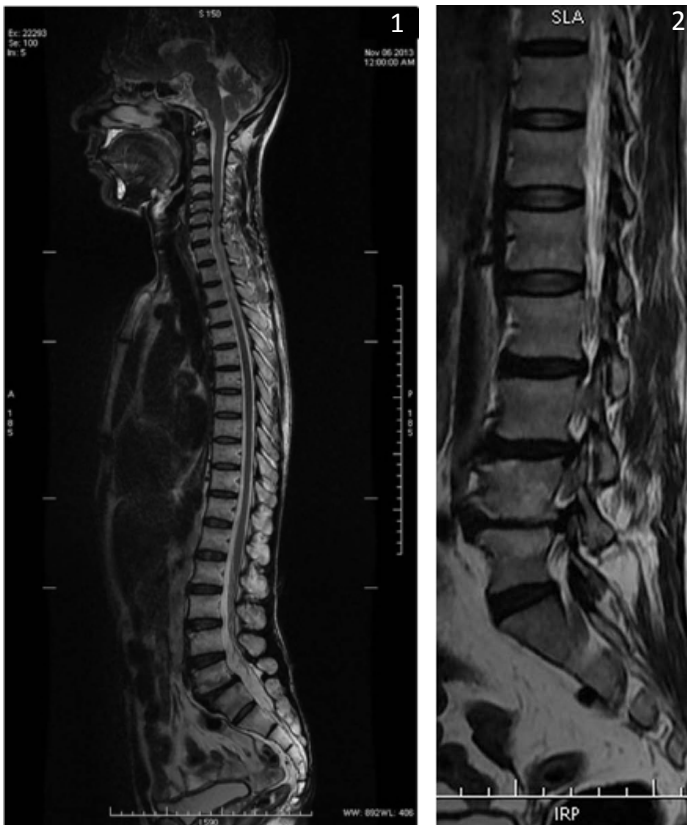
AIMS AND OBJECTIVE

- MR Imaging characterization of the disc degenerative changes of the lumbar spine.
- To evaluate extent of the involvement of the degenerative disc disease and its sequel.
- To identify the changes associated with the degenerative disc disease.

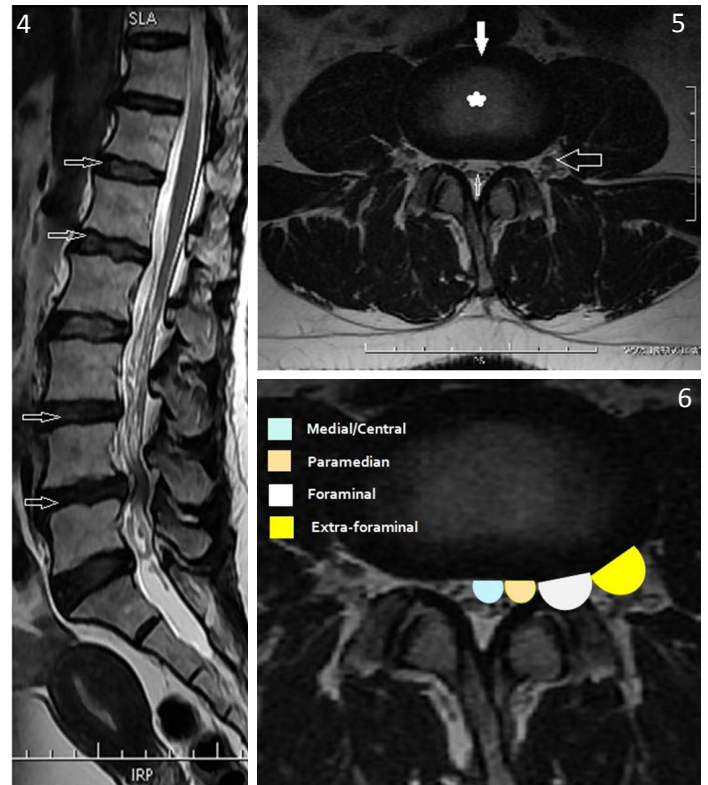
MATERIALS AND METHODS

This was a cross-sectional and observational study. The duration of the study was 2 months from 1st November 2013 to 31st December 2013. A total 109 patients of lumbar disc degeneration were diagnosed on 1.5 Tesla MRI machine. All the observation was done by three Radiologists (Professor, Associate Professor and Resident). Patients between 17 to 80 y of the age with low back pain were included in the study after obtaining a verbal consent. Patients with the history of trauma, prior surgery, spinal infections, active malignancy, pregnancy, cervical spine involvement, age < 17 y and > 80 y were excluded from the study. In the study 109 patients were enrolled and their demographic findings noted. The following MRI findings were noted: lumbar lordosis preserved or not [Table/Fig-1,2], Schmorl's nodes present or not [Table/Fig-3], decreased disc height as compared to the upper and lower vertebral levels.

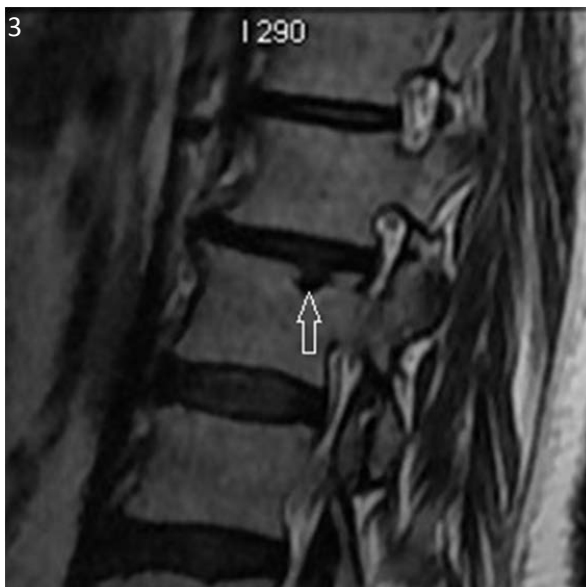Disc desiccation: It is a common degenerative change of intervertebral discs. On MRI imaging, the disc loses its central high T2 signal [8] [Table/Fig-4]. Normally, central nucleus pulposus shows



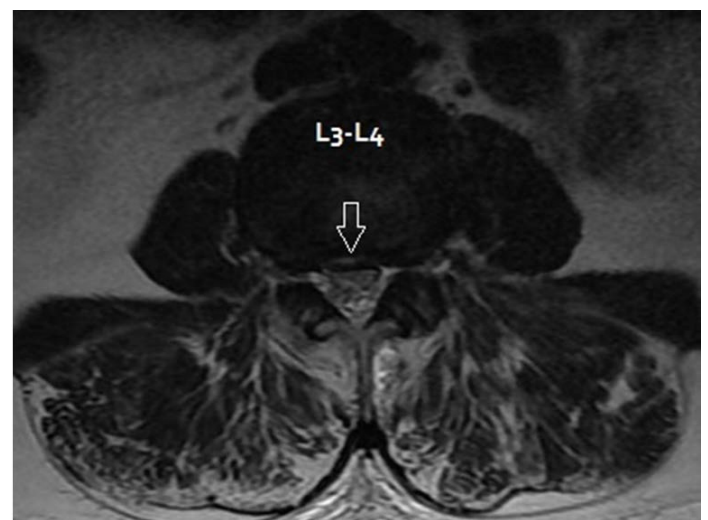
[Table/Fig-1]: Sagittal T2 Weighted MR Image: Normal lumbar lordosis
[Table/Fig-2]: Sagittal T2 Weighted MR Image: Loss of lumbar lordosis with straightening of lumbar spine. Decreased L4-L5 disc height with degenerative changes in adjacent end plate is present. L2-L3, L3-L4 & L4-L5 posterior disc bulge



[Table/Fig-4]: T2 Weighted Sagittal MR Image: Lumbar Disc Desiccations (open white arrow) **[Table/Fig-5]:** Axial T2 Weighted MR Image- Normal: High signal intensity nucleolus pulposus in center (solid white star) and peripheral low signal intensity annulus fibrosus in disc (solid white arrow). Look normal traversing (open small white arrow) & exiting nerve roots (open large white arrow)
[Table/Fig-6]: Axial T2 Weighted MR Image for axial localization: Medial/Central, Paramedian, Foraminal & Extra-foraminal



[Table/Fig-3]: Sagittal T2 WI shows Schmorl's node at the superior aspect of L2 vertebral body (open white arrow)



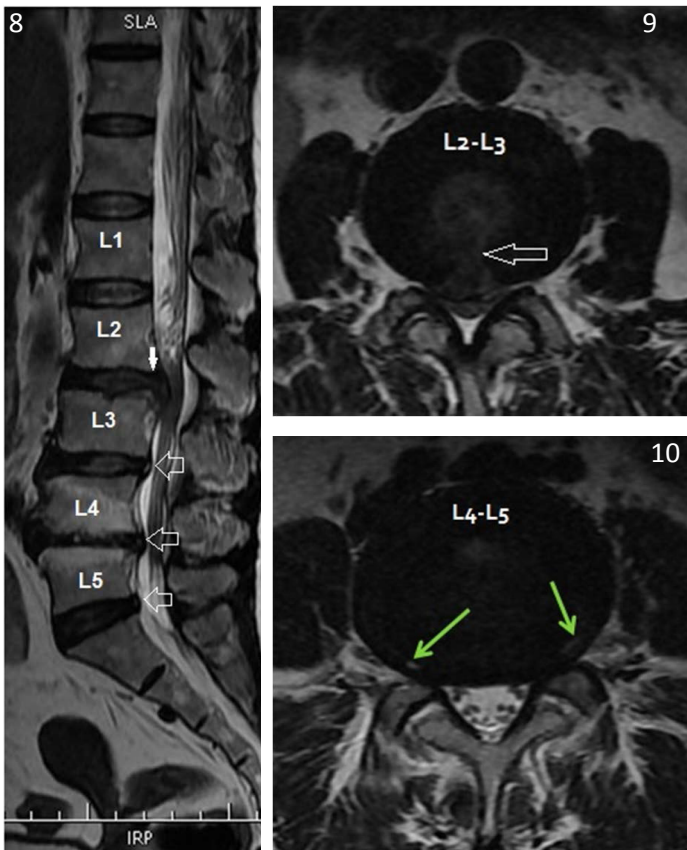
[Table/Fig-7]: Axial T2 WI: High signal intensity in annulus fibrosus at medial position of L3- L4 disc suggestive of Annular Fissure/Tear (open white arrow). Narrowing of spinal canal & bilateral lateral recess with compression of bilateral exiting nerve roots noted

high signal intensity on T2WI and peripheral annulus, low signal intensity on T2WI [Table/Fig-5].

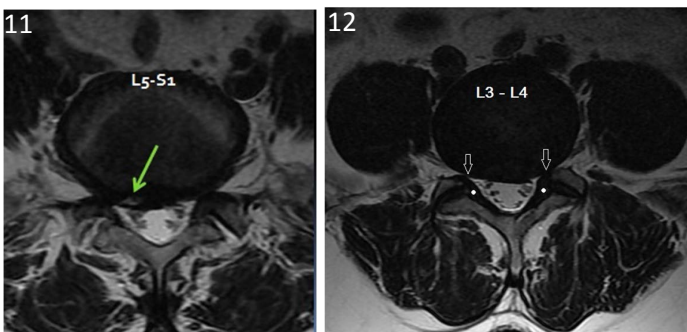
Annular tear: It is also called annular fissure and is a separation between annular fibers, avulsion of fibers from vertebral body insertion or break through fibers involving one or more layer of the annular lamella. Tear in the disc is seen as hyperintense on T2 Weighted images. Annular tear is further classified according to axial location into: central/medial, paramedian/lateral recess, foraminal/subarticular and extra-foraminal [Table/Fig-6-11]. Foraminal or subarticular disc herniation often very troublesome for the patient because compression of a 'Dorsal Root Ganglion'. Extra-foraminal is very rare.

Disc herniation: Whenever the displacement of disc material beyond the limits of the intervertebral disc space is called as a disc herniation. A herniated disc may or may not be covered by annulus fibrosus. Herniation can be focal or bulging. When herniation is less than 180° disc circumference it is called a focal disc herniation and when it is 180° to 360° beyond the edges of the ring apophyses it is called disc buldge [Table/Fig-12]. If herniation & buldge was present, it was marked with a "Y".

Disc protrusion & extrusion: Disc protrusion indicates that the distance between the edges of the disc herniation is less than the distance between the edges of the base. If disc protrusion was present it was marked with "Y". Whenever the distance between the edges of the disc material is greater than the distance at the base is called as disc extrusion [Table/Fig-13,14].



[Table/Fig-8]: Sagittal T2 Weighted MR Image of same patient: High signal intensity in annulus fibroses at L2- L3 disc suggestive of Annular Fissure with herniation of disc material in spinal canal & caudal migration of herniated disc material (solid white arrow). Narrowing of spinal canal is present. L3-L4, L4-L5 & L5-S1 shows posterior annular tears (open white arrow). Note Decreased disc height of L4- L5 with adjacent end plate high signal intensity. Loss of lumbar lordosis is seen
[Table/Fig-9]: Axial T2 Weighted MR Image: High signal intensity in annulus fibroses at medial/central part of L2- L3 disc (open white arrow) suggestive of Annular Fissure with herniation of disc material in spinal canal. Narrowing of spinal canal & bilateral lateral recess with compression of bilateral traversing as well as exiting nerve roots is seen
[Table/Fig-10]: Axial T2 Weighted MR Image: High signal intensity in annulus fibroses at bilateral foraminal position of L4- L5 disc (green arrow) suggestive of Annular Fissure with disc buldge. Narrowing of spinal canal & bilateral lateral recess with compression of bilateral exiting nerve roots is seen

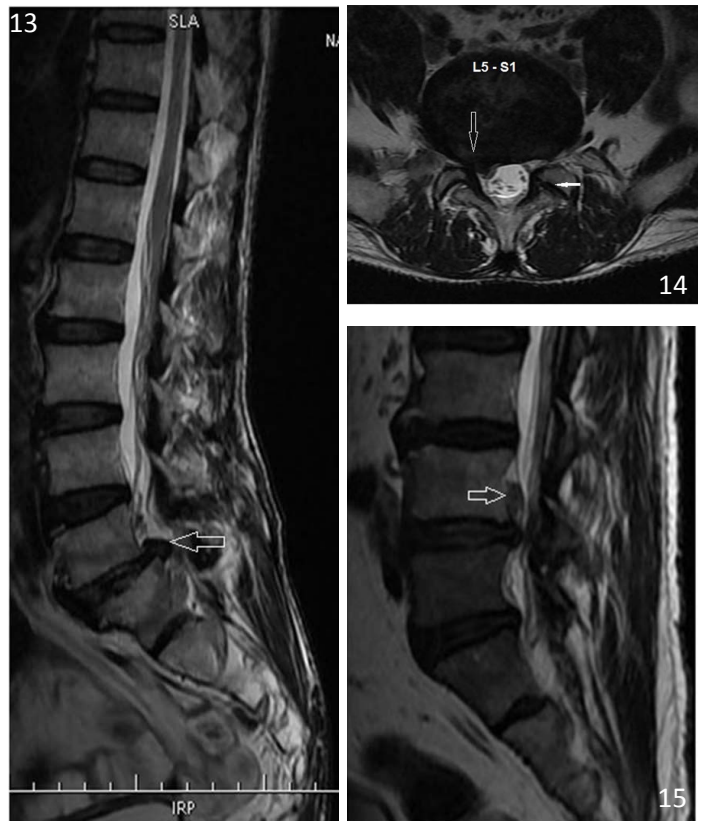


[Table/Fig-11]: T2 Weighted Axial MR Image: High signal intensity in annulus fibroses at right paramedian location of L5- S1 disc (green arrow) suggestive of Annular Fissure with disc herniation. Narrowing of spinal canal & bilateral lateral recess with compression of bilateral exiting nerve roots is seen
[Table/Fig-12]: T2 Weighted Axial MR Image: L3-L4 Disc bulge (Involvement of greater than 180° circumference). Narrowing of spinal canal and bilateral recess (open white arrow) with compression of exiting nerve roots is present. Ligamentum flavum appears thickened (solid white circle) with bilateral facet arthropathy

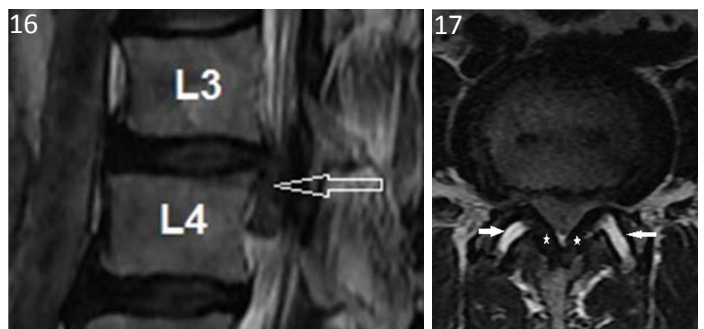
Migration: Whenever displacement of disc material is away from the site of extrusion it is called migration. Migration can occur either in cranial or caudal directions [Table/Fig-15,16].

Sequestration: When the displaced disc material has completely lost any continuity with the parent disc it is called sequestration.

Ligamentum flavum thickening: Ligamentum flavum thickening was measured on the axial image, perpendicular to the spinal canal axis and parallel to the lamina, where ligamentum flavum were seen along their entire length & measurement were taken at the half length



[Table/Fig-13]: T2 Weighted Sagittal MR Image: L5- S1 disc extrusion (white open arrow) with narrowing of spinal canal is seen
[Table/Fig-14]: T2 Weighted Axial MR Image of same patient: High signal intensity in annulus fibroses at right foraminal location of L5- S1 disc (open white arrow) suggestive of Annular Fissure with disc extrusion. Narrowing of spinal canal is present. Right lateral recess narrowing with compression of right exiting nerve roots is seen. Ligamentum flavum appears normal. However bilateral facet arthropathy (solid white arrow) is present
[Table/Fig-15]: Sagittal T2 Weighted MR Image : High signal intensity in annulus fibroses at L4- L5 disc with herniation of disc material in spinal canal & cranial migration of herniated disc material (open white arrow) leads to narrowing of spinal canal. Loss of lumbar lordosis is noted



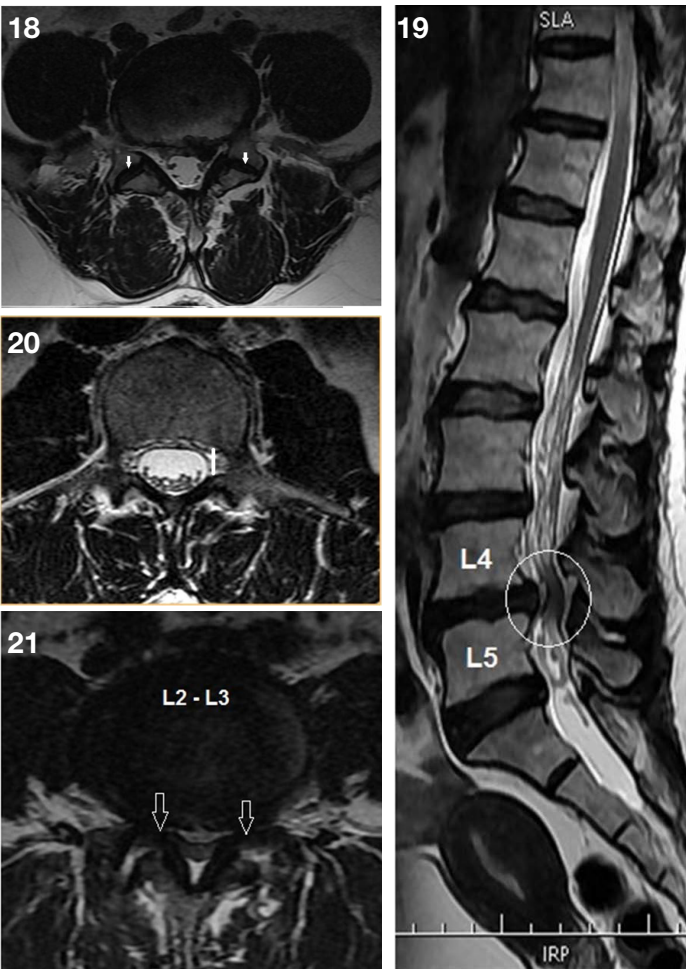
[Table/Fig-16]: Sagittal T2 Weighted MR Image : High signal intensity in annulus fibroses at L3- L4 disc with herniation of disc material in spinal canal & caudal migration (open white arrow) of herniated disc material leads to narrowing of spinal canal
[Table/Fig-17]: Axial T2 Weighted MR Image: Bilateral ligamentum thickening (solid white star). However facet joints appear normal (open white arrow)

of ligament flavum. According to Park et al., a mean thickness of the ligamentum flavum of 4.44 mm in the patients with the spinal canal stenosis labeled as thickened and 2.44 mm thickness in the control group. So, we had labeled a >4 mm ligamentum flavum thickening as thickened [9] [Table/Fig-17].

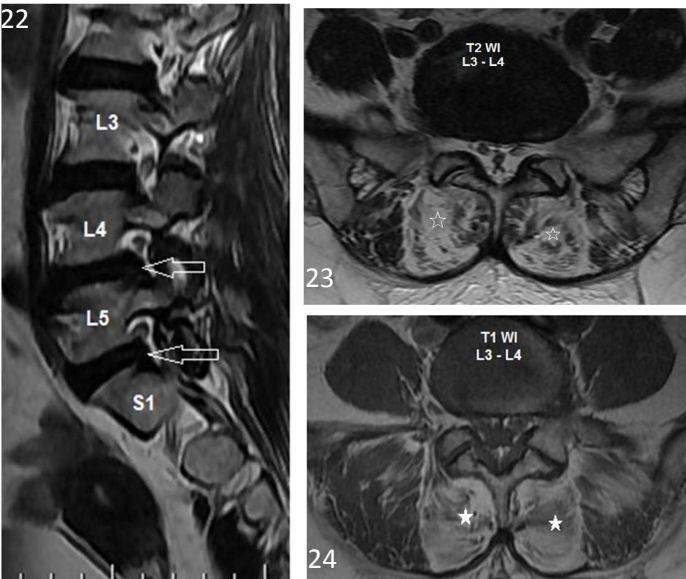
Facetal arthropathy: Facetal arthropathy was noted as reduction in synovial facet joint space with loss of high signal intensity on T2WI [Table/Fig-18].

Narrowing of the spinal canal: In the mid sagittal T2 Weighted images spinal canal diameter was measured. Spinal canal diameter less than 12 mm, indicates narrowing of the canal [Table/Fig-19].

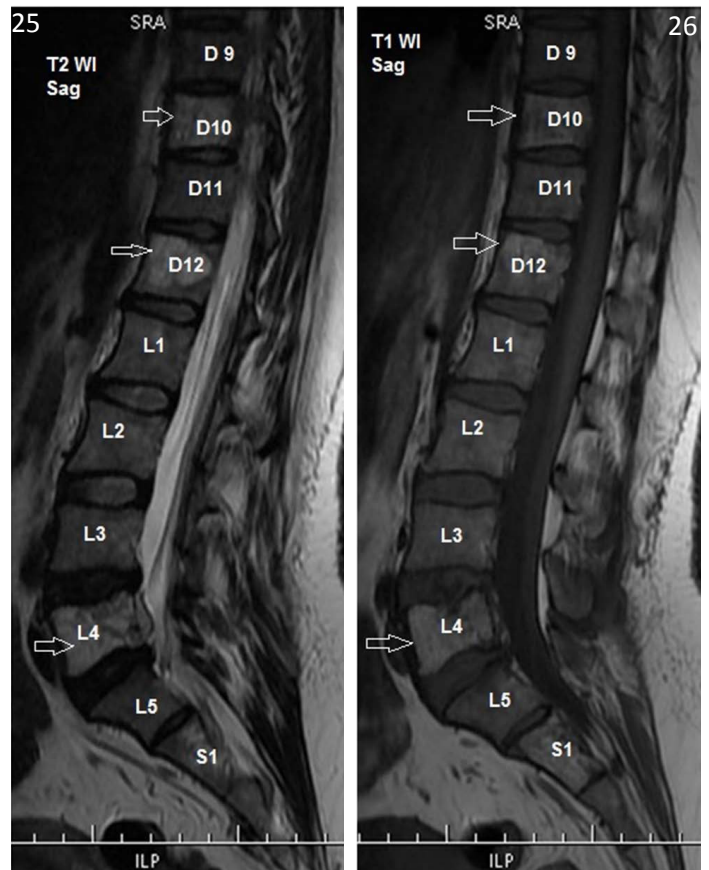
Narrowing of lateral recess: A lateral recess is the space which is bounded ventrally by the posterior surface of the vertebral body, dorsally by the superior articular facet, and laterally by the pedicle.



[Table/Fig-18]: Axial T2 Weighted MR Image: Narrowing of bilateral facet joint space with loss of high signal of synovial fluid suggestive of facet arthropathy (solid white arrow). Ligamentum flavum appears thickened **[Table/Fig-19]:** T2 Weighted Sagittal MR Image: L4-L5 disc herniation with narrowing of spinal canal (white open circle). Lumbar Disc Desiccations is seen to variable extent **[Table/Fig-20]:** Axial T2 Weighted MR Image- Normal Lateral recess: Space is bordered laterally by the pedicle, dorsally by the superior articular facet, and ventrally by the posterior surface of the vertebral body. Medially, it is open toward the spinal canal (solid white line). Normally it is greater than 4 mm **[Table/Fig-21]:** Axial T2 Weighted MR Image: L2-L3 Disc bulge with narrowing of spinal canal & bilateral lateral recess (open white arrow) with compression of exiting nerve roots. Ligamentum flavum and bilateral facet joint appear normal



[Table/Fig-22]: Sagittal T2 Weighted MR Image: L4-L5 and L5-S1 herniated disc leads to narrowing neural foramen (open white arrow) with abutting exiting nerve roots **[Table/Fig-23]:** Axial T2 Weighted MR Image: Abnormal high signals in bilateral paraspinal muscles (open white star) on both T1WI & T2WI represents fatty infiltration of bilateral paraspinal muscles. Note left foraminal L3-L4 disc annular tear **[Table/Fig-24]:** Axial T1 Weighted MR Image: Abnormal high signals in bilateral paraspinal muscles (solid white star) on both T1WI & T2WI represents fatty infiltration of bilateral paraspinal muscles



[Table/Fig-25]: Sagittal T2 Weighted MR Image: Sacralization of L5 vertebral body. Abnormal high signal intensity in D10, D12 & L4 vertebral body in both T1WI and T2W1 without fat suppression suggestive of vertebral body hemangioma (open white arrow). Note at L4 level there is epidural extension of hemangioma with spinal canal narrowing & central wedging of L4 vertebral body. L4-L5 disc shows posterior disc herniation **[Table/Fig-26]:** Sagittal T1 Weighted MR Image: Sacralization of L5 vertebral body. Abnormal high signal intensity in D10, D12 & L4 vertebral body in both T1WI (open white arrow) and T2W1 without fat suppression suggestive of vertebral body hemangioma. Central wedging of L4 vertebral body is seen

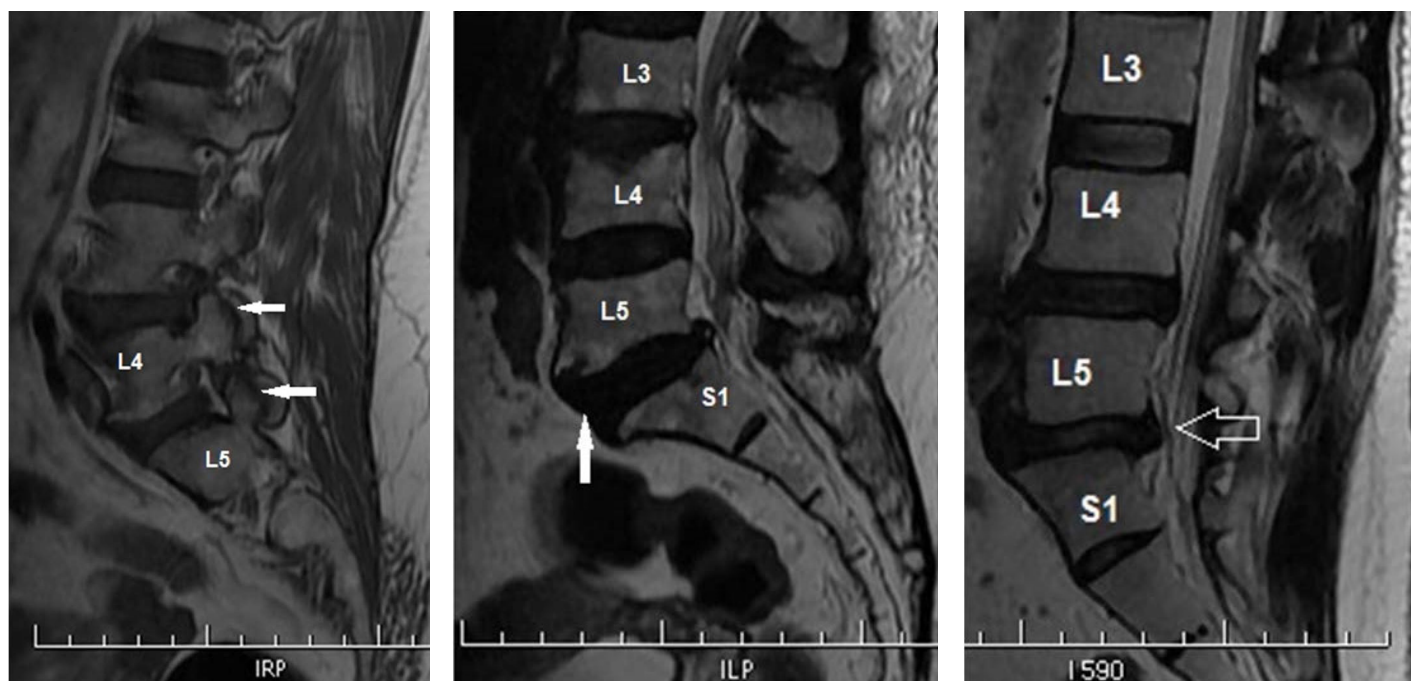
Medially, it is open toward the spinal canal. It is measured at the level of the pedicle in axial section as the distance between the post aspect of the vertebral body and superior articular facet. If it is less than 4 mm it is considered abnormal [Table/Fig-20,21]. Compression of neural foramen was observed in T2W Sagittal image [Table/Fig-22].

Abnormal hyper signal intensity in the spinal cord on T2 weighted images were evaluated for the spinal cord edema. Pre and Para vertebral soft tissue involvement [Table/Fig-23,24], vertebral hemangioma [Table/Fig-25,26], sacroiliitis, lumbarization and sacralization of the vertebra were observed.

Spondylolysis is seen as low signal on T1WI in pars interarticularis [Table/Fig-27]. Spondylolisthesis was measured and diagnosed by the methods of Meyer ding. Antero-posterior diameter of the superior surface of the lower vertebral body is divided into four equal parts and is Graded as I,II,III and IV if there is a corresponding slip of <25%, 25-50%, 50-75% and >75%. But we could not divide our data according to the grades of the spondylolisthesis, we simply noted that whether spondylolisthesis were present or not & anterolisthesis or posterolisthesis were present or not [Table/Fig-28,29].

RESULTS

Total 109 patients were studied in the evaluation of MRI appearance of Degenerative Spinal Disease. Sixteen patients were excluded from the study as they had history of prior surgery, spinal infections, and active malignancy. From total 109 patients, 60 patients (i.e.55.04% of total patients) were male and 49 patients (i.e.44.95% of total patients) were female. Lumbar lordosis was preserved in 51 (i.e. 46.79% of total patients) patients and loss of the lumbar lordosis was seen in 58 (i.e. 53.21% of total patients) patients. Conus end at



[Table/Fig-27]: Sagittal T1 Weighted MR Image: Linear low signal intensity in pars interarticularis of L4 and L5 vertebra (solid white arrow) represent spondylolysis without spondylolisthesis **[Table/Fig-28]:** Sagittal T2 Weighted MR Image: Posterior annular tear in L3-L4 and L5-S1 disc with herniation & spinal canal narrowing. Grade – I anterolisthesis of L5 over S1 vertebral body is seen (solid white arrow) **[Table/Fig-29]:** Sagittal T2 Weighted MR Image: L5- S1 posterior disc herniation with spinal canal narrowing. Grade – I retrolisthesis of L5 over S1 vertebral body is seen (open white arrow)

Inter-vertebral Disc Level	Disc Involvement (n = 241)	Decreased Disc Height (n = 31)	Central/ Medial Annular Tear (n = 55)	Paramedian Annular Tear (n = 43)	Right Paramedian Annular Tear (n = 21)	Left Paramedian Annular Tear (n = 22)	Foraminal Annular Tear (n = 41)	Right Foraminal Annular Tear (n = 16)	Left Foraminal Annular Tear (n = 25)
D10 – D11	1(0.41%)	-	-	-	-	-	-	-	-
D11 – D12	1(0.41%)	-	-	-	-	-	-	-	-
D12- L1	9(3.73%)	-	4(7.27%)	3(6.98%)	2(9.52%)	1(4.55%)	-	-	-
L1 – L2	14(5.81%)	3(9.68%)	4(7.27%)	-	-	-	2(4.88%)	1(6.25%)	1(4%)
L2 – L3	22(9.13%)	4(12.90%)	4(7.27%)	1(2.33%)	1(4.76%)	-	2(4.88%)	1(6.25%)	1(4%)
L3 – L4	42(17.43%)	5(16.13%)	8(14.55%)	6(13.95%)	2(9.52%)	4(18.18%)	12(29.27%)	6(37.50%)	6(24%)
L4 – L5	93(38.59%) #	9(29.03%)	21(38.18%) #	21(48.84%) #	10(47.62%) #	11(50.00%) #	24(58.54%) #	7(43.75%) #	17(68%) #
L5 – S1	56(23.24%)	10(32.26%) #	14(25.45%)	12(27.91%)	6(28.57%)	6(27.27%)	1(2.44%)	1(6.25%)	-
S1 – S2	3(1.24%)	-	-	-	-	-	-	-	-

[Table/Fig-30]: Different variables like Disc Involvement, Decreased Disc Height, Central/Medial Annular Tear, Paramedian Annular Tear, Right Paramedian Annular Tear, Left Paramedian Annular Tear, Foraminal Annular Tear, Right Foraminal Annular Tear, Left Foraminal Annular Tear and their correlation with the Intervertebral disc level. # indicates most common intervertebral disc level of involvement

Inter-vertebral Disc Level	Herniation (n = 150)	Disc Extrusion (n = 42)	Disc Bulge (n = 66)	Osteophytes (n = 17)	Spinal Canal Narrowing (n = 56)	Narrowing of lateral recess (n = 127)	Compression of neural foramen (n = 127)	Facetal Arthropathy (n = 209)	Ligamentum Flavum Thickening (n = 209)
D10 – D11	-	-	-	-	-	-	-	1(0.47%)	1(0.47%)
D11 – D12	-	-	-	-	-	-	-	1(0.47%)	1(0.47%)
D12- L1	1(0.67%)	1(2.38%)	6(9.09%)	1(5.88%)	-	1(0.79%)	1(0.79%)	1(0.47%)	1(0.47%)
L1 – L2	3(2%)	1(2.38%)	10(15.15%)	1(5.88%)	1(1.78%)	2(1.57%)	2(1.57%)	9(4.30%)	9(4.30%)
L2 – L3	11(7.33%)	4(9.52%)	8(12.12%)	3(17.65%)	6(10.71%)	8(6.30%)	8(6.30%)	21(10.04%)	21(10.04%)
L3 – L4	21(14%)	6(14.29%)	17(25.76%) #	5(29.41%) #	13(23.21%)	21(16.54%)	21(16.54%)	40(19.13%)	40(19.13%)
L4 – L5	68(45.33%) #	18(42.86%) #	17(25.76%) #	2(11.76%)	25(44.64%) #	60(47.24%) #	60(47.24%) #	86(41.14%) #	86(41.14%) #
L5 – S1	45(30%)	12(28.57%)	7(10.61%)	5(29.41%) #	10(17.85%)	34(26.77%)	34(26.77%)	48(22.96%)	48(22.96%)
S1 – S2	1(0.67%)	-	1(1.52%)	-	1(1.78%)	1(0.79%)	1(0.79%)	2(0.96%)	2(0.96%)

[Table/Fig-31]: Different variables like Herniation, Disc Extrusion, Disc Bulge, Osteophytes, Spinal Canal Narrowing, Narrowing of lateral recess, Compression of neural foramen, Facetal Arthropathy, Ligamentum Flavum Thickening and their correlation with the Intervertebral disc level. # indicates most common intervertebral disc level of involvement

L1 vertebral level which was most common and seen in 63 patients (i.e. 57.80% of total patients).

As seen in [Table/Fig-30,31] there were a total 241 disc involvements, so per patients average 2.21 disc involvements were found. L4 – L5 disc involvement was common & seen in 93 discs (i.e. 38.59% of the disc involvement). Decrease disc heights were seen in 31 disc

levels, from which decreased disc height common at L5-S1 level 10(i.e. 32.26% of decreased disc height). Two patients (1.83%) showed changes of discitis. Fifty five patients (i.e. 50.45% of total patients) showed medial annular disc tear. In medial annular disc tear L4 –L5 disc were common seen (i.e. 38.18% of medial annular tear). Forty three patients (i.e. 39% of total patients) showed

paramedian annular tear. In paramedian annular disc tear L4 –L5 disc were commonly seen 21 (i.e. 48.84% of paramedian annular tear). Left paramedian tear were seen in 22 patients and right paramedian tear were seen in 21 patients. So, left paramedian tear was common as compared to the right side. 41 patients (i.e. 37% of total patients) showed foraminal annular tear. In foraminal annular disc tear L4 –L5 disc were common 24(i.e. 58.54% of foraminal annular tear). Left foraminal tear were seen in 25 patients and right foraminal tear were seen in 16 patients. So, left foraminal tear was common as compare to the right side. Herniation in 150 discs (i.e. 62.24% of disc involvement), extrusion in 42 discs (i.e. 17.43% of disc involvement) and disc buldge in 66 disc (i.e. 27.39% of disc involvement). Herniation was common at L4 –L5 disc level 68(i.e. 45.33% of herniation). Extrusion was common at L4 – L5 disc level 18(i.e. 42.86% of extrusion). Disc buldge was common at L3 – L4 17(i.e. 25.76% disc buldge) & L4 – L5 disc level 17(i.e. 25.76% disc buldge). L3 – L4 & L5 – S1 level shows maximum osteophytes 5(i.e. 29.41% osteophytes). Spinal canal narrowing was seen in 56 discs (i.e. 23.24% of disc involvement). Spinal canal narrowing was common in L4 – L5 disc 25(i.e. 44.64% of spinal canal narrowing). Narrowing of lateral recess and compression of neural foramen were seen in 127 discs (i.e. 52.70% of disc involvement) and both were common at L4 –L5 disc 60(i.e. 47.24% of involvement). Facetal arthropathy and ligamentum flavum thickening was seen in 209 disc levels (i.e. 86.72% of the disc involvement) & both were common at the L4 – L5 disc level. Six patients (i.e. 5.5% of total patients) showed wedging in vertebral body and were equally common at L1, L4 & L5 vertebral body (i.e. 33% each). Fifteen patients (i.e. 13.76% of total patients) showed listhesis in the spine in the form of anterolisthesis or retrolisthesis. Anterolisthesis (i.e. 10.09% of spondylolisthesis) is common as compare to retrolisthesis (i.e. 3.67% of spondylolisthesis). L5 vertebral body listhesis over S1 vertebral body was common in both anterolisthesis & retrolisthesis. As incidental findings vertebral hemangioma in 12 patients (i.e. 11.01% of total patients), marrow edema in 2 patients (i.e. 1.83% of total patients), partial fusion of vertebral body in 1 patient (i.e. 0.92% of total patients), paraspinal muscles fatty infiltration and edema in 3 patients (i.e. 2.75% of total patients) and spinal cord syrinx in 1 patient (i.e. 0.92% of total patients) were found.

DISCUSSION

Lumbar disc degeneration is the most common cause of low back pain around the world and majority due to the disc herniation. Due to development of MRI, noninvasive excellent imaging of spine is possible. Men are more commonly affected to the disc degeneration than women. It is most likely due to the increased mechanical stress and injury [10]. The findings of our study were consistent with other studies [11].

Most common cause of disc degeneration was observed in 4th and 5th decades of life in our study, which was comparable with other studies [11]. Disc desiccation is a common degenerative change of intervertebral discs. It results from the replacement of the glycosaminoglycans within the nucleus pulposus with fibro cartilage which leads to reduced disc height due to reduction in nucleus pulposus volume [12]. Disc degeneration with diffuse disc changes are more commonly found at L4 - L5 and L5 – S1 level

[11] and L1 – L2 is least common. This Cranio-caudal direction pattern is also followed by disc herniation. It also can be deduced that lower the lumbar level the higher is the prevalence of disc herniation. Multiplicity in the disc level involvement is common as compare to the single disc involvement; which is also concordance with past studies [13]. The lower back pain and sciatica were due to nerve root compression, which was significantly associated with disc degeneration [14]. Spondylolisthesis was more commonly found in the patients of lumbar stenosis as compare to disc herniation, reflecting the fact that during stenosis, laxity of capsule and ligament may result in the development of spondylolisthesis. Spondylolisthesis was most commonly present at L5 – S1 disc level. This findings is inconcordance with a previous study where spondylolisthesis was common at L4 – L5 disc level [3].

CONCLUSION

Lumbar disc degeneration is the most common cause of low back pain. Men are more frequently affected to the disc degeneration than women. Multiple levels of the disc involvement are seen per person. Annular disc tear, disc herniation, disc extrusion, narrowing of spinal canal, narrowing of lateral recess, compression of neural foramen, facet arthropathy and ligamentum flavum thickening is common at the L4 –L5 disc level. L1- L2 disc involvement and spondylolisthesis are less common. MRI is the standard imaging modality for detecting disc pathology due to its advantage of lack of radiation, multiplanar imaging capability, excellent spinal soft-tissue contrast and precise localization of intervertebral discs changes.

REFERENCES

- [1] Neuropathy-sciatic nerve; sciatic nerve dysfunction; low back pain-sciatica [Internet]. Bethesda (MD): A.D.A.M. Inc.; c2013 [cited 2012 Aug 12]. Available from: <http://www.ncbi.nlm.nih.gov/pubmedhealth/PMH0001706/>.
- [2] Bakhs A. Long-term outcome of lumbar disc surgery: an experience from Pakistan. *J Neurosurg Spine*. 2010;12:666-70.
- [3] Modic MT, Ross JS. Lumbar degenerative disc disease. *Radiology*. 2007;245: 43-61.
- [4] Battie MC, Videman T, Gibbons LE, Fisher LD, Manninen H, Gill K. 1995 Volvo Award in clinical sciences: determinants of lumbar disc degeneration—a study relating lifetime exposures and magnetic resonance imaging findings in identical twins. *Spine*. 1995;20: 2601–12.
- [5] Shafaq Saleem, Hafiz Muhammad Aslam, Muhammad Asim Khan Rehmani, Aisha Raees, Arsalan Ahmad Alvi, Junaid Ashraf. Lumbar Disc Degenerative Disease: Disc Degeneration Symptoms and Magnetic Resonance Image Findings. *Asian Spine J*. 2013;7(4):322–34.
- [6] Haughton V. Imaging intervertebral disc degeneration. *J Bone Joint Surg Am*. 2006;88 (Suppl 2):15-20.
- [7] Maravilla KR, Lesh P, Weinreb JC, Selby DK, Mooney V. Magnetic resonance imaging of the lumbar spine with CT correlation. *AJNR Am J Neuroradiol*. 1985;6(2):237-45.
- [8] Modic MT, Pavlicek W, Weinstein MA, et al. Magnetic resonance imaging of intervertebral disk disease: clinical and pulse sequence considerations. *Radiology*. 1984;152:103–11.
- [9] Park JB, Chang H, Lee JK. Quantitative analysis of transforming growth factor-beta 1 in ligamentum flavum of lumbar spinal stenosis and disc herniation. *Spine (Phila Pa 1976)*. 2001;26:E492–95.
- [10] Wang YX, Griffith JF. Effect of menopause on lumbar disc degeneration: potential etiology. *Radiology*. 2010;257:318-20.
- [11] Cheung KM, Karppinen J, Chan D, Ho DW, Song YQ, Sham P, et al. Prevalence and pattern of lumbar magnetic resonance imaging changes in a population study of one thousand forty-three individuals. *Spine (Phila Pa 1976)*. 2009;34(9):934-40.
- [12] Lipson SJ, Muir H. Experimental intervertebral disc degeneration: morphologic and proteoglycan changes over time. *Arthritis Rheum*. 1981;24:12–21.
- [13] Takatalo J, Karppinen J, Niinimäki J, Taimela S, Näyhä S, Järvelin MR, et al. Prevalence of degenerative imaging findings in lumbar magnetic resonance imaging among young adults. *Spine (Phila Pa 1976)*. 2009;34(16):1716-21.
- [14] Shambrook J, McNee P, Harris EC, et al. Clinical presentation of low back pain and association with risk factors according to findings on magnetic resonance imaging. *Pain*. 2011;152:1659–65.

PARTICULARS OF CONTRIBUTORS:

1. Third Year Resident Doctor, Department of Radiology, S.S.G. Hospital, Medical College, Vadodara, India.
2. Assistant Professor, Department of Orthopedics, Virginia Commonwealth University (VCU), Richmond, Virginia, USA.
3. Associate Professor, Department of Radiology, S.S.G. Hospital, Medical College, Vadodara, India.
4. Professor, Department of Radiology, S.S.G. Hospital, Medical College, Vadodara, India.

NAME, ADDRESS, E-MAIL ID OF THE CORRESPONDING AUTHOR:

Dr. Pokhraj Prakashchandra Suthar,
5-Durga Nagar Society, Karodiya, Baroda, Gujarat-391310, India.
E-mail: pokhraj_suthar@yahoo.co.in

FINANCIAL OR OTHER COMPETING INTERESTS: None.

Date of Submission: **Nov 05, 2014**

Date of Peer Review: **Jan 20, 2015**

Date of Acceptance: **Feb 12, 2015**

Date of Publishing: **Apr 01, 2015**