



Virginia Commonwealth University
VCU Scholars Compass

Theses and Dissertations

Graduate School

2006

Treatment Effects of Incisor Positioning on Anterior Tooth Display

Scott J. Eberle

Virginia Commonwealth University

Follow this and additional works at: <http://scholarscompass.vcu.edu/etd>

 Part of the [Orthodontics and Orthodontology Commons](#)

© The Author

Downloaded from

<http://scholarscompass.vcu.edu/etd/895>

This Thesis is brought to you for free and open access by the Graduate School at VCU Scholars Compass. It has been accepted for inclusion in Theses and Dissertations by an authorized administrator of VCU Scholars Compass. For more information, please contact libcompass@vcu.edu.

© Scott J. Eberle, 2006

All Rights Reserved

TREATMENT EFFECTS OF INCISOR POSITIONING ON ANTERIOR TOOTH
DISPLAY

A thesis submitted in partial fulfillment of the requirements for the degree of Master of
Science at Virginia Commonwealth University.

by

SCOTT J. EBERLE
B.S., University of Louisville, 1995
M.Eng., University of Louisville, 1996
D.M.D., University of Louisville, 2004

Director: Steven J. Lindauer D.M.D., M.D.Sc.
Chair of the Department of Orthodontics

Virginia Commonwealth University
Richmond, Virginia
June 2006

Acknowledgement

Words are not adequate to describe the love and gratitude I have for my wife Jana. For eleven years of encouragement and believing in us while standing by my side - thank you. Your character and faithfulness during a difficult time in our lives have been a testimony to so many people. You continue to win my heart and inspire me to live courageously.

To my Lord and Savior, thank you Jesus for being truth and light through challenging times; for bearing our burdens and sharing in our joys. I can do all things through him who gives me strength (Philippians 4:13).

Many thanks to Drs. Steven J. Lindauer, Bhavna Shroff, and Eser Tüfekçi for cultivating an educational environment where new ideas are encouraged and proven principles are foundational. Your passion and devotion to the profession inspire me to be the best that I can be.

Thanks to all the residents who made these two years fun and educational. A special thanks to the assistants and staff, especially to Andrea Menger, who continue to make the clinical experience better than any other orthodontic program in the country. Your hard work and dedication are appreciated.

To my family and friends in Louisville and Southern Indiana, we're finally coming home. Thank you for your prayers and encouragement.

Table of Contents

	Page
Acknowledgements	ii
List of Tables.....	iv
List of Figures	v
Abstract	vi
Chapter	
1 Introduction	1
2 Materials and Methods	6
Overview.....	6
Cephalometric landmarks	7
Measurements	9
Statistics.....	10
3 Results	11
4 Discussion	16
Adults.....	17
Adolescents.....	17
Relationship between Initial ATD and ATD Change	18
5 Conclusion.....	20
Literature Cited.....	22
Vita	25

List of Tables

	Page
Table I: Age description of subjects.....	7
Table II: Measured characteristics of subjects.	12

List of Figures

	Page
Figure 1: Cephalometric landmarks and measurements.....	8
Figure 2: Cephalometric measurements	10
Figure 3: Relationship between initial ATD and ATD change	13
Figure 4: Relationship between anterior-posterior change and ATD change	14
Figure 5: Relationship between vertical change and ATD change	15
Figure 6: Relationship between angular change and ATD change	15

Abstract

TREATMENT EFFECTS OF INCISOR POSITIONING ON ANTERIOR TOOTH DISPLAY

By Scott J. Eberle, DMD

A Thesis submitted in partial fulfillment of the requirements for the degree of Master of
Science at Virginia Commonwealth University.

Virginia Commonwealth University, 2006

Major Director: Steven J. Lindauer, DMD, MDSc
Chair of the Department of Orthodontics

The purpose of this study was to determine the effect of changes in maxillary incisor position on anterior tooth display (ATD) in adult (n = 21) and adolescent (n = 38) orthodontic patients. The effects of anterior-posterior, vertical, and angular changes of the maxillary central incisor position during orthodontic treatment were evaluated relative to changes in the amount of ATD measured from pretreatment (T1) and posttreatment (T2) lateral cephalometric radiographs of existing patient records.

Results showed a significant relationship between starting ATD and ATD change during treatment for both adults ($P = .006$) and adolescents ($P < .0001$). In adults, there were significant correlations between vertical ($P = .047$) and angular ($P = .017$) changes and ATD, but no significant relationship between anterior-posterior movement and ATD. No correlation was found between maxillary incisor anterior-posterior, vertical or angular changes and ATD in adolescents.

CHAPTER 1 Introduction

An important characteristic considered during orthodontic treatment planning is anterior tooth display (ATD), defined as the amount of maxillary central incisor displayed inferior to the upper lip with the lips at rest. Clinicians use this diagnostic piece of information to help plan movement of the maxillary incisors. Increased ATD or a ‘gummy’ smile could be an indication for incisor intrusion. Lindauer et al¹ demonstrated that significant reductions in ATD were achieved with intrusion arch mechanics. Alternatively, patients who have a minimal amount of ATD could potentially benefit from extrusion of the anterior teeth to increase ATD. In more extreme cases, ATD could be a determining factor for recommending orthognathic surgery to increase or decrease incisor display.

Lip posture is regarded as an important factor in getting an accurate measurement of ATD. Burstone² stated that the lower lip contributed more movement to the closure of the interlabial gap than the upper lip. Relaxed lip position represented a state in which there was no contraction in lip musculature. This position produced a space between the upper and lower lips known as the interlabial gap. The average gap, according to Burstone’s sample of adolescents with “acceptable” faces, was found to be 1.8 mm (± 1.2 mm) in centric occlusion. Anterior tooth display was evaluated from the frontal view by asking the patient to relax and slightly open their mandible, measuring

the distance from the inferior border of the upper lip to the incisal edge of the maxillary central incisor. In Burstone's sample, the maxillary incisor demonstrated an average ATD of 2.3 mm (± 1.9 mm).

Peck et al³ measured maxillary incisor exposure at rest position and at full smile in a sample of 15 year-old males and females. At rest, ATD was found to be 4.7 mm (± 2.0 mm) for males and 5.3 mm for females (± 1.8 mm). Vig and Brundo⁴ reported a gradual decrease in maxillary incisor exposure for increasing age groups from under 30 years of age to over 60. The amount of mandibular incisor display after age 60 was approximately equal to the amount of maxillary incisor display before age 30.

There is general agreement that orthodontic treatment may influence the soft tissue profile, but there is still disagreement on the amount of response of the soft tissues to changes in the position of the teeth and alveolar process.⁵ Some investigators have reported a correlation between incisor movement and soft tissue response,⁶⁻⁸ while others have found little to no proportional correlation.⁹ In addition, there have been reports that various components of the facial soft tissues respond differently to underlying hard tissue movements. Moesling¹⁰ found that midfacial soft tissue form and position appear to be less dependent on underlying hard tissues than the lower facial soft tissues.

Sarver¹¹ stated that contemporary orthodontic treatment considers the need for dental normalcy and coordinates functional treatment goals with esthetic goals.

Ackerman and Proffit¹² claimed the soft tissue contours of the face are determined by three interacting factors. These were: 1) the skeletal foundation, which for the mid and

lower face is provided by the jaws, 2) the dental support system provided by the teeth, and 3) the soft tissue mask, influenced by both the underlying hard tissues and the components of the soft tissue itself. They stated that, ultimately, lip posture is affected by a combination of incisor position, skeletal pattern, size of the nose and chin, lip thickness and lip tonicity.

Soft tissue architecture has been shown to have an influence on lip response to tooth movement. For example, there were stronger correlations found between osseous changes and soft-tissue changes in patients with thin lips as opposed to those with thick lips.⁶ Also, subjects with high lip strain on closure of an interlabial gap (lip seal) demonstrated a significantly stronger correlation between maxillary incisor retraction and soft-tissue retraction than patients with minimal lip strain.

Craniofacial growth during orthodontic treatment has also been shown to influence soft and hard tissue relationships. Maxillary implant superimpositions have been used to reduce the confounding factors of the variability of facial growth and development when attempting to assess changes related to treatment. In a study utilizing implants as reference markers to examine the upper lip response to maxillary incisor retraction in adolescents, regional superimpositions showed that vertical changes in the lips were more related to growth, not tooth movement, whereas anterior-posterior changes were associated with incisor retraction.¹³

In a recent study of 16 Class II, division 1 patients treated with the removal of maxillary first premolars and full fixed appliance therapy, Ramos et al¹³ found no significant difference between groups of adolescents with or without anterior lip seal in

the change of ATD when treated with retraction of the maxillary anterior teeth. In the study, the group of patients with anterior lip seal had a mean retraction of the maxillary incisor tip of 3.73 mm back and 1.04 mm up and demonstrated an ATD increase of 0.65 mm. The group of patients without anterior lip seal had a mean retraction of 5.55 mm back and 1.56 mm up and demonstrated a mean ATD increase of 0.06 mm. This indicated that the presence or absence of lip seal did not significantly influence the extent to which incisor movement affected ATD.

In a study of 20 Class I and 20 Class II adult female patients whose maxillary incisor teeth were moved lingually during treatment, Perkins and Staley¹⁴ reported a statistically significant increase (0.7 mm) in ATD for patients who began treatment with less than 6 mm of anterior tooth display, but no significant change (-0.5 mm decrease) for patients who started with greater than 6 mm of ATD. They attributed this to the fact that in the group in which the upper lip more fully covered the maxillary incisor crown before treatment (the < 6 mm subgroup), the incisors were perhaps tipped more lingually and intruded less than the group in which the upper lip was more highly positioned on the maxillary incisor crown before treatment.

Previous studies have demonstrated that tooth movement during orthodontic treatment can affect both lip position and ATD. However, the specific relationship between incisor movements and changes in ATD has not been elucidated. The purpose of this study was to determine the relationship between vertical, anterior-posterior and angular incisor movements and ATD change in adult and adolescent orthodontic patients.

The null hypothesis was:

- There is no relationship between maxillary incisor movement and anterior tooth display change in adults and adolescents.

CHAPTER 2 Material and Methods

Overview

Approval to conduct this study was obtained from the Institutional Review Board at Virginia Commonwealth University. This retrospective study included data from records of patients treated at the Virginia Commonwealth University School of Dentistry Department of Orthodontics. Subjects were chosen who had pretreatment (T1) and posttreatment (T2) lateral cephalograms with 1) good definition of both hard and soft tissues, 2) soft tissues subjectively judged to be in an unstrained habitual position, 3) molars in centric occlusion, and 4) no orthodontic appliances in place. Patient treatment modalities were not criteria for patient selection. Patients with and without anterior lip seal were included in the study since lip seal was previously shown not to have an influence on ATD.¹³ Lateral cephalometric radiographs were used to measure anterior tooth display. Subjects were divided into adult (≥ 18 y.o.) and adolescent (< 18 y.o.) groups based on pretreatment age (T1) (Table I).

Table I. Pretreatment Age Description of Subjects

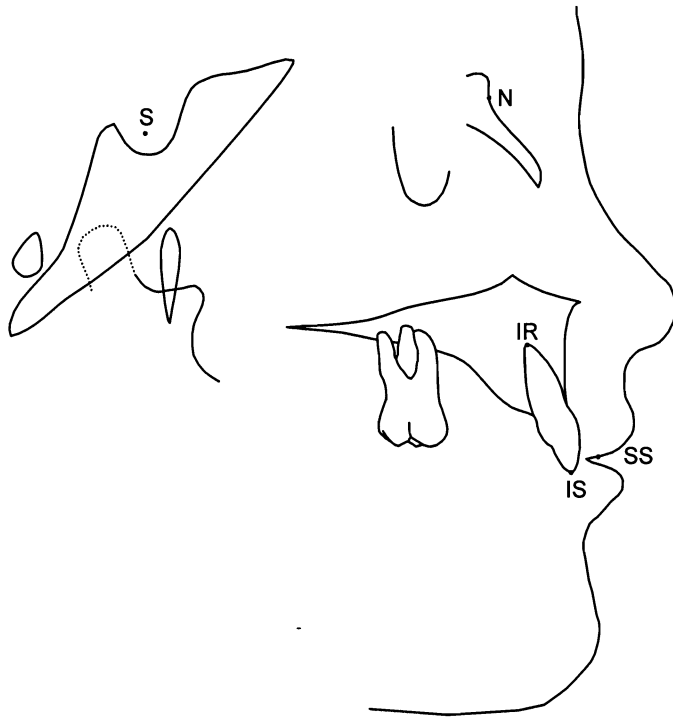Age	Adults (n = 21)	Adolescents (n = 38)
Mean	30.5	13.4
SD	9.4	1.8
Minimum	18.0	10.3
Maximum	54.2	17.9

Cephalometric Landmarks

Radiographs were digitized using Dolphin Imaging 9.0 (Chatsworth, CA), and the following landmarks were identified on each cephalogram (Fig. 1).

1. Sella (S): The midpoint of sella turcica.
2. Nasion (N): The most anterior point of the fronto-nasal suture in the midsagittal plane.
3. Stomion superius (SS): The lower most point of the upper lip.
4. Incision superius (IS): The most incisal point of the maxillary central incisor.
5. Maxillary incisor root apex (IR): The most apical point on the root of the maxillary central incisor.

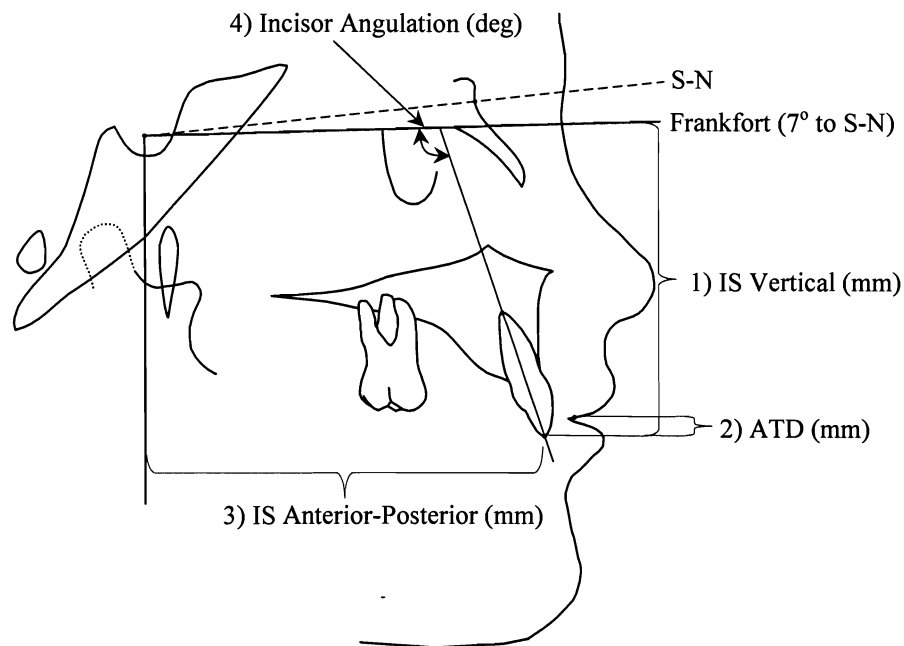
Figure 1: Cephalometric Landmarks



Measurements

All measurements were made using a customized digital analysis in Dolphin Imaging 9.0 (Chatsworth, CA). These measurements were 1) Incisor Vertical Position – the vertical distance between the maxillary incisal tip (IS) and Frankfort Horizontal (FH) (S-N - 7°), 2) Anterior Tooth Display (ATD) – the amount of maxillary central incisor inferior to Stomion Superius (SS), calculated by subtracting the perpendicular distance between SS and FH from IS Vertical, 3) Incisor Anterior-Posterior Position – the anterior-posterior distance between IS and a vertical reference line drawn through Sella perpendicular to FH, and 4) Incisor Angulation – the angle between the long axis of the maxillary central incisor (U1) and FH (Fig. 2).

Figure 2: Cephalometric measurements



Statistics

Correlation analysis was used to determine significant relationships between the independent variables (maxillary central incisor anterior-posterior, vertical, and angular change) and anterior tooth display (ATD). Paired t-tests were used to test for significant differences in tooth positions before (T1) and after (T2) treatment within groups, and t-tests were used to evaluate differences between adults and adolescents. The level of significance for all tests was set at $P \leq .05$.

CHAPTER 3 Results

Mean values for anterior-posterior (A-P), vertical, and angular tooth measures and ATD for adolescents and adults before and after treatment are shown and compared in Table II.

At T1, the relative position of the maxillary central incisor differed significantly between adults and adolescents in the anterior-posterior (74.2 mm vs. 70.2 mm; $P = .022$) and vertical (71.2 mm vs. 67.5 mm; $P = .008$) position. ATD also differed significantly at T1 in adults and adolescents (1.8 mm vs. 3.4 mm; $P = .021$).

At T2, adult and adolescent groups differed in vertical (72.0 mm vs. 68.7 mm; $P = .012$) and angular (111.4° vs. 115.2° ; $P = .042$) position, but anterior-posterior position (72.9 mm vs. 70.4 mm; $P = .119$) and ATD (2.1 mm vs. 2.9 mm; $P = .156$) did not differ significantly.

Change in ATD from T1-T2 differed significantly between adolescents and adults ($P = .020$). From T1 to T2, ATD increased non-significantly an average of 0.3 mm in the adult group ($P = .26$) and decreased an average of 0.5 mm in the adolescent group ($P = .001$). However, changes in anterior-posterior, vertical, and angular measures were not significantly different between the two groups ($P = .108$, $P = .393$, $P = .114$, respectively).

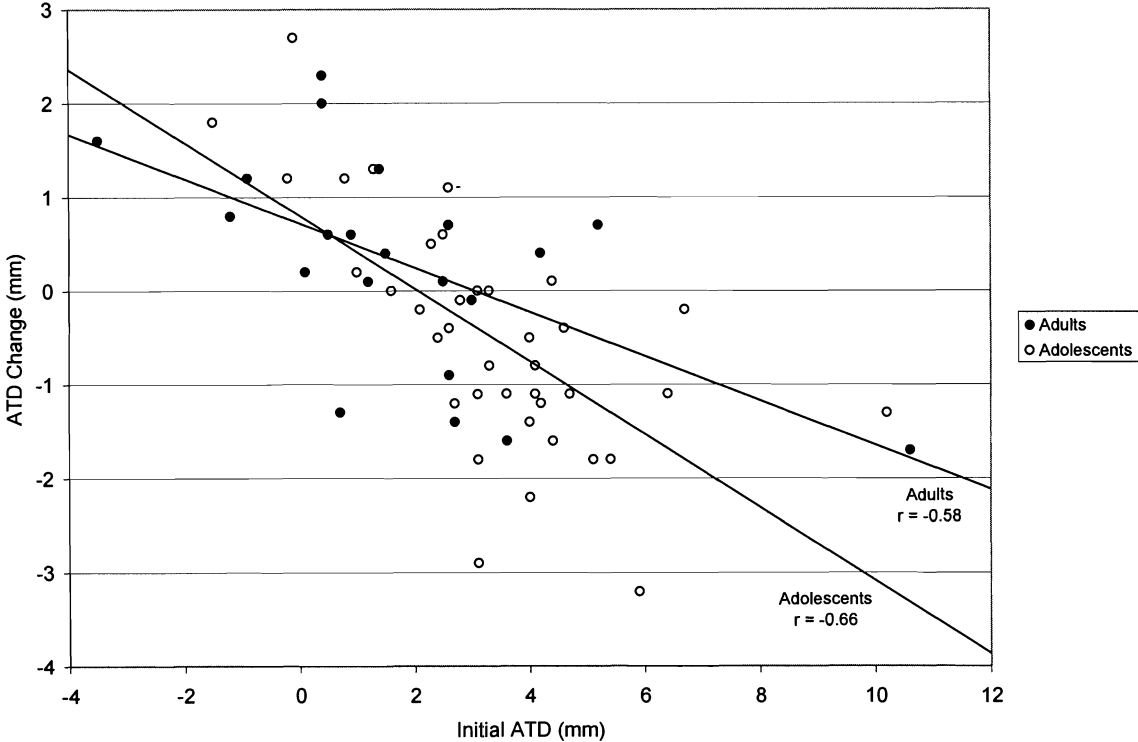
Table II: Measured Characteristics of Subjects

Incisor Measurement	Adults (n=21)		Adolescents (n=38)		Between Groups	
	Mean	SD	Mean	SD	t	p-value
Incisor A-P Position (mm)						
A-P (T1)	74.2	6.9	70.2	5.7	2.36	0.022
A-P (T2)	72.9	6.6	70.4	5.5	1.58	0.119
A-P Change	-1.2	3.1	0.2	3.2	1.64	0.108
Incisor Vertical Position (mm)						
Vertical (T1)	71.2	4.7	67.5	5.3	2.73	0.008
Vertical (T2)	72.0	4.8	68.7	4.7	2.59	0.012
Vertical Change	0.8 **	1.2	1.2 **	2.4	0.86	0.393
Incisor Angulation (°)						
Angulation (T1)	111.9	11.1	112.1	8.0	0.06	0.954
Angulation (T2)	111.4	7.2	115.2	6.4	2.08	0.042
Angular Change	-0.5	9.8	3.2 *	7.5	1.60	0.114
Anterior Tooth Display (mm)						
ATD (T1)	1.8	2.8	3.4	2.1	2.37	0.021
ATD (T2)	2.1	2.3	2.9	1.6	1.44	0.156
ATD Change	0.3	1.1	-0.5 **	1.3	2.39	0.020

- Significant Change (T1 – T2) * P < .05 ** P < .01

Figure 3 shows the relationship between pretreatment ATD (T1) and ATD change with treatment for adults and adolescents. Both groups demonstrated significant negative relationships ($P = .006$ and $P < .0001$ for adults and adolescents, respectively), indicating that patients who presented with relatively more ATD received orthodontic treatment that tended to reduce ATD.

Figure 3: Relationship between initial ATD and ATD change



There were no correlations between anterior-posterior (Fig. 4), vertical (Fig. 5), or angular (Fig. 6) changes in the maxillary incisor position and ATD in the adolescent group. In adults, there was also no significant relationship between anterior-posterior tooth movement and ATD (Fig. 4). However, there were significant correlations between vertical ($P = .047$) (Fig. 5) and angular ($P = .017$) (Fig. 6) incisor changes and ATD.

Figure 4: Relationship between anterior-posterior change and ATD change

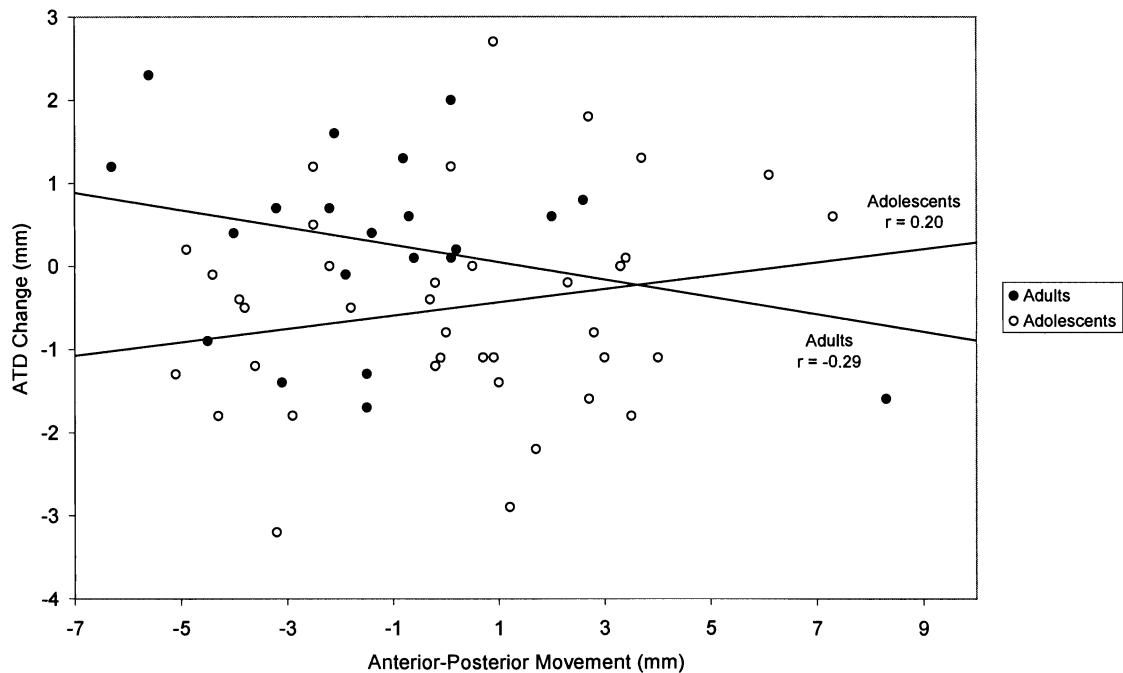
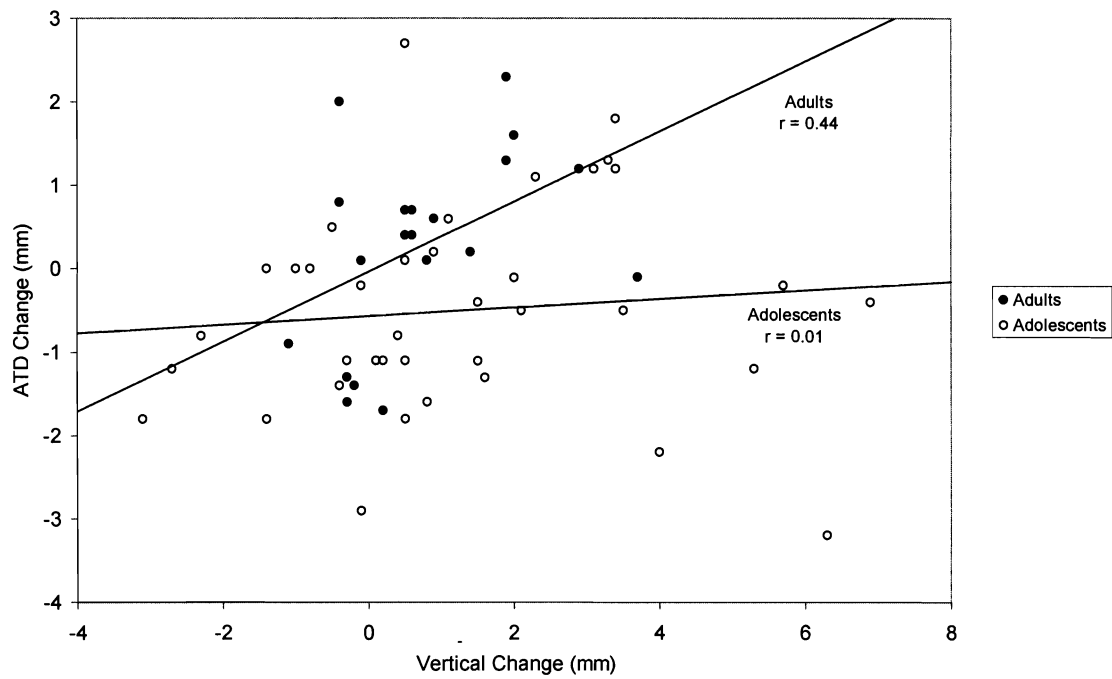
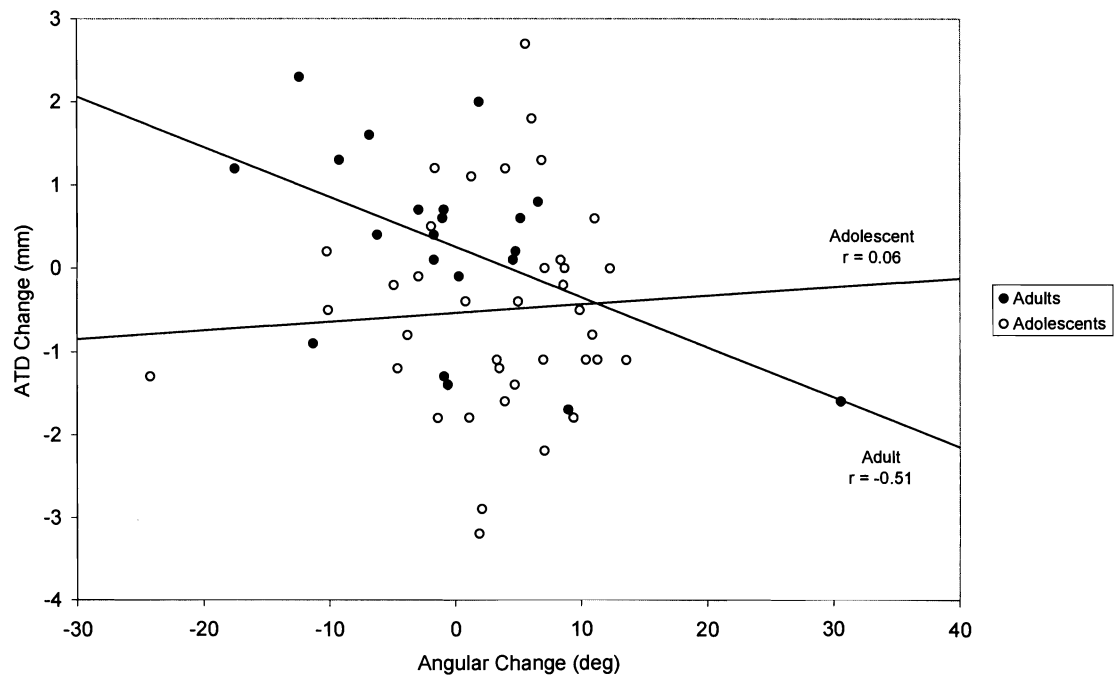


Figure 5: Relationship between vertical change and ATD change**Figure 6:** Relationship between angular change and change in ATD

CHAPTER 4 Discussion

Anterior tooth display is an important diagnostic characteristic quantified for the purpose of planning vertical goals of orthodontics and orthognathic surgery.¹⁵ Changes in ATD have been shown to significantly affect smile esthetics. According to Mackley,¹⁶ a reduction in the amount of maxillary incisor show was one of the most important factors associated with improvement of the smile. In contrast, Zachrisson¹⁵ recommended avoiding excessive decreases in ATD during treatment. Since treatment planning is case specific, there may be situations in which increasing or decreasing ATD would be desirable. For example, a patient with an ATD of 8 mm, a gummy smile and a reverse maxillary curve of Spee would benefit from a reduction in ATD with orthodontic treatment. However, an adolescent patient with minimal to no incisor display at rest would benefit from an increase in ATD. Since it has been documented that choice of treatment mechanics to position the maxillary incisor can affect ATD,¹ this study was designed to determine the effect of vertical, anterior-posterior, and angular changes in incisor position on ATD, and to compare the effects on ATD between adults and adolescents.

Adults

While there was no correlation between anterior-posterior incisor movements and ATD in adults, there was a positive relationship between vertical changes and ATD and a negative relationship between angular changes and ATD. In these non-growing patients, as the maxillary central incisor extruded, the amount of tooth visible at rest increased. Similarly, the significant correlation between angular change and ATD may actually be due to vertical movements induced by maxillary incisor uprighting or flaring, as the incisor tip moves along an arc of rotation. Uprighting results in relative extrusion of the incisal edge and a consequent increase in ATD, while flaring does the opposite. While incisor retraction is often accompanied by incisor uprighting and should therefore increase ATD, posterior movement also may allow the lip to come back and down, contributing to a decrease in ATD. Therefore, a consistent relationship was not found between anterior-posterior incisor movement and ATD.

Adolescents

Adolescents showed no significant correlations between incisor movement and ATD. Growth is likely a contributing factor to the lack of correlation between maxillary incisor anterior-posterior, vertical, and angular changes and ATD in the adolescent group. Since orthodontic treatment is often planned to begin around the adolescent growth spurt, associated changes in soft tissue morphology with growth are likely to influence ATD. Lengthening of the upper lip with no downward movement of

the maxillary incisor tip would result in decreased ATD, or potentially mask the effects of incisor movement.

Relationship between Initial ATD and ATD Change

Figure 3 shows the relationship between initial ATD and ATD change with orthodontic treatment. The relationship was found to be significantly correlated in adolescents ($r = -0.66$) and adults ($r = -0.58$). The slopes of ATD change to initial ATD for both groups were negative, indicating that patients who began orthodontic treatment with relatively greater ATD demonstrated more intrusion of the maxillary central incisor and a correspondingly larger reduction in ATD. It is logical that reduction of excessive ATD was an intended goal of treatment in patients with larger ATD measures at T1.

The significant relationship between starting ATD and ATD change during treatment is consistent with the findings of Perkins and Staley¹⁴ who studied 20 Class I and 20 Class II adult female patients whose maxillary incisor teeth were moved lingually during treatment. They reported a significant (0.7 mm) increase in ATD for patients who began treatment with less than 6 mm of anterior tooth display, but no significant change (a -0.5 mm decrease) for patients who started with greater than 6 mm of ATD.

The findings from the current study demonstrated that ATD can be influenced by incisor movement during orthodontic treatment, especially in adults. This

information can be useful for predicting changes expected from treatment in both adults and adolescents.

CHAPTER 5 Conclusion

The aim of this study was to determine the relationship between anterior-posterior, vertical, and angular movements of the maxillary central incisor and ATD changes during orthodontic treatment in adults and adolescents. Although there was no relationship found between changes in maxillary incisor position and ATD in adolescents, incisor movement in adults was shown to significantly influence ATD.

In adults, the following relationships were demonstrated:

- A positive correlation between vertical incisor movement and ATD was found. Incisor extrusion was associated with increased ATD. Incisor intrusion was associated with decreased ATD.
- A negative correlation between incisor angulation change and ATD was found. Incisor uprighting was associated with increased ATD. Incisor flaring was associated with decreased ATD.
- No significant relationship between anterior-posterior incisor movement and ATD change was found.

This information may be useful to practitioners for predicting changes in ATD expected during orthodontic treatment in adults and adolescents.

Literature Cited

Literature Cited

1. Lindauer SJ, Lewis SM, Shroff B. Overbite correction and smile esthetics. *Seminars in Orthod* 2005;11:62-6.
2. Burstone CJ. Lip posture and its significance in treatment planning. *Am J Orthod* 1967;53:262-84.
3. Peck S, Peck L, Kataja M. The gingival smile line. *Angle Orthod* 1992;62:91-100.
4. Vig RG, Brundo GC. The kinetics of anterior tooth display. *J Pros Dent* 1978;39:502-4.
5. Finnöy JP, Wisth PJ, Bøe OE. Changes in soft tissue profile during and after orthodontic treatment. *Eur J Orthod* 1987;9:68-78.
6. Oliver BM. The influence of lip thickness and strain on upper lip response to incisor retraction. *Am J Orthod* 1982;82:141-9.
7. Koch R, Gonzales A, Witt E. Profile and soft tissue changes during and after orthodontic treatment. *Eur J Orthod* 1979;1:193-9.
8. Riedel RA. An analysis of dentofacial relationships. *Am J Orthod* 1957;43:103-19.
9. Wisth PJ. Soft tissue response to upper incisor retraction in boys. *Br J Orthod* 1974;1:199-204.

10. Moseling KP, Woods MG. Lip curve changes in females with premolar extraction or nonextraction treatment. *Angle Orthod* 2004;74:51-62.
11. Sarver DM. The esthetic impact of orthodontics: Planning treatment to meet patients' needs. *J Am Dent Assoc* 1993;124:99-102.
12. Ackerman JL, Proffit WR. Soft tissue limitations in orthodontics: Treatment planning guidelines. *Angle Orthod* 1997;67:327-36.
13. Ramos AL, Sakima MT, Pinto AS, Bowman SJ. Upper Lip Changes Correlated to Maxillary Incisor Retraction—A Metallic Implant Study. *Angle Orthod* 2005;4:499-505.
14. Perkins RA, Staley RN. Change in lip vermilion height during orthodontic treatment. *Am J Orthod Dentofac Orthop* 1993;103:147-54.
15. Zachrisson BU. Esthetic factors involved in anterior tooth display and the smile: Vertical dimension. *J Clin Orthod* 1998;32:432-45.
16. Mackley RJ. An evaluation of smiles before and after orthodontic treatment. *Angle Orthod* 1993;63:183-90.

VITA

Dr. Scott Joseph Eberle was born in New Albany, Indiana on December 26th, 1972. He attended the University of Louisville J.B. Speed School of Engineering in Louisville, Kentucky. He earned Bachelor of Science and Master of Engineering degrees in chemical engineering in 1995 and 1996, respectively. He worked as a chemical engineer at Eastman Chemical Company in Kingsport, Tennessee before subsequently entering the University of Louisville Dental School. He was awarded his Doctor of Dental Medicine degree in 2004. The following year he entered the Virginia Commonwealth University graduate orthodontics program and is anticipating receiving a Master of Science degree in 2006. He will be opening a new orthodontic practice in Louisville, Kentucky upon graduation.