



Virginia Commonwealth University
VCU Scholars Compass

Surgery Publications

Dept. of Surgery

2014

Is the Consistency More Important Than the Ingredients for Treatment? Case Report for Eosinophilic Esophagitis

Dan W. Parrish

Virginia Commonwealth University, dparrish@mcvh-vcu.edu

Shashank Sharma

Virginia Commonwealth University, sharmas9@vcu.edu

Santhosh Kumar

Virginia Commonwealth University, skumar@vcu.edu

Follow this and additional works at: http://scholarscompass.vcu.edu/surgery_pubs

 Part of the [Pediatrics Commons](#), and the [Surgery Commons](#)

Copyright © Elsevier Ltd. NOTICE: this is the author's version of a work that was accepted for publication in *Annals of Allergy, Asthma & Immunology*. Changes resulting from the publishing process, such as peer review, editing, corrections, structural formatting, and other quality control mechanisms may not be reflected in this document. Changes may have been made to this work since it was submitted for publication. A definitive version was subsequently published in *Annals of Allergy, Asthma & Immunology*, Volume 112, Issue 4, April 2014, Pages 286–289, doi:10.1016/j.anai.2014.01.026.

Downloaded from

http://scholarscompass.vcu.edu/surgery_pubs/15

This Article is brought to you for free and open access by the Dept. of Surgery at VCU Scholars Compass. It has been accepted for inclusion in Surgery Publications by an authorized administrator of VCU Scholars Compass. For more information, please contact libcompass@vcu.edu.

Is the Consistency More Important Than the Ingredients for Treatment? Case Report for Eosinophilic Esophagitis

Dan W Parrish MD¹, Shashank Sharma BS², Santhosh Kumar MD³

Virginia Commonwealth University Department of Surgery¹, VCU School of Medicine²,
VCU Department of Pediatrics³

Corresponding Author

Dan W Parrish, MD

Virginia Commonwealth University Department of Surgery

P. O. Box 980645

Richmond, Virginia 23298-0645

Phone: (804) 828-7874

Cell: (501) 607-3472

Fax: (804) 828-5595

dparrish@mcvh-vcu.edu

No financial support was provided for this study.

Manuscript word count: 2496

Manuscript figure count: 6

NOTICE: this is the author's version of a work that was accepted for publication in *Annals of Allergy, Asthma & Immunology*. Changes resulting from the publishing process, such as peer review, editing, corrections, structural formatting, and other quality control mechanisms may not be reflected in this document. Changes may have been made to this work since it was submitted for publication. A definitive version was subsequently published in *Annals of Allergy, Asthma & Immunology*, Volume 112, Issue 4, April 2014, Pages 286–289, [doi:10.1016/j.anai.2014.01.026](https://doi.org/10.1016/j.anai.2014.01.026).

INTRODUCTION

Eosinophilic Esophagitis (EoE) is an increasingly prevalent condition characterized by chronic inflammation of the esophagus with a proposed etiology focused on dietary antigens ⁽¹⁾. This theory is further supported by the fact that most patients with EoE have a family history of allergic disorders ⁽²⁾. In the pediatric population, symptoms include food aversion, dysphagia, food impaction, failure to thrive, generalized abdominal pain, heartburn, nausea and vomiting. Since many other pediatric illnesses can present with these symptoms, multiple criteria are used in the diagnosis of EoE, including symptoms suggestive of esophageal dysmotility, histologic evidence of eosinophilic infiltration, resolution of esophageal eosinophilia with elimination diet or topical corticosteroid therapy, and the esophageal eosinophilia should not be responsive to proton pump inhibitor (PPI) therapy alone (PPI-RRE). Diagnosis is confirmed via mucosal biopsy when greater than 15 eosinophils per high-power field are present in the proximal and distal esophagus in the setting of a symptomatic patient. In addition to this histologic evidence, many visual findings can be suggestive of EoE. These include endoscopic findings of white exudative plaques, mucosal rings or trachealization of the esophagus, esophageal strictures, linear furrows, and edema ^(1, 4).

Current treatment for EoE involves diet modification, oral steroids, or both ^(1, 3). Many studies have been performed comparing different steroid regimens, including systemic, topical, and nebulized, with the safest and most typical steroid regimen consisting of viscous Budesonide respules (Pulmicort®, Astra Zeneca) mixed into a slurry-type

solution with sucralose artificial sweetener (Splenda®, Tate & Lyle and Johnson & Johnson) ^(1-3, 5-7).

Diagnosis

The patient is a 2 year old full term male, with history of breast feeding, who had no oral intake issues until he began eating solid foods at 10 months. When he was weaned from breast milk and started on solid food, he began having multiple episodes of emesis every day. Although never appearing to be nauseated, he continued vomiting after every meal and multiple times overnight until he was admitted to the local children's hospital in March 2012 for failure to thrive (FTT). His chief complaint at that time was a loss of weight at multiple previous office visits as well as a diagnosis of failure to thrive (<1st percentile starting at 9 months old). While in the hospital, a nasogastric (NG) tube was placed, and he was started on continuous tube feeds with Elecare® Junior (vanilla flavored). An Upper GI and Small Bowel series was performed demonstrating reflux with no anatomic abnormalities. Due to FTT, no PPI trial was attempted. Following an upper endoscopy, he was diagnosed with Eosinophilic Esophagitis based on esophageal biopsy results (upper biopsy: 5 eosinophils per high-power field, middle: 50, lower: 15) and visual evidence (furrows, erythema; Figures 1 and 2) and was started on 1 mg viscous Budesonide mixed with Splenda (1 mg budesonide mixed with five 1 gram packets of Splenda to create ~4cc slurry-type mixture) and Lansoprazole (Prevacid®, Novartis). Throughout his life, the patient was very active, reached appropriate milestones, and exhibited no symptomatic issues (nausea, lethargy, etc.) when he wasn't vomiting.

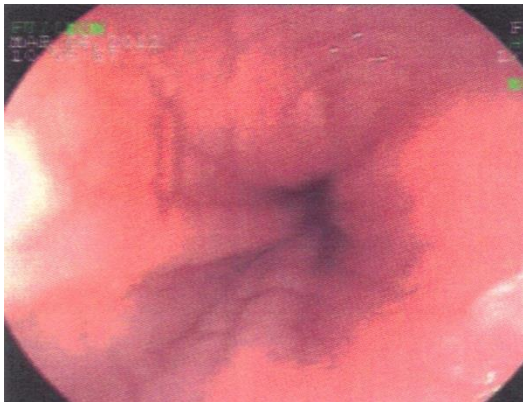

Figure 1. Endoscopy picture of lower third of esophagus demonstrating linear furrows and erythema, 3/6/2012.

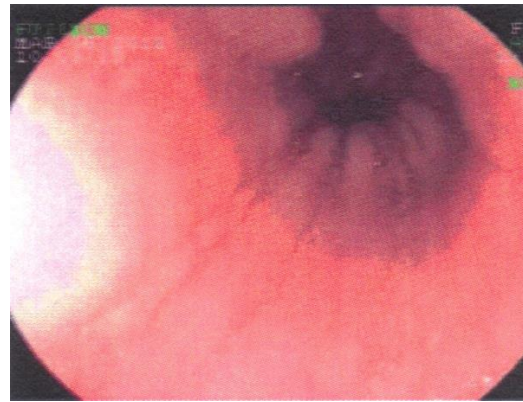


Figure 2. Endoscopy picture of middle third of esophagus demonstrating linear furrows and erythema, 3/6/2012.

After Treatment

His follow up upper endoscopy 3 months later demonstrated near complete resolution of eosinophils (upper: 3, lower: 2), but his symptoms, although lessened, were still present, in addition to a new symptom of daily episodes of lethargy. He had been strictly tube fed via NG or nasoduodenal tube from the time of his admission to the hospital in March to his June endoscopy. He continued having multiple episodes of emesis, including every night, but he had good weight gain (March =18.2 lbs; June = 20.9 lbs).

Due to his reflux, continued emesis, and the presumed need for long-term tube feeding, he received a Laparoscopic Nissen Fundoplication and Gastrostomy Tube placement. While in the hospital, his steroid and reflux medications were held due to difficulty increasing his tube feed rate, but on postoperative day three, the patient demonstrated that he was hungry and tolerated a half jar of baby food with no vomiting. He continued

eating a daily small meal in addition to his tube feeds and was discharged on postoperative day five tolerating his tube feeds at goal with no retching or vomiting.

Post-Operative Course

He was again started on his Budesonide/Splenda slurry upon his return home, but over the next several weeks and months, he continued experiencing daily episodes of retching, emesis, and lethargy. Changes were made to his feeding regimen but rarely to his medication regimen. Beginning in January 2013, he was taken off medications since no other interventions were helping and an attempt at increasing his PO intake was made. Surprisingly, his PO intake increased to the point that tube feeds were only used at night, and his episodes of emesis decreased to one every few days. Unsurprisingly, his February 2013 endoscopy demonstrated a return of his eosinophils on his esophageal biopsies (upper: 25, lower: 40) with continued visual evidence (Figures 3 and 4) of inflammation and white exudative plaques.

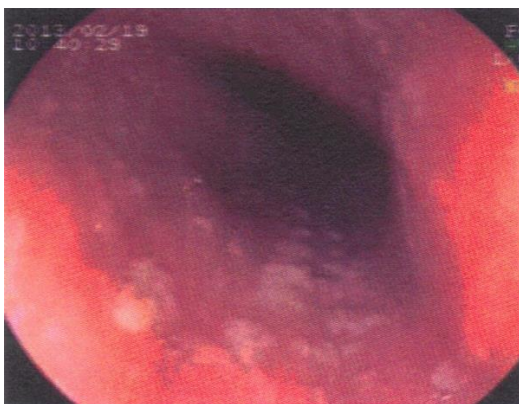


Figure 3. Endoscopy picture of middle third of esophagus with white exudative plaques and erythema, 2/19/2013.

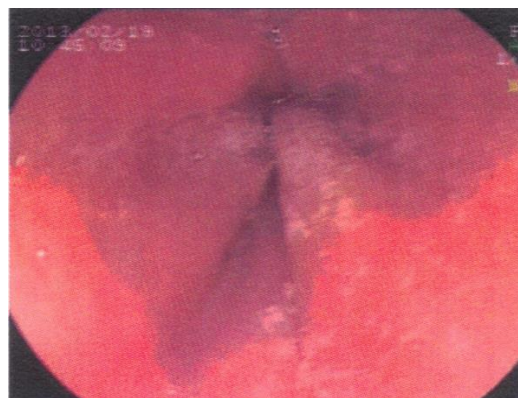


Figure 4. Endoscopy picture of lower third of esophagus with white exudative plaques and erythema, 2/19/2013.

Alternative Treatment Plan

Attempts made to restart the viscous budesonide and Splenda slurry were refused by the patient and parents because they had learned that another family member had reportedly had a cutaneous reaction to Splenda that resulted in patches of an erythematous and pruritic rash with eosinophilia. The suggestion was made to try mixing the Budesonide with honey instead of Splenda. However, the amount of honey needed to create a thick, slurry-like consistency was too much for the patient to ingest at one time. An assumption was made that the steroid could be mixed with any substance as long as the consistency of the slurry was such that the steroid coated the esophagus, so the family searched for substances at home to mix that the patient could tolerate and settled on mixing viscous Budesonide with 2 teaspoons of powdered sugar. The mixture was tolerated by the patient as far as taste, consistency, and amount (~5cc). He was not limited to an exclusive elemental diet as long as he was taking his steroid mixture daily, so the family enrolled the patient in an 8 week feeding program to assist in increasing his PO intake and the variety of foods in his diet, while still receiving nightly tube feeds.

His symptoms were unchanged, and he continued having an episode of emesis every few days. To evaluate whether there were any new anatomic or mechanical issues, a repeat Upper GI series and a Gastric Emptying study were performed and were negative. Due to the lack of symptom relief, everyone was unsure if the powdered sugar/Budesonide mixture was working. However, his endoscopy in June 2013 (4 months after the new

steroid mixture was started) demonstrated no evidence of Eosinophilic Esophagitis, visually (Figures 5 and 6) or on biopsies. And since his symptoms had remained unchanged, but not resolved, his formula was changed from Elecare Junior Vanilla to Unflavored Neocate, which has no Splenda, with near complete resolution of his symptoms 1 month later.

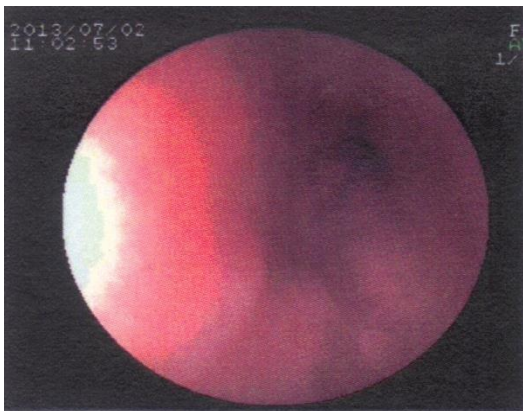

Figure 5. Endoscopy picture of lower third of esophagus with minimal erythema and no plaques or furrows, 7/2/2013.

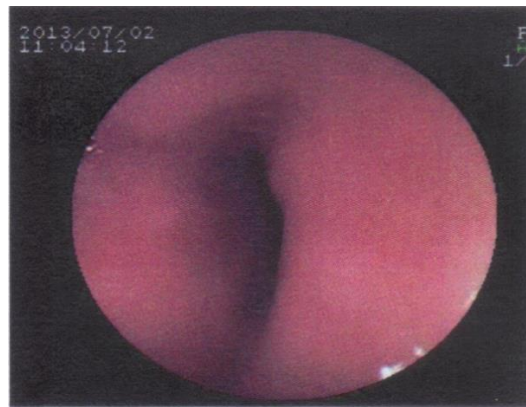


Figure 6. Endoscopy picture of middle third of esophagus with minimal to no erythema and no plaques or furrows, 7/2/2013.

DISCUSSION

Eosinophilic Esophagitis seems to be an ever-changing disease, from patient-to-patient and from year-to-year in the same patient. Improvements in these patients' lives have been made with the realization that elimination of dietary antigens helped with symptom relief and treatment with topical steroids assisted in eradication of esophageal eosinophils.

Our case has two very important aspects that should be emphasized. The first is the realization that it may be consistency of the steroid mixture rather than the ingredients that infer the effectiveness of the EoE treatment, and the second aspect is the willingness of the medical team to listen to the research and suggestions of the patient's parents and applying them to the treatment plan.

This case is potentially an example of a reaction or intolerance to the artificial sweetener, Splenda. Most studies have evaluated using Splenda in the mixture⁽⁵⁻⁷⁾. It is known, easy to measure, and dissolves well, but when the patient refuses the treatment whether it is due to taste or intolerance, the known and studied alternatives are lacking. Perhaps, the consistency is the most important aspect of the steroid mixture, and ensuring that the mixture is of the consistency such that it is thick enough to coat the esophagus, is more important than the mixing ingredient. Finding a mixing food that the child tolerates is potentially the most important part, whether it is powdered sugar or honey or pancake syrup or simply the last bite of a pureed meal.

Another important aspect of this case was the medical team and parents working together to determine the cause of continued symptoms. The parents noticed that when they would stop many of the patient's medications, including the steroid mixture, when he was experiencing an illness (cold, ear infection, etc.) and after his operation, he was not as lethargic, and the only symptoms that were present were from his acute illness. Parents' suggestions and ideas must be taken into account by medical teams because the parents see the patient every day and are able to see which treatments are most and least

effective, but also because the parents are dedicated to a single patient and are able to perform much more focused research and studying than doctors and nurses. This patient's parents making the extra effort, to not only research their child's illness but to research their family's medical history, contributed heavily to this case and may have prevented future unnecessary and/or invasive testing.

Every patient is different. Sometimes physician's own biases regarding disease management may cause them to overlook or ignore valuable input from the patient or the patient's caregivers. The need to step outside the typical treatment regimen should always be considered, and in this case, changing the regimen may have prevented further unnecessary and possibly invasive testing. By taking that extra step, the medical team was able to determine what was causing many of the patient's symptoms. Randomized trials are needed to assess whether this could be an alternative treatment, whether it is the mixture or the consistency that matters most, and to evaluate premixed EoE treatments.

A FATHER/PHYSICIAN'S PERSPECTIVE

The patient in this case report is my son. As a new father and a "seasoned" physician, in my 3rd month of my General Surgery residency, I loved every second of being a dad and thought about him nonstop. When I finally came to the realization that he was sick and the things going on with him were not normal, I felt like a failure as both a father and a physician. How could I not have seen what was going on? Had our delay in treatment caused significant problems?

When he finally began receiving the needed treatment, started feeling better and gaining weight, I felt like a hero again, as both a father and a physician. As an inpatient on the pediatric surgery service, any question we had regarding his care was answered quickly because I could pick up my phone and call the chief, mid-level, or first year resident or even the attending, and we knew what the day's plan would be. These were my friends and co-workers who were taking the time to answer my questions. Without my considerable advantages in obtaining the knowledge, the experience would have been potentially more frustrating. As physicians, sometimes we forget that the asymmetry of information is very powerful leverage, and we need to be sure that patient parents stay as informed as possible. But once we were finished as surgical patients, I quickly came to realize that I was the father to "just another patient."

We received care from Allergy and Immunology, Gastroenterology and Nutrition, General Pediatrics, Otolaryngology, and the Pediatric Feeding Clinic. Since Eosinophilic Esophagitis is not an illness commonly encountered on any surgical service, this was new territory for me, and my wife and I had lots of questions and concerns, especially regarding invasive testing. But far too often, the questions we deemed appropriate for one care team were quickly dismissed as another team's issue which were then passed off to another team...then another. As a physician I was more than familiar with this exercise. It was always part "I don't know the answer" and part "I don't want to be responsible for the outcome if I am wrong." I was also familiar with the use of excessive medical terminology and talking in circles to get out of a discussion that you don't have answers for. The answer we really wanted was simple, but nobody would say it. Just tell me you

don't know what's going on. Tell me you don't know why he's still throwing up and why he still can't eat anything after what has been appropriate treatment. Tell me you haven't seen this before, but you are going to help us figure out what is going on. As a parent or a patient, I want my physician to be honest when they do not have all the answers. Patients can accept that, so long as we trust that you are going to research the question further, or involve someone with more expertise that does know the answer.

In addition to the issues with communicating with our medical teams, I struggled with the thought that I was hindering my son's care. I would not call myself difficult to deal with because I was never confrontational, argumentative, or rude, but I did demand a reason for testing and an explanation for things that my wife may have agreed to without me. [Why do an expensive and time-consuming gastric emptying study when you can just start him on erythromycin and see if it helps? It's cheap, and if he doesn't improve, we have our answer... Explain how keeping him on a PPI helps with EoE when he has had a Nissen and no further evidence of reflux on his tests.] After a while, I got the feeling that suggestions regarding new medications or testing that a physician would normally make were no longer being made to prevent a flurry of questions. I don't know that this was actually happening, but it made me regret being so involved in my son's care. My residency had taught me to have a reason for everything I do, and if you cannot explain why you are doing it, you probably should not be doing it. Maybe it was unfair of me to question what other doctors and nurses felt was right, but I did not want my son to follow an algorithm. I wanted thought and care involved in every decision. With every decision, I wanted them to answer, what would you do if this were your son?

As physicians, we all encounter parents or patients who want justification for every care measure taken, and this can seem obstructive to care. What we have to realize is that this may be motivated by fear, concern, a loss of control, or other personal factors. Having been on both ends of this situation, this was a particularly enlightening experience that will help me communicate with families in the future. We have to remain sensitive to the patient experience.

REFERENCES

1. Lieberman JA, Chehade M. Eosinophilic esophagitis: Diagnosis and management. *Immunol Allergy Clin North Am.* 2012;32(1):67-81.
2. Liacouras CA, Markowitz JE. Eosinophilic esophagitis: A subset of eosinophilic gastroenteritis. *Curr Gastroenterol Rep.* 1999;1(3):253-258.
3. Dellon ES, Gonsalves N, Hirano I, et al. ACG clinical guideline: Evidenced based approach to the diagnosis and management of esophageal eosinophilia and eosinophilic esophagitis (EoE). *Am J Gastroenterol.* 2013;108(5):679-92; quiz 693.
4. Caetano AC, Goncalves R, Rolanda C. Eosinophilic esophagitis-endoscopic distinguishing findings. *World J Gastroenterol.* 2012;18(31):4221-4223.
5. Dellon ES, Sheikh A, Speck O, et al. Viscous topical is more effective than nebulized steroid therapy for patients with eosinophilic esophagitis. *Gastroenterology.* 2012;143(2):321-4.e1.
6. Dohil R, Newbury R, Fox L, Bastian J, Aceves S. Oral viscous budesonide is effective in children with eosinophilic esophagitis in a randomized, placebo-controlled trial. *Gastroenterology.* 2010;139(2):418-429.

7. Krishna SG, Kakati BR, Olden KW, Brown DK. Treatment of eosinophilic esophagitis: Is oral viscous budesonide superior to swallowed fluticasone spray? *Gastroenterol Hepatol (N Y)*. 2011;7(1):55-59.