

# PREVALENCE OF CORONARY ARTERY ANOMALIES DETECTED BY CORONARY CT ANGIOGRAPHY IN CANTON SARAJEVO, BOSNIA AND HERZEGOVINA

Fuad Zukić<sup>1</sup>, Miro Miljko<sup>2</sup>, Sandra Vegar-Zubović<sup>1</sup>, Adi Behmen<sup>1</sup> & Antonela Krasić Arapović<sup>3</sup>

<sup>1</sup>Clinic of Radiology, Clinical Center University of Sarajevo, Sarajevo, Bosnia and Hercegovina

<sup>2</sup>University Hospital, School of Medicine, Mostar, Bosnia and Hercegovina

<sup>3</sup>University Hospital, Departement of Clinical Radiology, Mostar, Bosnia and Hercegovina

received: 7.3.2017;

revised: 10.7.2017;

accepted: 15.11.2017

## SUMMARY

**Background:** Coronary artery anomalies (CAAs) are congenital variations of one or more of the coronary arteries and they are an uncommon but important cause of chest pain and, in some cases, sudden cardiac death. Anomalies of coronary arteries may be found incidentally in 0.3-1% of healthy individuals. The three types of coronary artery anomalies are anomalies of origin, anomalies of course and anomalies of termination.

The purpose of our study was to estimate the frequency of CAAs in Canton Sarajevo, B&H, and to determine the prevalence of origin, course and termination anomalies of coronary arteries.

**Subject and methods:** This was a retrospective analysis of 919 patients who underwent Coronary CT Angiography to determine CAAs in the period from 2013 to 2017.

**Results:** In our study, total number of CAAs have been found among the 130 patients (14.12%) out of which anomalies of origin are found at 14 patients (1.52%), anomalies of course at 115 patients (12.5%) and anomaly of termination in 1 patient (0.1%). Out of 14 cases in total anomalies of origin, anomalies of origin of the left coronary artery are observed among 11 patients (1.2%), and anomalies of origin of the right coronary artery among 3 patients (0.3%). From mentioned 14 cases of the anomalous origin of the coronary arteries, anomalies with clinical significance (interarterial, malignant course) of the coronary arteries are found among 6 patients (0.65%) and anomalies without clinical significance are found among 8 patients (0.87%). Coronary artery anomalies of origin with malignant course are divided in two groups: LMA from right sinus of Valsalva with interarterial course observed in 4 patients (0.43%) and RCA from left sinus of Valsalva, also with interarterial course in 2 patients (0.21%). We found 4 patients (0.43%) with separated origin LAD and LCX, without LMA. The prevalence rates of separate origin of RCA and conus artery, anomaly origin of the LCX from right coronary sinus, anomaly origin of the LMA from posterior coronary sinus and LMA from right coronary sinus without interarterial course were seen in 0.1% of patients. Among 115 cases of anomalies of course 111 cases (12.07%) belongs to bridging (37 cases to LAD; 25 cases to D1 and D2 and 49 to ramus intermedius), and 4 cases (0.43%) belongs to intraatrial course of RCA. Anomaly of termination presented with fistula between LCX and coronary sinus was found only in 1 case.

**Conclusion:** Coronary CT angiography is an excellent tool for diagnosis of CAAs regarding origin, course and termination of the coronary arteries.

**Key words:** prevalence - coronary artery anomalies - coronary CT angiography

\* \* \* \* \*

## INTRODUCTION

The coronary arteries arise from the aortic sinuses (Valsalva), converging towards the apex of the heart. Normally, there are two main coronary arteries, the right coronary artery (RCA) and the left main coronary artery (LMA), which is divided into the left anterior descending artery (LAD) and the left circumflex artery (LCX) (Villa A et al. 2016).

The RCA typically arises from the right sinus of Valsalva of the ascending aorta, passes anteriorly and to the right between the right auricle and the pulmonary artery, then descends vertically in the right atrioventricular sulcus. At the acute margin of the heart, the RCA turns to continue posteriorly in the sulcus onto the diaphragmatic surface and base of the heart. During its

course, several branches arise the RCA: the conus branch, the atrial branch, the sinus node artery, the right marginal branch, the atrioventricular nodal branch and the posterior interventricular branch.

The LMA typically arises from the left sinus of Valsalva, passes between the main pulmonary artery and the left auricle before entering the coronary sulcus and quickly bifurcates into the LAD and the LCX arteries. LMA can trifurcate into a LAD, LCX and a ramus intermedius. The ramus intermedius typically supplies the lateral and inferior walls, acting as a diagonal or obtuse marginal branch, while the arteries that usually supply this territory are small or absent. The LAD continues around the left side of pulmonary artery and descends in the apical fat obliquely toward the apex of the heart in the anterior interventricular sulcus. The

LAD gives rise to diagonal branches, one or two large branches that may arise and descend diagonally across the anterior surface of the left ventricle and to the septal perforator branches (D branches). The LCX courses toward the left, in the coronary sulcus and onto the diaphragmatic cardiac surface and usually ends before reaching the posterior interventricular sulcus. The LCX may give rise to the left marginal artery, a large branch, which continues across the rounded obtuse margin of the heart, the posterolateral branch and the obtuse marginal branch (OM branches) (Young et al. 2011, Menke et al. 1985, Chiribiri et al. 2011).

Coronary artery anomalies (CAAs) are congenital variations of the one or more of the coronary arteries and they are an uncommon but important cause of chest pain and, in some cases, sudden cardiac death. Asymptomatic CAAs are more common and have a better prognosis. The prevalence of CAAs is reported to be 0,3-1% of the general population. Greenberg et al. made a classification system where they classified CAAs as anomalies of origin, anomalies of course and anomalies of termination which is seen in table 1 (Smettei et al. 2017, Kim et al. 2016, Greenberg et al. 1989).

**Table 1.** Classification system of CCAs made by Greenberg et al. in 1989

Anomalies of origin	High takeoff Multiple ostia Single coronary artery Anomalous origin of left coronary artery from pulmonary artery (ALCAPA) Origin of coronary artery or branch from opposite or noncoronary sinus and an anomalous course
Anomalies of course	Myocardial bridging Duplication of arteries
Anomalies of termination	Coronary artery fistula Coronary arcade Extracardiac termination

**High Takeoff** refers the origin of either the RCA or the LMA at a point above the junctionalization zone between its sinus and the tubular part of the ascending aorta.

High takeoff of the coronary arteries usually presents no major clinical problems (Douglas et al. 1985).

In **multiple ostia**, typically either the RCA and the conus branch arise separately, or the LAD and LCX arteries arise separately with no LMA (Greenberg et al. 1989).

In the anomalous situation of a **single coronary artery**, only one coronary artery arises with a single ostium from the aortic trunk. A single coronary artery may either follow the pattern of a normal RCA or LMA, divide into two branches with distributions of the RCA

and LMA, or have distribution different from that of the normal coronary arterial tree (Smith 1950).

**Anomalous origin of the left coronary artery from the pulmonary artery** (ALCAPA) is one of the most serious CAAs. In the most common form of this disease, the LMA arises from the pulmonary artery and the RCA arises normally from the aorta (Bland-White-Garland syndrome) (Dodge-Khatami et al. 2002, Bland et al. 1933).

The four recognized patterns of an **anomalous origin of the coronary artery from the opposite or noncoronary sinus** are (a) the RCA arising from the left coronary sinus, (b) the LCA arising from the right coronary sinus, (c) the LCX or LAD artery arising from the right coronary sinus, and (d) the LMA or RCA (or a branch of either artery) arising from the noncoronary sinus. A coronary artery arising from the opposite or noncoronary sinus can take any of four common courses: (a) interarterial (between the aorta and the pulmonary artery), (b) retroaortic, (c) prepulmonic, or (d) septal (subpulmonic) (Greenberg et al. 1989, Ropers et al. 2002).

**Myocardial bridging** is caused by a band of myocardial muscle overlying a segment of a coronary artery. Is is most commonly localized in the middle segment of the LAD artery and ramus intermedius (Tio et al. 1997, Amoroso et al. 2004).

**Duplication of the LAD artery** consists of a short LAD artery, which courses and terminates in the anterior interventricular sulcus without reaching the apex, and a long LAD artery, which ariginates from either the LAD artery proper or a RCA, then enters the distal anterior interventricular sulcus and courses to the apex (Sajja et al. 2000).

**Coronary artery fistula** is a condition in which a communication exists between one or two coronary arteries and either a cardiac chamber, the coronary sinus, the superior vena cava, or the pulmonary artery. It more commonly involves the RCA than the LMA (Said et al. 1997, Neufeld et al. 1961).

**Coronary arcade** is a rare instance of communication that is large enough to be identified angiographically between the RCA and the LMA in the absence of coronary artery stenosis (Kruskal et al. 1995).

**Extracardiac termination** is a connection between the coronary arteries and extracardiac vessels (the bronchial, internal mammary, pericardial, anterior mediastinal, superior and inferior phrenic, intercostal arteries and the oesophageal branch of the aorta). These pathways become functionally significant only when a pressure gradient exists between two arterial systems (Kim et al. 2016, Greenberg et al. 1989).

The purpose of our study was to estimate the frequency of CAAs in Canton Sarajevo, B&H, and to determine the prevalence of origin, course and termination anomalies of coronary arteries.

## SUBJECTS AND METHODS

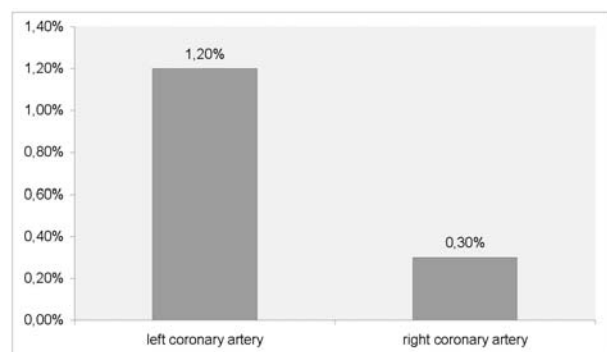
This was a retrospective analysis of 919 patients who underwent Coronary CT Angiography to determine CAAs in the period from 2013 to 2017 at the Clinical Center University of Sarajevo, Bosnia and Herzegovina. The study was approved by the Ethics Committee of Clinical Center University of Sarajevo.

Inclusion criteria for enrollment in the study were heart rate less than 65 bpm, avoiding coffee and smoking 12 hours prior to the procedure and avoiding eating solid food 4 hours prior to the procedure. Exclusion criteria were allergy on contrast agent, beta blocker and nitroglycerine and renal insufficiency. All patients with a baseline heart rate of >65 bpm received 5-20 mg of metoprolol intravenously. Sublingual nitroglycerin (0,5 mg) was given to all patients during the scan.

Coronary CT Angiography examination was performed using the unit GE Lightspeed VCT 64 Slice, which technical features includes X-ray tube rotation time of 0.35 s, a voltage of 120 kV and a layer thickness of 0.625 mm with the application of 80-100 ml intravenous iodine contrast media. Test bolus technique was used with a 5-seconds delay time after the peak contrast enhancement of a region of interest in ascending aorta, using 15ml of contrast agent, than 20ml saline.

## RESULTS

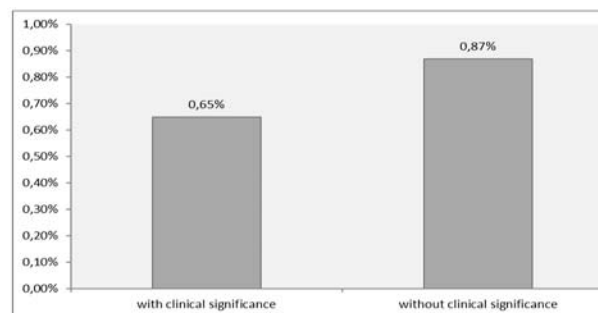
The total number of patients who underwent Coronary CT Angiography was 919. The frequency of CAAs in the population of Canton Sarajevo, Bosnia and Herzegovina, is shown in table 2. Chart 1 shows the frequency of anomalies of origin of the right and the left coronary artery, while chart 2 shows the frequency of anomalies with and without clinical significance. The division and frequency of anomalies with clinical significance of LMA and RCA is shown in chart 3, while the frequency of some cases of anomalies without clinical significance is shown in chart 4. Chart 5 shows the frequency of anomalies of course, and the frequency of same cases of bridging is shown in chart 6.



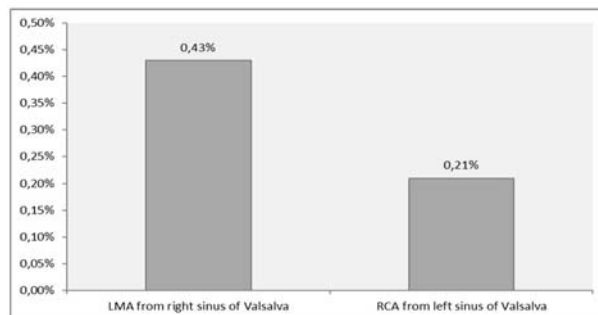
Graph 1. Anomalies of origin

Table 2. Frequency of CAAs

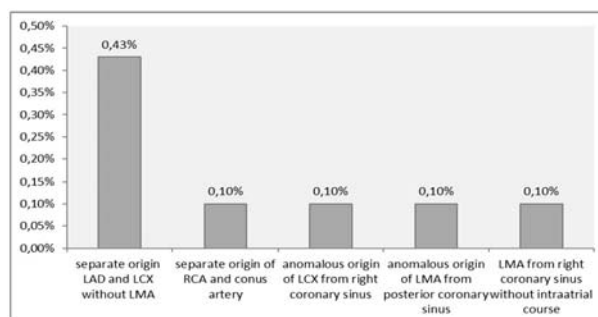
Patients who underwent Cardiac CT Angiography	Cases	%
Without CAAs	789	85.88
Anomalies of origin	14	1.52
Anomalies of course	115	12.50
Anomalies of termination	1	0.10
Total	919	100.00



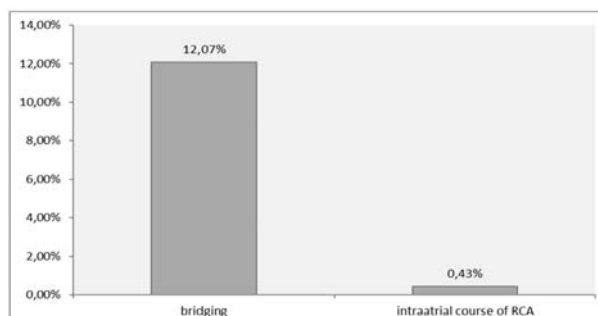
Graph 2. Clinical significance of anomalies



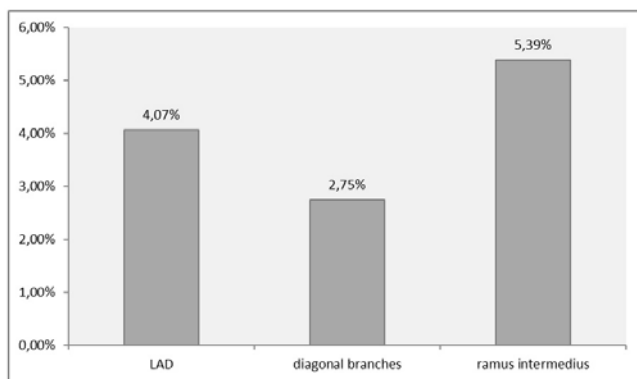
Graph 3. Anomalies with clinical significance (malignant course)



Graph 4. Anomalies without clinical significance (benignant course)



Graph 5. Anomalies of course



**Graph 6.** Frequency of some cases of bridging

## DISCUSSION

In our retrospective analysis of 919 patients who underwent Coronary CT Angiography in the Clinical Center University of Sarajevo, in the period from 2013 to 2017, we have found that CAAs were present in 130 patients (14.12%) out of which anomalies of origin were found in 14 patients (1.52%), anomalies of course in 115 patients (12.5%) and anomaly of termination in 1 patient (0.1%). In the literature data anomalies of origin and course were detected in 1.96% of the cases (Erol & Seker 2011).

Out of 14 cases in total anomalies of origin, anomalies of origin of the left coronary artery are observed among 11 patients (1.2%), and anomalies of origin of the right coronary artery among 3 patients (0.3%). From mentioned 14 cases of the anomalous origin of the coronary arteries, anomalies with clinical significance (interarterial, malignant course) of the coronary arteries are observed among 6 patients (0.65%) and anomalies without clinical significance are observed among 8 patients (0.87%). Coronary artery anomalies of origin with malignant course are divided in two groups: LMA from right sinus of Valsalva with interarterial course observed in 4 patients (0.43%) and RCA from left sinus of Valsalva, also with interarterial course in 2 patients (0.21%). We detected 4 patients (0.43%) with separated origin LAD and LCX, without LMA, which is corresponded to the literature data, where the same anomaly was found in 0.41% of patients (Danias et al. 2001). The prevalence rates of separate origin of RCA and conus artery, anomaly origin of the LCX from right coronary sinus, anomaly origin of the LMA from posterior coronary sinus and LMA from right coronary sinus without interarterial course were seen in 0.1% of patients, which is also corresponded to the literature data, where the separated origin of RCA was detected in 0.03-0.17% (Kim et al. 2016).

Among 115 cases of anomalies of course 111 cases (12.07%) belongs to bridging (37 cases to LAD – 4.07%; 25 cases to D1 and D2 – 2.75% and 49 to ramus intermedius – 5.39%), and 4 cases (0.43%) belongs to intraatrial course of RCA. The literature data show that

the prevalence of bridging the LAD has been 0.5-2.5%, which is less compare to our study (Amoroso et al. 2004).

Anomaly of termination presented with fistula between LCX and coronary sinus was observed only in 1 case (0.1%). In comparison with the literature data, a coronary artery fistula is observed in 0.33% of the patients (Erol & Seker 2011).

## CONCLUSION

Coronary CT angiography is an excellent tool for diagnosis of CAAs regarding origin, course and termination of the coronary arteries.

### **Acknowledgements:**

All of the listed co authors have contributed in this article through the work on the design of the study, literature search, literature and patient data analyses.

**Conflict of interest :** None to declare.

### **Contribution of individual authors:**

Fuad Zukić: Design of the study, literature searches, literature and patient data analyses

Miro Miljko: Design of the study, patient's data analyses

Sandra Vegar-Zubović: Design of the study, literature searches, patient's data analyses

Adi Behmen: Literature searches, patient's data analyses

Antonela Krasić Arapović: Design of the study, patient's data analyses

## References

1. Amoroso G, Battolla L, Gemignani C, Panconi M, Petronio AS, Rondine P, Mariani M, Falaschi F. Myocardial bridging on left anterior descending coronary artery evaluated by multidetector computed tomography. *Int J Cardiol* 2004; 95:335-337.
2. Chiribiri A, Ishida M, Nagel E, Botnar RM. Coronary imaging with cardiovascular magnetic resonance: current state of the art. *Pro Cardiovasc Dis* 2011; 54:240-252.
3. Danias PG, Stuber M, McConnell MV, Manning WJ. The diagnosis of congenital coronary anomalies with magnetic resonance imaging. *Coron Artery Dis* 2001; 12:621-626.
4. Dodge-Khatami A, Mavroudis C, Backer CL. Anomalous origin of the left coronary artery from the pulmonary artery: Collective review of surgical therapy. *Ann Thorac Surg* 2002; 74:946-955.
5. Douglas JS, Franch RH, King SB. Coronary artery anomalies. In: King SB, Douglas JS, eds. *Coronary arteriography and angioplasty*. New York, NY:McGraw Hill, 1985; 33-85.
6. EF, White PD, Garland J. Congenital anomalies of the coronary arteries: report of an unusual case associated with cardiac hypertrophy. *Am Heart J* 1933; 8:787-801.

7. Erol C, Seker M. Coronary artery anomalies: the prevalence of origination, course, and termination anomalies of coronary arteries detected by 64-detector computed tomography coronary angiography. *J Comput Assist Tomogr* 2011; 35(5):618-24.
8. Greenberg MA, Fish BG, Spindola-Franco H. Congenital anomalies of coronary artery: classification and significance. *Radiol Clin North Am* 1989; 27:1127-1146.
9. Kim SJ, Seo FB, Do KH, Heo FN, Lee FS, Song FW, Choe YH, Kim TH, Yong HS, Choi SI, Song KS, Lim TH. Coronary Artery Anomalies: Classification and ECG-gated Multi-Detector Row CT Findings with Angiographic Correlation. *RadioGraphics* 2016; 26:317-334.
10. Kruskal JB, Hartnell GG. Nonatherosclerotic coronary artery disease: more than just stenosis. *RadioGraphics* 1995; 15:383-396.
11. Menke DM, Waller BF, Pless JE. Hypoplastic coronary arteries and high takeoff position of the right coronary ostium. A fatal combination of congenital coronary artery anomalies in an amateur athlete. *Chest* 1985; 88:299-301.
12. Neufeld HN, Lester RG, Adams Pjr, Anderson RC, Lillehei CW, Edwards JE. Congenital communication of a coronary artery with a cardiac chamber or the pulmonary trunk (coronary artery fistula). *Circulation* 1961; 24:171-179.
13. Ropers D, Gehling G, Pohle K, Maeffert R, Regenfus M, Moshage W, Schuster P, Daniel WG, Achenbach S. Anomalous course of the left main or left anterior descending coronary artery originating from the right sinus of Val-salva identification of four common variations by electron beam tomography. *Circulation* 2002; 105:e42-e43.
14. Said SA, el gaman MI, van der Werf T. Coronary arteriovenous fistulas: collective review and management of six new cases-changing etiology, presentation, and treatment strategy. *Clin Cardiol* 1997; 20:748-752.
15. Sajja LR, Farooqi A, Shaik MS, Yarlagadda RB, Baruah DK, Pothineni RB. Dual left anterior descending coronary artery: surgical revascularization in 4 patients. *Tex Heart Inst J* 2000; 27:292-296.
16. Smettei OA, Sayed S, Abazid RM. The prevalence of coronary artery anomalies in Qassim Province detected by cardiac computed tomography angiography. *J Saudi Heart Assoc* 2017; 29:84-89.
17. Smith JC. Review of single coronary artery with report of 2 cases. *Circulation* 1950; 1:1168-1175.
18. Tio RA, Van Gelder IC, Boonstra PW, Crijns HJ. Myocardial bridging in a survivor of sudden cardiac near-death: role of intracoronary Doppler flow measurements and angiography during dobutamine stress in the clinical evaluation. *Heart* 1997; 77:280-282.
19. Villa A, Sammut E, Nair A, Rajani R, Bonamini R, Chiribiri A. Coronary artery anomalies overview: The normal and the abnormal. *World J Radiol* 2016; 8(6): 537-555.
20. Young PM, Gerber TC, Williamson EE, Julsud PR, Hefkens RJ. Cardiac imaging: Part 2, normal, variant, and anomalous configurations of the coronary vasculature. *AJR Am J Roentgenol* 2011; 197: 816-826.

Correspondence:

Fuad Zukić, MD

Clinic of Radiology, Clinical Center University of Sarajevo

Bolnička 25, 71000 Sarajevo, Bosnia & Hercegovina

E-mail: fuad\_zukic@hotmail.com