

# Tyrosine kinase inhibitors in sarcoma treatment (Review)

ANASTASIOS KYRIAZOGLOU<sup>1\*</sup>, LYDIA EVANGELIA GKARALEA<sup>2\*</sup>, IOANNIS KOTSANTIS<sup>1</sup>,  
 MARIA ANASTASIOU<sup>1</sup>, ANASTASIOS PANTAZOPOULOS<sup>1</sup>, MARIA PREVEZANOY<sup>1</sup>,  
 IOANNIS CHATZIDAKIS<sup>1</sup>, GEORGIOS KAVOURAKIS<sup>1</sup>, PANAGIOTA ECONOMOPOULOU<sup>1</sup>,  
 IOANNA FRAGKANDREA NIXON<sup>3</sup> and AMANDA PSYRRI<sup>1</sup>

<sup>1</sup>Second Propaedeutic Department of Medicine, Attikon University Hospital, 12462 Athens;

<sup>2</sup>Second Department of Medical Oncology, Agii Anargiri Cancer Hospital, 14564 Athens, Greece;

<sup>3</sup>Sarcoma Oncology, Beatson West of Scotland Cancer Centre, Glasgow G12 0YN, UK

Received December 15, 2021; Accepted March 29, 2022

DOI: 10.3892/ol.2022.13303

**Abstract.** Sarcomas are a group of rare mesenchymal malignant tumors that arise from transformed cells of the mesenchymal connective tissue, which are challenging to treat. The majority of sarcomas are soft tissue sarcomas (STSs; 75%) and this heterogeneous group of tumors is further comprised of gastrointestinal stromal tumors (~15%) and bone sarcomas (10%). Although surgery remains the current primary therapeutic approach for localized disease, recurrent, metastatic and refractory sarcomas require cytotoxic chemotherapy, which usually yields poor results. Therefore the efficiency of sarcoma treatment imposes a difficult problem. Furthermore, even though progress has been made towards understanding the underlying molecular signaling pathways of sarcoma, there are limited treatment options. The aim of the present study was therefore to perform a systematic literature review of the available clinical evidence regarding the role of tyrosine kinase inhibitors (TKIs) in patients with recurrent or refractory STSs and bone sarcomas over the last two decades. Tyrosine kinases are principal elements of several intracellular molecular signaling pathways. Deregulation of these proteins has been implicated in driving oncogenesis via the crosstalk of pivotal cellular signaling pathways and cascades, including cell proliferation, migration, angiogenesis and apoptosis. Subsequently, small molecule TKIs that target these proteins provide a novel potential therapeutic approach for several types of tumor by offering significant clinical benefits. Among the eligible articles, there were 45 prospective

clinical trials, primarily multicentric, single arm, phase II and non-randomized. Numerous studies have reported promising results regarding the use of TKIs, mainly resulting in disease control in patients with STSs. The lack of randomized clinical trials demonstrates the ambiguous efficiency of various studied treatment options, which therefore currently limits the approved drugs used in clinical practice. Research both in clinical and preclinical settings is needed to shed light on the underlying molecular drivers of sarcomagenesis and will identify novel therapeutic approaches for pretreated patients.

## Contents

1. Introduction
2. Methods
3. Results of the literature meta-analysis
4. Discussion
5. Conclusion

## 1. Introduction

Bone and soft tissue sarcomas (STSs) are malignant mesenchymal neoplasms. They represent 1% of all malignant diseases (1). The majority of sarcomas arise from soft tissue (75%), followed by gastrointestinal stromal tumors (GISTs; ~15%) and bone sarcomas (10%) (2). STSs are classified into 120 histological groups. Moreover, a recent World Health Organization classification described an even greater number of molecular subsets, comprising of a heterogeneous group of tumors with rare and ultrarare subcategories of STSs (3). The most common histological types are liposarcoma and leiomyosarcoma, with an incidence of less than 1 case in 100,000 individuals/year, which highlights the rarity of sarcomas (4).

Bone sarcomas have distinct patterns of incidence, with no more than 0.3 cases in 100,000 individuals/year for each bone sarcoma subtype (5). Osteosarcoma (OST) and Ewing sarcoma (ES) are most common in young individuals, with a high incidence rate in individuals <20 years old, whereas

---

*Correspondence to:* Dr Anastasios Kyriazoglou, Second Propaedeutic Department of Medicine, Attikon University Hospital, 1 Rimini Street, 12462 Athens, Greece  
 E-mail: tassoskyr@gmail.com

\*Contributed equally

**Key words:** soft tissue sarcoma, bone sarcoma, tyrosine kinase inhibitor

chondrosarcoma (CS) is more common in older adults (6). Extremities and trunk areas are the most common locations for the majority of bone sarcomas and approximately half of STSs. However, both bone and STSs can also develop in the head and neck, retroperitoneum, gastrointestinal tract and genitourinary tract (7,8).

A multidisciplinary approach is strongly recommended for sarcoma treatment due to the rarity and heterogeneity of bone sarcomas and STSs. Complete surgical resection remains the treatment of choice in regimens with curative intent. Cytotoxic chemotherapy is the backbone of the systemic treatment approach, but the discovery of various molecular signaling pathways implicated in sarcomagenesis has paved the way for targeted therapeutics (7-10). The targeting of tyrosine kinases is currently studied in clinical trials but this approach has also been used in clinical practice.

Tyrosine kinases are important molecules that cross-talk and regulate the activity of several intracellular signaling pathways. They are divided into two subtypes: i) receptor tyrosine kinases (RTKs); and ii) non-RTKs (NRTKs). RTKs are transmembrane glycoproteins that regulate proliferation, survival, migration, apoptosis and cell adhesion upon ligand binding. NRTKs act downstream of several signaling molecules and are located either in the cytoplasm or the nucleus. Tyrosine kinase receptors that have been considered as potential therapeutic targets in sarcomas include VEGFR, platelet-derived growth factor receptor (PDGFR), insulin-like growth factor receptor, cellular (c)-receptor tyrosine kinase KIT (KIT), fibroblast growth factor receptor (FGFR), mesenchymal epithelial transition (MET) and AXL receptor tyrosine kinase (AXL). Tyrosine kinase inhibitors (TKIs) are small molecules that inhibit these receptor tyrosine kinases (11,12).

The aim of the present systematic review was to discuss the role of TKIs in the treatment of patients with locally advanced, unresectable, or metastatic STSs and bone sarcomas.

## 2. Methods

This present review was conducted and reported in accordance with the Preferred Reporting Items for Systematic Reviews and Meta-Analyses (PRISMA) statement and the common practices in the field. Eligible articles were identified by performing a search of the Medical Literature Analysis and Retrieval System Online bibliographical database for the period between the 1 January 2000 and 30 August 2021. The search strategy included the following keywords: STS (neoplasm or cancer or sarcoma), bone sarcoma (neoplasm or cancer or sarcoma) and TKI (chemotherapy or systemic therapy or management). Only articles in English were included in the present review. Reviews, expert opinions and prospective and retrospective studies were also included, whereas case reports were excluded from the analysis. Moreover, manuscripts that did not state the name of the authors were excluded. Additional articles were identified from the reference lists of the retrieved articles.

## 3. Results of the literature meta-analysis

The initial literature search resulted in the identification of 351 articles, from which one duplicate was removed.

Moreover, one article was excluded due to language restrictions and 10 case reports were excluded; however, three case report series were included. Furthermore, 309 additional articles, which focused on sarcoma diagnosis, prognosis and biology, and articles presenting surgical approaches and primary or adjuvant sarcoma treatment or preclinical assays, or those referring to GISTs, were considered to be outside the scope of the present review and were therefore also excluded. Overall, 28 studies (27 prospective clinical trials—two phase I, one phase Ib/II and 24 phase II studies, of which five were randomized trials and one was a retrospective study) were recovered from the reference lists of rejected articles. Overall, 58 studies were considered eligible for inclusion in the final analysis. The research strategy is presented in Fig. 1.

The results identified 45 prospective clinical trials published between 2000 and 2021, among which six were phase I trials, two were phase Ib/II trials, 36 were phase II trials and one was a phase III trial. All studies were single arm, with the exception of seven previous, randomized, placebo-controlled trials (13-20). Moreover, 13 retrospective studies were analyzed (21-33). Furthermore, five reviews, one systematic literature review (34), one expert review (35) and three reviews of clinical trials (36-38) were identified.

*Pazopanib.* Pazopanib is a small molecule TKI. It primarily targets VEGFR-1/2/3, PDGFR- $\alpha/\beta$  and KIT (13).

The use of pazopanib in STSs was approved based on the results of the double-blinded, placebo-controlled, randomized, pazopanib explored in STS (PALETTE) phase III trial. This clinical trial demonstrated a significant improvement in the progression-free survival (PFS) of patients with non-adipocytic STS who were treated with pazopanib. The median PFS was 4.6 months for patients treated with pazopanib compared with 1.6 months for patients treated with the placebo ( $P < 0.0001$ ). However, no significant difference was observed in overall survival (OS; 12.5 vs. 10.7 months for the pazopanib and placebo arms, respectively) (14). Patients with liposarcoma were excluded from the PALETTE study based on the previous results of the European Organization for Research and Treatment of Cancer (EORTC) 62043 phase II study, in which patients in the liposarcoma cohort demonstrated a discouraging progression-free point at 12 weeks (39). However, preclinical investigations and prospective clinical trials focusing on dedifferentiated liposarcoma have reported that pazopanib has potential antitumor activity (40). In a phase II study of pazopanib for adipocytic sarcomas, a 68.3% PFS rate (PFSR) at 12 weeks and a median PFS of 4.4 months were demonstrated; well-differentiated liposarcomas were excluded from this study (41).

In a retrospective analysis based on two EORTC clinical trials, pazopanib was studied in uterine and nonuterine sarcomas. Pazopanib activity in patients with uterine sarcomas was similar to that in patients with nonuterine STSs. The PFS was 3.0 months (95% CI, 2.5-4.7 months) in uterine vs. 4.5 months (95% CI, 3.7-5.1 months) in nonuterine STS. Furthermore, the median OS was 17.5 months in the uterine STS population (95% CI, 11.1-19.6 months) vs. 11.1 months (95% CI, 10.2-12.0 months) ( $P = 0.352$ ) in the nonuterine STS population (21).

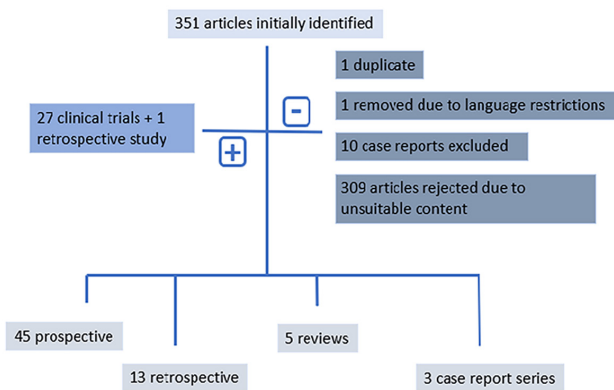


Figure 1. Diagram summarizing the elimination process of the initially identified published papers.

The activity of pazopanib in angiosarcoma (AS) is also comparable to its reported activity in other STS subtypes, as noted in a retrospective analysis (22). The median PFS and median OS were 3 (95% CI, 2.1-4.4 months) and 9.9 months (95% CI, 6.5-11.3 months), respectively, in AS. In this previous study, the activity of pazopanib was similar in cutaneous/non-cutaneous and radiation/non-radiation-associated AS. Furthermore, another study demonstrated that pazopanib exhibited promising activity in epithelioid hemangioendothelioma (EH) and intimal sarcoma (IS), two rare sarcomas with limited treatment options. The response rates were 8/40 (20%), 2/10 (20%) and 2/2 (100%) patients in the AS, EH and IS subtype groups, respectively.

The SPIRE study examined pazopanib for compassionate use in heavily pretreated patients with advanced STS. The treatment duration was influenced by histological subtype, with certain patients exhibiting long responses. Long responses were reported for perivascular epithelioid cell tumors (8.2 months), aggressive fibromatosis (AF; 8.0 months), alveolar soft part sarcoma (ASPS; 7.1 months), desmoplastic small round cell tumors (5.7 months) and synovial sarcoma (5.1 months). Histological subtypes with the highest percentage of clinical benefit [complete response (CR) + partial response (PR) + stable disease (SD)] at any time, included nonuterine leiomyosarcoma (45%; 18/40 patients), uterine leiomyosarcoma (43%; 17/40 patients), synovial sarcoma (54%; 13/24 patients), undifferentiated sarcoma (42%; 8/19 patients), AS (38%; 6/16 patients) and solitary fibrous tumors (54%; 7/13 patients) (23).

Pazopanib also benefits patients with surgically unresectable or metastatic CS. The disease control rate (DCR) was achieved in 43% of patients following 16 weeks of pazopanib treatment (95% CI, 28-58%) and the median OS was 17.6 months (95% CI, 11.3-35.0 months). Even though only 43% of patients reached the DCR, the results of this previous study are clinically meaningful as they offer the option of pazopanib in a traditionally chemotherapy-resistant disease (36,42).

Several case reports have also demonstrated PRs in patients with ES, with acquired resistance being developed with prolonged use (37). A single reference center case series report demonstrated that 2/4 patients with unresectable or metastatic chordoma, who were treated with pazopanib, derived clinical benefits and SD was achieved for 14 and 15 months (43).

The Pediatric Preclinical Testing Program evaluation of pazopanib revealed a statistically prolonged event-free survival (EFS) in ES xenografts but no objective responses were exhibited (44). Currently, in advanced OST, only case reports have been published with pazopanib (45).

Coadministration of TKIs with other targeted therapeutics and cytotoxic agents has also been investigated in retrospective studies. The safety and efficacy of pazopanib has been analyzed in combination with vorinostat, everolimus, lapatinib or trastuzumab, and MEK inhibitors in patients with advanced sarcoma. Pazopanib administration in combination with other agents is safe; however, pazopanib combinations do not reverse resistance. In a previous case series report, the inhibition of VEGFR with everolimus initially resulted in SD for the majority of patients with advanced sarcomas. The addition of everolimus resulted in a clinical benefit at 4 months for 3/6 patients (24). Moreover, a study on the addition of sirolimus in patients with metastatic high-grade STS, who progressed after previous clinical benefit on pazopanib, suggested that the combination of sirolimus and pazopanib may serve as a potential treatment to reverse resistance and extend the chemotherapy-free window (25). However, the small sample size of these aforementioned studies is a limitation that influences the statistical significance of these observations. Therefore, prospective studies are needed support the conclusions of these aforementioned studies. Furthermore, the combination of pazopanib with chemotherapy is associated with greater toxicity (26). Table I summarizes pazopanib clinical trials.

**Apatinib.** Apatinib is a small-molecule receptor TKI with potential antiangiogenic and antineoplastic activities. It selectively targets VEGFR2 and therefore inhibits endothelial cell migration and proliferation and further influences tumor microvascular density (46).

In a single-arm, phase II trial, apatinib exhibited encouraging objective efficacy and manageable toxicity in patients with metastatic STS who were previously unable to receive chemotherapy. At 12 weeks, the PFSR, objective response rate (ORR) and DCR were 70, 26.32 and 86.84%, respectively. The median PFS was 7.87 months and the median OS was 17.55 months. Apatinib was reported to be well tolerated, with the main adverse effects including, hypertension, palmar plantar erythrodysesthesia, anorexia, proteinuria, pain, fatigue and diarrhea, which were adequately controlled following symptomatic treatment or dose reduction to 375 mg and subsequently 250 mg (47). In an observational study, patients with leiomyosarcoma treated with apatinib did not show significant survival benefits compared with patients with other histological subtypes. The median PFS was 3.79 months (95% CI, 0.96-7.24 months) in patients with leiomyosarcoma vs. 4.35 months (95% CI, 2.22-5.58 months) in patients with other histological subtypes (P=0.3170). The median OS was 8.17 months (95% CI, 1.56 months-not estimated) months in patients with leiomyosarcoma vs. 11.22 months (95% CI, 6.64-18.72 months) in patients with other histological subtypes (P=0.9219) (27).

The results from a prospective phase II trial demonstrated that the administration of apatinib in patients with unresectable, locally advanced or metastatic OST, which was progressing upon prior treatment with chemotherapy agents,

Table I. Pazopanib.

Study type	Phase	Patient number	Subtype	PFS (months)	OS (months)	Outcomes	(Refs.)
Randomized	III	372	Non-adipocytic STS	4.6	12.5	Approved as 2nd line treatment	(14)
Prospective	II	41	Liposarcoma	4.4	12.6	Promising activity	(41)
Retrospective		44	Uterine sarcomas	3	17.5	Promising activity	(21)
Retrospective		42	Vascular sarcomas	3	9.9	Promising activity	(22)
Retrospective		211	Advanced STS	3	11.1	Activity in compassionate use setting	(23)
Prospective	II	47	Chondrosarcoma	7.9	17.6	Negative	(42)
Retrospective		9	Advanced sarcoma	3.1	-	Disease stability with the combo of pazopanib + everolimus	(24)
Retrospective		8	Advanced STS	5.5	-	Promising activity	(25)
Retrospective		44	Advanced sarcoma	2.4	9	Negative	(26)

STS, soft tissue sarcomas; PFS, progression-free survival; OS, overall survival.

resulted in tumor shrinkage of at least 30% in 16/37 patients (43.24%). However, this result only had a short response duration, as the median duration response was 5.07 months (95% CI, 2.70-6.53 months) (48). In a recently published retrospective study, a regime of a combination of apatinib with ifosfamide and etoposide exhibited clinically meaningful antitumor activity in patients with recurrent or refractory OST, as the 4- and 6-month EFS rates were 90.9 (95% CI, 74.4-97.0%) and 78.5% (95% CI, 60.0-89.1%), respectively. However, the adverse effects of the combination were severe and the majority of grade 3 and 4 toxicities included myelosuppression, bronchial infection, pneumothorax, anorexia and posterior leukoencephalopathy syndrome, which resulted in dose reductions (28).

In an off-label study of apatinib in patients with advanced, previously treated bone and STS, toxicity was more severe than results reported in clinical trials. The ORR (CR + PR) was 40.9% (9/22 patients) for OST, 70% (7/10 patients) for ES, 100% (3/3 patients) for CS and 71.4% (15/21 patients) for STS. Moreover, the median duration of response was 8.8 months (95% CI, 4.3-11.5 months) for malignant peripheral nerve sheath tumors and 5.6 months (95% CI, 1.3-9.8 months) for undifferentiated pleomorphic sarcoma (UPS) (29).

In preclinical studies, apatinib reduces programmed death-ligand 1 (PD-L1) expression in OST cells, which suggested that it may act as an immunotherapy modulator in patients with sarcoma (49,50). An open-label, phase II trial studying the combination of apatinib with camrelizumab (an anti-programmed cell death 1 antibody) revealed prolongation of PFS compared with apatinib only in treating advanced OST (51). However, this previous clinical trial did not reach the prespecified target of a 6-month PFS of 60%. This study also suggested that patients with high PD-L1 expression levels and pulmonary metastases exhibited a longer PFS than those with bone lesions ( $P=0.017$ ). Table II summarizes the clinical trials that have studied apatinib.

**Sunitinib.** Sunitinib malate is a multitargeted TKI with activity against VEGFR1/2/3, PDGFR- $\alpha/\beta$ , KIT, Fms-like

tyrosine kinase 3 (FLT3), RET and colony stimulating factor 1 (CSF1) (52). Sunitinib also has both antiangiogenic and anti-tumor activities.

George *et al* (53) reported a multicenter, single-arm, phase II study of sunitinib in metastatic or locally advanced non-GIST STS, in which 53 patients were enrolled and 48 of them were eligible for response assessment. An imaging assessment demonstrated a median PFS of 1.8 months, with 11/48 patients (22%) exhibiting SD at 12 weeks and seven patients (14%) maintaining SD after 24 weeks of treatment (53). In another phase II study, 48 patients with documented unresectable or metastatic STS (liposarcoma, leiomyosarcoma and UPS), in which other therapeutic approaches had failed, were treated with sunitinib malate. The median PFS and OS for liposarcoma, leiomyosarcoma and malignant fibrous histiocytoma were 3.9 and 18.6, 4.2 and 10.1 and 2.5 and 13.6 months, respectively. The safety profile did not reveal any new toxicities, with the most common adverse effects being fatigue/asthenia and other gastrointestinal complaints at grade 1 or 2 (54).

A further small, nonrandomized, open-label, prospective, phase II trial of sunitinib was performed by Jo *et al* (55), in which 19 patients with advanced AF, which was not amenable to surgery, were treated with 37.5 mg sunitinib once daily. Following treatment, five patients (26.3%) achieved a PR and eight (42.1%) presented with SD. With a median follow-up time of 20.3 months (range, 1.8-50.7 months), the 2-year rates for PFS and OS were 74.7 and 94.4%, respectively. However, 3/12 patients in this trial with mesenteric AF experienced serious adverse effects, including mesenteric mass bleeding ( $n=1$ ), bowel perforation ( $n=1$ ) and bowel fistula ( $n=1$ ), which were likely to be related to tumor necrosis. Therefore, sunitinib may be useful for the management of non-mesenteric AF (55). Sunitinib has also been tested in patients with metastatic ASPS in a small case series. In nine patients with progressive/advanced ASPS, treated with sunitinib, five patients (55%) had a PR, based on the Response Evaluation Criteria in Solid Tumors (RECIST), and an additional three patients (33%) exhibited SD (56). When sunitinib was given to 31 patients with progressive advanced solitary fibrous tumors, of which 25 patients were pretreated with conventional

Table II. Apatinib.

Study type	Phase	Patient number	Subtype	PFS (months)	OS months)	Outcomes	(Refs.)
Prospective	II	42	Advanced STS	7.87	17.55	Promising activity	(47)
Retrospective	II	31	Advanced STS	4.25	9.43	Promising activity	(27)
Prospective	II	37	Advanced OS	4.5	9.87	Moderate activity	(48)
Retrospective		79	Advanced OS	12.6	19.8	High toxicity	(28)
Prospective	II	43	Advanced OS	6.2	-	Negative	(51)

STS, soft tissue sarcomas; PFS, progression-free survival; OS, overall survival.

chemotherapeutic regimens, disease control was achieved in 18/31 patients (58%) with a median PFS of 6 months (30). In a retrospective case series of 10 patients with extra-skeletal myxoid CS treated with sunitinib, 6/10 patients (60%) had a PR, which was determined using RECIST, two patients presented with SD (20%) and two patients exhibited disease progression (20%) (31). The single-arm, nonrandomized design of these studies limited any definitive conclusions regarding the efficacy of sunitinib in STS. However, the activity of sunitinib in specific subtypes is very promising despite the often-indolent nature of these tumors, such as AF.

Sunitinib has previously been co-administered with nivolumab in patients with refractory, advanced sarcomas. The ImmunoSarc trial evaluated the efficacy of sunitinib in combination with nivolumab as assessed by PFSR at 6 months. The 6-month PFSR was 48% according to the central assessment, whereas the median PFS was 5.6 months (3-8.1 months). One CR was registered in a patient with AS and a PR was described in patients with ASPS, AS, synovial sarcoma and extra-skeletal myxoid CS (57). The bone sarcoma group demonstrated similar results, with a 6-month PFSR of 32% and a modified (m)PFS of 3.7 months (95% CI, 3.4-4.0 months). Moreover, the median OS was 14.2 months (95% CI, 7.1-21.3 months), inducing durable disease control in 55% of patients and a PR in one patient with OST (58). Table III summarizes the trials that have studied sunitinib.

**Regorafenib.** Regorafenib is an oral multikinase inhibitor that targets VEGFR1/2/3, FGFR1, PDGFR- $\alpha/\beta$ , CSF1 receptor and c-KIT (59).

A randomized placebo-controlled phase II trial, regorafenib in metastatic STS (REGOSARC), was performed for non-GIST STSs in which the response and survival benefit of regorafenib were evaluated in four cohorts (leiomyosarcoma, synovial sarcoma, liposarcoma and other histologies). Three cohorts, excluding the patients with liposarcoma, exhibited PFS prolongation compared with the placebo arm. PFS was 1.1 months with regorafenib (95% CI, 0.9-2.3 months) vs. 1.7 months (0.9-1.8) with the placebo [hazard ratio (HR), 0.89; 95% CI, 0.48-1.64 months] (P=0.70) in the liposarcoma cohort. Furthermore, in the leiomyosarcoma cohort PFS was 3.7 months (95% CI, 2.5-5.0 months) with regorafenib vs. 1.8 months (95% CI, 1.0-2.8 months) with the placebo (HR, 0.46; 95% CI, 0.46-0.80 months) (P=0.0045). In the synovial sarcoma cohort, PFS was 5.6 months (95% CI, 1.4-11.6 months) with regorafenib vs. 1.0 months (95% CI, 0.8-1.4 months) with

the placebo (HR, 0.10; 95% CI, 0.03-0.35 months) (P<0.0001). Finally, in the other histologies sarcoma cohort, PFS was reported to be 2.9 months (95% CI, 1.0-7.8) with regorafenib vs. 1.0 months (95% CI, 0.9-1.9) with the placebo (HR, 0.46; 95% CI, 0.25-0.81 months) (P=0.0061) (15). The REGOSARC trial also demonstrated the benefits of quality-adjusted survival (60). The survival benefits of regorafenib in the REGOSARC trial were similar to those of pazopanib. The median PFS of the regorafenib-treated patients with non-liposarcoma was limited to 4 months and the OS was limited to 13.4 months. Moreover, regorafenib treatment for liposarcoma, similar to pazopanib, failed to result in PFS prolongation (38). The most common clinically significant grade 3 or higher adverse events exhibited included arterial hypertension (19%), hand and foot skin reactions (15%) and asthenia (13%).

The results of a prospective, open-label, single-arm, nonrandomized phase II trial verified that regorafenib is active in patients with non-adipocytic pretreated advanced STS (leiomyosarcoma, synovial sarcoma and vascular sarcoma), as 13/21 (62%) patients were progression-free at 8 weeks (61). Therefore, regorafenib proved to have a clinically meaningful antitumor effect in non-adipocytic STSs by improving PFS.

The randomized, double-blind, placebo-controlled regorafenib in patients with metastatic bone sarcomas (REGOBONE) and SARC024 clinical trials, in relapsed progressive metastatic OST, demonstrated the benefit of regorafenib in patients with bone sarcoma. In the REGOBONE trial, 38 patients with advanced bone sarcoma were randomized (2:1) to receive either regorafenib or the placebo. This study demonstrated that 17/26 patients (65%; one-sided 95% CI, 47%) in the regorafenib group were nonprogressive at 8 weeks compared with no patients in the placebo group, resulting in a median PFS of 4.1 months (95% CI, 8.0-27.3 months) vs. 1.0 month (95% CI, 3.0-5.7 months), respectively (16). Similarly, in the North American trial, among the 22 patients treated with regorafenib, a median PFS of 3.6 months was achieved vs. 1.7 months in the placebo group (HR, 0.42; 95% CI, 0.21-0.85 months; P=0.017). However, regarding OS, there was no statistically significant difference (11.1 vs. 13.4 months for regorafenib and placebo, respectively; P=0.62) (17).

SARC024 also assessed the efficacy of regorafenib in 30 patients with advanced ES, in which it was noted that the median PFS was 3.6 months (95% CI, 2.8-3.8 months) and the median duration of response was 5.5 months (95% CI, 2.9-8.0 months). This study met its primary endpoint and the toxicity of the drug was similar to that seen previously; no

Table III. Sunitinib.

Study type	Phase	Patient number	Subtype	PFS (months)	OS	Outcomes	(Refs.)
Prospective	II	53	Advanced STS	1.8	-	Activity in DC (SD)	(53)
Prospective	II	48	Liposarcoma, leiomyosarcoma, malignant fibrous histiocytoma	3.9 (LS) 4.4 (LMS) 2.5 (MFH)	18.6 (LS) 10.1 (LMS) 13.6 (MFH)	Moderate activity	(54)
Prospective	II	19	Advanced aggressive fibromatosis	74.7% (median follow-up time of 20.3 months)	94.4% (median follow-up time of 20.3 months)	Promising activity	(55)
Retrospective		35	Advanced solitary fibrous tumor	6	16	Promising activity with a long-lasting response	(30)
Retrospective		10	Extraskelatal myxoid chondrosarcoma	Not reached	-	Statistically non-significant	(31)
Prospective	Ib/II	68	Advanced STS	5.6	24	Promising activity	(57)
Prospective	II	40	Advanced OS	3.7	14.2	Promising activity	(58)

STS, soft tissue sarcomas; PFS, progression-free survival; OS, overall survival.

grade 4 adverse effects were noted (18,37). In the same study, the OST cohort included 42 patients and regorafenib resulted in a mPFS of 3.6 (95% CI, 2-7.6 months) vs. 1.7 months (95% CI, 1.2-1.8 months) for the placebo. There was no benefit to OS. Table IV summarizes the trials that have studied regorafenib.

**Sorafenib.** Sorafenib targets Raf, VEGFR2/3 and PDGFR- $\beta$ , and therefore inhibits tumor cell proliferation and angiogenesis (37).

In a prospective multicenter open-label nonrandomized phase II trial, 101 patients with advanced STS, pretreated with anthracycline-based chemotherapy, received sorafenib (400 mg) twice daily for 28 days. Even though the primary endpoint of the PFSR at 6 months was not reached by the entire population, patients with leiomyosarcoma achieved a 6-month PFSR of 38.4%, which confirmed the activity of sorafenib in this subset of patients (62). In the French Sarcoma Group study, which assessed the response to sorafenib in 41 patients with advanced AS, the primary end point was PFS at 9 months, which was assessed by RECIST. There were no responses reported in the chemotherapy naïve group, but there was a 40% tumor control rate and a 23% response rate in pretreated patients (63). Similar results were seen in another phase II trial of 51 patients with advanced STS, in which five patients with vascular sarcoma (63%), eight patients with leiomyosarcoma (42%) and two patients with dedifferentiated liposarcoma (20%) had SD, resulting in a median PFS of 5 months for patients with vascular sarcoma compared with 2-3 months for the patients with liposarcoma and leiomyosarcoma (64).

Regarding bone sarcomas, sorafenib has also demonstrated activity in patients with OST. The Italian Sarcoma Group designed a single-arm phase II study of sorafenib as a single treatment agent in patients with relapsed and unresectable OST. PFS at four months was 46%, whereas OS was 7 months. An objective response was seen in 14% of

patients and 29% of patients had SD (65). Another previous nonrandomized phase II trial used a combination of sorafenib and everolimus in 38 patients with high-grade, nonresectable OST. This combination demonstrated the greatest antitumor activity as a second- and third-line treatment for OST, as 17/38 patients (45%; 95% CI, 28-61) were progression free at 6 months. However, the trial did not reach the prespecified threshold of activity (6-month PFS  $\geq$ 50%) with a 6-month PFS of 45% (66).

**Cabozantinib.** Cabozantinib inhibits the activity of multiple tyrosine kinases that are expressed in STSs, such as MET, VEGFR, AXL and TYRO3 protein tyrosine kinase (67).

In a phase II study, 20 heavily-treated patients with relapsed uterine leiomyosarcoma received a combination of temozolomide and bevacizumab without (n=9) or with cabozantinib (n=6). Cabozantinib, in combination with temozolomide and bevacizumab, increased the clinical benefit rate (CBR) from 67 to 100%, without providing any additional benefits to the ORR (33% for both cohorts) (68).

In the phase II cabozantinib in patients with advanced ES or OS clinical trial, heavily pretreated patients with OST (n=45) or ES (n=45) were enrolled and patients were treated with cabozantinib (60 mg) once daily in adults or 40 mg/m<sup>2</sup> once daily in children (<16 years). In patients with OST and ES, the median PFS was 6.7 (95% CI, 5.4-7.9 months) and 4.4 months (95% CI, 3.7-5.6 months), respectively, and the median OS was 10.6 (95% CI, 7.4-12.5 months) and 10.2 months (95% CI, 8.5-18.5 months), respectively, which demonstrated promising activity for cabozantinib. However, 61/90 (68%) patients presented with at least one serious adverse event. No deaths due to drug-related toxic effects were reported (69).

**Cediranib.** Cediranib is a receptor TKI that targets VEGFR1/2/3, KIT and PDGFRs (70).

Table IV. Regorafenib.

Study type	Phase	Patient number	Subtype	PFS (months)	OS (months)	Outcomes	(Refs.)
Randomizee	II	182	Liposarcoma, leiomyosarcoma, synovial sarcoma, other histologies	1.1 (LS) 3.7 (LMS) 5.6 (SVS) 2.9 (other)	-	Promising activity except from LS	(15)
Prospective	II	21	Advanced STS	3.8	14.8	Clinical activity	(61)
Randomized	II	38	Advanced OS	4.1	-	Clinical activity	(16)
Randomized	II	42	Advanced OS	3.6	-	Clinical activity	(17)
Randomized	II	30	Ewing sarcoma	3.6	-	Clinical activity	(18)

STS, soft tissue sarcomas; PFS, progression-free survival; OS, overall survival; LS, liposarcoma; LMS, leiomyosarcoma; SVS, synovial sarcoma.

A phase II study, including GISTs and sarcomas, reported the activity of cediranib in metastatic ASPS. Of the six patients with ASPS, two achieved PR and four exhibited SD (71). Further investigation in a double-blind, placebo-controlled, randomized, phase II trial confirmed cediranib's activity in ASPS (19). A total of 48 patients with advanced ASPS were recruited and randomly assigned to cediranib treatment (n=32) or placebo (n=16) groups. The primary endpoint was the percentage change in the sum of the longest diameters of target marker lesions between the baseline and week 24, or progression if this was sooner. The median PFS was 10.1 months (95% CI, 5.3-19.0 months) with cediranib and 4.9 months (95% CI, 1.9-20.0 months) with the placebo.

A pediatric phase I study of cediranib for children and adolescents with refractory solid tumors defined the maximum tolerated monotherapy dose as 12 mg/m<sup>2</sup>/dose administered orally, once daily, continuously. Objective responses were observed in pediatric patients with ES, synovial sarcoma and OST, which resulted in a reduction in primary tumor size and pulmonary metastatic lesions (72). As a result, a phase II study of cediranib in children with metastatic ASPS was developed. This study did not reach the primary endpoint and cediranib as a single agent was found to be inactive in ASPS in the pediatric cohort compared with the adult PR rate of 35%. Therefore, the role of cediranib in the treatment of children and adolescents with ASPS remains unclear (73).

**Crizotinib.** Crizotinib is a small molecule that targets MET, anaplastic lymphoma kinase (ALK) and ROS proto-oncogene 1 receptor tyrosine kinase.

The EORTC initiated a multinational, multi-tumor, prospective phase II clinical trial, cross-tumoral phase II with crizotinib ('CREATE'), and evaluated the efficacy and safety of crizotinib in patients with advanced tumors characterized by abnormal MET and/or ALK expression. In this study 26/43 enrolled patients with clear-cell sarcoma were treated with crizotinib. The study design focused on MET+ disease with documented rearrangement of the EWS RNA binding protein 1 gene confirmed via fluorescence *in situ* hybridization. The primary end point of the trial, the ORR, was not met, as only one objective PR was observed in 26 MET+ patients (ORR, 3.8%;

95% CI, 0.1-19.6%). However, disease control was achieved in 18/26 MET+ patients (DCR, 69.2%; 95% CI, 48.2-85.7%) and the median PFS was 131 days (95% CI, 49-235 days). This trial demonstrated that crizotinib could potentially provide clinical benefits to patients with locally advanced or metastatic MET+ clear-cell sarcoma (74). The 'CREATE' trial also demonstrated that crizotinib is an active compound for patients with advanced or metastatic ASPS with central determination of rearrangement of transcription factor binding to IGHM enhancer 3. The DCR determined in this histotype-specific trial was 90% (36/40 MET+ patients; 95% CI, 76.3-97.2%) and the PFSR at 1 year was 37.5% (95% CI, 22.9-52.1%) (75). Crizotinib as a single agent in patients with advanced metastatic alveolar rhabdomyosarcomas was well tolerated but lacked clinically meaningful activity, with a median PFS of 1.3 months (95% CI, 0.5-1.5 months) and a median OS of 5.6 months (95% CI, 0.7-7.0 months) (76). Crizotinib could be considered as the standard of care for patients with locally advanced or metastatic ALK-positive inflammatory myofibroblastic tumors, as 6/12 ALK+ patients (50%; 95% CI, 21.1-78.9) and 1/7 ALK-negative patients (14%; 95% CI, 0.0-57.9) achieved an objective response according to RECIST 1.1 in the 'CREATE' trial (77).

**Axitinib.** Axitinib is a selective small molecule inhibitor of VEGFR1/2/3 that binds to the inactive conformation of the catalytic domain of VEGF RTKs.

A phase I trial of young patients with refractory solid neoplasms demonstrated the safety and tolerability of axitinib. One patient with ASPS had a confirmed PR that lasted for 6 months and both patients with OST and ½ patients with ES were progression free at 6 months of axitinib treatment (78).

Moreover, the combination of axitinib plus pembrolizumab was used in 33 patients with advanced sarcomas, including ASPS, in a single-arm, phase II trial. This treatment combination was reported to result in 3-month PFS rates of 65.6% (95% CI, 46.6-79.3%) for all evaluable patients, especially leiomyosarcoma and UPS, and 72.7% (95% CI, 37.1-90.3%) for patients with ASPS, with a manageable toxicity profile (79).

**Anlotinib.** Anlotinib inhibits angiogenesis signaling via selectively targeting VEGFR1/2/3 and FGFR1/2/3/4. Furthermore,

it targets and decreases the activity of PDGFR- $\alpha/\beta$ , c-KIT and RET and therefore significantly inhibits tumor cell proliferation in preclinical studies (80).

In a phase I, open-label study, at a dose of 12 mg once daily with a 2-1 treatment schedule, anlotinib displayed significant antitumor effects in patients with advanced refractory solid tumors, including STS (80). A phase II clinical trial demonstrated that 166 patients with advanced STS had a 12-week PFSR of 68.42% and an ORR of 12.65% following treatment with anlotinib. PFS and OS were 5.63 and 12.33 months, respectively (81). A placebo-controlled trial of 233 patients with recurrent advanced STS presented with a PFS of 6.27 months vs. 1.47 months ( $P < 0.0001$ ) for anlotinib compared with the placebo (82). A retrospective single-center analysis studying the combination of chemotherapy with anlotinib and anlotinib maintenance in patients with metastatic STS, reported that the treatment had good efficacy and a favorable survival benefit. The PFS at 3 and 6 months was 81 and 69%, respectively (32).

**Imatinib.** Imatinib is known to inhibit c-KIT, the breakpoint cluster region-ABL fusion protein and PDGFRs (83).

In a phase II multicenter trial, the efficacy of imatinib was tested in patients with different subtypes of advanced sarcoma. However, although CBRs, defined as SD + PR + CR, were exhibited in the subgroups of patients with liposarcomas (CBR=24.1%) and leiomyosarcomas (CBR=21.4%), imatinib was not considered an active agent in patients with advanced STS (84).

In a collaborative Italian-Swiss, prospective, phase II clinical trial, 56 patients with advanced chordoma expressing PDGFR- $\beta$  and/or platelet-derived growth factor subunit B (PDGFB) were treated with imatinib. Confirmed SD (RECIST PR + SD) was observed in 72% of patients, with a median PFS of 9 months and a 64% CBR, defined as RECIST CR + PR + SD, which was greater than that exhibited at 6 months (85). Trials with imatinib have demonstrated promising results, especially in PDGFB+ or PDGFR- $\beta$ + chordomas, whereby SD has been exhibited in previously progressive advanced chordomas in up to 70% of cases. However, no benefit in survival rates was noted (33).

Imatinib as a single agent has also been tested in young patients with relapsed or refractory ES and OST but it did not confer any objective benefit (86).

**Erlotinib.** Erlotinib is a highly potent inhibitor of the EGFR tyrosine kinase with significant but lesser inhibitory activity against Erb-B2 receptor tyrosine kinase 2.

Erlotinib and temozolomide form another tolerable double regimen that has been tested in patients <22 years old with osteogenic sarcoma, rhabdomyosarcoma and STS. However, it was not demonstrated to be effective against recurrent OST and STS (87).

**Gefitinib.** Gefitinib is an EGFR TKI. The results of a phase II study in which gefitinib was used as a monotherapy for patients with advanced HER1-expressing synovial sarcoma, as doxorubicin-containing regimens were ineffective, did not demonstrate sufficient activity in this tumor subtype. These results suggested that HE-1 was not a critical protein in tumor progression in this disease (88).

A phase I trial that combined gefitinib and irinotecan treatment reported no benefit for patients with OST or ES, despite exhibiting activity in other tumor types (89).

**Nintedanib.** Nintedanib is an oral TKI that targets PDGFR- $\alpha/\beta$ , FGFR1/2/3, VEGFR1/2/3 and FLT3. A prospective, multicentric, randomized, open-label phase II trial assessed the efficacy and safety of nintedanib compared with the intravenous cytotoxic compound ifosfamide. Patients had advanced, inoperable and/or metastatic STS following the failure of systemic non-oxazaphosphorine-based first-line chemotherapy. However, the trial was stopped early as nintedanib did not prove to be beneficial as a second-line therapy and resulted in a mPFS of 2.5 months compared with 4.4 months for ifosfamide (20).

**Lenvatinib.** Lenvatinib is a synthetic, orally available inhibitor of VEGFR2 with antineoplastic activity. A single-arm phase Ib/II study reported on the combination of lenvatinib and eribulin in advanced adipocytic sarcoma and leiomyosarcoma. This previous study was designed to investigate the safety and efficacy of this treatment in 20 patients with inoperable or metastatic liposarcoma and leiomyosarcoma. The ORR, determined using RECIST 1.1, was 27% (5/18 patients; 95% CI, 10-53%) and the median PFS and 6-month PFSR were 56 weeks (95% CI, 25 weeks-not reached) and 72%, respectively. Even though no benefit was observed in OS, the combination of lenvatinib and eribulin exhibited promising efficacy in advanced leiomyosarcomas and liposarcomas (90).

#### 4. Discussion

In the present study, a systematic literature review of the available clinical evidence regarding the role of TKIs in the treatment of patients with locally advanced, unresectable or metastatic STS and bone sarcoma, was performed. For this purpose, available scientific reports that were published between 2000 and 2021 were explored. The results identified 45 prospective clinical trials, 13 retrospective studies and five reviews of clinical studies that fit into the aforementioned criteria and the results of these were therefore discussed in the present review.

Advanced, unresectable and/or metastatic sarcomas, both soft tissue and bone, have a relatively poor outcome, with very few systemic therapies demonstrating clinical benefits in terms of PFS and OS prolongation. Current practice for advanced, unresectable, or metastatic STSs includes anthracycline-based chemotherapy regimens as first-line treatment, which present with a median PFS of 4.5 months and a median OS of 12-18 months. It has previously been reported that a combination of doxorubicin and ifosfamide improves the mPFS (7.4 vs. 4.6 months) and ORR (26 vs. 14%) compared with doxorubicin alone. However, toxicity is increased with the combination without being associated with an OS benefit compared with the doxorubicin alone. (91) TKIs are included in the algorithm for the treatment of STSs and bone sarcomas, as demonstrated in the National Comprehensive Cancer Network and European Society for Medical Oncology guidelines (7-10). However, the fact that first-line therapy is still based on anthracyclines, which have become the gold standard over the last 35 years, highlights the necessity for the development of new treatment options for this heterogeneous group of tumors.



Table V. Active trials.

Trial	Study type	Phase	Interventions	Primary outcome measures
NCT03798106	A study of pazopanib and durvalumab for metastatic soft tissue sarcoma	II	Durvalumab + Pazopanib	PFR at 12 weeks
NCT04741438	Efficacy of the combination of nivolumab and ipilimumab as a treatment in patients with sarcoma of rare subtype (RAR-Immune)	III, Randomized	Nivolumab + Ipilimumab OR Pazopanib	PFS up to 36 months
NCT04351308	Comparison of MAPI + camrelizumab vs. API + apatinib vs. MAPI in patients with a poor response to preoperative chemotherapy for newly diagnosed high-grade osteosarcoma (MAPAC)	II, Randomized	MAPI chemotherapy OR Apatinib Mesylate OR Camrelizumab	EFSR
NCT03475953	A phase I/II study of regorafenib plus avelumab in solid tumors (REGOMUNE)	I/II	Regorafenib + Avelumab	Objective response
NCT04803877	SARC038: Phase 2 study of regorafenib and nivolumab in osteosarcoma	II	Regorafenib + Nivolumab	PFSR at 16 weeks

The results of the PALETTE study were the foundations for the approval of pazopanib for STSs, which was the first molecular targeted therapy for STS (14). After the introduction of pazopanib, numerous clinical trials have been performed for other antiangiogenic TKIs (34,35). The majority of TKIs that display clinical activity against sarcomas offer a 6-month PFSR of ~40-50%, which is close to a recent strict limit of 42% that is recommended from the EORTC meta-analysis for leiomyosarcomas (92). These results provide an important rationale to further investigate TKIs in the treatment of sarcomas as a second-line treatment and beyond. Furthermore, the combination of TKIs with immune checkpoint inhibitors has demonstrated promising results in pretreated sarcomas both in STSs and bone tumors (57,58,79). Moreover, an understanding of the molecular mechanisms underlying mesenchymal tumor responses to immunotherapy could potentially support the potential activity of immunotherapy agents in combination with TKIs. However, a 6-month PFSR of >70%, at least for leiomyosarcomas, is very high for the implementation of TKIs in a first-line setting.

Despite improvements in treatment approaches, unresectable and/or metastatic bone and STSs remain a therapeutic challenge, as the median OS of patients with sarcomas is <2 years. Several preclinical studies and investigations of sarcoma genomics and mutations of signaling pathways have indicated potential therapeutic targets. The molecular biology of both STSs and bone sarcomas demonstrates the importance of several signaling pathways for the oncogenesis of these tumors (35). It can therefore be hypothesized that the addition of TKIs that interfere with these cellular signaling pathways may have an important clinical impact. The results of numerous phase II trials support this hypothesis. However, it should be noted that the results of trials testing TKIs, either in monotherapy or in combination with other treatments, have not exhibited unequivocal superiority compared with other treatments. Moreover, the rarity and heterogeneity of sarcomas highlights the relatively low number of randomized studies and phase III trials with TKIs. Therefore trials of this design

should be performed in the future. The active trials using combinations of TKIs are summarized in Table V.

Furthermore, the design of these trials should not only compare the study drug with the placebo but should also compare the study drug with at least one active agent already used in sarcoma treatment. Due to the heterogeneity of sarcomas, these agents can be chosen according to the sarcoma histotype, which would provide more representative data regarding the activity of the tested TKI.

It is important to highlight that TKIs may cause numerous adverse effects. TKI toxicities may systematically affect the gastrointestinal tract, cutaneous system, cardiovascular system and may result in biochemical abnormalities or general symptoms, such as fatigue. When TKIs are given in combination with other agents, the toxicity profile seems to be unchanged; however, clinicians need to specify the causality of each adverse event. The wide use of TKIs in the treatment of numerous types of tumor has ensured that medical oncologists have the necessary experience to cope effectively with the toxicity profile of these drugs, which therefore contributes to good tolerability in patients.

The present review demonstrated that TKIs are an important therapeutic option in the treatment of both STSs and bone sarcomas, especially in second-line settings. Furthermore, the results of recent trials have highlighted the potential beneficial activity of combinations of TKIs with immunotherapy in patients with sarcoma. The molecular and genetic background of sarcomas further supports the implementation of TKIs in their treatment. New clinical trials with histotype specificity, even with a lower number of patients, are needed for this heterogeneous and lethal group of tumors.

## 5. Conclusion

In conclusion, STSs and bone sarcomas are significant neoplasms; however, their rarity and heterogeneity have contributed to a relatively low number of studies. Molecular

targeted therapy development has brought a new era of drug treatments for bone and STSs. Future studies will shed light on the underlying pathophysiology of sarcoma, providing patients and physicians with more treatment options.

### Acknowledgements

Not applicable.

### Funding

This study was funded by HESMO (Hellenic Society of Medical Oncology; grant no. 8036/25-09-2020).

### Availability of data and materials

The datasets used and/or analyzed during the current study are available from the corresponding author on reasonable request.

### Authors' contributions

AK, LEG were the writers of the article. AK and LEG were the two investigators, who performed the literature search and data extraction from all studies examined. Data acquisition was performed by AK, IK, MP, IFN, MA, GK, APa and IC. PE, IK and AK contributed to conception and design of the study. Manuscript editing and the revision were performed by PE and APs. All authors have read and approved the final manuscript. Data sharing is not applicable.

### Ethics approval and consent to participate

Not applicable.

### Patient consent for publication

Not applicable.

### Competing interests

The authors declare that they have no competing interests.

### References

- Burningham Z, Hashibe M, Spector L and Schiffman JD: The epidemiology of sarcoma. *Clin Sarcoma Res* 2: 14, 2012.
- Stiller CA, Trama A, Serraino D, Rossi S, Navarro C, Chirilaque MD and Casali PG; RARECARE Working Group: Descriptive epidemiology of sarcomas in Europe: Report from the RARECARE project. *Eur J Cancer* 49: 684-695, 2013.
- World Health Organization (WHO): *Soft Tissue and Bone Tumours*. In: WHO Classification of Tumours. 5th edition. Vol 3. IARC, Lyon, 2020. <https://publications.iarc.fr/588>.
- Gatta G, Capocaccia R, Botta L, Mallone S, De Angelis R, Ardanaz E, Comber H, Dimitrova N, Leinonen MK, Siesling S, *et al*: Burden and centralized treatment in Europe of rare tumors: Results of RARECAREnet-a population-based study. *Lancet Oncol* 18: 1022-1039, 2017.
- Ottaviani G and Jaffe N: The epidemiology of osteosarcoma. *Cancer Treat Res* 152: 3-13, 2009.
- Valery PC, Laversanne M and Bray F: Bone cancer incidence by morphological subtype: A global assessment. *Cancer Causes Control* 26: 1127-1139, 2015.
- National Comprehensive Cancer Network (NCCN): Bone Cancer (ver. 2.2021). [http://www.nccn.org/professionals/physician\\_gls/pdf/bone.pdf](http://www.nccn.org/professionals/physician_gls/pdf/bone.pdf). Accessed July 26, 2021.
- National Comprehensive Cancer Network (NCCN). Soft Tissue Sarcoma (ver. 2.2021). [https://www.nccn.org/professionals/physician\\_gls/pdf/sarcoma.pdf](https://www.nccn.org/professionals/physician_gls/pdf/sarcoma.pdf). Accessed July 26, 2021.
- Gronchi A, Miah AB, Dei Tos AP, Abecassis N, Bajpai J, Bauer S, Biagini R, Bielack S, Blay JY, Bolle S, *et al*: ESMO Guidelines Committee, EURACAN and GENTURIS: Soft tissue and visceral sarcomas: ESMO-EURACAN-GENTURIS Clinical Practice Guidelines for diagnosis, treatment and follow-up. *Ann Oncol* 32: 1348-1365, 2021.
- Casali PG, Bielack S, Abecassis N, Aro HT, Bauer S, Biagini R, Bonvalot S, Boukovinas I, Bovee JVMG, Brennan B, *et al*: ESMO Guidelines Committee, PaedCan and ERN EURACAN: Bone sarcomas: ESMO-PaedCan-EURACAN Clinical Practice Guidelines for diagnosis, treatment and follow-up. *Oncol* 29 (Suppl 4): iv79-iv95, 2018.
- Rettew AN, Getty PJ and Greenfield EM: Receptor tyrosine kinases in osteosarcoma: Not just the usual suspects. *Adv Exp Med Biol* 804: 47-66, 2014.
- Wu P, Nielsen TE and Clausen MH: FDA-approved small-molecule kinase inhibitors. *Trends Pharmacol Sci* 36: 422-439, 2015.
- Hamberg P, Verweij J and Sleijfer S: (Pre)clinical pharmacology and activity of pazopanib, a novel multikinase angiogenesis inhibitor. *Oncologist* 15: 539-547, 2010.
- Van der Graaf WTA, Blay JY, Chawla SP, Kim DW, Bui-Nguyen B, Casali PG, Schöffski P, Aglietta M, Staddon AP, Beppu Y, *et al*: Pazopanib for metastatic soft-tissue sarcoma (PALETTE): A randomized, double-blind, placebo-controlled phase 3 trial. *Lancet* 379: 1879-1886, 2012.
- Mir O, Brodowicz T, Italiano A, Wallet J, Blay JY, Bertucci F, Chevreau C, Piperno-Neumann S, Bompas E, Salas S, *et al*: Safety and efficacy of regorafenib in patients with advanced soft tissue sarcoma (REGOSARC): A randomized, double-blind, placebo-controlled, phase 2 trial. *Lancet Oncol* 17: 1732-1742, 2016.
- Duffaud F, Mir O, Boudou-Rouquette P, Piperno-Neumann S, Penel N, Bompas E, Delcambre C, Kalbacher E, Italiano A, Collard O, *et al*: Efficacy and safety of regorafenib in adult patients with metastatic osteosarcoma: A noncomparative, randomized, double-blind, placebo-controlled, phase 2 study. *Lancet Oncol* 20: 120-133, 2019.
- Davis LE, Bolejack V, Ryan CW, Ganjoo KN, Loggers ET, Chawla S, Agulnik M, Livingston MB, Reed D, Keedy V, *et al*: Randomized double-blind phase II study of regorafenib in patients with metastatic osteosarcoma. *J Clin Oncol* 37: 1424-1431, 2019.
- Attia S, Bolejack V, Ganjoo KN, George S, Agulnik M, Rushing DA, Loggers ET, Livingston MB, Wright JA, Chawla SP, *et al*: A phase 2 trial of regorafenib (REGO) in patients with advanced Ewing sarcoma and related tumors of soft tissue and bone: SARC0024 trial results. *J Clin Oncol* 35 (Suppl 15): S11005, 2017.
- Judson I, Morden JP, Kilburn L, Leahy M, Benson C, Bhadri V, Campbell-Hewson Q, Cubedo R, Dangoor A, Fox L, *et al*: Cediranib in patients with alveolar softpart sarcoma (CASPS): A double-blind, placebo-controlled, randomized, phase 2 trial. *Lancet Oncol* 20: 1023-1034, 2019.
- Schöffski P, Toulmonde M, Estival A, Marquina G, Dudzisz-Śledź M, Brahmi M, Steeghs N, Karavasilis V, de Haan J, Wozniak A, *et al*: Randomized phase 2 study comparing the efficacy and safety of the oral tyrosine kinase inhibitor nintedanib with single agent ifosfamide in patients with advanced, inoperable, metastatic soft tissue sarcoma after failure of first-line chemotherapy: EORTC-1506-STBSG 'ANITA'. *Eur J Cancer* 152: 26-40, 2021.
- Benson C, Ray-Coquard I, Sleijfer S, Litière S, Blay JY, Le Cesne A, Papai Z, Judson I, Schöffski P, Chawla S, *et al*: Outcome of uterine sarcoma patients treated with pazopanib: A retrospective analysis based on two European organisations for research and treatment of cancer (EORTC) soft tissue and bone sarcoma group (STBSG) clinical trials 62043 and 62072. *Gynecol Oncol* 142: 89-94, 2016.
- Kollár A, Jones RL, Stacchiotti S, Gelderblom H, Guida M, Grignani G, Steeghs N, Safwat A, Katz D, Duffaud F, *et al*: Pazopanib in advanced vascular sarcomas: An EORTC soft tissue and bone sarcoma group (STBSG) retrospective analysis. *Acta Oncol* 56: 88-92, 2017.
- Gelderblom H, Judson IR, Benson C, Merimsky O, Grignani G, Katz D, Freivogel KW, Stein D, Jobanputra M, Mungul A, *et al*: Treatment patterns and clinical outcomes with pazopanib in patients with advanced soft tissue sarcomas in a compassionate use setting: Results of the SPIRE study. *Acta Oncol* 56: 1769-1775, 2017.

24. ElNaggar AC, Hays JL and Chen JL: Addition of everolimus post VEGFR inhibition treatment failure in advanced sarcoma patients who previously benefited from VEGFR inhibition: A case series. *PLoS One* 11: e0156985, 2016.
25. Katz D, Azraq Y, Eleyan F, Gill S, Peretz T and Merimsky O: Pazolimus: Pazopanib plus sirolimus following progression on pazopanib, a retrospective case series analysis. *BMC Cancer* 16: 616, 2016.
26. Dembla V, Groisberg R, Hess K, Fu S, Wheler J, Hong DS, Janku F, Zinner R, Piha-Paul SA, Ravi V, *et al*: Outcomes of patients with sarcoma enrolled in clinical trials of pazopanib combined with histone deacetylase, mTOR, Her2, or MEK inhibitors. *Sci Rep* 7: 15963, 2017.
27. Zhu B, Li J, Xie Q, Diao L, Gai L and Yang W: Efficacy and safety of apatinib monotherapy in advanced bone and soft tissue sarcoma: An observational study. *Cancer Biol Ther* 19: 198-204, 2018.
28. Xie L, Xu J, Sun X, Li X, Liu K, Liang X, Zhou Z, Zhuang H, Sun K, Wu Y, *et al*: Apatinib plus ifosfamide and etoposide for relapsed or refractory osteosarcoma: A retrospective study in two centers. *Oncol Lett* 22: 552, 2021.
29. Xie L, Guo W, Wang Y, Yan T, Ji T and Xu J: Apatinib for advanced sarcoma: Results from multiple institutions' off-label use in China. *BMC Cancer* 18: 396, 2018.
30. Stacchiotti S, Negri T, Libertini M, Palassini E, Marrari A, De Troia B, Gronchi A, Dei Tos AP, Morosi C, Messina A, *et al*: Sunitinib malate in solitary fibrous tumor (SFT). *Ann Oncol* 23: 3171-3179, 2012.
31. Stacchiotti S, Pantaleo MA, Astolfi A, Dagrada GP, Negri T, Dei Tos AP, Indio V, Morosi C, Gronchi A, Colombo C, *et al*: Activity of sunitinib in extraskeletal myxoid chondrosarcoma. *Eur J Cancer* 50: 1657-1664, 2014.
32. Wang HY, Chu JF, Zhang P, Wang JQ, Yan Z, Yao SN, Yao ZH and Liu YY: Safety and efficacy of chemotherapy combined with anlotinib plus anlotinib maintenance in Chinese patients with advanced/metastatic soft tissue sarcoma. *Onco Targets Ther* 13: 1561-1568, 2020.
33. Hindi N, Casali PG, Morosi C, Messina A, Palassini E, Pilotti S, Tamborini E, Radaelli S, Gronchi A and Stacchiotti S: Imatinib in advanced chordoma: A retrospective case series analysis. *Eur J Cancer* 51: 2609-2614, 2015.
34. Smolle MA, Szkandera J, Andreou D, Palmerini E, Bergovec M and Leithner A: Treatment options in unresectable soft tissue and bone sarcoma of the extremities and pelvis-a systematic literature review. *EFORT Open Rev* 5: 799-814, 2020.
35. Constantiniidou A, Pollack S, Loggers E, Rodler E and Jones RL: The evolution of systemic therapy in sarcoma. *Expert Rev Anticancer Ther* 13: 211-223, 2013.
36. Polychronidou G, Karavasilis V, Pollack SM, Huang PH, Lee A and Jones RL: Novel therapeutic approaches in chondrosarcoma. *Future Oncol* 13: 637-648, 2017.
37. Bailey K, Cost C, Davis I, Glade-Bender J, Grohar P, Houghton P, Isakoff M, Stewart E, Laack N, Yustein J, *et al*: Emerging novel agents for patients with advanced Ewing sarcoma: A report from the Children's Oncology Group (COG) New Agents for Ewing Sarcoma Task Force. *F1000Res* 8: F1000 Faculty Rev-493, 2019.
38. Nakano K and Takahash S: current molecular targeted therapies for bone and soft tissue sarcomas. *Int J Mol Sci* 19: 739, 2018.
39. Sleijfer S, Ray-Coquard I, Papai Z, Le Cesne A, Scurr M, Schöffski P, Collin F, Pandite L, Marreaud S, De Brauwier A, *et al*: Pazopanib, a multikinase angiogenesis inhibitor, in patients with relapsed or refractory advanced soft tissue sarcoma: A phase II study from the European organization for research and treatment of cancer-soft tissue and bone sarcoma group (EORTC Study 62043). *J Clin Oncol* 27: 3126-3132, 2009.
40. Li H, Wozniak A, Sciort R, Cornillie J, Wellens J, Van Looy T, Vanleeuw U, Stas M, Hompes D, Debiec-Rychter M and Schöffski P: Pazopanib, a receptor tyrosine kinase inhibitor, suppresses tumor growth through angiogenesis in dedifferentiated liposarcoma xenograft models. *Transl Oncol* 7: 665-671, 2014.
41. Samuel BL, Chawla SP, Somaiah N, Staddon AP, Skubitz KM, Milhem MM, Kaiser PE, Portnoy DC, Priebe DA, Walker MS and Stepanski EJ: Results of a prospective phase 2 study of pazopanib in patients with advanced intermediate-grade or high-grade liposarcoma. *Cancer* 123: 4640-4647, 2017.
42. Chow W, Frankel P, Ruel C, Araujo DM, Milhem M, Okuno S, Hartner L, Undevia S and Staddon A: Results of a prospective phase 2 study of pazopanib in patients with surgically unresectable or metastatic chondrosarcoma. *Cancer* 126: 105-111, 2020.
43. Lipplaa A, Dijkstra S and Gelderblom H: Efficacy of pazopanib and sunitinib in advanced axial chordoma: A single reference centre case series. *Clin Sarcoma Res* 6: 19, 2016.
44. Keir ST, Morton CL, Wu J, Kurmasheva RT, Houghton PJ and Smith MA: Initial testing of the multitargeted kinase inhibitor pazopanib by the pediatric preclinical testing program. *Pediatr Blood Cancer* 59: 586-588, 2012.
45. Umeda K, Kato I, Saida S, Okamoto T and Adachi S: Pazopanib for second recurrence of osteosarcoma in pediatric patients. *Pediatr Int* 59: 937-938, 2017.
46. Hicklin DJ and Ellis LM: Role of the vascular endothelial growth factor pathway in tumor growth and angiogenesis. *J Clin Oncol* 23: 1011-1027, 2005.
47. Liu X, Xu J, Li F, Liao Z, Ren Z, Zhu L, Shi Y, Zhao G, Bai X, Zhao J, *et al*: Efficacy and safety of the VEGFR2 inhibitor Apatinib for metastatic soft tissue sarcoma: Chinese cohort data from NCT03121846. *Biomed Pharmacother* 122: 109587, 2020.
48. Xie L, Xu J, Sun X, Tang X, Yan T, Yang R and Guo W: Apatinib for advanced osteosarcoma after failure of standard multimodal therapy: An open label phase II clinical trial. *Oncologist* 24: e542-e550, 2019.
49. Zheng B, Ren T, Huang Y and Guo W: Apatinib inhibits migration and invasion as well as PD-L1 expression in osteosarcoma by targeting STAT3. *Biochem Biophys Res Commun* 495: 1695-1701, 2018.
50. Li F, Liao Z, Zhang C, Zhao J, Xing R, Teng S, Zhang J, Yang Y and Yang J: Apatinib as targeted therapy for sarcoma. *Oncotarget* 9: 24548-24560, 2018.
51. Xie L, Xu J, Sun X, Guo W, Gu J, Liu K, Zheng B, Ren T, Huang Y, Tang X, *et al*: Apatinib plus camrelizumab (anti-PD1 therapy, SHR-1210) for advanced osteosarcoma (APFAO) progressing after chemotherapy: A single-arm, open-label, phase 2 trial. *J Immunother Cancer* 8: e000798, 2020.
52. Chow LQ and Eckhardt SG: Sunitinib: From rational design to clinical efficacy. *J Clin Oncol* 25: 884-896, 2007.
53. George S, Merriam P, Maki RG, Van den Abbeele AD, Yap JT, Akhurst T, Harmon DC, Bhuchar G, O'Mara MM, D'Adamo DR, *et al*: Multicenter phase II trial of sunitinib in the treatment of nongastrointestinal stromal tumor sarcomas. *J Clin Oncol* 27: 3154-3160, 2009.
54. Mahmood ST, Agresta S, Vigil CE, Zhao X, Han G, D'Amato G, Calitri CE, Dean M, Garrett C, Schell MJ, *et al*: Phase II study of sunitinib malate, a multitargeted tyrosine kinase inhibitor in patients with relapsed or refractory soft tissue sarcomas. Focus on three prevalent histologies: Leiomyosarcoma, liposarcoma and malignant fibrous histiocytoma. *Int J Cancer* 129: 1963-1969, 2011.
55. Jo JC, Hong YS, Kim KP, Lee JL, Lee J, Park YS, Kim SY, Ryu JS, Lee JS and Kim TW: A prospective multicenter phase II study of sunitinib in patients with advanced aggressive fibromatosis. *Invest New Drugs* 32: 369-376, 2014.
56. Jagodzińska-Mucha P, Switaj T, Kozak K, Koseła-Paterczyk H, Klimczak A, Ługowska I, Rogala P, Wągródzki M, Falkowski S and Rutkowski P: Long-term results of therapy with sunitinib in metastatic alveolar soft part sarcoma. *Tumori* 103: 231-235, 2017.
57. Martin-Broto J, Hindi N, Grignani G, Martinez-Trufero J, Redondo A, Valverde C, Stacchiotti S, Lopez-Pousa A, D'Ambrosio L, Gutierrez A, *et al*: Nivolumab and sunitinib combination in advanced soft tissue sarcomas: A multicenter, single-arm, phase Ib/II trial. *J Immunother Cancer* 8: e001561, 2020.
58. Palmerini E, Lopez-Pousa A, Grignani G, Redondo A, Hindi N, Stacchiotti S, Sebío A, Lopez-Martin JA, Morales CMV, Martinez-Trufero J, *et al*: IMMUNOSARC: A collaborative Spanish (GEIS) and Italian (ISG) sarcoma groups phase I/II trial of sunitinib and nivolumab in advanced soft tissue and bone sarcoma: Results from the phase II part, bone sarcoma cohort. *J Clin Oncol* 38 (Suppl 15): S11522, 2020.
59. Mross K, Frost A, Steinbild S, Hedbom S, Büchert M, Fasol U, Unger C, Krätzschar J, Heinig R, Boix O and Christensen O: A phase I dose-escalation study of regorafenib (BAY 73-4506), an inhibitor of oncogenic, angiogenic, and stromal kinases, in patients with advanced solid tumors. *Clin Cancer Res* 18: 2658-2667, 2012.
60. Berry V, Basson L, Bogart E, Mir O, Blay JY, Italiano A, Bertucci F, Chevreau C, Clisant-Delaine S, Liegl-Antzinger B, *et al*: REGOSARC: Regorafenib versus placebo in doxorubicin-refractory soft-tissue sarcoma-A Quality-adjusted time without symptoms of progression or toxicity analysis. *Cancer* 123: 2294-2302, 2017.

61. Marrari A, Bertuzzi A, Bozzarelli S, Gennaro N, Giordano L, Quagliuolo V, De Sanctis R, Sala S, Balzarini L and Santoro A: Activity of regorafenib in advanced pretreated soft tissue sarcoma: Results of a single-center phase II study. *Medicine (Baltimore)* 99: e20719, 2020.
62. Santoro A, Comandone A, Basso U, Soto Parra H, De Sanctis R, Stroppa E, Marcon I, Giordano L, Lutman FR, Boglione A and Bertuzzi A: Phase II prospective study with sorafenib in advanced soft tissue sarcomas after anthracycline-based therapy. *Ann Oncol* 24: 1093-1098, 2013.
63. Valentin T, Fournier C, Penel N, Bompas E, Chaigneau L, Isambert N and Chevreau C: Sorafenib in patients with progressive malignant solitary fibrous tumors: A subgroup analysis from a phase II study of the French Sarcoma Group (GSF/GETO). *Invest New Drugs* 31: 1626-1627, 2013.
64. von Mehren M, Rankin C, Goldblum JR, Demetri GD, Bramwell V, Ryan CW and Borden E: Phase 2 Southwest Oncology Group-directed intergroup trial (S0505) of sorafenib in advanced soft tissue sarcomas. *Cancer* 118: 770-776, 2012.
65. Grignani G, Palmerini E, Dileo P, Asaferi SD, D'Ambrosio L, Pignochino Y, Mercuri M, Picci P, Fagioli F, Casali PG, *et al*: A phase II trial of sorafenib in relapsed and unresectable high-grade osteosarcoma after failure of standard multimodal therapy: An Italian Sarcoma Group study. *Ann Oncol* 23: 508-516, 2012.
66. Grignani G, Palmerini E, Ferraresi V, D'Ambrosio L, Bertulli R, Asaferi SD, Tamburini A, Pignochino Y, Sangiolo D, Marchesi E, *et al*: Sorafenib and everolimus for patients with unresectable high-grade osteosarcoma progressing after standard treatment: A nonrandomized phase 2 clinical trial. *Lancet Oncol* 16: 98-107, 2015.
67. Schöffski P, Blay JY and Ray-Coquard I: Cabozantinib as an emerging treatment for sarcoma. *Curr Opin Oncol* 32: 321-331, 2020.
68. Ikeda S, Kudoh K, Sasaki N, Takano M, Goto T, Sakamoto RK, Kita T, Susumu N, Aoki D, Kouta H and Kikuchi Y: Synergistic effects of cabozantinib to temozolomide and bevacizumab in patients with heavily pretreated relapsed uterine leiomyosarcoma. *J Clin Oncol* 33 (15\_Suppl): S5590, 2015.
69. Italiano A, Mir O, Mathoulin-Pelissier S, Penel N, Piperno-Neumann S, Bompas E, Chevreau C, Duffaud F, Entz-Werlé N, Saada E, *et al*: Cabozantinib in patients with advanced Ewing sarcoma or osteosarcoma (CABONE): A multicenter, single-arm, phase 2 trial. *Lancet Oncol* 21: 446-455, 2020.
70. Morabito A, De Maio E, Di Maio M, Normanno N and Perrone F: Tyrosine kinase inhibitors of vascular endothelial growth factor receptors in clinical trials: Current status and future directions. *Oncologist* 11: 753-764, 2006.
71. Brahmi M, Vanacker H and Dufresne A: Novel therapeutic options for alveolar soft part sarcoma: Antiangiogenic therapy, immunotherapy and beyond. *Curr Opin Oncol* 32: 295-300, 2020.
72. Fox E, Aplenc R, Bagatell R, Chuk MK, Dombi E, Goodspeed W, Goodwin A, Kromplewski M, Jayaprakash N, Marotti M, *et al*: A phase I trial and pharmacokinetic study of cediranib, an orally bioavailable pan-vascular endothelial growth factor receptor inhibitor, in children and adolescents with refractory solid tumors. *J Clin Oncol* 28: 5174-5181, 2010.
73. Cohen JW, Widemann BC, Derdak J, Dombi E, Goodwin A, Dompierre J, Onukwubiri U, Steinberg SM, O'Sullivan Coyne G, Kummar S, *et al*: Cediranib phase-II study in children with metastatic alveolar soft-part sarcoma (ASPS). *Pediatr Blood Cancer* 66: e27987, 2019.
74. Schöffski P, Wozniak A, Stacchiotti S, Rutkowski P, Blay JY, Lindner LH, Strauss SJ, Anthony A, Duffaud F, Richter S, *et al*: Activity and safety of crizotinib in patients with advanced clear-cell sarcoma with MET alterations: European organization for research and treatment of cancer phase II trial 90101 'CREATE'. *Ann Oncol* 28: 3000-3008, 2017.
75. Schöffski P, Wozniak A, Kasper B, Aamdal S, Leahy MG, Rutkowski P, Bauer S, Gelderblom H, Italiano A, Lindner LH, *et al*: Activity and safety of crizotinib in patients with alveolar soft part sarcoma with rearrangement of TFE3: European organization for research and treatment of cancer (EORTC) phase II trial 90101 'CREATE'. *Ann Oncol* 29: 758-765, 2018.
76. Schöffski P, Wozniak A, Leahy MG, Aamdal S, Rutkowski P, Bauer S, Richter S, Grünwald V, Debiec-Rychter M, Sciort R, *et al*: The tyrosine kinase inhibitor crizotinib does not have clinically meaningful activity in heavily pre-treated patients with advanced alveolar rhabdomyosarcoma with FOXO rearrangement: European Organisation for Research and Treatment of Cancer phase 2 trial 90101 'CREATE'. *Eur J Cancer* 94: 156-167, 2018.
77. Schöffski P, Sufliarsky J, Gelderblom H, Blay JY, Strauss SJ, Stacchiotti S, Rutkowski P, Lindner LH, Leahy MG, Italiano A, *et al*: Crizotinib in patients with advanced, inoperable inflammatory myofibroblastic tumours with and without anaplastic lymphoma kinase gene alterations (European Organisation for Research and Treatment of Cancer 90101 CREATE): A multicentre, single-drug, prospective, non-randomised phase 2 trial. *Lancet Respir Med* 6: 431-441, 2018.
78. Geller JI, Fox E, Turpin BK, Goldstein SL, Liu X, Minard CG, Kudgus RA, Reid JM, Berg SL and Weigel BJ: A study of axitinib, a VEGF receptor tyrosine kinase inhibitor, in children and adolescents with recurrent or refractory solid tumors: A children's oncology group phase 1 and pilot consortium trial (ADVL1315). *Cancer* 124: 4548-4555, 2018.
79. Wilky BA, Trucco MM, Subhawong TK, Florou V, Park W, Kwon D, Wieder ED, Kolonias D, Rosenberg AE, Kerr DA, *et al*: Axitinib plus pembrolizumab in patients with advanced sarcomas including alveolar soft-part sarcoma: A single-center, single-arm, phase 2 trial. *Lancet Oncol* 20: 837-848, 2019.
80. Sun Y, Niu W, Du F, Du C, Li S, Wang J, Li L, Wang F, Hao Y, Li C and Chi Y: Safety, Pharmacokinetics, and antitumor properties of anlotinib, an oral multitarget tyrosine kinase inhibitor, in patients with advanced refractory solid tumors. *J Hematol Oncol* 9: 105, 2016.
81. Chi Y, Fang Z, Hong X, Yao Y, Sun P, Wang G, Du F, Sun Y, Wu Q, Qu G, *et al*: Safety and efficacy of anlotinib, a multitargeted angiogenesis inhibitor, in patients with refractory metastatic soft-tissue sarcoma. *Clin Cancer Res* 24: 5233-5238, 2018.
82. Tang L, Wang Y, Zhang J, Yu W, Huang Y and Yao Y: Efficacy and safety of anlotinib in advanced soft tissue sarcoma: Results from one of multi-centers in a phase IIB trial (ALTER0203). *J Clin Oncol* 37 (Suppl 15): e22518, 2019.
83. Pindolia VK and Zarowitz BJ: Imatinib mesylate, the first molecularly targeted gene suppressor. *Pharmacotherapy* 22: 1249-1265, 2002.
84. Chugh R, Wathen JK, Maki RG, Benjamin RS, Patel SR, Meyers PA, Priebe DA, Reinke DK, Thomas DG, Keohan ML, *et al*: Phase II multicenter trial of imatinib in 10 histologic subtypes of sarcoma using a bayesian hierarchical statistical model. *J Clin Oncol* 27: 3148-3153, 2009.
85. Stacchiotti S, Longhi A, Ferraresi V, Grignani G, Comandone A, Stupp R, Bertuzzi A, Tamborini E, Pilotti S, Messina A, *et al*: Phase II study of imatinib in advanced chordoma. *J Clin Oncol* 30: 914-920, 2012.
86. Bond M, Bernstein ML, Pappo A, Schultz KR, Krailo M, Blaney SM and Adamson PC: A phase II study of imatinib mesylate in children with refractory or relapsed solid tumors: A Children's oncology group study. *Pediatr Blood Cancer* 50: 254-258, 2008.
87. Jakacki RI, Hamilton M, Gilbertson RJ, Blaney SM, Tersak J, Krailo MD, Ingle AM, Voss SD, Dancey JE and Adamson PC: Pediatric phase I and pharmacokinetic study of erlotinib followed by the combination of erlotinib and temozolomide: A Children's oncology group phase I consortium study. *J Clin Oncol* 26: 4921-4927, 2008.
88. Ray-Coquard I, Le Cesne A, Whelan JS, Schöffski P, Bui BN, Verweij J, Marreaud S, van Glabbeke M, Hogendoorn P and Blay JY: A phase II study of gefitinib for patients with advanced HER-1 expressing synovial sarcoma refractory to doxorubicin-containing regimens. *Oncologist* 13: 467-473, 2008.
89. Brennan RC, Furman W, Mao S, Wu J, Turner DC, Stewart CF, Santana V and McGregor LM: Phase I dose escalation and pharmacokinetic study of oral gefitinib and irinotecan in children with refractory solid tumors. *Cancer Chemother. Pharmacol* 74: 1191-1198, 2014.
90. Chen TWC, Yu CW, Hong RL, Yen CC, Guo JC, Chen SC, Lee JC, Chen ML, Chang HF, Hsu MC and Kung TF: An Ib/II study of the combination of lenvatinib (L) and eribulin (E) in advanced liposarcoma (LPS) and leiomyosarcoma (LMS) (LEADER). *J Clin Oncol* 38: (15\_Suppl): S11507, 2020.
91. Judson I, Verweij J, Gelderblom H, Hartmann JT, Schöffski P, Blay JY, Kerst JM, Sufliarsky J, Whelan J, Hohenberger P, *et al*: Doxorubicin alone versus intensified doxorubicin plus ifosfamide for first-line treatment of advanced or metastatic soft-tissue sarcoma: A randomized controlled phase 3 trial. *Lancet Oncol* 15: 415-423, 2014.
92. Kantidakis G, Litière S, Neven A, Vinches M, Judson I, Schöffski P, Wardelmann E, Stacchiotti S, D'Ambrosio L, Marréaud S, *et al*: Efficacy thresholds for clinical trials with advanced or metastatic leiomyosarcoma patients: A European organization for research and treatment of cancer soft tissue and bone sarcoma group meta-analysis based on a literature review for soft-tissue sarcomas. *Eur J Cancer* 154: 253-268, 2021.

