

The history and evolution of vestibular schwannoma surgery: a comprehensive review

Nikolai Gajic, BSc^{a,*}, Mohd Afiq Mohd Slim, MBChB^b, Georgios Kontorinis, MD, MSc, FRCS (ORL-HNS)^b

Abstract

Vestibular schwannoma (VS) surgery has had a compelling historical evolution. This article aimed to provide a detailed narrative historical review of the chronological progression and conception of surgical VS management. Acknowledgment of the development, revision, and transformation of VS surgery over the decades facilitate a comprehensive understanding of current clinical practice and the scope for further procedural evolution. Following the commencement of VS surgery in the late 18th century, procedures and management have been perpetually revised and augmented, culminating in drastically improved surgical outcomes. This article draws upon the primary source material to provide augmented acuity into the principal pioneers and landmark cases that define the surgery's trajectory. Moreover, the article includes original interpretive artwork by the first author along with a detailed timeline to facilitate enhanced perspicacity of this unique and salient constituent in surgical history.

Keywords: Vestibular schwannoma surgery, Neurotology, Evolution, Acoustic neuroma surgery, History

Vestibular schwannoma (VS) surgery has an extensive and tortuous history. Its procedural evolution is characterized by innovation, nonfulfillment, and perseverance. Initial descriptions of VS emerged in the latter half of the 18th century, and by the 19th century surgeons began attempting resection of the tumor. Lacking the sterility, visualization, and anesthesia afforded modern operating theaters, these early endeavors were hazardous and highly unpredictable. Because of such technical inadequacy, suitable surgical approaches, currently widely utilized across the world, were condemned and disregarded as implausible by the medical community. The work of Harvey Cushing and Walter Dandy was paramount in reducing the threat to life associated with the surgery. The ensuing conglomeration between otologists and neurosurgeons, alongside the inauguration of novel technological adjuncts, namely, the use of microscopic surgery and intraoperative monitoring, resulted in remarkable augmentation across all measurable parameters of surgical success.

This extensive evolution, cultivated through the application of surgical pioneers, still forms a critical proponent of 21st century VS surgery. Moreover, modern technological advancements,

such as endoscopy, have demonstrated the potential for further procedural evolution. This article intends to gain insight into modern VS practice by acknowledging the people and cases that established its fundamental rudiments, a useful tool to facilitate an informed perspective on the aptitude of ensuing surgical iterations. On this account, the chronology of VS surgical evolution is documented from its humble beginnings, its 20th century escalation, and its current 21st century state (Fig. 1).

Methods

The data for this review were derived through searches of PubMed/MEDLINE and Google Scholar using the search terms “vestibular schwannoma surgery,” “history” and “evolution,” in the English language using all fields. Relevant articles that were not identified through the initial searches were added through a manual search. Moreover, we included extensive primary source materials and original transcripts accessed through the Glasgow University Library.

As this was a review of published literature, no requirement of ethical approval needed to be addressed.

Observations

“A certain hard body attached to the auditory nerve”

In 1777, a Dutch professor of anatomy named Eduard Sandifort (1742–1814) published an autopsy report detailing a patient who, shortly before her death, had developed unilateral deafness^[1]. Sandifort's paper, “De duro quodam corpusculo, nervo auditorio adherente” or “a certain hard body attached to the auditory nerve” would determine the “body” as the undoubted cause of deafness in the patient. The tumor was found to have been connected to the eighth cranial nerve, emerging from the medulla, and extending into the internal acoustic meatus. Unbeknown to Sandifort^[1], he provided the first description of what was almost certainly a VS.

It was not until 50 years later that Sir Charles Bell (1774–1842), a Scottish anatomist, would provide what is now

^aUniversity of Glasgow, Glasgow and ^bDepartment of Otolaryngology, University of Glasgow, Queen Elizabeth University Hospital, Lanarkshire, Glasgow

This manuscript has been peer reviewed.

Sponsorships or competing interests that may be relevant to content are disclosed at the end of this article.

*Corresponding author. Address: 25A Newark Dr, Lanarkshire, Glasgow G414QA. Tel/fax: 01414241772. E-mail address: 2366471g@student.gla.ac.uk (N. Gajic).

Copyright © 2022 The Authors. Published by Wolters Kluwer Health, Inc. on behalf of IJS Publishing Group Ltd. This is an open access article distributed under the terms of the Creative Commons Attribution-Non Commercial-No Derivatives License 4.0 (CCBY-NC-ND), where it is permissible to download and share the work provided it is properly cited. The work cannot be changed in any way or used commercially without permission from the journal.

International Journal of Surgery: Global Health (2022) 5:e74

Received 31 January 2022; Accepted 13 April 2022

Published online 10 May 2022

<http://dx.doi.org/10.1097/GH9.000000000000074>

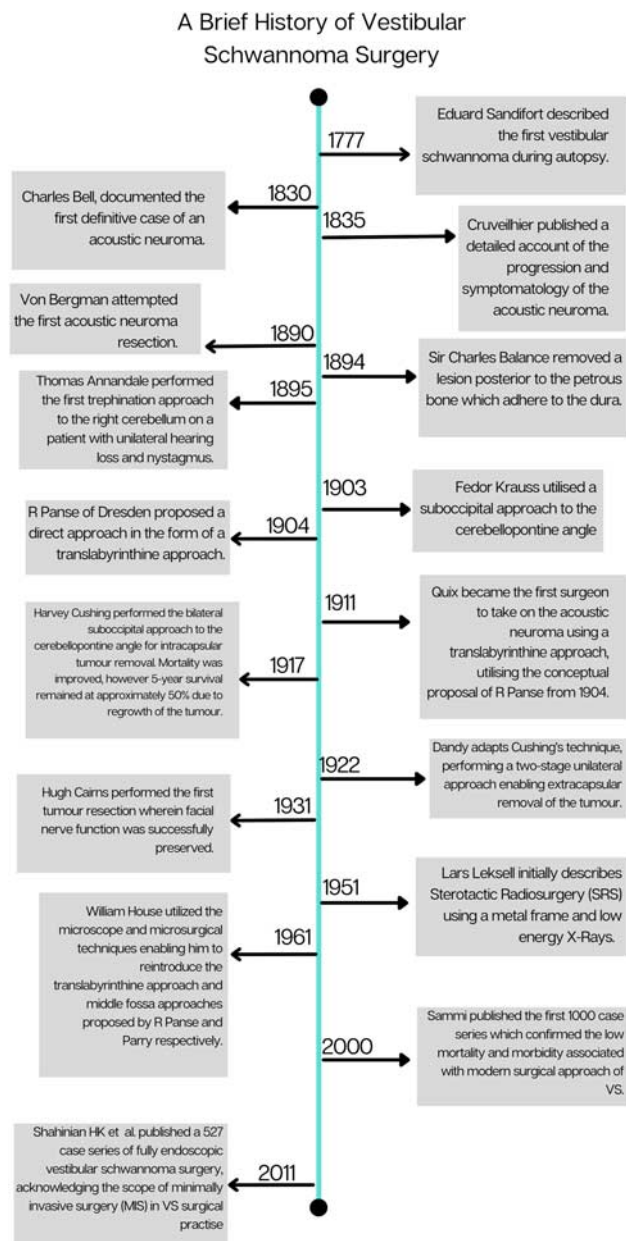


Figure 1. A detailed timeline documenting notable landmarks in vestibular schwannoma surgical evolution^[1–16].

recognized as the first definitive VS case^[2]. Bell described a woman who initially presented with significant loss of trigeminal nerve sensation. Thereafter, the patient developed hearing loss, ataxia, and slurred speech before dying of respiratory failure secondary to brainstem compression. The autopsy revealed a tumor occupying much of the cerebellopontine angle (CPA)^[2]. The observations made of the tumor's pathologic anatomy and the structures upon which it had impinged, were interpreted as a rationale for the patient's progressive clinical deterioration^[2].

Five years later, Jean Cruveilhier (1791–1874), a Parisian professor of anatomy, published a case report documenting the progressive symptomatology of a growing VS^[3,17]. In doing so, Cruveilhier was able to describe the progression of the patient's

clinical features and relate these to the anatomic structures affected by the mass effect of a growing tumor. The case pertained to a 19-year-old female, who initially presented with a history of headache and unilateral hearing loss. Cruveilhier observed the evolution of the patient's morbidity as she developed uncontrolled facial twitching, visual deterioration and eventual muscle rigidity and blindness. The patient died at the age of 26 from what Cruveilhier had diagnosed as “a tumor compressing the brain.” Autopsy findings confirmed Cruveilhier's assumptions, revealing a large posterior fossa tumor compressing the fifth to eleventh cranial nerves, the brainstem and cerebellum^[3].

Initial attempts

In the latter half of the 19th century, it is presumptuous that attempts at surgical VS excision went unreported. In 1890, von Bergman (1836–1907), working at Oppenheim's clinic in Utrecht, published the first documented account of attempted VS excision. Due to extensive bleeding, von Bergman was unable to locate the tumor before his patient died on the table^[18]. This attempt commenced an effervescent period in VS surgery, characterized by a plethora of research, significant surgical advancement, and tragic rates of mortality.

The accolade to whom the first successful VS surgery belongs remains controversial. Literary consensus divides the recognition between 2 neurosurgeons, both British, whose respective procedures were performed just 1 year apart. In 1894, Sir Charles Ballance (1856–1936) used a suboccipital approach to successfully remove a tumor that could, conceivably, have been a VS. The case involved a 49-year-old female presenting with a history of headache, tinnitus, and vertigo^[4]. Here, Ballance^[4] described, “A solid tumor found attached to the dura over inner part of posterior surface of petrous.” The significance of this description, is that attachment to the dura is a finding more typically associated with a meningioma^[19]. It has therefore been skepticized among scholars as to whether what Balance had successfully removed was a VS or a tumor of a different variety. Interestingly, in his sentinel paper of 1917, Harvey Cushing (1869–1939), a character who would color the landscape of VS practise in the 20th century, stated that the case notes written by Balance almost certainly describe a meningeal endothelioma^[5]. Notwithstanding, Ballance's patient would live until 1907; however, not without harboring significant morbidity associated with extensive nerve deficits^[4].

One year after Balance's operation, Thomas Ammandale (1838–1907) successfully excised what, due to its location and symptomatology, was almost certainly a VS^[5,6]. The lack of ambiguity surrounding Ammandale's case is why he is often accredited for the first successful VS surgical excision. This case involved a young, pregnant woman presenting with unilateral hearing loss and nystagmus. Ammandale trephined the skull over the right lobe of the cerebellum and removed a tumor described as being, “the size of a pigeon's egg.” The woman would recover well postoperatively and later that year gave birth to a healthy child^[5]. This was a “brilliant surgical result”; however, Ammandale's success would not accurately forecast the outcomes of VS surgery in the ensuing years^[6].

The early 1900s were fraught with poor patient outcomes. Curiously, many of the techniques used at the time closely resemble procedures applied in current surgical practice; these early attempts simply lacked the technology and anatomical understanding afforded to 21st century surgery. Between 1903

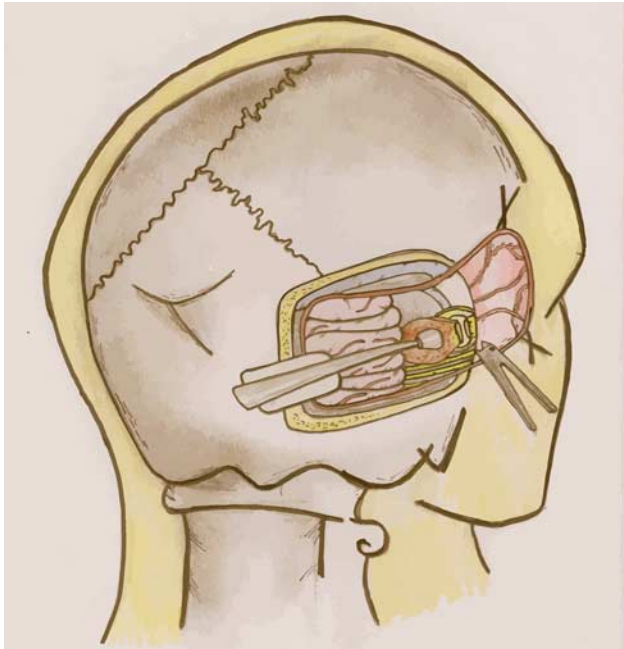


Figure 2. The retrosigmoid suboccipital approach, currently the most widely utilized open surgical approach to the vestibular schwannoma^[21].

and 1905, Woolsey popularized a unilateral suboccipital approach to skull-based surgery, which Fedor Krauss (1857–1937) adapted for use in his suboccipital approach to VS^[7,20]. Krauss’s approach had a remarkable resemblance to the most common open surgical approach used in current clinical practice, the retrosigmoid suboccipital approach (Fig. 2). Despite the evident viability of Krauss’ approach, he reported a mortality rate of 84%, a rate that was congruent with the field of VS surgery during this period^[7].

Inadequate technology and restricted awareness of surgical anatomy, contributed to this lack of success. The use of an index finger to try and dislodge the mass, commonly results in parenchymal injury, and consequently contributed to poor patient outcomes. Moreover, surgeons of the time had an incomplete anatomical appreciation for the course of the anterior inferior cerebellar artery, which meant that bleeding at the CPA was so fast and profuse, the site became known as the “bloody angle”—consequently compromising visualization of the tumor. This culminated in VS being referred to as “the most problematic of all brain tumors” at the International Conference of Medicine in London in 1913, posing a quandary to both neurosurgeons and otologists^[22].

Condemning the translabyrinthine approach

Failure of the suboccipital approach caused surgeons to seek other methods of approaching the tumor. One remarkable proposal was that of Rudolf Panse (1863–1942) in 1904^[8]. Panse practised in Dresden, Germany under the tutelage of Herman Schwartz^[23]. He nominated a procedure that involved chiselling out the mastoid and removing the labyrinth in its entirety (Fig. 3). The procedure was met with devastating criticism by the medical community as Panse proposed the complete destruction of middle

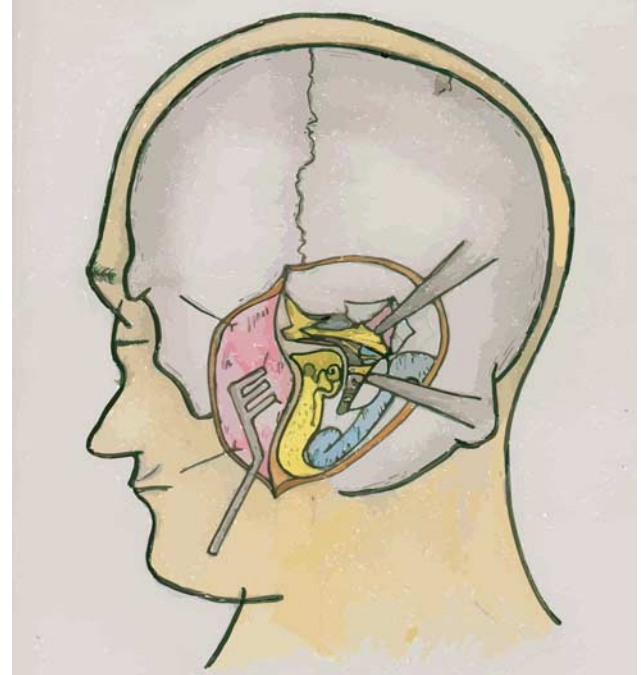


Figure 3. The translabyrinthine approach, initially proposed by Panse in 1904, offers an effective surgical strategy in patients who lack serviceable hearing^[8,24].

ear structures and in exchange offered a limited operating field that forbade the excision of a large tumor.

The procedure was an early rendition of the translabyrinthine approach, a widely used method of VS excision in current clinical practice. Despite the indignation of much of the surgical community toward Panse’s proposal, there were outliers who gave this early translabyrinthine approach consideration. A professor of otolaryngology named Franciscus Quix (1874–1946), was intrigued by the procedure and deemed it entirely plausible^[9]. On 20 May 1911—Quix became the first surgeon to take on the VS using a translabyrinthine approach. However, Quix failed to fully excise the tumor and 6 months after surgery, the patient died after regrowth. This prompted Quix to conclude that this approach was most suitable for removal of small VSs, confined to the internal acoustic meatus^[9].

Further attempts at surgery using a translabyrinthine approach were made by Werner Kümmel and Schmieglow in 1909 and 1912, respectively^[25,26]. In both cases the patient did not survive longer than a month following the procedure. The poor patient outcomes associated with these early attempts, partnered with the overwhelming disapproval of the surgical community meant that the approach was to be temporarily abandoned. The surgery would remain dormant for the next 50 years.

It has now become apparent that the technology of the early 20th century was simply inadequate to support Panse’s proposal and that these early attempts, aided by magnification and microsurgical instrumentation, may have produced entirely different outcomes. Among those in opposition to the translabyrinthine approach, were 2 surgeons who would play an integral role in the evolution of VS surgery in the subsequent decades; Harvey Cushing and Walter Dandy (1886–1946).

Cushing and Dandy

Harvey Cushing is often referred to as a forefather of modern neurosurgery. Cushing was dissatisfied with the early 20th century state of VS surgery, prompting him to apply a concerted effort to improve VS outcomes. Cushing's initial attempts at VS surgery endured comparably poor results to those of his predecessors and contemporaries, with his first patient dying soon after surgery and his second patient harboring significant facial nerve palsy following the procedure^[5].

Despite these initial negative experiences, Cushing persisted with the surgery and began incorporating strategies to overcome the obstacles he encountered. Such amendments included the incorporation of a sterile operating field, the use of procaine to provide adequate anesthesia, and electrocoagulation to ensure cerebral hemostasis. Cushing also pioneered the use of novel instrumentation to aid in surgical techniques.

Cushing opted for a bilateral suboccipital approach and advocated for a subtotal rather than total resection to eliminate the risks associated with tumor capsule dissection. In 1917, the results of Cushing's approach were published in his sentinel paper: "Tumours of the nervus acusticus and syndrome of the cerebellopontine angle"^[5]. Remarkably, Cushing was able to reduce the mortality associated with the procedure to around 20%, a figure that was wholly unattainable to any of his colleagues at the time. However, likely due to failure to remove the entirety of the tumor, there was a 54% mortality rate within 5 years in Cushing's patient cohort^[5].

Walter Dandy was an American neurosurgeon who had trained under Cushing at John Hopkins Hospital. Dandy^[27] himself had pioneered the use of ventriculography, novel technology that provided viable means of detecting hydrocephalus and thus facilitated the operation on small tumors. While at one time colleagues, it has been well established that Dandy and Cushing had a longstanding disrepute. This likely influenced Cushing's convictions toward the use of ventriculography, foreseeing that it would have no impression on the advancement of VS surgery^[28]. Moreover, it is conceivable that this disagreement could have incited Dandy's desire to improve and augment the work of his former teacher, as he observed the 5-year survival among Cushing's patients to be unacceptable.

Dandy's initial attempts at VS surgery were fraught with impediments, similar to those experienced by his former tutor. Not 1 of Dandy's first 4 VS patients survived longer than 48 hours postoperatively, however, it was Dandy's fifth attempt that enlightened him to a concept that radically changed his approach^[29]. The patient was a 60-year-old man, soon after having undergone subtotal intracapsular removal, who began experiencing symptoms of drowsiness, vomiting, and dysphagia. Dandy was certain that these symptoms were the result of tumor remnants compressing the brainstem. He therefore elected to re-operate and was able to remove the remaining piece of the tumor that he had correctly predicted to have been the source of the patient's symptomatology^[30]. The patient recovered within 5 days and was discharged shortly afterwards. This case prompted Dandy to conclude that improvement in 5-year survival was reliant upon total VS resection.

The next 2 patients upon whom Dandy would perform VS surgery, would be operated on using a 2-stage procedure. The first stage involved intracapsular debulking of the tumor, and the second stage involved capsule excision. The success of these cases

prompted Dandy to progress the surgery to a single operative procedure. After 4 years, Dandy operated on 30 patients, achieving a mortality rate of ~30%, which was higher than that of Cushing. However, by removing the entirety of the tumor, Dandy^[10] was able to reduce the 5-year mortality associated with the tumor from 54% to 40%. Dandy also advocated for a unilateral approach as opposed to Cushing's bilateral, which would eventually be proven to be the most appropriate method^[31].

The surgical microscope, nerve monitoring, and otology

In 1931, Hugh Cairns (1896–1952), an Oxford University professor, achieved the first successful VS resection with facial nerve preservation. Immediately following the procedure, Cairns thought it highly unlikely that facial nerve preservation would be achieved as he believed the operation had compromised the nerve's blood supply, making regeneration impossible. However, after waking from surgery his patient showed glimpses of facial nerve function and over the next months regained a significant degree of CNVII capacity^[11].

The affirmation that facial nerve preservation was possible led surgeons to view this as the next obstacle in tackling the tumor. The introduction of microscopy and nerve monitoring, alongside the development of modern diagnostic modalities, would prove to be essential constituents in salvaging nerve function and improving VS patients' postoperative quality of life. Moreover, otologists were able to apply auditory and vestibular testing to patients with inner ear symptoms, aiding in earlier VS diagnosis.

The first surgeon to use the microscope for VS surgery was Theodore Kurze (1922–2002) in 1957^[32]. Kurze was inspired by an American otolaryngologist, William House (1923–2012), who had created a film depicting the use of the surgical microscope^[32,33]. Kurze employed the technique to successfully remove the schwannoma following careful creation of a suboccipital corridor, guided by a surgical microscope. However, Kurze et al^[34] had trouble maintaining the sterility of drapes for his microscope, an issue that would later be resolved through the application of ethylene oxide gas.

The latter half of the 20th century was greatly influenced by the aforementioned William House, who was a catalyst for the integration of the microscope, microsurgical technique, and drill into VS surgery. House and House's first innovative contribution was to revive the middle fossa approach, initially proposed by Parry in 1904^[12,35]. The technique involved using a supratentorial approach to detach the facial nerve from the tumor and a subtemporal approach to remove the tumor from the posterior fossa (Fig. 4). The approach was used in 8 cases, of which facial nerve preservation was achieved in 4. House would later conclude that the middle fossa approach provided an efficacious method for removing small VS in patients with serviceable hearing^[13]. However, still dissatisfied by outcomes of facial nerve preservation, House revisited the translabyrinthine approach proposed by Panse. The use of surgical microscopy meant that House was able to avoid destruction of key anatomic structures as well to afford himself far superior visualization. House would later published a case series detailing 200 translabyrinthine VS surgeries; the mortality rate among this cohort was 7% with facial nerve preservation at 72%^[37]. The success of House's procedures encouraged the adoption of the surgical microscope and microscopic instrumentation across VS surgery.

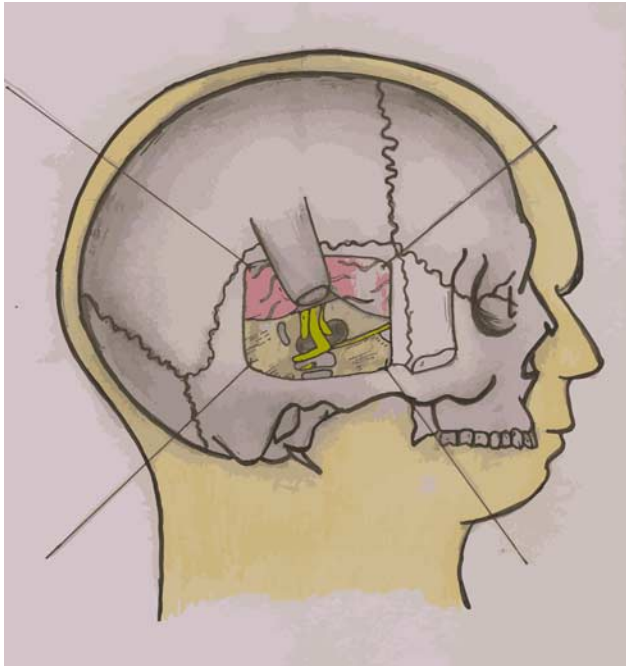


Figure 4. The middle cranial fossa approach, initially proposed by Parry in 1904, effective for removal of small vestibular schwannoma in patients with serviceable hearing^[35,36].

As well as adequate visualization of anatomic structures, preserving nerve function obligated the need to monitor the nerve intraoperatively. The first reported attempt to monitor facial nerve function during posterior cranial fossa surgery, predates the 20th century, to 1898 wherein Krause et al^[7], “irritated the CNVII nerve trunk using the weakest possible current to initiate contraction of the right facial region,” the patient emerged from surgery harboring almost no facial paresis. Similar methods of intraoperative nerve function were conjectured around this period, with one anomalous was proposal made by Hummay and Tommits, recommending that removal of the VS under local anesthetic to provide more robust means of assessing the functionality of the facial nerve intraoperatively^[38,39]. However, this preliminary application of facial nerve monitoring could at times be imprecise and provide surgeons a false sense of security, prompting Dr Jack Kartush to conclude at the American Society of Neurophysiological monitoring in 1986 that “no monitoring is better than poor monitoring”^[40]. Use of visual facial contractions were the sole means by which surgeons could capture intraoperative facial nerve function until 1979, when Delgado et al^[41], working at Temple University Hospital, Philadelphia, introduced facial electromyography (EMG). EMG provided a more astute insight into nerve function through detection and amplification of minute electrical impulses released upon contraction of muscle fibers. By the early 1990s use of EMG was employed routinely to monitor facial nerve function intraoperatively and has been utilized with good effect to reduce the incidence of facial nerve damage during VS surgery^[42].

To examine the functionality of the cochlear nerve, more sophisticated technology was statutory; therefore, no documented attempts were made at intraoperative cochlear nerve monitoring until the late 20th century. Auditory brain response

(ABR) technology was initially introduced by Jewell and Williston^[43] in 1971 and is a prerequisite for intraoperative cochlear nerve monitoring. To facilitate ABR and cochlear nerve action potential monitoring, the cochlear nerve is stimulated at or near the cochlea through sound introduced through earphones or direct electrical stimulation of the nerve, allowing detection of auditory brainstem responses^[44]. This further enhances the scope of mitigation against postoperative morbidity, providing viable means of salvaging hearing function.

These advances, concurrent with improved diagnostic faculty, meant that VS surgery experienced a compelling transition from a crude surgery wherein limiting mortality was a mark of success, to procedures in which surgeons could apply state-of-the-art technological adjuncts to salvage cranial nerve function and optimize for patient quality of life. By the end of the 20th century surgical microscopy, intraoperative monitoring and modern diagnostic modalities made VS surgery unrecognizable to its early 20th century rendition. This evolution was exemplified by a case series published by Sammi and Matthies^[14] in 1997, wherein Sammi achieved 1.1% mortality rate while successfully preserving facial nerve function in 93% of his 1000 cases.

21st century VS surgery

Recent decades have observed curtailment in the use of microsurgical strategies as an initial course of action in VS cases^[45]. While tumor incidence has remained relatively constant, improvements in diagnostic technology have meant that the average tumor size at the point of diagnosis is significantly smaller. Identifying tumors at earlier stages has sanctioned the consideration of less invasive, risk-harboring forms of management, typically through conservative and radiosurgical approaches.

The emergence of MRI technology in the 70s gave rise to the conservative, “watch and wait” approach as it pertained to the VS^[46]. Initially adopted as a course of management in Denmark, Gentofte University Hospital, the protocol has now acquired a substantiated evidence base for small tumors with good prognostic features^[47,48]. Such features have been identified as: small tumor size at time of diagnosis, no extra canalicular location, no hearing loss at clinical presentation, and no evidence of inflammation and angiogenesis^[48,49]. Moreover, within this patient cohort evidence suggests that conservative management poses no increased risk to mortality despite tumor progression and consequent mass effect.

Another reason for the diminished recruitment of microsurgical strategies is the progressive establishment of stereotactic radiosurgery (SRS). SRS was initially described by Lars Leksell (1907–1986) in 1951, using a metal fixation frame cooperatively with orthovoltage x-rays^[49,50]. Low-energy x-rays have now been replaced by high-energy gamma rays, and our capacity to precisely align the beam of radiation toward the isocenter of the tumor has significantly improved. This practice offers clinicians and patients a viable noninvasive alternative to open surgery, particularly for those harboring tumors of smaller dimensions. SRS has been shown to be highly efficacious, sometimes more so than microsurgery, in tumors <3 cm in diameter and below 10 cm³ volume^[51,52]. This can vary depending on local practice and the available radiotherapy facilities, or where tumor volume is <15 cm³^[52]. SRS is not considered optimal for large VSs, as these tumors necessitate surgical decompression to relieve symptomatic burden, as well as having higher rates of re-emergence following

Table 1
The advantages, disadvantages, and suitable clinical indications for each of the 3 main surgical approaches^[21,24,36]

Surgical Approach	Advantages	Disadvantages	Suitable Clinical Indication
Retrosigmoid suboccipital	Approach is flexible to tumors at extremes of size. Provides a wide panoramic view of the surgical field. Allows hearing preservation	Requires cerebellar retraction, provides more limited access to distal IAC structures thereby increasing the risk of subtotal rather than total resection	Patients with serviceable hearing, tumor size can be variable
Translabyrinthine	Minimal brain retraction is required to access the IAC thereby minimizing the risk of parenchymal injury	Destruction of the inner ear structures mean complete hearing loss is unavoidable. The approach does not provide the same panoramic visual field afforded by the RS approach	Patients with large tumors who already lack hearing or their hearing is extremely poor
Middle fossa	Provides the opportunity to preserve hearing in intracanalicular tumors and/or tumors that minimally extend toward the CPA	Requires temporal lobe retraction, risking parenchymal injury. Provides limited access to the cerebellopontine angle	Patients with small intracanalicular tumors and serviceable hearing

CAP indicates cerebellopontine angle; IAC, internal acoustic canal.

SRS. Moreover, the gamma ray dosage requirement of large tumors puts the surrounding trigeminal, facial, and cochlear nerve structures at risk from dose-related toxicity.

While the 21st century has prompted the rise in popularity of alternative management strategies, open microsurgery remains the mainstay of treatment for the VS. A myriad of different open surgical approaches has been outlined in current literature, namely, the retrosigmoidal, translabyrinthine, middle fossa, transotic, endoscopic and extended middle fossa^[53]. The 3 principal approaches, most widely across the world today, are renditions of the surgical procedures cultivated and pioneered by central historical figures amidst the landscape of VS surgery. The first and most used is the retrosigmoid suboccipital, initially described by Krause, before being refined by Cushing and Dandy. The second, the translabyrinthine, initially described by Rudolf Panse, and revisited and augmented by William House. The third is the middle fossa approach, initially described by RH Parry and revisited and augmented by William House. Each approach presents its own set of unique advantages and disadvantages, making the procedures the most appropriate for different clinical scenarios.

The retrosigmoid approach provides a panoramic view of the CPA, making it favorable for tumors with a large CPA component, and is also the most versatile approach to ensure facial nerve preservation. The risk of parenchymal injury following retraction of the cerebellum is one of the main limitations associated with the procedure^[21]. The translabyrinthine approach is only suitable for patients who already have a complete or extremely poor hearing as the procedure involves the complete destruction of the inner ear. For this patient cohort, the approach offers access to the internal acoustic canal (IAC) without the need for significant brain retraction^[24]. The middle fossa approach offers an efficacious approach for small tumors located in the lateral IAC in patients with serviceable hearing. The requirement of temporal lobe retraction poses the risk of parenchymal damage and therefore risks functional complications such as seizures, stroke, or aphasia^[36] (Table 1).

While we have expanded the scope of our management options, the work carried out in the late 1800s and throughout the 20th century, is very much imprinted on current clinical principles.

Minimally invasive?

In 1985, Eric Mühe (1938–2005) performed the first minimally invasive surgery (MIS) in the form of a laparoscopic

cholecystectomy^[54]. Since then, the utility of MIS has exponentially expanded and caused dramatic alterations to the broad surgical landscape. Moreover, MIS has replaced traditional open surgery alternatives in many cases.

Within the field of VS surgery, endoscopic MIS has demonstrated potential as a viable management option. The application of endoscopy enables the surgeon to visualize the entire IAC and clearly illuminates important anatomic structures. In 2011, Shahinian and Ra^[16] published a review evaluating the success of 527 fully endoscopic VS resections. The study found that total resection of the tumor was achieved in 94% of cases, with facial nerve function being preserved in 57% of cases, with a mean VS size of 2.8 cm^[16]. The advantages of endoscopic surgery over classical microscopic surgery are the requirement of a smaller incision, better visualization of anatomic structures and a reduced need to maneuver neurovascular structures around the skull base.

However, the success of endoscopic VS surgery is highly dependent on the surgeon's ability to intricately maneuver around narrow corridors. Because of the delicate nature of skull-based structures, small technical errors can result in profound complications^[55]. Minimally invasive endoscopic surgery may indicate ensuing prospects, but perhaps not its exclusive incarnation. Endoscopic-assisted microsurgery offers a composite of endoscopic and classical microsurgery. This amalgamation provides improved visualization afforded to endoscopic procedures without the technical demands of the exclusive endoscopic variant^[56].

Future directions

While the rising popularity of the “watch and wait” policy alongside stereotactic radiotherapy has resulted in alterations to the indications for classic microsurgery, surgical strategies remain the mainstay in VS management. However, there is a need for more definite guidance to support clinical decision making. Much of the current literature aiding in management election is retrospective in nature, and as such, there is a necessity for multicenter prospective studies to formulate a more standardized management stratagem^[57]. The acquisition of such an evidence base will maximize both the safety and efficacy of our current assortment of management strategies.

There have been significant strides made in our understanding of the histologic and pathologic characteristics of VS, offering potential translatability into clinical therapeutics. Agnihotri et al^[58], identified genetic variants in the PI3K/AKT/mTOR

signalling pathway as a potential therapeutic target. The pathway appears to offer the most promising pharmaceutical strategy^[59]. There is as yet no clinical evidence to support this line of theorem; however, preclinical evidence investigating OSU-03012 (AR-12); a phosphoinositide-dependent kinase-1 (PDK1) inhibitor, demonstrated a dose-dependent reduction of AKT phosphorylation in VS cells and instigated consequential regression in VS cell growth as well as successful induction of apoptosis in vivo^[59]. Despite still being in its infancy, targeted medicinal therapy for VS provides the possibility of a novel management option that could be used in isolation or synergistically alongside surgery.

The utility of endoscopy in VS surgery remains opaque. There is evidence to suggest that capable surgeons can utilize intraoperative endoscopic guidance successfully to aid in facial and auditory preservation alongside reducing the risk of cerebrospinal fluid leak^[56]. However, where this technology should be optimally placed and the definite tools that should be adopted, utilizing a rigid and/or flexible endoscope, requires further clinical investigation.

Conclusion

Since the initial attempts at VS surgery in the late 19th century, removal of the VS has evolved from being an experimental procedure, harboring a significant threat to life, into the vicinity of routine practice, conveying low mortality risk and high rates of hearing and facial nerve preservation.

The core surgical approaches currently used in surgical VS management have fundamental rudiments spanning from their initial conception in the early to mid-20th century. These core practices have been augmented by modern technological advancements, a trend that is likely to persist.

Through the incorporation of modern technological advancements to augment classic surgical convictions, surgeons worldwide can achieve predominantly positive patient outcomes using open microscopic surgery. However, there is a necessity for a more robust evidence base to direct definite management decisions. The implementation of more stringent management algorithms alongside the application of novel surgical and medicinal technological advancements is sure to perpetuate the admirable progress made in the field of VS management over the past centuries.

Ethical approval

As this was a review of published literature, no requirement of ethical approval needed to be addressed.

Sources of funding

None.

Author contribution

N.G. and M.A.M.S.: participated in research design, writing of the paper, and contributed to data procurement. N.G.: participated in the performance of the research. G.K.: participated in research design, writing of the paper, and contributed to data procurement, supervisor of project.

Conflicts of interest disclosure

The authors declare that they have no financial conflict of interest with regard to the content of this report

Research registration unique identifying number (UIN)

None.

Guarantor

G.K.: Consultant ENT & Skull Base Surgeon, Honorary Clinical Associate Professor Department of Otolaryngology, Queen Elizabeth University Hospital University of Glasgow.

Acknowledgments

The authors thank the University of Glasgow and the staff at the Department of Otolaryngology, Queen Elizabeth University Hospital for their support throughout this project.

References

- [1] Sandifort E. *Observationes Anatomico-Pathologicae*. Lyon: Academie Batavae Curatoribus; 1777.
- [2] Bell C. *The Nervous System of the Human Body; Embracing the Papers Delivered to the Royal Society on the Subject of the Nerves*. Washington, DC: Duff Green; 1833.
- [3] Cruveilhier J. *L'Anatomie Pathologique du Corps Humain; Descriptions Avec Figures Lithographiées et Coloriées: Diverses Alterations Morbides Dont le Corps Humain est Susceptible*. Paris: Paris Bailliere; 1829.
- [4] Ballance C. *Some Points in the Surgery of the Brain and its Membranes*. London: McMillan and Co; 1907:276–82.
- [5] Cushing H. *Tumors of the Nervus Acusticus and the Syndrome of the Cerebellopontile Angle*. Philadelphia, PA and London: W. B. Saunders Co; 1917.
- [6] Ramsden RT. "A brilliant surgical result, the first recorded": Annandale's case, 3 May 1895. *J Laryngol Otol* 1995;109:369–73.
- [7] Krause F, Haubold A, Thorek M. *Surgery of the Brain and Spinal Cord, Based on Personal Experiences*. New York, NY: Trans Rebman; 1912.
- [8] Panse R. Klinische und pathologische Mitteilungen IV. Ein Gliom des Akustikus [Clinical and pathological observations IV. A tumour of the acoustic nerve]. *Arch Ohrenheilkd* 1904;61:251Y5.
- [9] Quix F. Ein Fall von translabyrinthinisch operiertem Tumor acusticus [A case of a translabyrinthine acoustic tumour removal]. *Verh dt Otol Ges* 1912;21:245–55.
- [10] Dandy WE. Results of removal of acoustic tumors by the uni-lateral approach. *Arch Surg* 1941;42:1026–33.
- [11] Cairns H. Acoustic neurinoma of right cerebello-pontine angle. Complete removal. Spontaneous recovery from post-operative facial palsy. *J R Soc Med* 1931;25:35–40.
- [12] House HP, House WF. Transtemporal bone microsurgical removal of acoustic neuromas. *Arch Otolaryngol* 1964;80:601–4.
- [13] House WF, Shelton C. Middle fossa approach for acoustic tumor removal. *Neurosurg Clin N Am* 1992;19:279–88.
- [14] Samii M, Matthies C. Management of 1000 vestibular schwannomas (acoustic neuromas): surgical management and results with an emphasis on complications and how to avoid them. *Neurosurgery* 1997;40:11–21.
- [15] Leksell L. The stereotaxic method and radiosurgery of the brain. *Acta Chir Scand* 1951;102:316.
- [16] Shahinian HK, Ra Y. 527 fully endoscopic resections of vestibular schwannomas. *Minim Invasive Neurosurg* 2011;54:61–7.
- [17] Pearce JM. Cruveilhier and acoustic neuroma. *J Neurol Neurosurg Psychiatry* 2003;74:1015.
- [18] Bergmann. quoted by Cushing. *Tumors of the Nervus Acusticus and the Syndrome of the Cerebellopontile Angle*. Philadelphia, PA and London: W. B. Saunders Co; 1917.

- [19] Lyndon D, Lansley JA, Evanson J, *et al.* Dural masses: meningiomas and their mimics. *Insights Imaging* 2019;10:11.
- [20] Krause F. Zur Freilegung der hinteren Felsenbeinfl228; che und des Kleinhirns [To expose the posterior petrous bone and cerebellum]. *Beitr Klein Chir* 1903;2:728–64.
- [21] Eser Ocak P, Dogan I, Sayyahmelli S, *et al.* Vestibular Schwannoma Surgery. Cham: Springer; 2019.
- [22] Costea C, Turluc D, Sava A, *et al.* Fedor Krause (1857-1937): the father of German neurosurgery, the father of the German people. *Romanian Neurosurg* 2016;2:241–47.
- [23] Zange J. Rudolf Panse zum Gedächtnis [To Commemorate Rudolf Panse]. *Eur Arch Otorhinolaryngol (Hist Arch)* 1943;152:102Y4.
- [24] Nickele CM, Akture E, Gubbels SP, *et al.* A stepwise illustration of the translabyrinthine approach to a large cystic vestibular schwannoma. *Neurosurg Focus* 2012;33:E11.
- [25] Kummel W. Otologische Gesichtspunkte bei der Diagnose und Therapie von Erkrankungen der hinteren Sch-idelgrube [Otolological Aspects in Diagnosis and Therapy of Diseases of the Posterior Fossa]. *Dtsch Z Nervenheilk* 1909;36:132–42.
- [26] Schmiegelow E. Beitrag zur translabyrinthären Entfernung der Akustikustumoren [The contribution of the translabyrinthine approach to the removal of acoustic tumours]. *Z Ohrenheilkd* 1915;73:1Y21.
- [27] Dandy WE. Ventriculography following the injection of air into the central ventricles. *Ann Surg* 1918;68:5–11.
- [28] Cushing H to Dandy WE: Letter, May 12, 1922, Yale Manuscript Archives. Available at: <http://hdl.handle.net/10079/fa/mssa.ms.0160>.
- [29] Dandy WE. An operation for the total extirpation of tumors in the cerebello-pontine angle. A preliminary report. *Bull JohnsHopkins Hosp* 1922;33:344–5.
- [30] Dandy WE. An operation for the total removal of cerebellopon-tine (acoustic) tumors. *Surg Gynecol Obstet* 1925;41:129–48.
- [31] Brown NJ, Shahrestani S, Tafreshi AR, *et al.* Staged cranial surgery for intracranial lesions: historical perspective. *World Neurosurg* 2020;144: 28–33.
- [32] Kurze T, Doyle JB. Extradural intracranial (middle fossa) approach to the internal auditory canal. *J Neuro surg* 1962;19:1033–7.
- [33] Uluç K, Kujoth GC, Başkaya MK. Operating microscopes: past, present, and future. *Neurosurg Focus* 2009;27:E4.
- [34] Kurze T, Apuzzo ML, Weiss MH, *et al.* Experiences with sterilization of the operating microscope. *J Neurosurg* 1977;47:861–3.
- [35] Parry RH. A case of tinnitus and vertigo treated by division of the auditory nerve. *J Laryngotolog* 1904;19:402–6.
- [36] Jean WC, Mueller K, Kim HJ. Middle fossa approach for resection of an intracanalicular vestibular schwannoma. *J Neurol Surg B Skull Base* 2019;80(suppl 3):S287.
- [37] House WF. *Translabyrinthine Approach*. Baltimore: University Park Press; 1979:43Y87.
- [38] Albin MS, Babinski M, Maroon JC. Anesthetic management of posterior fossa surgery in the sitting position. *Acta Anaesthesiol Scand* 1976;20:117–28.
- [39] Hullay J, Tomits GH. Experiences with total removal of tumors of the acoustic nerve. *J Neurosurg* 1965;22:127–35.
- [40] Kircher ML, Kartush JM. Pitfalls in intraoperative nerve monitoring during vestibular schwannoma surgery. *Neurosurg Focus FOC* 2012;33:E5.
- [41] Delgado TE, Buchheit WA, Rosenholtz HR. Intraoperative monitoring of facial muscle evoked responses obtained by intracranial stimulation of the facial nerve: a more accurate technique for facial nerve dissection. *Neurosurgery* 1979;4:418–21.
- [42] Yingling CD, Gardi JN. Intraoperative monitoring of facial and cochlear nerves during acoustic neuroma surgery. *Neurosurg Clin N Am* 1992;19: 289–315.
- [43] Jewett DL, Williston JS. Auditory evoked far fields averaged from the scalp of humans. *Brain* 1971;94:681–96.
- [44] Kasbekar AV, Tam YC, Carlyon RP. Intraoperative monitoring of the cochlear nerve during neurofibromatosis type-2 vestibular schwannoma surgery and description of a “test intracochlear electrode”. *J Neurol Surg Rep* 2019;80:e1–9.
- [45] Torres Maldonado S, Naples JG, Fathy R. Recent trends in vestibular schwannoma management: an 11-year analysis of the National Cancer Database. *Otolaryngol Head Neck Surg* 2019;161:137–43.
- [46] Zou J, Hirvonen T. “Wait and scan” management of patients with vestibular schwannoma and the relevance of non-contrast MRI in the follow-up. *J Otol* 2017;12:174–84.
- [47] Stangerup SE, Caye-Thomasen P, Tos M. The natural history of vestibular schwannoma. *Otol Neurotol* 2006;27:547–452.
- [48] Nguyen D, de Kantow L. Vestibular schwannomas: a review. *Appl Radiol* 2019;48:22–7.
- [49] Lewis D, Roncaroli F, Agushi E. Inflammation and vascular permeability correlate with growth in sporadic vestibular schwannoma. *Neuro Oncol* 2019;21:314–25.
- [50] Leksell L. A note on the treatment of acoustic tumours. *Acta Chir Scand* 1971;137:763–65.
- [51] Tsao MN, Sahgal A, Xu W. Stereotactic radiosurgery for vestibular schwannoma: International Stereotactic Radiosurgery Society (ISRS) Practice Guideline. *J Radiosurg SBRT* 2017;5:5–24.
- [52] Huang C, Tu H, Chuang C, *et al.* Gamma knife radiosurgery for large vestibular schwannomas greater than 3 cm in diameter. *J Neurosurg* 2018;128:1380–7.
- [53] Sweeney AD, Carlson ML, Ehtesham M. Surgical approaches for vestibular schwannoma. *Curr Otorhinolaryngol Rep* 2014;80:256–64.
- [54] Mühe E. Long-term follow-up after laparoscopic cholecystectomy. *Endoscopy* 1992;24:754–8.
- [55] Setty P, D’Andrea KP, Stucken EZ, *et al.* Endoscopic resection of vestibular schwannomas. *J Neurol Surg B Skull Base* 2015;76:230–8.
- [56] Kumon Y, Kohno S, Ohue S, *et al.* Usefulness of endoscope-assisted microsurgery for removal of vestibular schwannomas. *J Neurol Surg B Skull Base* 2012;73:42–7.
- [57] Merlin T, Weston A, Tooher R. Extending an evidence hierarchy to include topics other than treatment: revising the Australian “levels of evidence”. *BMC Med Res Methodol* 2009;9:34.
- [58] Agnihotri S, Gugel I, Remke M, *et al.* Gene-expression profiling elucidates molecular signaling networks that can be therapeutically targeted in vestibular schwannoma. *J Neurosurg* 2014;121:1434–45.
- [59] Lee TX, Packer MD, Huang J, *et al.* Growth inhibitory and anti-tumour activities of OSU-03012, a novel PDK-1 inhibitor, on vestibular schwannoma and malignant schwannoma cells. *Eur J Cancer* 2009;45: 1709–20.