

Orbital floor reconstruction with high density polyethylene

Reconstrução de assoalho orbital com polietileno de alta densidade

Daniel Humberto Pozza¹, Diego Segatto Blaya², Marcos André Matos de Oliveira³, Nelson Ribeiro Neto⁴, Marília Gerhardt de Oliveira⁵

¹Doctor of Laser - Universidade Federal da Bahia/Universidade Federal de Paraíba; Specialist in Oral and Maxillofacial Surgery (OMS) - Centro Baiano de Estudos Odontológicos, Salvador, BA; ²Master in OMS - Pontifícia Universidade Católica do Rio Grande do Sul; Specialist in OMS - PUCRS; ³Doctor of Immunology - UFBA; ⁴Doctor of Laser - UFBA/UFPB; Specialist in OMS - Universidade Federal do Ceará; Specialist in Implantodontology - Escola de Aperfeiçoamento Profissional - Associação Brasileira de Odontologia/BA; ⁵PhD Associate Professor Post-graduate Program in OMS - School of Dentistry – PUCRS; CNPq fellow

Abstract

Surgical interventions in blow out fractures are generally indicated in cases of alterations in orbital function (e.g. diplopia) and for aesthetic reasons (e.g. enophthalmos). In assessing the severity of the injury, the clinician often uses parameters such as changes in visual acuity, patient-reported diplopia, changes in globe position and evaluation of the extraocular muscles in association with imaging exams. Computed tomography has been the modality of choice for detailed imaging diagnosis and surgical planning of orbital trauma. High density polyethylene may be successfully used in orbital floor reconstruction to restore function and esthetics. Taking into account the follow up of six months, the availability and the advantages of high density polyethylene implants, it can be concluded that their use in reconstruction of orbital floor defects is a good choice.

Keywords: Orbital fractures – Surgery – High density polyethylene.

Resumo

Justifica-se intervir cirurgicamente em fraturas do tipo blow out naqueles casos em que haja alterações da função orbital, como a diplopia, ou mesmo por razões estéticas, como a enoftalmia. Clinicamente, as fraturas do tipo blow out revelam alterações estéticas e funcionais que, associadas aos exames complementares por imagem, como a tomografia computadorizada, indicam o procedimento cirúrgico reparador. A utilização do polietileno de alta densidade (PAD) na reconstrução do assoalho orbital reduz a morbidade do enxerto autógeno, apresentando estabilidade e biocompatibilidade. Este artigo discute um caso cirúrgico de evolução favorável após seis meses de reconstrução do assoalho orbital com PAD.

Palavras-chave: Fraturas orbitárias – Tratamento cirúrgico – Polietileno de alta densidade.

INTRODUCTION

The orbital cavity is comprised of the frontal, sphenoid, and ethmoid bones of the neurocranium, and the maxillary, palatine, zygomatic and lacrimal bones of the visceral cranium. These bilateral cavities house the ocular globes, muscles, cranial nerves (II, III, IV, V and VI), vascular and connective tissue and fat^{1,2}. Knowledge of orbital anatomy is fundamental in making a better diagnosis of periorbital fractures and a correct imaging assessment in traumatized patients.³

Signs associated with orbital fractures include periorbital ecchymosis, edema and subconjunctival ecchymosis, ophthalmoplegia, enophthalmia, hemosis and bone rupture, revealed by imaging exams; and the symptoms are infraorbital paresthesia and diplopia.^{4,5,6,7,8,9,10}

Bourguignon Filho and collaborators⁷ reported that among orbital fractures, the blow out type consists of

the rupture of the orbital walls without fracture of the orbital contour, possibly causing diplopia. One of the probable causes of diplopia is muscular incarceration at the site of the fracture¹¹, which must be treated in order to eliminate the diplopia.

The major cause of orbital fractures are car accidents, followed by physical aggression⁴. In blow out fractures the trauma increases internal pressure of the orbital cavity, and in order to impede ocular explosion, there is a rupture of fine bone on the orbital floor and/or of the papyraceous lamina of the ethmoid bone.^{9,11}

According to Panarello and collaborators¹², diagnosis of the periorbital region is very complex especially when there is swelling and laceration. In these cases, imaging exams are of the utmost importance.

One complementary exam that could be used is the Water's postero-anterior radiograph⁴, though only for an initial evaluation, given its limitations. Fractures that involve the orbital cavity demand more accurate exams, such as computed tomography (CT), in order to visualize the extension and localization of fractures in this complex region and to recommend the surgical procedure that would involve the minimum sequelae^{3,13}.

Recebido em 08 de setembro de 2009; revisado em 10 de fevereiro de 2010
Correspondência / Correspondence: Dra. Marília Gerhardt de Oliveira.
Rua Lucas de Oliveira, 1841/203. CEP: 90.460-001 – Porto Alegre – RS
- Brazil. Phone: +55 (51) 3330-9545. E-mail: mogerhardt@yahoo.com.br

Innovations in CT have enabled earlier surgeries for the reconstruction of internal orbital walls. This immediate diagnosis and early treatment has prevented sequelae such as enophthalmia.¹⁴

Jank and collaborators¹⁵ evaluated CT exams in 424 patients with orbital fracture, and observed that the majority were fractures of the orbital floor (84.2%), followed by the lateral wall (6.1%). They also observed combined fractures in the orbital floor and lateral and medial walls (1.2%) and isolated fractures of the medial (0.9%).

When surgery is indicated, autogenous bone grafts provide excellent biological adaptation, but present disadvantages such as donor site morbidity, limited quantity and moldability as well as the possibility of sub-correction reabsorption.^{16,17}

The main applications for high density polyethylene are restitution of cranial volume, bone defect filling, and orbital reconstruction¹⁶. According to Renò, Lombardi e Cannas¹⁸, alloplastic implants may cause minor inflammatory reactions. However, this does not produce complications such as the need to remove the implant.¹⁰

Zim¹⁷ reported that high density polyethylene is inert, with low tissue reaction and minimal reaction to foreign bodies, and is insoluble to tissue fluids. Its microporous nature (100 a 300µm) allows for the growth of a fibrous tissue that stabilizes the implant. In addition, it is easy to use as it is malleable and can be shaped in an infinite number of forms and sizes. Subperiosteal placement is indicated and fixation with titanium screws is necessary.

CASE REPORT

Male patient, 22 years of age, single, soldier, faioderma, who was punched. Clinical examination showed the presence of periorbital ecchymosis, edema, paresthesia of the infraorbital nerve, diplopia, as well as respiratory difficulty. Palpation of the infraorbital contour and the Waters radiographic exam revealed a possible fracture of the orbital floor, hemossinus and fracture of the nasal bones. CT in coronal (Figure 1) and axial cuts confirmed orbital floor and nose fracture. The patient was evaluated by ophthalmologists and

Figure 1. Tomography in coronal cut demonstrating herniation of the left orbital content by rupture of the orbital floor.

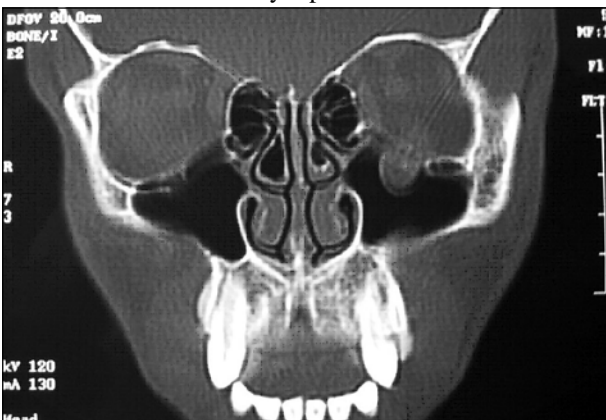


Figure 2. Access to the fracture after incision and separation of the infraorbital tissues.




Figure 3. Insertion and fixation of high density polyethylene with titanium micro-screws.

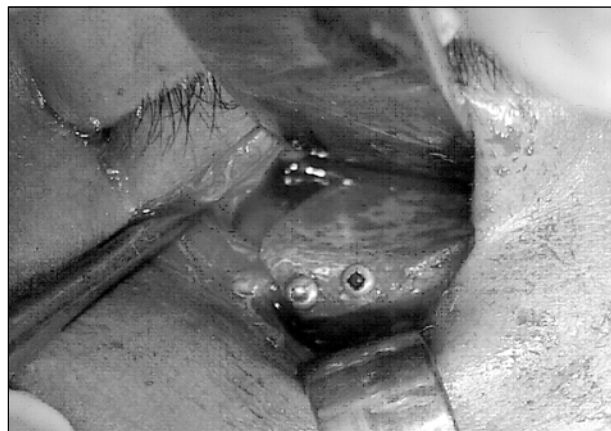
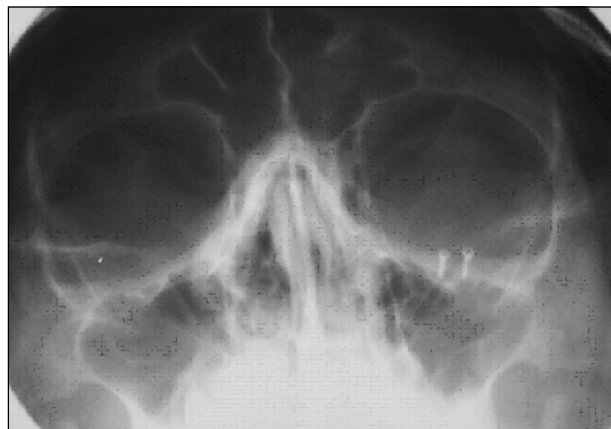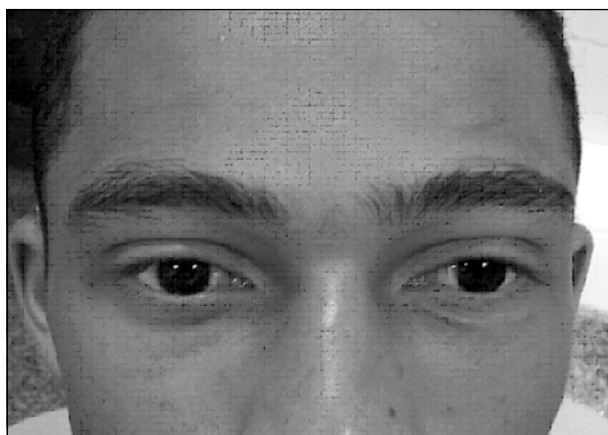


Figure 4 . Waters radiograph at 15 days post-operative.



authorized for surgical treatment. The patient gave free and informed consent of both the surgical procedure and publication of the present case study. Subpalpebral incision and tissue separation was carried out to allow access to the fracture (Figure 2). Correction of the remaining orbital floor was carried out using MEDPOR®

Figure 5. Clinical aspect of the patient at 6 months post-operative.



(Porex Surgical, Inc, College Park, GA) high density polyethylene fixed with two 4mm titanium microscrews (Figure 3). The cut was sutured in planes with 4-0 vicryl and 5-0 mononylon. In the immediate post operative period, the patient presented paresthesia, but not diplopia. At 15 days (Figure 4) and 6 months (Figure 5) post-operative, the patient showed no sequelae.

DISCUSSION

In the clinical exam, the patient presented signs of periorbital ecchymosis, edema and symptoms of infraorbital paresthesia and diplopia, which are the classical signs and symptoms of blow out fractures.^{4,5,6,7,8,9,10}

Enophthalmia may occur in more extensive blow out fractures, due to the herniation of orbital fat after the dislocation of orbital cavity walls^{6,8,9,10,16}. The fracture was relatively small and, consequently, significant enophthalmia was not observed, though diplopia was reported by the patient. Diplopia was probably caused by the herniation of the orbital content to the inner maxillary sinus and not because of muscle incarceration^{8,10,11}, since the patient did not present restriction of ocular movement (ophthalmoplegia).

According to the patient, the fracture was caused by physical aggression, which is in accordance with other studies.⁴

Clinical and Waters radiographic examination demonstrated orbital fracture, but were unable to verify the extension of the fracture. CT in coronal and axial cuts was necessary to quantify the length of the fracture, in accordance with other authors^{7,14,19,20,21,22}

In depth anatomic knowledge of the orbital region is necessary due to the complexity of the structures such as the ocular globe and the innervations of this area.^{1,2,3}

Alloplastic material was used for reconstruction of the fracture in order to avoid of donor site morbidity^{7,16,17}. High density polyethylene was chosen as it is inert, biocompatible, malleable, can not be reabsorbed and can be shaped into an infinite number of forms and sizes,

allowing a prediction of the final result of surgical reconstruction.¹⁷ The objectives of the surgery were to reconstruct the orbital floor and consequently orbital volume, reducing herniation; correct diplopia and avoid enophthalmia, allowing correct muscular function; relieve the compressed infraorbital nerve, allowing paresthesia involution; create a barrier against infections from the maxillary sinus. Taken together, these aspects restore function and aesthetics, as has been indicated by several authors^{5,23,24,25,26}. We agree with Panarello and collaborators¹² that conservative treatment is indicated in cases in which bone dislocation is not visible and if there are no clinical manifestations that would affect aesthetic and function after 14 days.

CONCLUSIONS

It can be concluded that CT is necessary for a correct diagnosis and improved rehabilitative planning in blow out fractures. In addition, in cases where there are aesthetic-functional alterations, surgery is indicated. When possible, alloplastic material should be used and high density polyethylene is a good option due to its adaptability, biocompatibility, lack of reabsorption and, mainly, to the reduction in morbidity and the length of the surgery.

REFERENCES

1. COSTA, A.T. Anatomia e acessos cirúrgicos em região periorbitária para tratamento de traumatismos faciais. 2002. (Trabalho de Conclusão de Curso) - Faculdade de Odontologia, Pontifícia Universidade Católica do Rio Grande do Sul, Porto Alegre, 2002.
2. GERHARDT DE OLIVEIRA, M. Manual de anatomia da cabeça e do pescoço.4.ed. rev. e ampliada. Porto Alegre: EDIPUCRS, 2002.
3. SANTOS, R.S. et al. Diagnóstico de traumatismos faciais periorbitários por meio de tomografias computadorizadas. RFO: R. Fac. Odontol., Passo Fundo, v.9, n.1, p.139-141, jan./jun. 2004.
4. GERHARDT DE OLIVEIRA, M.; RAMOS, A.; OLIVEIRA, R.B. Estudo descritivo de sinais e sintomas das fraturas do complexo orbital e avaliação radiográfica pela incidência de Waters. RFO: R. Fac. Odontol., Passo Fundo, v.4, n.2, p.53-56., jul./dez. 1999.
5. GUERRA, M.F. et al. Reconstruction of orbital fractures with dehydrated human dura mater. J. Oral Maxillofac. Surg., Philadelphia, v.58, n.12, p.1361-1366, Dec. 2000.
6. JIN, H.R. et al. Endonasal endoscopic reduction of blowout fractures of the medial orbital wall. J. Oral Maxillofac. Surg., Philadelphia, v.58, n.8, p.847-851, Aug. 2000.
7. BOURGUIGNON FILHO, A.M. et al. Fraturas orbitárias blowout: tratamento com telas de titânio. R. Cir. Traumatol. Buco-Maxillo-Fac., Recife, v.5, n.3, p.35-42, jul./set. 2005.
8. MAZOCK, J.B.; SCHOW, S.R.; TRIPLETT, R.G. Evaluation of ocular changes secondary to blowout fractures. J. Oral Maxillofac. Surg., Philadelphia, v.62, n.10, p.1298-1302, Oct. 2004.
9. CUNNINGHAM, L.L.; PETERSON, G.P.; HAUG, R.H. The relationship between enophthalmos, linear displacement, and volume change in experimentally recreated orbital fractures. J. Oral Maxillofac. Surg., Philadelphia, v.63, n.8, p.1169-1173, Aug. 2005.
10. AL-SUKHUN, J.; LINDQVIST, C. A comparative study of 2 implants used to repair inferior orbital wall bony defects: autogenous bone graft versus bioresorbable poly-L/DL-Lactide [P(L/DL)LA70/30] plate. J. Oral Maxillofac. Surg., Philadelphia, v.64, n.7, p.1038-1048, July 2006.

11. ILIFF, N. et al. Mechanism of extraocular muscle injury in orbital fractures. *Plastic Reconstr. Surg.*, Hagerstown, v.103, n.3, p.787-799, Mar. 1999.
12. PANARELLO, A.F. et al. Fraturas orbitárias: diagnóstico e indicações para cirurgia: revisão de literatura. *R. Int. Cir. Traumatol. Bucomaxilofac.*, Curitiba, v.2, n.8, p.245-251, 2004.
13. KOLK, A. et al. A novel high-resolution magnetic resonance imaging microscopy coil as an alternative to the multislice computed tomography in postoperative imaging of orbital fractures and computer-based volume measurement. *J. Oral Maxillofac. Surg.*, Philadelphia, v.63, n.4, p.492-498, Apr. 2005.
14. ELLIS 3rd, E.; TAN, Y. Assessment of internal orbital reconstruction for pure blow out fractures: cranial bone grafts versus titanium mesh. *J. Oral Maxillofac. Surg.*, Philadelphia, v.61, n.4, p.442-453, Apr. 2003.
15. JANK, S. et al. Clinical signs of orbital wall fractures as a function of anatomic location. *Oral Surg. Oral Med. Oral Pathol. Oral Radiol. Endod.*, St. Louis, v.96, n.2, p.149-153, Aug. 2003.
16. KONTIO, R. Treatment of orbital fractures: the case for reconstruction with autogenous bone. *J. Oral Maxillofac. Surg.*, Philadelphia, v.62, n.7, p.863-868, July 2004.
17. ZIM, S. Skeletal volume enhancement: implants and osteotomies. *Curr. Opin. Otolaryngol. Head Neck Surg.*, Philadelphia, v.12, n.4, p.349-356, Aug. 2004.
18. RENÒ, F.; LOMBARDI, F.; CANNAS, M. Oxidation increases granulocytes activation: a role in tissue response after prosthesis implant. *Biomaterials*, Oxford, v.24, n.17, p.2895-2900, Aug 2003.
19. HARRIS, G.J. et al. Correlation of preoperative computed tomography and postoperative ocular motility in orbital blowout fractures. *Ophthal. Plast. Reconstr. Surg.*, Hagerstown, v.16, n.3, p.179-187, May 2000.
20. BRADY, S.M. et al. The diagnosis and management of orbital blow out fractures: update 2001. *Am. J. Emerg. Med.*, Philadelphia, v.19, n.2, p.147-154, Mar. 2001.
21. TANRIKULU, R.; EROL, B. Comparison of computed tomography with conventional radiography for midfacial fractures. *Dentomaxillofac. Radiol.*, Houndsmills, v.30, n.3, p.141-146, May 2001.
22. SOARES, L.P. et al. Indicações da tomografia computadorizada no diagnóstico das fraturas naso-órbito-etimoidais. *R. Clin. Pesq. Odontol.*, Curitiba, v.1, n.1, p.29-33, 2004.
23. BANSAGI, Z.C.; MEYER, D.R. Internal orbital fractures in the pediatric age group: characterization and management. *Ophthalmology*, New York, v.107, n.5, p.829-836, May 2000.
24. EGBERT, J.E. et al. Pediatric orbital floor fracture: direct extraocular muscle involvement. *Ophthalmology*, New York, v.107, n.10, p.1875-1879, Oct. 2000.
25. SIDDIQUE, S.A.; MATHOG, R.H. A comparison of parietal and iliac crest bone grafts for orbital reconstruction. *J. Oral Maxillofac. Surg.*, Philadelphia, v.60, n.1, p.44-50, Jan. 2002.
26. GRANT 3rd, J.H. et al. Trapdoor fracture of the orbit in a pediatric population. *Plastic Reconstr. Surg.*, Hagerstown, v.109, n.2, p.482-489, Feb. 2002.