

# Cat scratch disease without a history of cat exposure

Kosuke Oka<sup>1</sup>  | Yume Takagi<sup>2</sup> | Hideharu Hagiya<sup>1</sup>  | Fumio Otsuka<sup>1</sup> 

<sup>1</sup>Department of General Medicine, Okayama University Graduate School of Medicine, Dentistry and Pharmaceutical Sciences, Okayama, Japan

<sup>2</sup>Okayama University Medical School, Okayama, Japan

## Correspondence

Kosuke Oka, Department of General Medicine, Okayama University Graduate School of Medicine, Dentistry and Pharmaceutical Sciences, 2-5-1 Shikata-cho, Kita-ku, Okayama 700-8558, Japan.  
Email: [me20014@s.okayama-u.ac.jp](mailto:me20014@s.okayama-u.ac.jp)

## Abstract

A patient complaining of swelling and tenderness in her left axilla was diagnosed with cat scratch disease despite no apparent history of cat exposure. Zoonosis can occur even in the absence of cat exposure because cat flea *Ctenocephalides felis* is also the vector of the pathogen through the flea feces.

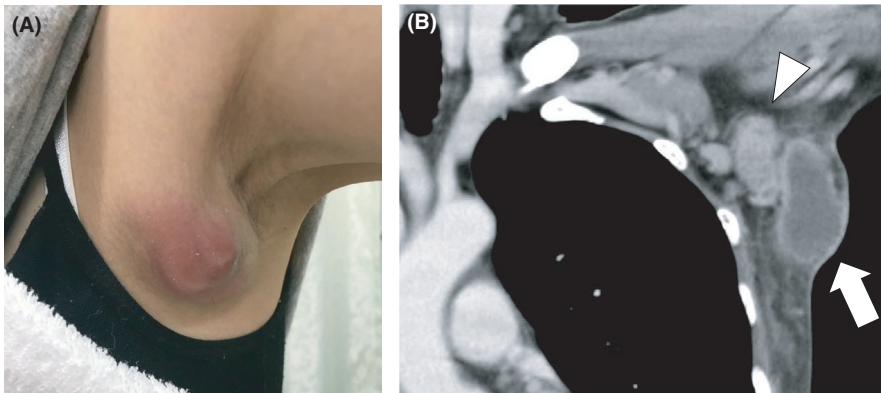
## KEYWORDS

cat scratch disease, lymphadenopathy and subcutaneous abscess

A 52-year-old woman with no history of a cat scratch complained of swelling and tenderness in her left axilla that deteriorated over a month (Figure 1A). Enhanced computed tomography revealed a lymphadenopathy (Figure 1B, arrowhead) and a subcutaneous abscess measuring 4 cm (Figure 1B, arrow). Although she had no apparent history of cat exposure, she was diagnosed with cat scratch disease because serum *Bartonella henselae* IgG titer was highly elevated (1:512; normal range, <1:64). Drainage for

the subcutaneous abscess and administration of oral minocycline and levofloxacin improved the lesion.

In general, cat scratch disease is caused by scratch or bite from a cat infected with *Bartonella* species. However, it can occur without a cat exposure because cat flea *Ctenocephalides felis* is also the vector of the pathogen through the flea feces.<sup>1</sup> In addition to fleas, there are other known and suspected modes of *Bartonella* species transmission.<sup>2</sup> When a patient manifest with single axilla



**FIGURE 1** (A) Shows an axillary image. (B) Shows a contrast-enhanced CT image

lymphadenopathy, the zoonosis should be kept in mind even in the absence of precedent cat exposure.

#### ACKNOWLEDGMENT

None.

#### CONFLICT OF INTEREST

None declared.

#### AUTHOR CONTRIBUTIONS

KO: wrote the first draft and managed all the submission process. YT and HH: contributed to the clinical management of the patient. FO: organized writing the manuscript.

#### CONSENT

Written informed consent was obtained from the patient to publish this case report.

#### DATA AVAILABILITY STATEMENT

Not applicable.

#### ORCID

Kosuke Oka  <https://orcid.org/0000-0002-7996-2354>

Hideharu Hagiya  <https://orcid.org/0000-0002-5086-1891>

Fumio Otsuka  <https://orcid.org/0000-0001-7014-9095>

Fumio Otsuka  <https://orcid.org/0000-0001-7014-9095>

#### REFERENCES

1. Mazur-Melewska K, Mania A, Kemnitz P, Figlerowicz M, Słuzewski W. Cat-scratch disease: a wide spectrum of clinical pictures. *Postep Dermatologii i Alergol.* 2015;32:216-220.
2. Cheslock MA, Embers ME. Human bartonellosis: an underappreciated public health problem? *Trop Med Infect Dis.* 2019;4(2):69.

**How to cite this article:** Oka K, Takagi Y, Hagiya H, Otsuka F. Cat scratch disease without a history of cat exposure. *Clin Case Rep.* 2022;10:e04816. <https://doi.org/10.1002/ccr3.4816>