



# Ukrainian Journal of Nephrology and Dialysis

Scientific and Practical, Medical Journal

## Founders:

- State Institution «Institute of Nephrology NAMS of Ukraine»
- National Kidney Foundation of Ukraine

ISSN 2304-0238;

eISSN 2616-7352

Journal homepage: <https://ukrjnd.com.ua>

## Research Article

Olha Yarmolenko<sup>1</sup>, Valentyna Bumeister<sup>1</sup>, Stefan Polak<sup>2</sup>,  
Olena Gordienko<sup>1</sup>, Olha Prykhodko<sup>1</sup>, Nadiia Demikhova<sup>1</sup>,  
Yurii Shkatula<sup>1</sup>, Andrii Demikhov<sup>1</sup>

doi: 10.31450/ukrjnd.3(71).2021.01

## The effect of the experimental chronic hyperglycemia on the kidney and myocardium

<sup>1</sup>Sumy State University, Sumy, Ukraine

<sup>2</sup>Comenius University, Bratislava, Slovakia

### Citation:

Yarmolenko O, Bumeister V, Polak S, Gordienko O, Prykhodko O, Demikhova N, Shkatula Yu, Demikhov A. The effect of the experimental chronic hyperglycemia on the kidney and myocardium. Ukr J Nephrol Dial. 2021;3(71):3-10. doi: 10.31450/ukrjnd.3(71).2021.01

### Article history:

Received April 26, 2021

Received in revised form  
May 12, 2021

Accepted May 13, 2021

**Abstract.** *The number of patients with diabetes increases annually. Modern forecasts predict that diabetes will be the seventh leading cause of death in 2030. Despite many significant advances in the research of diabetes and the use of new modern treatments, the disease is still progressing, and it is necessary to continue to study the effects of diabetes on human systems and organs: kidney and myocardium.*

**Methods.** *A total of 24 rats of reproductive age (6 months old) were involved in this experimental study. Experimental rats were injected with alloxan intraperitoneally once at a dose of 20 mg/100 g on an empty stomach. In addition, they received a 10% glucose solution 24 hours after alloxan injection and a 5% glucose solution during the experiment. We measured glucose level with Accu-Chek Advantage (Boehringer, Germany) after 2, 12, and 24 hours after alloxan injection, and then weekly. The subjects of the investigation were kidney and heart of the experimental (n=12) and control (n=12) animals for correct comparative analysis.*

**Results.** *The average blood glucose level remained at 11 mmol/L ± 2 mmol/L. During the experimental period, the rats' weight gain, dilation of both ventricles and relative renal weight gain were determined. By the histological examination of the myocardium, we revealed polymorphic nuclei, perinuclear cytolysis, fragmentation, wavy-like deformation of cardiomyocytes, stromal and perivascular edema, uneven filling of blood vessels, and local fibrosis. Thinning of fibrous capsule and cortical layer, destruction of nephrons, and hemorrhages were detected in the kidney.*

**Conclusions.** *Our study confirms the robustness of alloxan-induced hyperglycemia in rats. We came to this conclusion because the early changes in the kidneys and heart are explained by the development of microangiopathies, which is a typical feature of the pathogenesis of diabetes. With prolonged exposure to chronic hyperglycemia, structural disorders of vital organs are worsened. This experimental model could be used for conducting comprehensive research aimed to study the mechanisms of diabetes mellitus, the effects of hyperglycemia on organs and tissues, and correct the complications.*

**Keywords:** hyperglycemia, alloxan, kidney, myocardium, remodeling.

**Conflict of interest statement.** The authors declare no competing interest.

© Yarmolenko O., Bumeister V., Polak S., Gordienko O., Prykhodko O., Demikhova N., Shkatula Yu., Demikhov A., 2021. All rights reserved.

Correspondence should be addressed to Nadiia Demikhova [n.demyhova@med.sumdu.edu.ua](mailto:n.demyhova@med.sumdu.edu.ua)



© Ярмоленко О., Бумейстер В., Полак С., Гордієнко О., Приходько О.,  
Деміхова Н., Шкатула Ю., Деміхов А., 2021

УДК: 616.61:616.12]:612.352.122

О. Ярмоленко<sup>1</sup>, В. Бумейстер<sup>1</sup>, С. Полак<sup>2</sup>, О. Гордієнко<sup>1</sup>,  
О. Приходько<sup>1</sup>, Н. Деміхова<sup>1</sup>, Ю. Шкатула<sup>1</sup>, А. Деміхов<sup>1</sup>

## Вплив експериментальної хронічної гіперглікемії на нирки та міокард

<sup>1</sup>Сумський державний університет, м. Суми, Україна

<sup>2</sup>Університет Коменського, Братислава, Словаччина

**Резюме.** Щорічно збільшується кількість хворих на цукровий діабет. Сучасні прогнози передбачають, що цукровий діабет стане сьомою провідною причиною смертності у 2030 р. Незважаючи на значний прогрес у патогенезі та лікуванні цукрового діабету, прогресування захворювання вимагає вивчення наслідків цукрового діабету на нирки та міокард.

**Методи.** До експерименту залучені 24 щури репродуктивного віку (6 місяців). Піддослідним щурам вводили алоксан внутрішньочеревно одноразово у дозі 20 мг/100 г натще. Крім того, щури отримували 10% розчин глюкози протягом 24 годин після введення алоксану та 5% розчин глюкози під час експерименту. Ми вимірювали рівень глюкози за допомогою Асси-Чек Advantage (Boehringer, Німеччина) через 2, 12 та 24 години після введення алоксану, а потім щотижня. Об'єктом дослідження були нирки та серце піддослідних (n=12) та контрольних (n=12) тварин.

**Результати.** Середній рівень глюкози в крові залишався на рівні 11 ммоль/л ± 2 ммоль/л. Визначено збільшення ваги щурів, розширення обох шлуночків серця та відносне збільшення ваги нирок. При гістологічному дослідженні міокарда визначено поліморфні ядра, перинуклеарний цитоліз, фрагментацію, хвилеподібну деформацію кардіоміоцитів, стромальний та периваскулярний набряк, нерівномірне заповнення судин та локальний фіброз. У нирках виявлено витончення волокнистої капсули та коркового шару, руйнування нефронів та крововиливи.

**Висновки.** Наше дослідження підтверджує, що вибраний індуктор експериментальної гіперглікемії алоксан та його доза викликає стійку гіперглікемію у щурів. Ми дійшли до такого висновку, оскільки ранні зміни в нирках та серці пояснюються розвитком мікроангіопатій, що є типовою ознакою патогенезу діабету. При тривалому впливі на хронічну гіперглікемію структурні порушення життєво важливих органів посилюються. Така експериментальна модель може бути корисною для проведення комплексних досліджень, спрямованих на вивчення механізмів розвитку цукрового діабету, впливу гіперглікемії на органи та тканини та пошук шляхів корекції ускладнень цукрового діабету.

**Ключові слова:** гіперглікемія, алоксан, нирки, міокард, ремоделювання.

**Introduction.** Millions of people of all genders and races have diabetes. The World Health Organization informs about to increase the number of such patients aged 20–79 from 108 million in 1980 to almost 463 million in 2019. Approximately half of them do not even suspect the presence of their disease [1, 2]. According to the forecasts of the International Diabetes Federation, given the current trends of urbanization and population growth, the number of adults with diabetes in 2025, 2030 and 2045 will be 438, 578 and 700 million, respectively [3, 4]. The number of deaths due to diabetes in 2019 is 4.2 million, which is 11.3% of all deaths in the world. By the end of 2019, the total cost of treating diabetes has reached \$ 760 billion, which is

about 10% of all health care costs. The countries with the highest prices for the treatment of diabetes in 2019 were the USA, China, and Brazil. Analysts attribute this to a large number of overweight residents. Despite the decline in morbidity in some European countries, the increase is 3.4% annually [5–11].

In 2013 1.04 million patients with diabetes were registered in Ukraine, including 438 000 men and 605 000 women (age 20–79 years) [12, 13]. Diabetes prevalence in the European countries is similarly heterogeneous with an age-standardized comparative prevalence ranging from 2.4% in Moldova to 14.9% in Turkey in 2013. Overall, the raw prevalence of diabetes in Europe in 2013 is estimated to be 8.5%, which corresponds to 56 million cases (age 20–79 years) [14].

It is predicted that diabetes will be the seventh leading cause of death in 2030 [1, 2]. Some trends in the stabilization of morbidity in developed countries may not be a reason to suspend preventive work, especially against the background of the Covid-19 pandemic, which is now raging around the world. When

Nadiia Demikhova

n.demyhova@med.sumdu.edu.ua

the virus enters the body, the immune system begins to produce cytokines that coordinate cells in the fight against the pathogen. However, some people have an overproduction of cytokines, which leads to a cytokine storm, which attacks both affected and healthy cells. Experiments on mice with induced hyperglycemia and infected with influenza virus revealed excess cytokine production [15, 16]. In addition, studies by Chinese physicians have shown that coronavirus-infected people with comorbidities such as diabetes have a more frequent cytokine storm than patients without comorbidities. Therefore, despite many significant advances in the study of diabetes and the use of modern treatments, the disease is still progressing, and it is necessary to continue to study the effects of diabetes on human systems and organs.

**The present study aimed** to investigate the remodeling of experimental rats' kidneys and myocardium under alloxan-induced hyperglycemia.

**Materials and Methods.** The experimental animals, white inbred matured male rats (n=24), were housed under standard conditions, with proper diet and water ad libitum at the animal facility of Sumy State University, Ukraine.

Animal treatment and all experimental procedures were performed in compliance with the European Convention for the Protection of Vertebrate Animals used for Experimental and other Scientific Purposes. The study was approved by the Ethical Committee of Sumy State University, Ukraine.

Experimental study design comprised 3 groups: control (group 1; n=12) - intact animals; animals with alloxan-induced hyperglycemia, 30 days after alloxan administration (group 2; n=6); animals with alloxan-induced hyperglycemia, 60 days after alloxan administration (group 3; n=6).

Alloxan-induced diabetes is one of the widely used model to induce T1DM in experimental animals [17-21]. For this purpose, we used such a chemical substance as alloxan monohydrate. Alloxan is a urea derivative that causes selective necrosis of the  $\beta$ -cells of pancreatic islets [22, 23]. The alloxan was re-dissolved in a 0.9% solution of sodium chloride and injected intraperitoneally once at a dose of 20 mg/100 g on an empty stomach [24]. Taking into account that the alloxan causes a toxic effect on the nephron tubules cells [25, 26], the experimental animals additionally received a 10% glucose solution 24 hours after alloxan injection and 5% glucose solution during the experiment.

**Blood glucose determination.** Blood glucose levels were determined using the glucose oxidase method with Accu-Chek Advantage glucometer (Boehringer, Germany) after 2, 12 and 24 hours and then weekly after alloxan administration. Blood samples were taken from the tail vein. The average blood glucose level remained at  $11 \pm 2$  mmol/L.

To study the remodeling of the internal organs under the alloxan-induced hyperglycemia, we used the following methods [27-39].

#### 1. Organometry.

We measured the weight of the organs on analytical scales VLR-200-M (Ukraine). Rats' hearts were dissected by Avtandilov, GG [40], and divided into 4 parts: a free wall of the left ventricle (LV), a free wall of the right ventricle (RV), interventricular septum and atria. We weighted the wall of the LV (LVW) and the RV (RVW) with a proportioned mass part of the interventricular septum. We measured the endocardial surface area of the LV (LVSA) and the RV (RVSA) by the method of indirect planimetry and calculated the planimetric index (PI) as the ratio of RVSA to LVSA.

In kidneys, we investigated the absolute weight, the relative weight (g) of organs was calculated by the following formula: Relative weight = absolute lung weight (g) / rat body weight (g), and we measured the thickness of the cortex.

2. *Histological examination.* Histological samples prepared by the standard method were stained with hematoxylin and eosin, investigated using the light microscope "OLIMPUS BH-2" and photographed with a digital video camera Baumer/optronic Type: CX 05c (Switzerland).

**Statistical analysis.** The experimental data were processed and analyzed using MS Office 2016 EXCEL (Microsoft Corp., USA) and STATISTICA 13 (TIBCO Software Inc., 2018). The results were expressed as a mean  $\pm$  SEM. The difference between the groups was determined using the Student's t-test. A probability level (p-value) of less than 0.05 was considered to be statistically significant.

**Results.** The obtained data shows significant changes in heart organometric indices during the experiment. Thus, LVW increases by 53.4% ( $p < 0.0001$ ). RVW is 40.23% ( $p < 0.0001$ ) more than respective index of control rats. LVSA increases by 33.53% ( $p < 0.0001$ ), RVSA – by 42.25% ( $p=0.0012$ ). PI does not change, indicating a uniform dilatation of the heart ventricles.

On visual examination, the kidneys of animals affected by hyperglycemia are visually enlarged, their capsule is tense, smooth, pale gray. The relative weight increases by 27,3% ( $p < 0,05$ ), the absolute weight changes nonsignificantly.

The histological examination of experimental animals' myocardial samples on day 30 of the experiment reveals the presence of polymorphic nuclei of cardiomyocytes. There is a local loss of integrity (fragmentation) and unidirectionality of muscle fibers. The gaps between the cardiomyocyte fibers are dilated due to the development of stromal edema. Significant violations are observed on the part of the vascular component. In some fields of view, vessels are empty. In others, the aggregation of erythrocytes in vessels, capillary hyperemia is visualized (Fig.1).

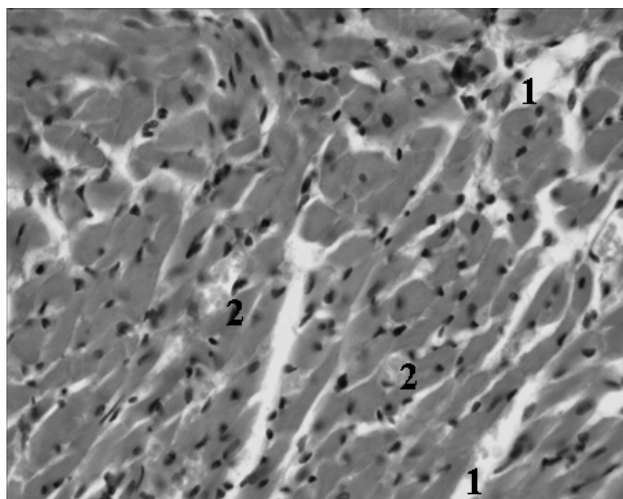


Fig. 1. The myocardium of the experimental rats on the 30<sup>th</sup> day of alloxan-induced hyperglycemia x 800. 1 – stromal edema, 2 – capillary hyperemia.

Continued exposure to chronic hyperglycemia causes even more significant changes in the myocardial structure of experimental rats. On day 60 of the investigation, fibers of cardiomyocytes are deformed wavelike. Some cells are unevenly stained; the perinuclear zone is enlightened (cytolysis). Stromal edema progresses, capillaries are full of blood. In some fields of view, areas of the myocardium are replaced by connective tissue with foci of cellular infiltration. There is edema around the vessels (Fig. 2).

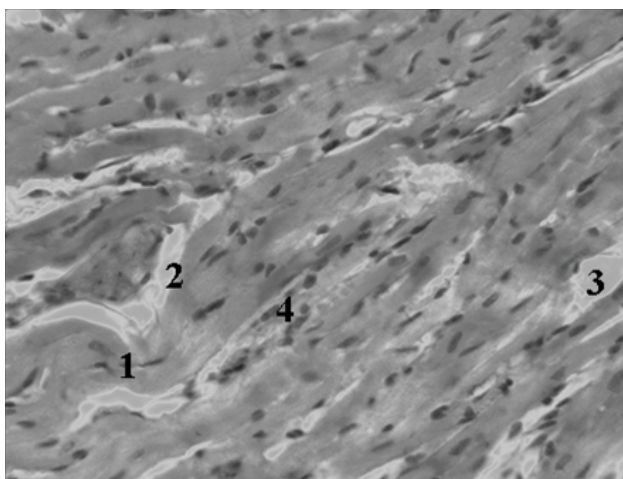


Fig. 2. The myocardium of the experimental rats on day 60 of alloxan-induced hyperglycemia x 800. 1 – a wavy deformed fibers of cardiomyocytes, 2 – perivascular edema, 3 – stromal edema, 4 – cellular infiltration.

On day 30 of the experiment, the fibrous capsule of the kidney does not have a clear separation from the cortical substance. The amount of subcapsular nephrons increases. Most glomeruli had smooth contours with a distinct cavity between the glomerulus and the capsule. In some areas of the nephron's glomeruli, the capillaries are partially destroyed, so there is hemorrhage within the capsule. No structural changes are detected in the renal medulla (Fig. 3).

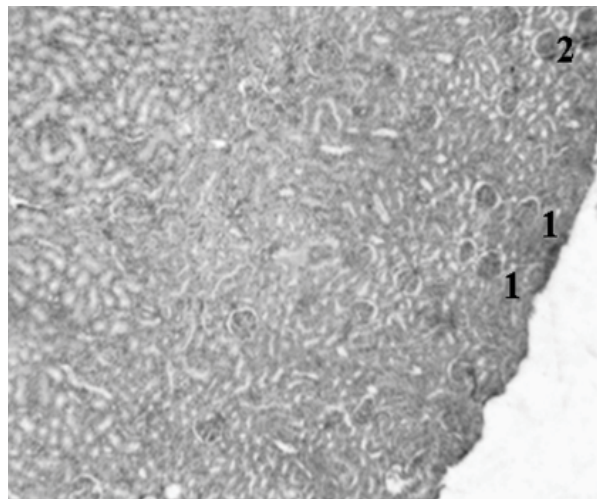


Fig. 3. The kidney of the experimental rats on day 30 of alloxan-induced hyperglycemia x 400. 1 – subcapsular nephrons, 2 – hemorrhage within the capsule.

On day 60 of the experiment, the fibrous capsule is almost invisible. The thickness of the cortical layer is uneven. There is a tendency to thin it. Hemorrhages are present in the glomeruli of the nephrons. A pyramid of the renal medulla (in a rat's kidney it is single) loses its shape and clear contours. Many hemorrhages are visible in the renal medulla (Fig. 4).

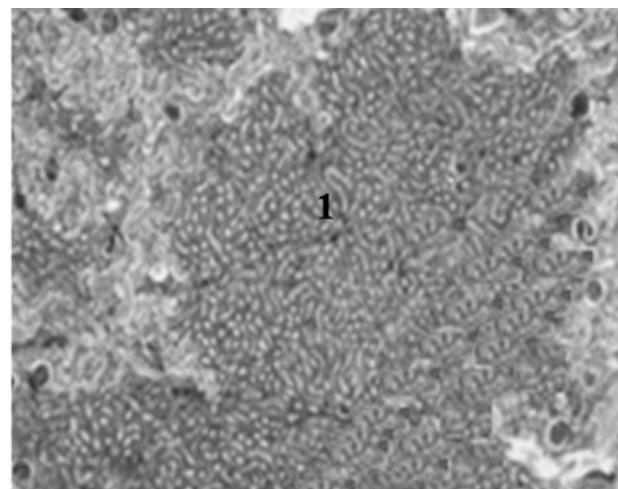


Figure 4. The kidney of the experimental rats on day 60 of alloxan-induced hyperglycemia x 800. 1 – the renal pyramid with no clear contours.

**Discussion.** Diabetes mellitus (DM) is a multifactorial metabolic disorder, characterized by chronic hyperglycemia leading to significant physiological, biochemical, and histological changes in the internal organs, including kidneys [40, 41]. Diabetic nephropathy is the leading cause of end-stage renal disease. The characteristic histologic changes of diabetic nephropathy include thickening of the glomerular and tubular basement membrane, increase in the mesangial matrix, Kimmelstiel-Wilson nodules sometimes combined with microaneurysms, exudative or hyalinosis lesions, capsular drop and afferent and efferent arteriolar hyalinosis [40]. Several factors related to DN include the effect of

genetic susceptibility, high glucose, polyol pathway activation, renin-angiotensin system activation, reactive oxygen species, activation of the protein kinase C pathway, increase of advanced glycation end-product and glomerular hyperfiltration [42, 43]. There are data that alloxan-induced diabetic rat is the most widely in used studying diabetic nephropathy and histological changes in the rat diabetic nephropathy closely resemble the human disease [44].

Pathophysiology of diabetic nephropathy is considered as the result of the interaction between metabolic and haemodynamic factors [45]. There are data that sodium and water retention plays a dominant role in the initiation and maintenance of systemic hypertension in patients with diabetic nephropathy, whereas the contribution of the renin-angiotensin-aldosterone system is smaller [46]. Disorders of urine secretion and urination complicate disorders of homeostasis, especially water-electrolyte balance (Fig. 5). Water-electrolyte and metabolic imbalance significantly worsen the morpho-functional state of the cardiovascular system [45]. Therefore, to study the structural changes in alloxan-induced hyperglycemia, we chose kidneys and heart.

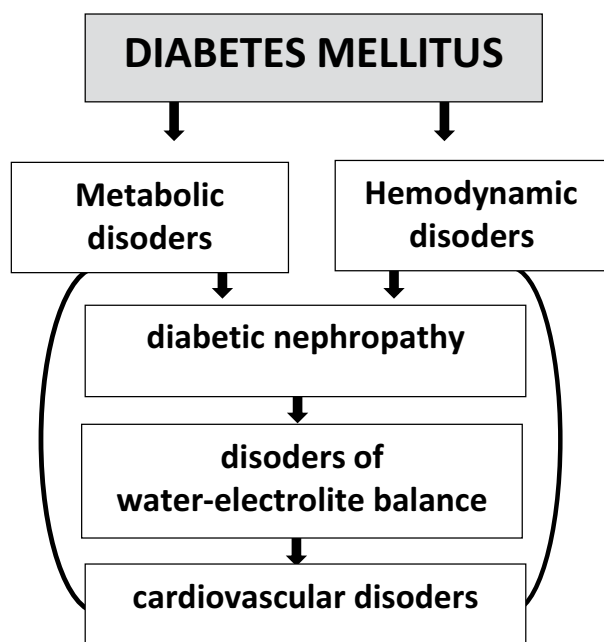


Fig. 5. Relationship between renal and cardiovascular complications of diabetes

On day 30 of the experiment, changes in the studied organs are associated with microcirculatory disorders. In kidneys, the changes are manifested by partial destruction of glomeruli. Such changes in the kidneys' structure develop as a result of microangiopathies with direct damage to the capillary networks of the nephron, as well as damage to the afferent and efferent arterioles which later lead to glomerular hyperfiltration. Damage to the glomerular membrane causes the appearance of protein in the urine. It is no coincidence that microalbuminuria is an early marker of diabetic nephropathy development. Modern research emphasizes that chron-

ic hyperglycemia leads to activation of the renin-angiotensin system. Increasing angiotensin II levels lead to efferent arteriolar vasoconstriction and are associated with albuminuria. Another link in the development of efferent arteriolar vasoconstriction is endothelin-1 [47-49].

Activation of the renin-angiotensin system leads not only to disorders in the kidneys but also to vasoconstriction of blood vessels in the body as a whole. Therefore, on the 30th day of the experiment, morphological disorders are detected in the myocardium as well. Their manifestations are polymorphic nuclei of cardiomyocytes, local loss of integrity and unidirectionality of muscle fibers, stromal edema, and uneven filling of blood vessels.

On day 60 of the study, the above-described changes in kidneys and heart progress. The fibrous capsule and the cortical layer of the kidney become visually thinner. Damage to the nephrons covers not only the glomeruli but also the nephron tubules. Changes in the myocardial structure are worsened by cytolysis, wavelike deformation of cardiomyocytes and local fibrosis. During the experiment, there is an increase in the mass of the heart's ventricles and an expansion of their cavities. Such changes are explained in our recent study, which found damage to lung tissue under the influence of chronic hyperglycemia [25].

Therefore, disorders occur in both systemic and pulmonary circulation and explain the development of uniform hypertrophy and dilatation of both ventricles during our research. Disorders of water-electrolyte balance due to impaired renal function cause arrhythmias, which are manifested by contractile damage and wavy deformation of cardiomyocyte fibers on the histological preparations of the myocardium.

**Conclusions.** Our study confirms the robustness of alloxan-induced hyperglycemia in rats. We came to this conclusion because the early changes in the kidneys and heart are explained by the development of microangiopathies, which is a typical feature of the pathogenesis of diabetes. With prolonged exposure to chronic hyperglycemia, structural disorders of vital organs are worsened. This experimental model could be used for conducting comprehensive research aimed to study the mechanisms of diabetes mellitus, the effects of hyperglycemia on organs and tissues, and correct the complications.

#### Authors' contribution.

**Yarmolenko O. & Bumeister V.:** data collection and idea owner of this study;

**Prykhodko O., Demikhova N., Shkatula Y. & Polak S.:** the study design;

**Gordienko O., Prykhodko O., Shkatula Y.:** data collection;

**Bumeister V., Gordienko O., Prykhodko O.:** writing and submitting the manuscript;

**Yarmolenko O., Demikhova N., Demikhov A.:** the manuscript editing and approval of the final draft.

**Source of Funding.** Sumy State University.

**References:**

1. International Diabetes Federation. IDF Diabetes Atlas, 9th edn. Brussels, Belgium: 2019. Available at: <https://www.diabetesatlas.org>.
2. Mathers CD, Loncar D. Projections of global mortality and burden of disease from 2002 to 2030. *PLoS Med.* 2006;3(11):e442. doi: 10.1371/journal.pmed.0030442.
3. Maslova OV, Suncov JuI. Epidemiology of diabetes mellitus and microvascular complications. *Diabetes mellitus.* 2011;3:6-11.
4. Pankiv V.I. Diabetes mellitus: definition, classification, epidemiology, risk factors. *International Endocrinological Journal.* 2013;7(55):95-104.
5. de Leeuw TG, Mangiarini L, Lundin R, Kaguelidou F, van der Zanden T, Pasqua OD, et al; GAPP consortium. Gabapentin as add-on to morphine for severe neuropathic or mixed pain in children from age 3 months to 18 years - evaluation of the safety, pharmacokinetics, and efficacy of a new gabapentin liquid formulation: study protocol for a randomized controlled trial. *Trials.* 2019;20(1):49. doi: 10.1186/s13063-018-3169-3. Erratum in: *Trials.* 2019;20(1):368.
6. Demikhova N, Cherkashyna L, Chernatska O et al. The relationship between lipid metabolism and albuminuria level with single nucleotide polymorphism -204a>c [rs 3808607] CYP7A1 gene in patients with 2 type diabetes mellitus and diabetic nephropathy. *Romanian Journal of Diabetes, Nutrition and Metabolic Diseases.* 2019;26(3):253-261. doi: 10.2478/rjdnmd-2019-0026.
7. Chernatska O, Demikhova N, Rudenko T et al. Assessment of the lipid profile correction in patients with arterial hypertension and type 2 diabetes mellitus. *Azerbaijan Medical Journal.* 2019;1:95-99.
8. Chernatska O, Demikhova N. Improvement of treatment in persons with arterial hypertension and type 2 diabetes mellitus. *Georgian Medical News.* 2018;11(284):47-51.
9. Marushchak M, Krynytska I, Mikolenko A, Andreychyn Yu, Bodnar Ya, Chornomydz I. Chronic heart failure causes osteopathy or is osteopathy a factor in development of chronic heart failure? *Asian Journal of Pharmaceutical and Clinical Research.* 2018;11(1):111-115. doi: 10.22159/ajpcr.2018.v11i1.17532.
10. Popov SV, Melekhovets OK, Demikhova NV, Vynnychenko LB, Khil'ko IeS, Tychyna DO, Murga IV. Application of "reytoil" in prevention of atherosclerosis in diabetes patients. *Lik Sprava.* 2012 ;(8):119-26. [In Ukrainian].
11. Siddiqui A, Siddiqui S, Ahmad S et al. Diabetes: Mechanism, Pathophysiology and Management. *A Review International Journal of Drug Development & Research.* 2013;5(2):1-23.
12. Tkachenko VI, Vydyborets NV, Kovalenko OF. Analysis of the prevalence and incidence of diabetes mellitus and its complications among the population of Ukraine and in the Kyiv region for 2004-2013. *Achievements of clinical and experimental medicine.* 2014;2:177-182. doi:10.22141/2224-0721.14.3.2018.136426.
13. Woynarowska-Soldan M, Yezhova O, Sytnyk O, Węziak-Białowolska D. Positive health behaviours Polish and Ukrainian medical students in the context of chronic diseases. *Przegl Epidemiol.* 2018;72(4):509-523. doi: 10.32394/pe.72.4.26.
14. Tamayo T, Rosenbauer J, Wild SH, Spijkerman AM, Baan C, Forouhi NG, et al. Diabetes in Europe: an update. *Diabetes Res Clin Pract.* 2014 Feb;103(2):206-17. doi: 10.1016/j.diabres.2013.11.007.
15. Sattar N. Revisiting the links between glycaemia, diabetes and cardiovascular disease. *Diabetologia.* 2013 Apr;56(4):686-95. doi: 10.1007/s00125-012-2817-5.
16. de Ferranti SD, de Boer IH, Fonseca V, Fox CS, Golden SH, Lavie CJ, et al. Type 1 diabetes mellitus and cardiovascular disease: a scientific statement from the American Heart Association and American Diabetes Association. *Circulation.* 2014 Sep 23;130(13):1110-30. doi: 10.1161/CIR.0000000000000034.
17. Chawla A, Chawla R, Jaggi S. Microvascular and macrovascular complications in diabetes mellitus: Distinct or continuum?. *Indian J Endocrinol Metab.* 2016;20(4):546-551. doi:10.4103/2230-8210.183480.
18. Chougale AD, Panaskar SN, Gurao PM et al. Optimization of Alloxan Dose is Essential to Induce Stable Diabetes for Prolonged Period. *Asian Journal of Biochemistry.* 2007;2(6):402-408. doi:10.3923/AJB.2007.402.408.
19. Ighodaro OM, Adeosun AM, Akinloye OA. Alloxan-induced diabetes, a common model for evaluating the glycemic-control potential of therapeutic compounds and plants extracts in experimental studies. *Medicina (Kaunas).* 2017;53(6):365-374. doi: 10.1016/j.medic.2018.02.001.
20. Jain DK, Arya RK. Anomalies in alloxan-induced diabetic model: It is better to standardize it first. *Indian J Pharmacol.* 2011;43(1):91. doi:10.4103/0253-7613.75684.
21. Mostafavinia A, Amini A, Ghorishi SK, Pouriran R, Bayat M. The effects of dosage and the routes of administrations of streptozotocin and alloxan on induction rate of type1 diabetes mellitus and mortality rate in rats. *Lab Anim Res.* 2016;32(3):160-165. doi: 10.5625/lar.2016.32.3.160.

22. *Lenzen S.* The mechanisms of alloxan- and streptozotocin-induced diabetes. *Diabetologia*. 2008 Feb;51(2):216-26. doi: 10.1007/s00125-007-0886-7.
23. *Korol LV, Mygal LYa, Stepanova NM.* Intensity of oxidative stress and activity of angiotensin converting enzyme in blood of patients with uncomplicated pyelonephritis. *Ukr Biochem J*. 2017;89(2):99-105. doi: 10.15407/ubj89.02.099.
24. *Demikhova N, Yarmolenko O, Teslyk T, Bumeister V, Prykhodko O, Dmytruk S.* The remodeling of lung under the influence of alloxan-induced hyperglycemia. *Romanian Journal of Diabetes Nutrition and Metabolic Diseases*. 2020;27(1):45-49. doi:10.46389/rjd-2020-1008.
25. *Shkatula YV, Badion YO, Tkachenko YA et al.* Epidemiology of injuries in children resulting from a fall from a height. *Azerbaijan Medical Journal*. 2021;2.
26. *Misra M, Aiman U.* Alloxan: an unpredictable drug for diabetes induction?. *Indian J Pharmacol*. 2012;44(4):538-539. doi:10.4103/0253-7613.99348.
27. *Cherkashyna L, Konoval N, Shklyar A, Kyrychenko I, Haidash O, Demikhova N.* Study of structural and biochemical changes in the muscular tissue of the oesophagus for solving the problem of diagnosing the prescription of death coming. *Pol Merkur Lekarski*. 2020;48(283):42-44.
28. *Cherkashyna L, Konoval N, Shklyar A, Najar S, Haidash O, Kuts L, Gortinskaya O, Demikhova N.* The dynamics of changes in biochemical markers of the state of tissue in intercostal muscles during the early postmortem period. *Pol Merkur Lekarski*. 2020;48(283):45-48.
29. *Cherkashyna L, Shklyar A, Demikhova N, Protsenko O, Kicha N, Sukhonosov R, Singh HH, Sytiuk T.* Lipofuscin content in the muscle tissue during the early postmortem period: improvement of forensic diagnosis of the prescription of death coming. *Pol Merkur Lekarski*. 2020;48(284):93-96.
30. *Cherkashyna L, Shklyar A, Sukhonosov R, Miroshnikova O, Naguta L, Olkhovskiy V.* Cholinesterase in different types of the muscle tissue during the early postmortem period for diagnosis of death coming. *Bangladesh Journal of Medical Science*. 2021;20(1):95-100. doi:10.3329/bjms.v20i3.50352
31. *Etuk EU.* Animals models for studying diabetes mellitus. *Agriculture and Biology Journal of North America*. 2010;1(2):130-134.
32. *Grytsiuk MI, Bojchuk TM, Petryshen OI.* Comparative characteristics of experimental models of diabetes mellitus. *World of Medicine and Biology*. 2014;2(44):199-203.
33. *Guzyk MM, Dyakun KO, Yanytska LV, Pryvrotska IB, Krynytska IYa, Pishel IM.* Inhibitors of Poly(ADP-Ribose) Polymerase-1 as Agents Providing Correction of Brain Dysfunctions Induced by Experimental Diabetes. *Neurophysiology*. 2017;49(3):183-193. 10.1007/s11062-017-9672-4.
34. *Krynytska I, Marushchak M.* The Indices of Nitric Oxide System in Rats with Carrageenan-Induced Enterocolitis Combined with Diabetes Mellitus. *Romanian Journal of Diabetes, Nutrition and Metabolic Diseases*. 2018;25(3):283-288. doi: 10.2478/rjdnmd-2018-0033.
35. *Shkatula YV, Badion YO, Novikov MV.* Efficiency of different methods of temporary external hemostasis at the pre-hospital stage of emergency medical care. *Novosti Khirurgii*. 2021;28(6):688-693. doi: 10.18484/2305-0047.2020.6.688.
36. *Prykhodko O, Gulaya V, Yarmolenko O et al.* Microscopic changes in the organs of rats under conditions of general dehydration of the organism. *Azerbaijan Medical Journal*. 2016;4:95-100.
37. *Sakata N, Yoshimatsu G, Tsuchiya H, Egawa S, Unno M.* Animal models of diabetes mellitus for islet transplantation. *Exp Diabetes Res*. 2012;2012:256707. doi: 10.1155/2012/256707.
38. *Yarmolenko O, Sikora V, Bumeister V, Prykhodko O, Demikhova N, Bumeister L.* Age-dependent cardioprotective action of meldonium on heart remodeling under the experimental hypoosmolar hyperhydration. *Bangladesh J Med Sci*. 2019;18(2):395-401. doi:10.3329/bjms.v18i2.40714.
39. *Zaragoza C, Gomez-Guerrero C, Martin-Ventura JL, Blanco-Colio L, Lavin B, Mallavia B, Tarin C, Mas S, Ortiz A, Egido J.* Animal models of cardiovascular diseases. *J Biomed Biotechnol*. 2011;2011:497841. doi: 10.1155/2011/497841.
40. *Avtandilov GG.* Moscow, Meditsina Publ., 2002, 240 pp.
41. *Degen AS, Krynytska IY, Kamyshnyi AM.* Changes in the transcriptional activity of the entero-insular axis genes in streptozotocin-induced diabetes and after the administration of TNF- $\alpha$  non-selective blockers. *Endocr Regul*. 2020;54(3):160-171. doi: 10.2478/enr-2020-0019.
42. *Jain M.* Histopathological changes in diabetic kidney disease. *Clinical Queries: Nephrology*. 2012;1(2):127-133.
43. *Pourghasem M, Shafi H, Babazadeh Z.* Histological changes of kidney in diabetic nephropathy. *Caspian J Intern Med*. 2015;6(3):120-7.
44. *Yamamoto T, Nakamura T, Noble NA, Ruoslahti E, Border WA.* Expression of transforming growth factor beta is elevated in human and experimental diabetic nephropathy. *Proc Natl Acad Sci U S A*. 1993;90(5):1814-1818. doi:10.1073/pnas.90.5.1814.

45. *Mora-Fernández C, Domínguez-Pimentel V, de Fuentes MM, Górriz JL, Martínez-Castelao A, Navarro-González JF.* Diabetic kidney disease: from physiology to therapeutics. *J Physiol.* 2014;592(18):3997-4012. doi: 10.1113/jphysiol.2014.272328.
46. *Czekalski S.* Diabetic nephropathy and cardiovascular diseases. *Roczniki Akademii Medycznej w Białymstoku.* 2005;50:122-125.
47. *Toth-Manikowski S, Atta MG.* Diabetic Kidney Disease: Pathophysiology and Therapeutic Targets. *J Diabetes Res.* 2015;2015:697010. doi:10.1155/2015/697010.
48. *Vasylchenko VS, Korol LV, Kuchmenko OB, Stepanova NM.* The oxidative status in patients with chronic kidney disease. *Ukr. Biochem Journal.* 2020;92(5):70–77. doi.org/10.15407/ubj92.05.070.
49. *Vilhova I, Kryvko YY, Maciejewski R.* The radio-anatomical research of plural renal arteries. *Folia Morphol (Warsz).* 2001;60(4):337-41.