

# A comparative assessment of the amount and rate of orthodontic space closure toward a healed vs recent lower premolar extraction site: *A split-mouth randomized clinical trial*

Elham S. Abu Alhaja<sup>a</sup>; Rami A. Al Shayeb<sup>b</sup>; Susan Al-Khateeb<sup>c</sup>; Hasan O. Daher<sup>d</sup>, Saba O. Daher<sup>d</sup>

## ABSTRACT

**Objectives:** To investigate and compare the amount and rate of space closure and tooth tipping during orthodontic space closure toward a recent vs healed first premolar extraction site.

**Materials and Methods:** The mandibular arches of 23 patients were included. Treatment plans included lower first premolar extractions. After reaching 0.019 × 0.025-inch stainless-steel archwires (SSAW), patients were subdivided into two groups (Group 1: space closure was carried out toward a healed first premolar extraction space and Group 2: space closure was carried out immediately after first premolar extraction). Elastomeric power chain from second molar to second molar was used to close lower extraction spaces. The following time points were defined: T1: just before space closure; T2–T4: 1–3 months after initial space closure. Records consisted of dental study models. The amount and rate of extraction space closure were evaluated at each time point.

**Results:** In Group 1 (healed socket), a total amount of 1.98 mm (coronally) and 1.75 mm (gingivally) of space closure was achieved. The rate of space closure was 0.66 mm/month coronally and 0.58 mm/month gingivally. In Group 2 (recent socket), the total amount of space closure was 3.02 mm coronally and 2.68 mm gingivally. The rate of space closure was 1.01 mm/month coronally and 0.89 mm/month gingivally. Differences between the two groups were significant ( $P < .01$ ). Tipping of adjacent teeth during space closure was similar in both groups ( $P > .05$ ).

**Conclusions:** In the lower arch, the amount and rate of space closure toward a recent extraction site were higher than that toward a healed extraction socket with similar tipping of teeth in both groups. (*Angle Orthod.* 0000;00:000–000.)

**KEY WORDS:** Healed; Recent; Lower arch; Space closure, Tipping

## INTRODUCTION

Orthodontic treatment duration depends on the severity of malocclusion, the extraction or nonextraction

treatment plan, and patient compliance during treatment.<sup>1–3</sup> Conventional treatment using fixed appliances requires 18–24 months,<sup>4</sup> where extraction space closure is the core time-consuming process requiring one-third to one-half of orthodontic treatment duration.<sup>5</sup> In adult patients, lengthy orthodontic treatment is often accompanied with periodontal challenges such as root resorption, alveolar bone loss, and gingival recession.<sup>6,7</sup>

Acceleration of orthodontic treatment became interesting to patients and orthodontists,<sup>8</sup> especially adult patients who preferred to complete orthodontic treatment with minimal time because of periodontal, social, and esthetic concerns.<sup>6,7,9</sup> Accelerated tooth movement into a recent extraction site has been reported and compared to a healed socket. It is believed that retraction of a tooth toward a recent extraction site is more advantageous compared to delayed retraction after extraction.<sup>10–12</sup> Häslér et al.<sup>10</sup> studied the rate of

<sup>a</sup> Professor in Orthodontics, College of Dental Medicine, QU Health, Qatar University, Doha, Qatar.

<sup>b</sup> Orthodontist, Private orthodontic clinic, Amman, Jordan.

<sup>c</sup> Professor, Division of Orthodontics, Department of Preventive Dentistry, Faculty of Dentistry, Jordan University of Science and Technology, Irbid, Jordan.

<sup>d</sup> Student, Faculty of Medicine, Jordan University of Science and Technology, Irbid, Jordan.

Corresponding author: Dr Elham S. Abu Alhaja, Professor in Orthodontics, College of Dental Medicine, QU Health, Qatar University, P.O. Box 2713, Doha, Qatar (e-mail: elhama@qu.edu.qa)

Accepted: February 2022. Submitted: October 2021.

Published Online: March 28, 2022

© 0000 by The EH Angle Education and Research Foundation, Inc.

maxillary canine movement into healed or recent first premolar extraction sockets and found that tooth movement was faster at sites of recent extraction. Liou and Huang<sup>11</sup> reported that tooth movement increased from 1 mm/mo to 6.5 mm/3 wk in a study of canine retraction into a socket generated by recent first premolar extraction. In contrast, Diedrich and Wehrbein,<sup>13</sup> in an animal study, found greater tooth retraction velocity into a healed socket than into a recent extraction socket. Samruajbenjakun et al.,<sup>14</sup> in an animal study, reported that corticotomy-assisted orthodontic tooth movement into recent and healed socket sites did not differ. Furthermore, Zubair et al.<sup>12</sup> conducted a clinical randomized controlled trial to compare maxillary canine retraction into healed and recently extracted sites. They reported faster canine retraction into the recent extraction site (mean difference: 0.45 mm between the two sides).

As power chain to close extraction space is placed at the bracket level and not through the center of resistance, tipping of teeth during space closure is inevitable. Greater adjacent tooth tipping has been reported when teeth were moved toward recent extraction sites.<sup>10</sup> The increased tipping on the recent extraction side was explained by the increased movement and the apical repositioning of the center of resistance after adjacent tooth extraction.<sup>10</sup>

Although the previously mentioned studies investigated canine retraction into recent extraction sites, they involved only maxillary canines and none were conducted in the lower jaw. Therefore, this randomized clinical study was undertaken to compare orthodontic retraction of lower canines toward recent vs healed extracted sockets. The objectives of the current study were to investigate and compare width of the extraction space, rate of space closure, and adjacent tooth tipping during orthodontic space closure toward a recent vs healed lower first premolar extraction site using 0.019 × 0.025-inch stainless-steel archwires (SSAW) at different time points.

## MATERIALS AND METHODS

This study was a randomized controlled clinical trial with a split-mouth design. The methods were not changed after trial initiation. The study was reviewed and approved by the Institutional Review Board at Jordan University of Science and Technology/King Abdullah University Hospital (approval number 107/118/2018). This trial was registered at ClinicalTrials.gov with the identifier number NCT04598490. The participants for this study were recruited from patients attending the orthodontic clinic at the postgraduate dental clinics/Jordan University of Science and Technology. A total of 28 subjects who fulfilled the inclusion

**Table 1.** Inclusion and Exclusion Criteria of Participants

Inclusion Criteria	
Age	≥ 16 y
Need for	lower first premolars extraction
Average lower facial height and maxillomandibular plane angle	(22° < MM < 32°)
Good oral hygiene and healthy periodontium	
Exclusion Criteria	
Diseases and medications that were likely to affect bone biology	
Previous orthodontic treatment	
Evidence of bone loss	
Smoking	

criteria were invited to participate in the study. All patients were treated by upper and lower first premolar extractions using fixed appliances (only the lower arch was included in this study). The inclusion and exclusion criteria of the participants in this study are shown in Table 1. Subjects were asked to sign a consent form to participate in the study after the purpose of the intervention was clarified.

## Sample Size

Sample size was calculated using the G\*power 3.1.9 program for power analysis, assuming a medium effect size difference of (0.3) between groups based on a split-mouth study conducted by Zubair et al.<sup>12</sup> They reported a mean rate of 1.17 ± 0.27 mm and 0.75 ± 0.26 mm of canine retraction into recent and healed extraction site groups, respectively. The power analysis yielded a total sample size estimate of 36 teeth (18/group) at a conventional alpha level (0.05) and desired power of 0.95. Assuming an overall attrition rate of 10%, initial recruitment targeted a total of 40 teeth (20/group).

## Randomization

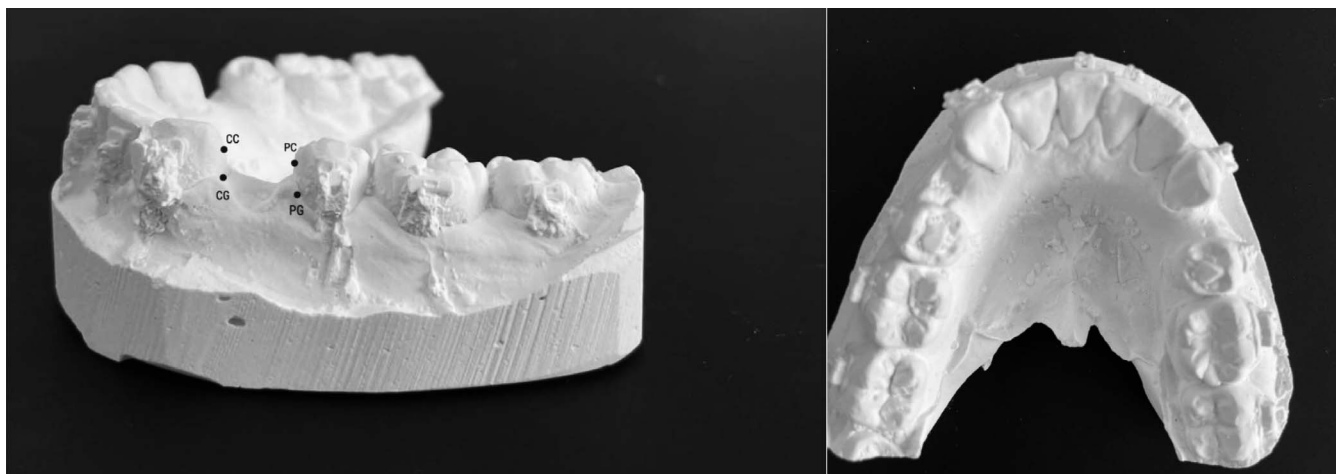
The intervention was randomly allocated by one dental research assistant (S.D.) to either the right or left side using the permuted random block size of 2 with 1:1 allocation ratio. The random sequence for the intervention was concealed in opaque envelopes. Each patient was asked to pick a sealed envelope to assign the intervention to either the right or left side.

## Blinding

It was not possible to blind the patient nor the clinician during treatment. However, the measurements of the dental casts were performed by one research assistant (H.D.) who was blinded to the type of the intervention used/side.

## Intervention

All patients were treated by the same orthodontic postgraduate student (R.A.) using a pre-adjusted



**Figure 1.** Extraction space width measurements; CC indicates canine coronally; CG, canine gingivally; PC, premolar coronally; PG, premolar gingivally.

edgewise fixed appliance (3M Gemini Unitek, Monrovia, CA, USA, 0.022-inch MBT prescription brackets) after the extraction of one right or left lower first premolar (based on the allocated intervention). All lower teeth were included in the appliance, including second molars. Alignment started with a 0.014-inch nickel-titanium (NiTi) archwire, then with a sequence of 0.018-inch, 0.016 × 0.022-inch and 0.019 × 0.025-inch NiTi archwires, before 0.019 × 0.025-inch SSAW was reached and kept for 1 month before space closure. After reaching 0.019 × 0.025-inch SSAW and according to subjects' random allocation, patients were subdivided into two groups:

- Group 1: Right or left lower arch (28 patients). Lower first premolar was extracted before orthodontic treatment (1 week before bond-up) and space closure was carried out into the healed extraction site when 0.019 × 0.025-inch SSAW was reached.
- Group 2: The other side of Group 1 (28 patients). Lower first premolar was extracted when 0.019 × 0.025-inch SSAW was reached, immediately before space closure. Shifting of the midline was prevented by holding the incisors together on the delayed extraction side using long lacebacks.

The same SSAW was used in the lower arch during space closure. Elastomeric power chain from second molar to second molar was used to close lower extraction spaces. Patients were instructed to contact the clinic within 24 hours if any bracket was debonded. The patients were followed up monthly, at which time the elastomeric power chain was replaced with a new one. On each monthly visit, alginate impressions were taken of the lower arch with no archwire in place. Dental casts were then produced in the laboratory on the same day, using orthodontic stone.

## Outcome

*Amount and rate of lower extraction space closure (Figure 1).* Follow-up models of each subject were labeled. A digital caliper was used to measure the width of extraction space on each follow-up model. Two readings (one coronal and one gingival) were obtained from each side. Coronally, space width was measured between two points at the maximum convexity of the lower canine and second premolar. Gingivally, space width was measured between two points on the gingival margin of the canine and second premolar.

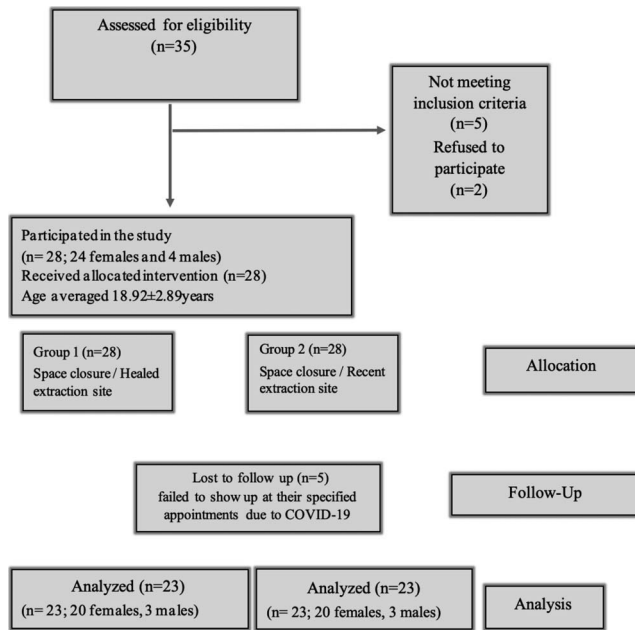
Amount of space closure was calculated by subtracting values at each time point. The rate of space closure was calculated as space closure achieved in mm/month (3 months). The following time points were defined to measure the amount of space closure.

- T1: When reaching 0.019X0.025-inch SSAW and just before space closure.
- T2: First follow-up (1 month from T1).
- T3: Second follow-up (2 months from T1).
- T4: Third follow-up (3 months from T1).

A 3-month end point after initial space closure began was chosen for this study because it was previously demonstrated that the extraction socket will be replaced by provisional matrix and immature bone at 8 weeks postextraction.<sup>15</sup>

## Method Error

Dental casts of 10 randomly selected patients were remeasured after a 2-week interval by the same investigator (H.D.) under the same conditions to determine the measurement error in this study. The method error was calculated using Dahlberg's double determination formu-



CONSORT flow chart showing patients flow during the trial

Figure 2. CONSORT flowchart.

la. The Dahlberg error ranged from 0.05 mm to 0.10 mm for gingival and coronal space width, respectively.

### Statistical Analysis

Statistical analysis was performed with the Statistical Package for Social Science (SPSS) computer software (SPSS 23, SPSS Inc., IBM, Armonk, NY, USA). The Shapiro-Wilk test was used to assess normality of extraction space width data. The values were  $\geq 0.05$ , indicating the data were normally distributed. Intention-to-treat (ITT) analysis was performed. Descriptive statistics were calculated for the measured variables for each group. Within group space width differences at the different time points were determined using repeated-measures analysis of variance. Differences between the two groups were examined using independent *t*-test. *P* value was set at .05.

## RESULTS

### Subjects: Participant Flowchart (Figure 2)

Subjects were recruited between December 2018 and September 2019, with the final data collection in August 2020. Twenty-eight subjects received the planned intervention.

In groups 1 and 2, 28 teeth on each side were to be moved into healed or recent extraction sites. Five patients failed to show up at their specified appointments due to COVID-19. During the analysis stage,

Table 2. Baseline Data for the Subjects Included in the Study<sup>a</sup>

Variable	Mean (SD)
SNA°	85 (1.31)
SNB°	79.2 (1.52)
ANB°	4.0 (0.56)
Ui-MxPA°	116.7 (1.24)
Li-MPA°	102.8 (1.18)
MMPA°	27.8 (4.21)
Lower arch crowding (mm)	3.0 (1.13)
Age (y)	18.92 (2.89)

<sup>a</sup> SD indicates standard deviation.

there were complete records for 23 patients (20 females and three males). The end point of this study was 3 months after initial space closure.

### Baseline Data

Data regarding age and cephalometric analysis of the subjects are listed in Table 2.

### Analyses at Each Time Point

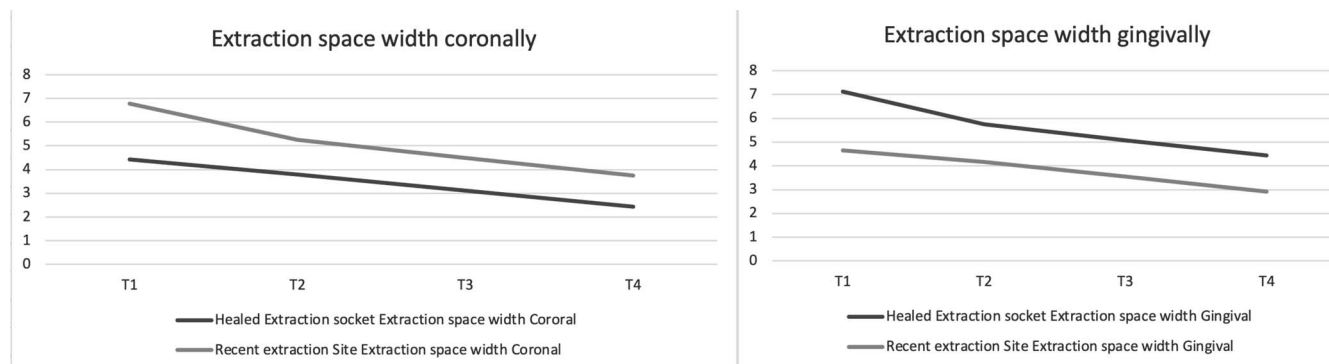
At T2, data from five patients were missing ( $n = 23$ ). Between T2 and T4, none of the subjects had any missing data. During the analysis stage, there were complete data for 23 patients (23 quadrants/group).

### Primary Outcome

*Amount and rate of lower extraction space closure (Figure 3).* Means and standard deviations (SDs) for the extraction space width and the rate of space closure/mo, and within- and between-subject differences at the measured time points, are shown in Tables 3 through 5. In group 1, a total amount of 1.98 mm and 1.75 mm of space closure (coronally and gingivally, respectively) during the period of 3 months was achieved. The rate of space closure was 0.66 mm/mo coronally and 0.58 mm/mo gingivally. In group 2, the total amount of space closure was 3.02 mm coronally and 2.68 mm gingivally with a rate of space closure of 1.01 mm/mo coronally and 0.89 mm/mo gingivally. The differences between the two groups were significant at  $P < .01$ .

During the first month (T1–T2), a significantly greater amount of space closure was measured in group 2 compared to group 1 ( $P < .001$ ). Afterward (T2–T3 and T3–T4), the amount of space closure was similar between the two groups ( $P > .05$ ).

Adjacent tooth tipping during space closure was determined by subtracting the space width coronally from that measured gingivally. Tipping of teeth was detected in both groups (Table 6). However, the differences between the groups was not statistically significant ( $P > .05$ ).



**Figure 3.** Extraction space width at the different time points.

**Table 3.** Means, SDs of Coronal and Gingival Extraction Space Widths and Rate of Space Closure in the Lower Arch for the 2 Studied Groups at Different Time Intervals<sup>a</sup>

Time point	Group 1 (Healed)		Group 2 (Recent)	
	Extraction Space Width/ Coronal, Mean (SD)	Extraction Space Width/ Gingival, Mean (SD)	Extraction Space Width/ Coronal, Mean (SD)	Extraction Space Width/ Gingival, Mean (SD)
T1	4.42 (1.39)	4.66 (1.46)	6.78 (0.81)	7.12 (0.84)
T2	3.79 (1.38)	4.16 (1.49)	5.26 (1.23)	5.74 (1.21)
T3	3.11 (1.32)	3.54 (1.39)	4.50 (1.19)	5.07 (1.25)
T4	2.44 (1.40)	2.91 (1.42)	3.75 (1.26)	4.44 (1.28)
Rate of space closure/mo				
T1–T4	0.66 (0.16)	0.58 (0.17)	1.01 (0.41)	0.89 (0.08)

<sup>a</sup> SD indicates standard deviation.

**Table 4.** Within-Subject Differences of the Coronal and Gingival Extraction Space Widths, *F* Values, SE of the Mean Differences, and Significance in Healed and Recent Extraction Site Groups at the Different Time Points<sup>a</sup>

	Group 1 (Healed)		Group 2 (Recent)	
	Extraction Space Width/ Coronal, Mean (SE)	Extraction Space Width/ Gingival, Mean (SE)	Extraction Space Width/ Coronal, Mean (SE)	Extraction Space Width/ Gingival, Mean (SE)
<i>F</i> value, <i>P</i> value	117.66, 0.000	88.74, 0.000	59.83, 0.000	41.10, 0.000
Diff. T1–T2	-0.62 (0.06)***	-0.50 (0.05)***	-1.51 (0.22)***	-1.38 (0.19)***
Diff. T2–T3	-0.68 (0.06)***	-0.62 (0.07)***	-0.77 (0.09)***	-0.67 (0.08)***
Diff. T3–T4	-0.67 (0.05)***	-0.63 (0.06)***	-0.74 (0.07)***	-0.63 (0.09)***
Diff. T1–T4	-1.98 (0.10)***	-1.75 (0.11)***	-3.02 (0.25)***	-2.68 (0.25)***

<sup>a</sup> CI indicates confidence interval; SE, standard error.

\*\* *P* < .01, \*\*\* *P* < .001.

**Table 5.** Diff. Between the Means of Coronal and Gingival Extraction Space Widths Between the Two Studied Groups, SE of the Mean Differences, 95% CI of Means Diff. and *P* Value at the Different Time Points<sup>a</sup>

Time Points	Group 1 & Group 2		Group 1 & Group 2	
	Extraction Space Width/ Coronal, Mean Diff (SE)	95% C.I. of the Mean Diff.	Extraction Space Width / Gingival, Mean Diff (SE)	95% C.I. of the Mean Diff.
T1	2.36 (0.34)***	1.68 to 3.03	2.46 (0.35)***	1.75 to 3.17
T2	1.47 (0.39)***	0.69 to 2.25	1.58 (0.40)***	0.78 to 2.39
T3	1.38 (0.37)***	0.64 to 2.13	1.53 (0.39)***	0.75 to 2.32
T4	1.32 (0.39)**	0.53 to 2.11	1.53 (0.40)***	0.72 to 2.33
T1–T2	0.89 (0.22)***	-1.34 to -0.44	0.87 (0.19)***	-1.27 to -0.49
T2–T3	0.09 (0.10) NS	-0.28 to 0.11	0.05 (0.10) NS	-0.26 to 0.16
T3–T4	0.07 (0.09) NS	-0.25 to 0.12	0.01 (0.11) NS	-0.23 to 0.22
T1–T4	1.04 (0.28)***	-1.59 to -0.49	0.93 (0.27)***	-1.48 to -0.38
Rate of space closure mm/mo	0.34 (0.09)***	0.16 to 0.53	0.31 (0.10)**	0.13 to 0.50

<sup>a</sup> CI indicates confidence interval; Diff. between the means, difference between the means; NS, not significant; SE of the mean differences, standard error of the mean differences.

\*\* *P* < .01, \*\*\* *P* < .001.

**Table 6.** Mean Coronal and Gingival Extraction Space Width Differences (Tipping), SDs, Diff. Between the Means, SE of the Mean Differences, 95% C.I. and *P* Value for the 2 Studied Groups in the Lower Arch at Different Time Intervals<sup>a</sup>

	Group 1 (Healed), Mean (SD)	Group 2 (Recent), Mean (SD)	Differences Between Groups, Mean (SE)	95% C.I.	<i>P</i> Value
T1 C-G space with difference (mm)	-0.24 (0.17)	-0.34 (0.24)	0.10 (0.06)	-0.22 to 0.03	.116 NS
T2 C-G space with difference (mm)	-0.37 (0.27)	-0.48 (0.34)	0.11 (0.09)	-0.29 to 0.07	.224 NS
T3 C-G space with difference (mm)	-0.42 (0.31)	-0.57 (0.47)	0.15 (0.12)	-0.39 to 0.09	.205 NS
T4 C-G space with difference (mm)	-0.47 (0.39)	-0.69 (0.57)	0.21 (0.15)	-0.51 to 0.08	.157 NS

<sup>a</sup> CI indicates confidence interval; Diff. between the means, difference between the means; NS, not significant; SD, standard deviation; SE of the mean differences, standard error of the mean differences.

## DISCUSSION

It is believed that starting retraction into a extraction site at an early stage results in more rapid tooth movement.<sup>13</sup> Since there is only a thin interdental septum that acts as a separation between thin connective tissue and the tooth, it should move rapidly.<sup>16</sup> In the current study, retraction was initiated immediately after tooth extraction.

In most situations, tooth extraction induces bone resorption, which leads to a reduction of alveolar bone volume. Hammerle et al.<sup>17</sup> reported an average 3.8 mm of horizontal and 1.24 mm of vertical alveolar bone loss 6 months after extraction. In the healed extraction socket, alveolar ridge atrophy tends to occur, which may obstruct the tooth movement passing through this defect. One suggested method to increase efficiency of space closure is to move teeth into a freshly extracted socket.<sup>10,16</sup> All previously studies conducted to compare the rate of tooth movement between recent and healed extraction sites were performed in the maxillary arch. It was demonstrated that maxillary canines had a 25% greater rate of tooth movement than mandibular canines.<sup>18</sup> Differences in bone density and rate of remodeling between the maxilla and mandible have been suggested to explain why there is slower tooth movement in the lower arch.<sup>19</sup> Only one previous study was conducted in the lower arch; it was not a randomized clinical trial and lower canine retraction was carried out using frictionless loop mechanics.<sup>20</sup> Therefore, this randomized controlled clinical study was carried out.

A split-mouth design was adopted in this study to reduce the biological variability between subjects.<sup>21</sup> The timing for lower first premolar extraction was planned to be either before or after the leveling phase. At T1, the width of the extraction site was different between the two sides due to space loss during the alignment phase. Shifting of the midline was prevented by holding the incisors together on the delayed extraction side using long lacebacks.

It is believed that tooth movement and biological responses are slower in adults compared to adolescents.<sup>22</sup> In the current study, all selected patients were

over 18 years of age because a higher rate of tooth movement was reported in patients younger than 16.<sup>22</sup>

In this study, extraction space was measured coronally and gingivally to detect tipping of the canine during retraction using the most prominent points on the distal surface of the lower canine and the most mesial surface of the premolar to obtain a coronal measurement. This was different than reference points used by others.<sup>23,24</sup> Miles<sup>23</sup> measured tooth movement during space closure using the mesial surface of the mesial wing of the premolar bracket and the distal surface of the distal wing of the canine bracket as reference points, which might have been imprecise due to variations in bracket placement during bonding. Dixon et al.<sup>24</sup> used the cusp tip of the canine and the buccal groove of the first permanent molar as reference points and ignored the amount of space closed by tipping of the teeth.

In the current study, although space closure was carried out on a rigid rectangular SSAW to achieve maximum bodily movement,<sup>25</sup> slight tipping of adjacent teeth was evident in both extraction site groups. Orthodontic space closure was carried out using elastomeric chain applied far from the center of resistance where space closure was achieved through a succession of tipping and uprighting of teeth. In addition, the archwire/bracket slot play allowed teeth to tip during space closure. These reasons may explain the tipping of adjacent teeth observed during space closure. The coronal-gingival space width difference ranged from 0.10 mm to 0.21 mm, indicating that mainly bodily tooth movement occurred with very minimal tipping. The groups showed similar adjacent tooth tipping during space closure. This was in disagreement with Häslar et al.,<sup>10</sup> who reported more tipping on the recent extraction side than on the healed extraction side.

A greater amount of tooth movement was noted when teeth were moved into a recent extraction site compared to a healed extraction socket. In addition, the rate of space closure during the 3-month study period was less in the healed extraction site. In the current study, the amount of space closure into a healed extraction socket averaged 2 mm, whereas it

averaged 3 mm into a recent extraction socket. This finding was in agreement with previously reported studies.<sup>10–12,16</sup> Liou and Huang<sup>11</sup> reported that tooth movement increased from 1 mm/mo to 6.5 mm/3 wk in a study of canine retraction into a recent first premolar extraction socket using an intraoral distraction device.

Kalra et al.<sup>20</sup> showed that, during a study period of 90 days, the canine in the mandibular arch was retracted 1.44 mm into a recent extraction site. In that study, canine retraction was performed by frictionless mechanics using a composite T-Loop, which may explain the difference in the amount of canine retraction compared to the current study. Zubair et al.<sup>12</sup> found that, canines moved 0.75 mm and 1.17 mm toward the healed and recent extraction sites, respectively, 1 month after activation. This was similar to the rate of space closure measured per month in the current study.

Increased rate of space closure in the recent extraction site group may have been related to the tissue inflammatory response immediately after extraction. In addition, the phenomenon of regional acceleration (RAP) could explain the rapid tooth movement detected, as it is known to peak at 1–2 months.<sup>26</sup> Additionally, the less calcified bone surrounding the recent extraction socket compared to that of the healed extraction site may have been another reason for the faster rate of space closure.<sup>13</sup>

In the current study, the amount of space closure was greater in the recent extraction group only during the first month of retraction. Later, it was similar between the two groups. This was consistent with the phenomenon of RAP, which usually lasts for 1–2 months.<sup>6</sup> Also, the formation of mature and more calcified bone 1 month after extraction, where most trabecular bone forms by 38 days after extraction, may explain this similarity after 2 months.<sup>13</sup> On the other hand, findings of the current study were in disagreement with Diedrich and Wehrbein,<sup>13</sup> who reported greater tooth movement into a healed socket compared to a fresh socket and with Samruajbenjakun,<sup>14</sup> who reported similar rates of tooth movement between healed and recent extraction sockets.

Limitations of the current study included a high female-to-male ratio, and the fact that canine retraction was not carried out individually. In the current study, all anterior teeth were retracted together, which may have affected the amount of teeth movement and resulted in a crossover effect. Additionally, use of an elastomeric powerchain with more rapid force degradation compared to a NiTi coil spring, which produces light continuous force, may have affected results.

## Generalizability

Extraction of premolars immediately before space closure using 0.019 × 0.025 SSAW increased the rate of space closure with minimal tipping.

## CONCLUSIONS

- Amount and rate of space closure in the lower arch toward a recent extraction site was greater than that toward a healed extraction socket, with similar amounts of tipping observed in both groups.

## ACKNOWLEDGMENTS

This study was supported by the Deanship of Research/Jordan University of Science and Technology (Grant number 53/2019).

## REFERENCES

1. Fisher MA, Wenger RM, Hans MG. Pretreatment characteristics associated with orthodontic treatment duration. *Am J Orthod Dentofacial Orthop.* 2010;137:178–186.
2. Mavreas D, Athanasiou AE. Factors affecting the duration of orthodontic treatment: a systematic review. *Eur J Orthod.* 2008;30:386–395.
3. Moresca R. Orthodontic treatment time: can it be shortened? *Dental Press J Orthod.* 2018;23:90–105.
4. Tsihaki A, Chin SY, Pandis N, Fleming PS. How long does treatment with fixed orthodontic appliances last? A systematic review. *Am J Orthod Dentofacial Orthop.* 2016;149(3):308–318.
5. Abbas NH, Sabet NE, Hassan IT. Evaluation of corticotomy facilitated orthodontics and piezocision in rapid canine retraction. *Am J Orthod Dentofacial Orthop.* 2016;149:473–480.
6. Talic NF. Adverse effects of orthodontic treatment: a clinical perspective. *Saudi Dent J.* 2011;23:55–59.
7. López D, Benjumea J. Alveolar growth stimulated by periodontally accelerated osteogenic orthodontics. *J Dent Oral Health.* 2017;3:2–7.
8. Uribe F, Padala S, Allareddy V, Nanda R. Patients', parents', and orthodontists' perceptions of the need for and costs of additional procedures to reduce treatment time. *Am J Orthod Dentofacial Orthop.* 2014;145:S65–73.
9. Rosvall MD, Fields HW, Ziuchkovski J, Rosenstiel SF, Johnston WM. Attractiveness, acceptability, and value of orthodontic appliances. *Am J Orthod Dentofacial Orthop.* 2009;135: 276–277.
10. Häsler R, Schmid G, Ingervall B, Gebauer U. A clinical comparison of the rate of maxillary canine retraction into healed and recent extraction sites—a pilot study. *Eur J Orthod.* 1997;19:711–719.
11. Liou EJ, Huang CS. Rapid canine retraction through distraction of the periodontal ligament. *Am J Orthod Dentofacial Orthop.* 1998;114:372–382.
12. Zubair NR, Ehsan AA, Sakrani H. Comparison of mean canine retraction between healed and recently extracted site: a single center, randomized control trial. *APOS Trends Orthod.* 2021;11:132–139.

13. Diedrich P, Wehrbein H. Orthodontic retraction into recent and healed extraction sites. A histologic study. *J Orofac Orthop*. 1997;58:90–99.
14. Samruajbenjakun B, Kanokpongsak K, Leethanakul C. Comparison of clinical and histological characteristics of orthodontic tooth movement into recent and healed extraction sites combined with corticotomy in rats. *Korean J Orthod*. 2018;48:405.
15. Cohen N, Cohen-Lévy J. Healing processes following tooth extraction in orthodontic cases. *J Dentofacial Anom Orthod*. 2014;17:304.
16. Murphey WH. Oxytetracycline microfluorescent comparison of orthodontic retraction into recent and healed extraction sites. *Am J Orthod*. 1970;58:215–239.
17. Hammerle CH, Araujo MG, Simion M, Osteology Consensus G. Evidence-based knowledge on the biology and treatment of extraction sockets. *Clin Oral Implants Res*. 2012;23:80–82.
18. da C Monini A, Gandini LG Jr, Vianna AP, Martins RP, Jacob HB. Tooth movement rate and anchorage lost during canine retraction: a maxillary and mandibular comparison. *Angle Orthod*. 2019;89(4):559–565.
19. Park HS, Lee YJ, Jeong SH, Kwon TG. Density of the alveolar and basal bones of the maxilla and the mandible. *Am J Orthod Dentofacial Orthop*. 2008;133:30–37.
20. Kalra A, Jaggi N, Bansal M, et al. Comparison of rate of canine retraction into recent extraction site with and without gingival fiberotomy: a clinical study. *J Contemp Dent Pract*. 2013;14:419–426.
21. Pandis N, Walsh T, Polychronopoulou A, Katsaros C, Eliades T. Split-mouth designs in orthodontics: an overview with applications to orthodontic clinical trials. *Euro J Orthod*. 2013;35:783–789.
22. Giannopoulou C, Dudic A, Pandis N, Kiliaridis S. Slow and fast orthodontic tooth movement: an experimental study on humans. *Eur J Orthod*. 2015;38:404–408.
23. Miles PG. Self-ligating vs conventional twin brackets during en-masse space closure with sliding mechanics. *Am J Orthod Dentofacial Orthop*. 2007;132:223–225.
24. Dixon V, Read MJ, O'Brien KD, Worthington HV, Mandall NA. A randomized clinical trial to compare three methods of orthodontic space closure. *J Orthod*. 2002;29:31–36.
25. Tanne K, Koenig HA, Burstone CJ. Moment to force ratios and the center of rotation. *Am J Orthod Dentofacial Orthop*. 1988;94:426–431.
26. Frost HM. The biology of fracture healing, an overview for clinicians, Part II. *Clin Orthop Relat Res*. 1989;248:294–309.