

A Wolf in Sheep's Clothing: Systemic Immune Activation Post Immunotherapy

Crescens Tiu,¹ Rajiv Shinde,¹ Abhijit Pal,¹ Andrea Biondo,¹ Alex Lee,¹ Nina Tunariu,¹ Shaman Jhanji,² Vimal Grover,² Kate Tatham,² Pascale Gruber,² Udai Banerji,¹ Johann S. De Bono,¹ Emma Nicholson,¹ Anna R. Minchom,¹ Juanita S. Lopez¹

¹Drug Development Unit, The Royal Marsden Hospital and The Institute of Cancer Research, Sutton, United Kingdom

²Critical Care Unit, The Royal Marsden Hospital, Sutton, United Kingdom

Address correspondence to Juanita Lopez (juanita.lopez@icr.ac.uk).

Crescens Tiu and Rajiv Shinde contributed equally to this work as first authors.

Source of Support: None. Conflict of Interest: None.

Received: Apr 23, 2021; Revision Received: Jul 8, 2021; Accepted: Jul 9, 2021

Tiu C, Shinde R, Pal A, et al. A wolf in sheep's clothing: systemic immune activation post immunotherapy. *J Immunother Precis Oncol.* 2021; 4:189–195. DOI: 10.36401/JIPO-21-9.

This work is published under a CC-BY-NC-ND 4.0 International License.

ABSTRACT

Introduction: Immune checkpoint inhibitors (ICIs) are increasingly a standard of care for many cancers; these agents can result in immune-related adverse events (irAEs) including fever, which is common but can rarely be associated with systemic immune activation (SIA or acquired HLH). **Methods:** All consecutive patients receiving ICIs in the Drug Development Unit of the Royal Marsden Hospital between May 2014 and November 2019 were retrospectively reviewed. Patients with fever $\geq 38^\circ\text{C}$ or chills/rigors (without fever) ≤ 6 weeks of commencing ICIs were identified for clinical data collection. **Results:** Three patients met diagnostic criteria for SIA/HLH with median time to onset of symptoms of 10 days. We describe the clinical evolution, treatment used, and outcomes for these patients. High-dose steroids are used first-line with other treatments, such as tocilizumab, immunoglobulin and therapeutic plasmapheresis can be considered for steroid-refractory SIA/HLH. **Conclusion:** SIA/HLH post ICI is a rare but a potentially fatal irAE that presents with fever and a constellation of nonspecific symptoms. Early recognition and timely treatment are key to improving outcomes.

Keywords: immune checkpoint inhibitor, immune-related adverse events, toxicity, systemic immune activation, HLH, fever

INTRODUCTION

Immune checkpoint inhibitors (ICIs) have been paradigm shifting for numerous cancers, and increasingly incorporated into standard of care. Anti-programmed cell death (PD)-1/PD-ligand (L)1 agents now serve as the backbone of the expanding approaches in immunoncology with more than 1000 recruiting combination clinical trials.^[1]

Their widespread use has seen increasing awareness of significant immune-related adverse effects (irAEs). Fever can be the sole manifestation of an adverse drug reaction in 3% to 5% of patients,^[2] but also may be the harbinger of a rarer but more serious and potentially fatal side effect known as systemic immune activation (SIA) or hemophagocytic lymphohistiocytosis (HLH).^[3–6]

SIA is a manifestation of severe cytokine release syndrome (CRS), most commonly presenting with high-grade fevers, skin rash, enlarged liver or spleen,

lymphadenopathy, dyspnea, easy bruising or bleeding, and elevated transaminases. Patients also can present with neurological symptoms, such as confusion, seizures, ataxia, dysphasia, and mental state changes. Critically, these symptoms evolve rapidly, are difficult to differentiate from sepsis or other mimicking conditions, and can be life-threatening without prompt and aggressive treatment.^[7]

SIA/HLH is caused by excessive activation of lymphocytes and macrophages that produce high levels of cytokines^[8] (Fig. 1A). Familial or inherited forms of HLH are rare in adulthood^[9] and mostly triggered by a variety of conditions, including infection, autoimmune diseases, malignancies, drugs, and metabolic triggers, and also can develop post-autologous and allogeneic stem cell transplantation. Mechanisms in acquired HLH are diverse, with some patients being immunosuppressed (which may result in the inability to cope with an infectious trigger, thus leading to HLH) and others

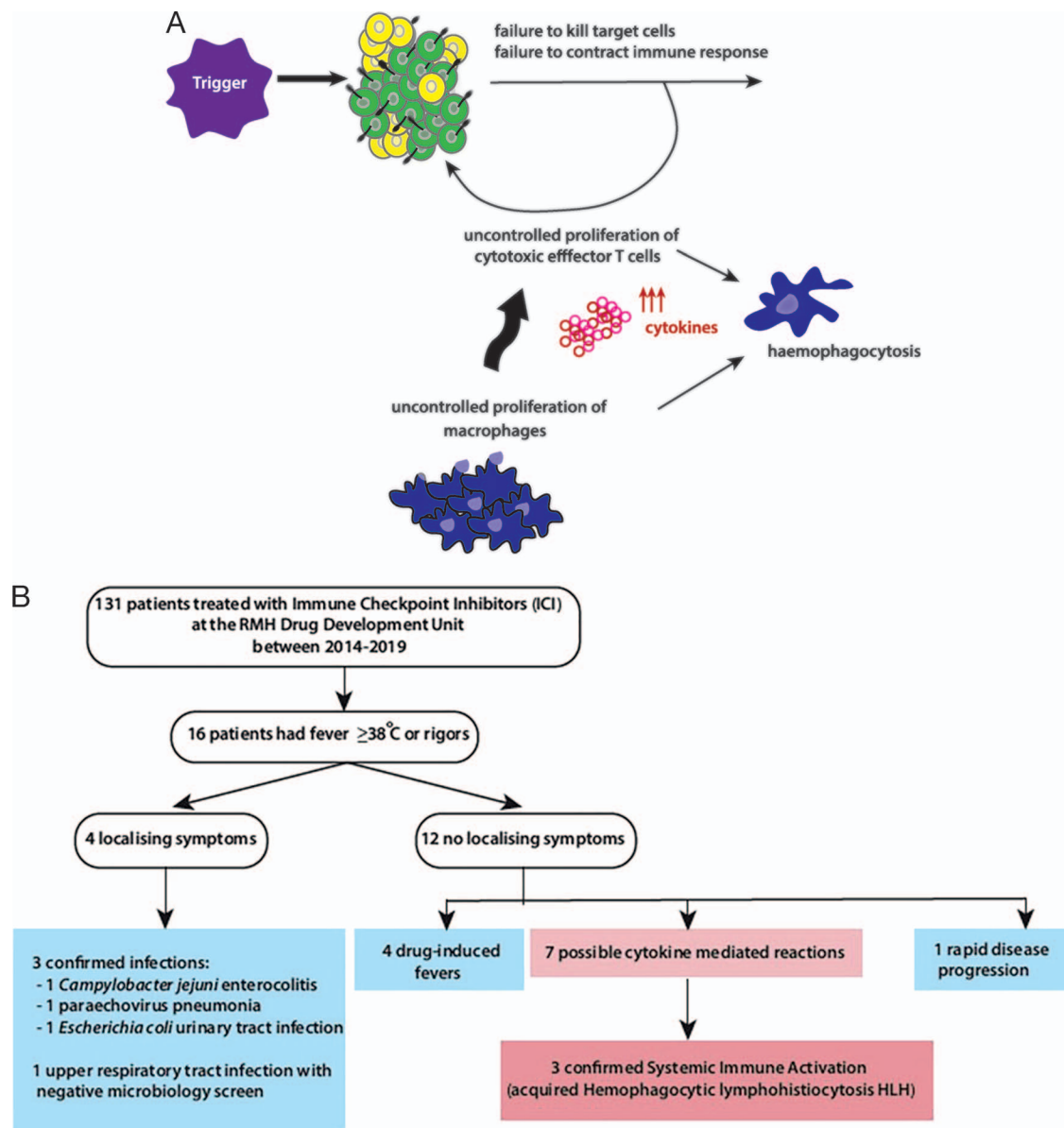


Figure 1. (A) The pathogenesis of HLH. Known triggers include infection, malignancy, and autoimmune diseases, but also ICI therapies. Unchecked stimulation of lymphocytes (green cells indicating CD8⁺ effector cells and yellow cells indicate regulatory CD4⁺ cells) leads to hypercytokinemia, predominantly driven by interferon- γ leading to clinical symptoms. (B) CONSORT diagram demonstrating selection of patients treated with ICIs who experienced fever $\geq 38^{\circ}\text{C}$ or chills without fever within 6 weeks of first ICI dose and attribution of causality of fever/chills. Sixteen patients with fevers were identified, of whom four had localizing symptoms (three of whom were confirmed as having fevers due to infection with positive microbiology). Of the 12 patients without localizing symptoms, four were deemed by exclusion to have an acute drug reaction, and one patient had fevers due to rapid disease progression. Seven patients were suspected to have a cytokine-mediated reaction, for which three patients met diagnostic criteria for SIA/HLH. HLH, hemophagocytic lymphohistiocytosis; ICIs, immune checkpoint inhibitors; SIA, systemic immune activation.

having a clear overactivation of their immune systems resulting in non-antigen-specific stimulation of innate immunity.^[10] In all cases however, hyperelevated levels of proinflammatory cytokines are seen together with elevated levels of soluble CD25 (sCD25) reflecting excessive T-cell activation.^[11] It is not clear whether hemophagocytosis itself plays a pathogenic, bystander, or immunoregulatory role in HLH, and it is not always seen at initial presentation, but often can be detected on repeated examination^[12] (Fig. 1A).

We comprehensively reviewed the incidence of fevers in patients treated with ICIs in a dedicated early-phase trials unit. We discuss in detail three case vignettes of

patients with confirmed SIA/HLH, aiming to draw attention to this rare phenomenon that is likely to become more common with the increasing use of immune-modulatory treatments for cancer. We discuss the diagnostic dilemmas and the treatment paradigms that may be useful for clinicians in managing patients with cancer presenting with fever, being mindful not to miss this “wolf in sheep’s clothing.”

METHODS

After institutional review board approval, patients with metastatic solid tumors who received ICIs (anti-

Table 1. Baseline demographics of patients with fever/chills < 6 weeks from first ICI dose ($N = 16$)

	n (%)
Sex	
Male	7 (44)
Female	9 (56)
Age, median (range), y	61.5 (41–79)
Tumor type	
Bladder	3 (19)
Breast	4 (25)
Colorectal cancer	3 (19)
Non-small-cell lung cancer	4 (25)
Mesothelioma	1 (6)
Ovary	1 (6)
ICI received	
Anti-PD-L1 combination	8 (50)
Anti-PD-L1 only	4 (25)
Anti-PD-1 combination	4 (25)

ICI: immune checkpoint inhibitor; ICI: immune checkpoint inhibitor; PD-L1: programmed death ligand 1; PD-1: programmed death-1.

PD-1 or anti-PD-L1) either alone or in combination with other agents on an experimental phase 1 trial from May 2014 to November 2019 at the Drug Development Unit of the Royal Marsden Hospital were identified from the trials database and reviewed retrospectively. All patients provided trial-specific informed consent.

The following clinical data were collected from electronic hospital records: patient demographics; occurrence of fever $\geq 38^\circ\text{C}$ or symptoms of chills or rigors (without fever) within 6 weeks from first dose of ICI; time to fever onset; real-time fever grade (G) per Common Terminology Criteria for Adverse Events, version 5.0 (US National Cancer Institute); investigations as to the cause of the fever, including septic screen, initial ferritin levels and serial changes; working diagnosis for cause of fever; treatment received; drug rechallenge, and fever recurrence. Patients who fulfilled the diagnostic criteria for SIA/HLH per the HLH-2004 algorithm and Hejblum criteria (HScore)^[13,14] (Table 2) were identified and selected for detailed analysis.

RESULTS

Of 131 patients who received ICI, 16 (12%) had fever $\geq 38^\circ\text{C}$ or chills/rigors within 6 weeks of the first treatment dose; 4 (25%) of 16 received monotherapy ICI, whereas the rest had combination with another trial drug (Table 1; Fig. 1B). Attribution of causality of fever was determined by the investigator based on the full set of available data, including biochemical, hematological, immunological, microbiological, imaging test results, and clinical evolution (Supplemental Fig. S1, available online). Three patients fulfilled diagnostic criteria for SIA/HLH per the HLH-2004 algorithm and Hejblum criteria (HScore) (Table 2) and all had initial fevers commencing 10–11 days post first ICI dose (Supplemental Fig. S1).

Case Vignette 1: Patient A

A 59-year-old woman with ALK/ROS-1/PD-L1-negative, epidermal growth factor receptor wild type, metastatic non-small-cell lung cancer was treated with anti-PD-L1 ICI. Previously treatment included one line of platinum-based chemotherapy. Other past medical history included hypertension and lumpectomy for a benign left-sided breast tumor > 20 years earlier. On day 11 after the first dose of ICI, she presented with G2 fever ($> 39^\circ\text{C}$), with rigors without any localizing symptomatology. She was treated empirically with broad-spectrum intravenous (IV) antibiotics. Microbiological screens were negative, and no cause was found on imaging. Abnormalities on blood tests included G3 lymphopenia, G1 thrombocytopenia, raised lactose dehydrogenase (LDH), rising transaminases up to G2, raised triglycerides and highly elevated ferritin (> 7500 ng/mL), and early changes of hemophagocytosis in bone biopsy. Methylprednisolone 2 mg/kg, with proton pump inhibitor (PPI) cover was commenced 4 days following the first occurrence of fever. Fevers and all symptoms resolved within 24 hours of starting steroids (Fig. 2A).

Case Vignette 2: Patient B

A 42-year-old woman with triple-negative metastatic breast cancer was enrolled into a phase I clinical trial and treated with a combination of a novel agent and anti-PD-L1 ICI. Previous cancer treatment included four lines of chemotherapy in the metastatic setting with no other significant past medical history. On day 11 after the first dose of ICI, she presented with G2 fever and G1 erythematous maculo-papular skin rash. She received empiric broad-spectrum IV antibiotics with no clear source identified on microbiological screening and imaging. Abnormalities on blood tests included G2 thrombocytopenia, raised LDH, G1 transaminitis, and raised triglycerides. Initial ferritin level was normal but rose to > 3000 ng/mL 3 days from the first fever. Methylprednisolone 1 mg/kg with PPI cover was commenced with initial improvement in fever, but the subsequent development of G1 dyspnea without hypoxia. High-resolution computed tomography (CT) chest imaging showed evolving thickening of septal lines suggestive of interstitial edema, but electrocardiogram, cardiac biomarkers, and echocardiogram were normal. Tocilizumab 8 mg/kg was given with rapid resolution of her fever, skin rash, and a marked improvement in her respiratory symptoms (Fig. 2B).

Case Vignette 3: Patient C

A 67-year-old man with low-volume metastatic bladder cancer was enrolled onto a phase I clinical trial and treated with combination anti-PD-L1. Past medical history included hypertension and hypercholesterolemia. Ten days after receiving the first dose of the ICI drug combination, he presented with G3 fever, with rigors. He was given empiric broad-spectrum IV antibiotics. No infective cause was identified on septic

Table 2. How the three patients described in the case series met diagnostic criteria for SIA/HLH per HLH-2004 criteria and HScore^[13,14]

	Patient A	Patient B	Patient C
HLH-2004 Criteria			
Fever	✓	✓	✓
Splenomegaly	Normal	Normal	✓
Cytopenias (in ≥ 2 lineages)	✓	✓	✓
Hypertriglyceridemia and/or hypofibrinogenemia	✓	✓	✓
Hemophagocytosis in bone marrow or spleen or lymph nodes	✓	Not tested	✓
Low or absent NK cell activity	Not tested	Not tested	Not tested
Ferritin ≥ 500 mcg/L	✓	✓	✓
Soluble CD25 (i.e., IL-2 receptor) ≥ 2400 U/L	Not tested	Not tested	✓
Total score (5 out of 8 is diagnostic)	5	4	7
H Score			
Known underlying immunosuppression	No (0 points)	No (0 points)	No (0 points)
Maximal temperature:	> 39.4°C (49 points)	> 39.4°C (49 points)	> 39.4°C (49 points)
Organomegaly	No (0 points)	No (0 points)	Splenomegaly (23 points)
Number of cytopenias	2 lineages (24 points)	2 lineages (24 points)	3 lineages (34 points)
↑ Ferritin (ng/mL)	> 6000 (50 points)	2000–6000 (35 points)	> 6000 (50 points)
↑ Triglyceride (mmol/L)	1.5–4 (44 points)	1.5–4 (44 points)	> 4 mmol/L (64 points)
↓ Fibrinogen (g/L)	≤ 2.5 (30 points)	≤ 2.5 (30 points)	≤ 2.5 (30 points)
↑ AST (U/L)	≥ 30 (19 points)	≥ 30 (19 points)	≥ 30 (19 points)
Hemophagocytosis features on bone aspirate	Yes (35 points)	Not tested	Yes (35 points)
Total points (H Score)	251 points	201 points	304 points
Probability of having HLH	> 99%	88%	> 99%
Genetic predisposition	None*	Not tested	None*

✓ indicates presence of criteria; ↑: elevated; ↓: low; SIA: systemic immune activation; HLH, hemophagocytic lymphohistiocytosis; NK: natural killer; IL-2: interleukin-2; AST: aspartate aminotransferase.

*Germline genetic testing was undertaken using a next generation sequencing panel of 71 genes associated with primary immunodeficiency disorders including all coding bases of the *PRF1*, *STXBP2*, *STX11*, and *UNC13D* genes that are associated with primary HLH. Patient A and Patient C did not have any detected germline predisposition on this panel.

screening and imaging. Mild cytopenia (G1 thrombocytopenia, G2 lymphopenia, etc.) and elevated ferritin level (4000 ng/mL) prompted an early suspicion of HLH and the initiation of high-dose methylprednisolone at a dosage of 1 g/kg per day. Over the next 24 hours, the patient deteriorated, with type 2 respiratory failure requiring intubation and admission to intensive care. Seven (out of eight) HLH diagnostic criteria were met, including hemophagocytosis in a bone biopsy, with a high H score suggesting > 99% probability of having HLH (Figs. 2C and D; Table 2). Serial cytokines were also substantially elevated (including interleukin [IL]-1, IL-6, IL-8, IL-10, interferon- γ , and tumor necrosis factor [TNF]- α). All microbiological results, including full viral profile (Epstein-Barr virus [EBV]; adenovirus; cytomegalovirus [CMV]; herpes simplex virus; human herpes viruses (HHV) 6, 7, and 8; John Cunningham virus; varicella zoster virus; enterovirus, and respiratory viruses [influenza A/B, metapneumovirus, parainfluenza, respiratory syncytial virus]) and *Pneumocystis jirovecii* tests, were negative. CT scan did not reveal an underlying focus of infection. In view of these findings, IL-6 blockade with tocilizumab 8 mg/kg (2 doses 24 hours apart) was commenced followed by the addition of a single dose of siltuximab of 11 mg/kg and daily anakinra 200 mg (11 doses given in total). Despite aggressive cytokine blockade, fevers and ventilatory requirements persisted with worsening cytopenias. Despite transient resolution of

these fevers being seen after continuous veno-venous hemofiltration initiated on day 23, these fevers rebounded as soon as this was interrupted. Given the known long half-life of ICIs (20–30 days),^[15–16] therapeutic plasma exchange together with IV immunoglobulin at a dosage of 40 g per day (2 doses given on consecutive days) was initiated on the 13th day of his intensive care admission; these steps were an attempt to rapidly remove any circulating drug that may be continuing to trigger this ongoing reaction. This resulted in a rapid resolution of the patient's temperature, concomitant recovery of the abnormal blood parameters, and successful weaning from his ventilation and inotropic support requirement over subsequent days (Fig. 2C). The patient is now rehabilitating following his long course on intensive care.

DISCUSSION

SIA, or secondary HLH, is rare adverse drug reaction and our single-center experience with three cases identified of 131 patients (prevalence of 2.2%) treated with ICIs in our early-phase trials unit raises the question of whether it is in fact more prevalent than previously reported. The largest database recording prevalence is the World Health Organization (WHO) Vigibase, which reported 38 cases of SIA/HLH of 49,883 ICI-related adverse drug reactions observed in routine clinical use

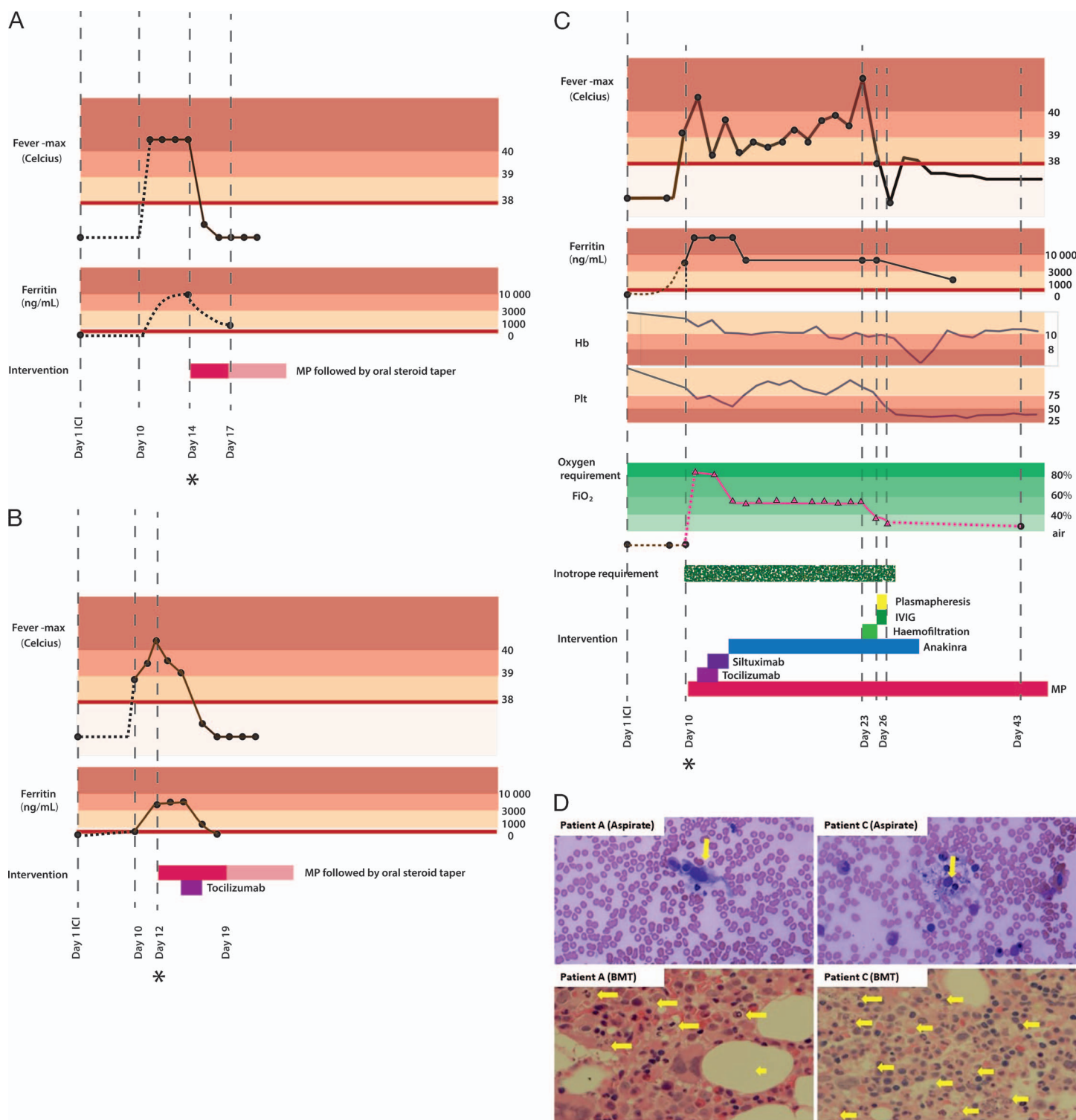


Figure 2. (A–C) Clinical course of three patients who confirmed SIA. Maximum temperature and ferritin levels are plotted against time from onset of ICI therapy commencement. Color bars indicate CTCAE grading (cream, Grade 1; pink, Grade 2; salmon, Grade 3+), with the thick red line indicating threshold of meeting major diagnostic criteria for SIA. Oxygen requirements have been indicated per level of FiO₂ support required, with triangles representing ventilation. (A) Patient A: steroid-responsive SIA. (B) Patient B: steroid- and Tocilizumab-responsive SIA. (C) Patient C: steroid-refractory SIA. (D) Morphological features of HLH seen in patient A taken on day 4 post onset of G2 fever (top left), which are less pronounced compared with the features seen in patient C taken on day 14 post onset of fever (top right). Bone marrow aspirate (Asp) for patients A (i) and C (iii) demonstrates hemophagocytic macrophages containing erythrocytes, granulocytes, and cellular debris. Bone marrow trephine (BMT) for patient A (ii) and patient C (iv) showing hemophagocytic cells with abundant clear cytoplasm containing cellular debris. CTCAE: Common Terminology Criteria for Adverse Events; MP: methylprednisolone; SIA, systemic immune activation; ICIs, immune checkpoint inhibitors; HLH, hemophagocytic lymphohistiocytosis; IVIG, intravenous immunoglobulin.

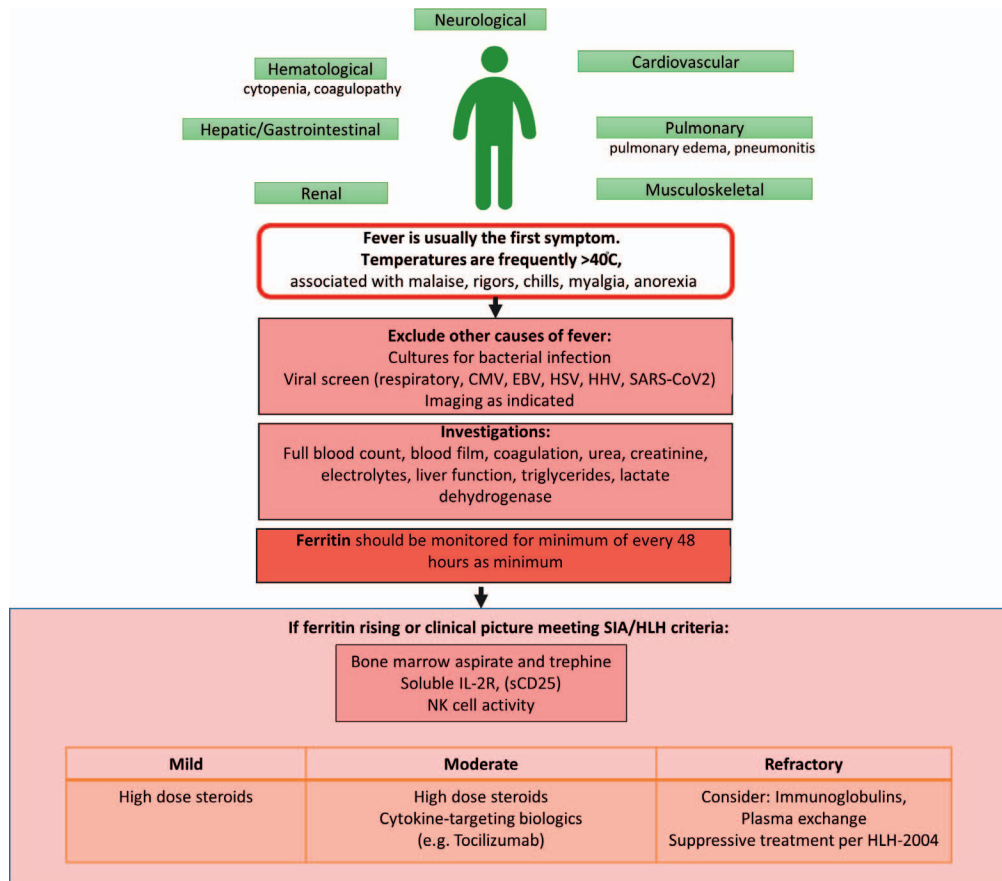


Figure 3. Suggested clinical algorithm for managing systemic immune activation or acquired HLH in patients with cancer on immune checkpoint inhibitor therapy. Patients with mild symptoms could be treated with high-dose steroids with cytokine targeting biologics added for more severe symptoms. Patients with refractory symptoms could be considered for immunoglobulin or plasma exchange before the institution of etoposide-based chemotherapy combinations per the HLH-2004 protocol. HLH, hemophagocytic lymphohistiocytosis.

of ICI as of Sept 30, 2018^[17] (prevalence of 0.0007%). However, this is likely to increase in incidence with the increasing use of ICI therapies, and their combinations with other more complex immune-modulatory therapeutic strategies.

The poor outcome of secondary HLH has been attributed to a lack of awareness and missed diagnosis of this condition in adults,^[18] with fever easily confused as being infective in origin or cancer-associated.^[19] Our three patients had low-volume malignancy with no febrile symptoms before commencing on ICI and none had localizing infective symptoms when first presenting with $G \geq 2$ fever. A rigorous workup in each case excluded infection and a high or rising hyperferritinemia prompted the early consideration of SIA/HLH.^[13,14] The median time to onset of initial fever from commencement of ICI in our patients was 10 days, consistent with case reports in the WHO global database of suspected adverse drug reaction; this time suggests that it is in this early period post initiation of ICIs that clinicians should be most vigilant in considering the possibility of a systemic immune reaction. Viral infections, classically EBV and CMV,^[7] but also severe acute respiratory syndrome coronavirus 2 (SARS-CoV-2),^[20] are also known triggers

themselves of secondary HLH, but it is unknown if these infections in patients with cancer who have received ICIs can *co-trigger* SIA/HLH. All three patients described had extensive microbiological screening, which did not reveal an infectious co-trigger. No germline predisposition genes were identified in our patients (Table 2).

Suppression of hyperinflammation with corticosteroids is the mainstay of first-line treatment.^[21] Second-line treatment with cytokine targeting biologics, including inhibitors of IL-6 (tocilizumab), IL-1 β (anakinra, rilonacept, canakinumab), and TNF- α (etanercept, infliximab, adalimumab), have been particularly applied in secondary HLH.^[22-24] The early use of tocilizumab in combination with steroids has been recommended by a chimeric antigen receptor (CAR) T-cell-associated toxicity working group for suspected HLH post CAR T-cell therapies.^[25] Chemotherapeutic combinations according to the pediatric HLH-94 protocol^[26] have been used in adults with acquired HLH with limited success, thought mainly due to the comorbidities that render these patients vulnerable to end-organ damage.^[27] Chemotherapy was deemed too high risk for our patient C, who was cytopenic and ventilator-dependent. The use of renal replacement therapy in intensive care to optimize his fluid balance

might have improved hypercytokinemia but was short-lived. Given the long half-life in tissue of ICIs (up to 30+ days,^[15,16] we initiated plasma exchange given together with IV immunoglobulins in an attempt to extract any remaining drug that may be continuing to trigger an ongoing cytokine storm. Rapidly following the plasma exchange, patient C's temperature normalized with improvement of blood parameters and respiratory requirements. To our knowledge, this is the first report of plasma exchange being used to treat steroid- and anti-cytokine-refractory SIA/HLH effectively, thereby avoiding the use of myelosuppressive chemotherapy. Our proposed clinical algorithm for the early diagnosis and management of SIA/HLH in patients with cancer receiving ICIs is summarized in Figure 3.

CONCLUSION

SIA/HLH post ICI is a rare but a potentially fatal irAE. With the increasing use of immunotherapy, early recognition and timely treatment are essential to limit morbidity and mortality.

Supplemental Material

Supplemental data are available online with the article.

References

1. Tang J, Pearce L, O'Donnell-Tormey J, et al. Trends in the global immuno-oncology landscape. *Nat Rev Drug Discov*. 2018;17:783–784.
2. Tabor PA. Drug-induced fever. *Drug Intell Clin Pharm*. 1986;20:413–420.
3. Sadaat M, Jang S. Hemophagocytic lymphohistiocytosis with immunotherapy: brief review and case report. *J Immunother Cancer*. 2018;6:49.
4. Al-Samkari H, Snyder GD, Nikiforow S, et al. Haemophagocytic lymphohistiocytosis complicating pembrolizumab treatment for metastatic breast cancer in a patient with the PRF1A91V gene polymorphism. *J Med Genet*. 2019;56:39–42.
5. Akagi Y, Awano N, Inomata M, et al. Hemophagocytic lymphohistiocytosis in a patient with rheumatoid arthritis on pembrolizumab for lung adenocarcinoma. *Intern Med*. 2020;59:1075–1080.
6. Satzger I, Ivanyi P, Langer F, et al. Treatment-related hemophagocytic lymphohistiocytosis secondary to checkpoint inhibition with nivolumab plus ipilimumab. *Eur J Cancer*. 2018;93:150–153.
7. Ramos-Casals M, Brito-Zeron P, Lopez-Guillermo A, et al. Adult haemophagocytic syndrome. *Lancet*. 2014;383:1503–1516.
8. Ishii E. Hemophagocytic lymphohistiocytosis in children: pathogenesis and treatment. *Front Pediatr*. 2016;4:47.
9. Zhang K, Jordan MB, Marsh RA, et al. Hypomorphic mutations in PRF1, MUNC13–4, and STXBP2 are associated with adult-onset familial HLH. *Blood*. 2011;118:5794–5798.
10. Janka GE, Lehmsberg K. Hemophagocytic lymphohistiocytosis: pathogenesis and treatment. *Hematology Am Soc Hematol Educ Program*. 2013;2013:605–611.
11. Akashi K, Hayashi S, Gondo H, et al. Involvement of interferon-gamma and macrophage colony-stimulating factor in pathogenesis of haemophagocytic lymphohistiocytosis in adults. *Br J Haematol*. 1994;87:243–250.
12. Brisse E, Matthys P, Wouters CH. Understanding the spectrum of haemophagocytic lymphohistiocytosis: update on diagnostic challenges and therapeutic options. *Br J Haematol*. 2016;174:175–187.
13. Henter JI, Horne A, Arico M, et al. HLH-2004: Diagnostic and therapeutic guidelines for hemophagocytic lymphohistiocytosis. *Pediatr Blood Cancer*. 2007;48:124–131.
14. Fardet L, Galicier L, Lambotte O, et al. Development and validation of the HScore, a score for the diagnosis of reactive hemophagocytic syndrome. *Arthritis Rheumatol*. 2014;66(9):2613–2620.
15. Tecentriq. Electronic Medicines Compendium. Leatherhead, United Kingdom: Datapharm Ltd. Updated July 25, 2021. Accessed August 7, 2021. www.medicines.org.uk/emc/product/8442/smpc
16. Keytruda. Electronic Medicines Compendium. Leatherhead, United Kingdom: Datapharm Ltd. Updated July 25, 2021. Accessed August 7, 2021. www.medicines.org.uk/emc/product/2498/smpc
17. Nosedà R, Bertoli R, Müller L, et al. Haemophagocytic lymphohistiocytosis in patients treated with immune checkpoint inhibitors: analysis of WHO global database of individual case safety reports. *J Immunother Cancer*. 2019;7:117.
18. Daver N, McClain K, Allen CE, et al. A consensus review on malignancy-associated hemophagocytic lymphohistiocytosis in adults. *Cancer*. 2017;123:3229–3240.
19. Castillo L, Carcillo J. Secondary hemophagocytic lymphohistiocytosis and severe sepsis/ systemic inflammatory response syndrome/multiorgan dysfunction syndrome/macrophage activation syndrome share common intermediate phenotypes on a spectrum of inflammation. *Pediatr Crit Care Med*. 2009;10:387–392.
20. Huang C, Wang Y, Li X, et al. Clinical features of patients infected with 2019 novel coronavirus in Wuhan, China. *Lancet*. 2020;395:497–506.
21. Carter SJ, Tattersall RS, Ramanan AV. Macrophage activation syndrome in adults: recent advances in pathophysiology, diagnosis and treatment. *Rheumatology (Oxford)*. 2019;58:5–17.
22. Dufranc E, Del Bello A, Belliere J, et al. IL-6-R blocking with tocilizumab in critically ill patients with hemophagocytic syndrome. *Crit Care*. 2020;24:166.
23. Nigrovic PA, Mannion M, Prince FH, et al. Anakinra as first-line disease-modifying therapy in systemic juvenile idiopathic arthritis: report of forty-six patients from an international multicenter series. *Arthritis Rheum*. 2011;63:545–555.
24. Maude SL, Barrett D, Teachey DT, et al. Managing cytokine release syndrome associated with novel T cell-engaging therapies. *Cancer J*. 2014;20:119–122.
25. Neelapu SS, Tummala S, Kebriaei P, et al. Chimeric antigen receptor T-cell therapy - assessment and management of toxicities. *Nat Rev Clin Oncol*. 2018;15:47–62.
26. Trottestam H, Horne A, Arico M, et al. Chemoimmunotherapy for hemophagocytic lymphohistiocytosis: long-term results of the HLH-94 treatment protocol. *Blood*. 2011;118:4577–4584.
27. La Rosee P, Horne A, Hines M, et al. Recommendations for the management of hemophagocytic lymphohistiocytosis in adults. *Blood*. 2019;133:2465–2477.