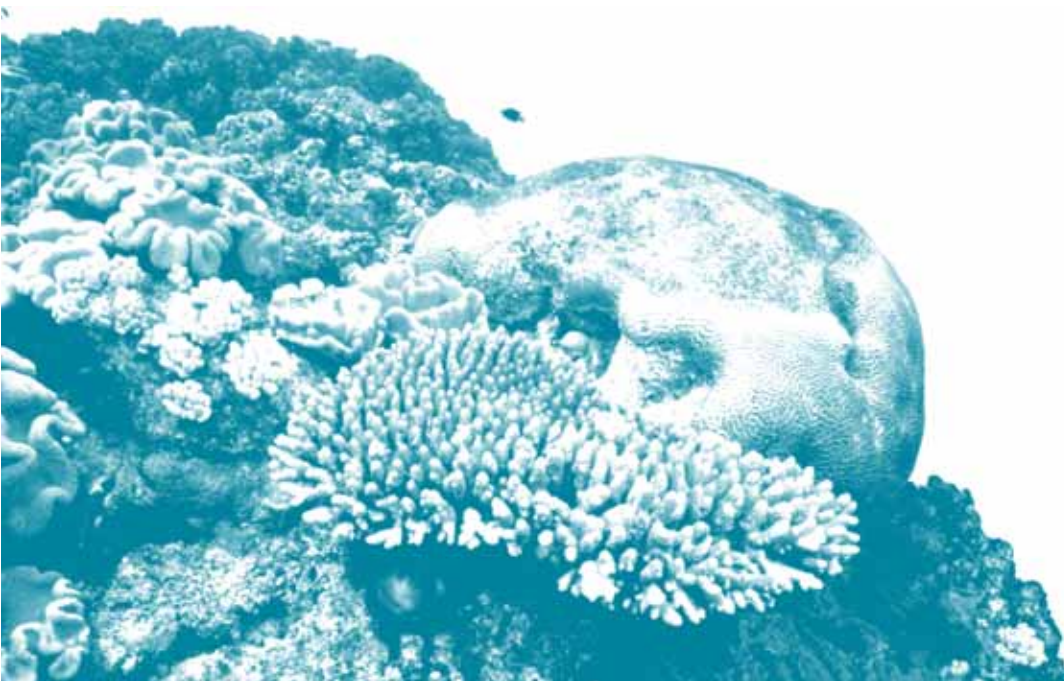



Australian Government
Great Barrier Reef
Marine Park Authority

RESEARCH PUBLICATION No. 85

Procedures for the Salvage and Necropsy of the Dugong (*Dugong dugon*) - Second Edition



Carole Eros, Helene Marsh,
Robert Bonde, Thomas O'Shea,
Cathy Beck, Cheri Recchia,
Kirstin Dobbs, Malcolm Turner,
Stephanie Lemm, Rachel Pears
and Rachel Bowater

let's keep it great

RESEARCH PUBLICATION No. 85

Procedures for the Salvage and Necropsy of the Dugong (*Dugong dugon*) - Second Edition

Carole Eros^{1,2}, Helene Marsh¹, Robert Bonde³, Thomas O'Shea⁴,
Cathy Beck³, Cheri Recchia⁵, Kirstin Dobbs⁶, Malcolm Turner⁶,
Stephanie Lemm⁶, Rachel Pears⁶ and Rachel Bowater⁷

¹ School of Earth and Environmental Sciences, James Cook University, Townsville Queensland, 4811, Australia

² Present address: Fisheries and Oceans Canada, 200-401 Burrard Street, Vancouver, B.C., U6C354 Canada

³ U.S. Geological Survey, Florida Integrated Science Center, Sirenia Project, 2201 NW 40th Terrace, Gainesville, FL 32605, USA

⁴ U.S. Geological Survey, Fort Collins Science Center, 2150 Centre Ave Bldg C, Fort Collins, CO 80526-8118 USA

⁵ Wildlife Conservation Society, International Conservation, 2300 Southern Boulevard, Bronx, New York, 10460-1099, USA

⁶ Great Barrier Reef Marine Park Authority, PO Box 1379, Townsville, Queensland, 4810, Australia

⁷ Department of Primary Industries and Fisheries, PO Box 1085, Townsville, Queensland, 4810, Australia

June 2007

SECOND EDITION

© Great Barrier Reef Marine Park Authority 2007

Published by the Great Barrier Reef Marine Park Authority

This work is copyright. Apart from any use as permitted under the *Copyright Act 1968*, no part may be reproduced by any process without the prior written permission of the Great Barrier Reef Marine Park Authority. Requests and inquiries concerning reproduction and rights should be addressed to Manager, Species Conservation, Great Barrier Reef Marine Park Authority, PO Box 1379, Townsville, Qld 4810.

National Library of Australia Cataloguing-in-Publication data:

Procedures for the salvage and necropsy of the dugong (*Dugong dugon*).

2nd ed.
Bibliography.
ISBN 9781876945534.

ISBN 1 876945 53 2.

1. Dugong - Anatomy. 2. Dugong - Autopsy. I. Eros, C., 1970- .
II. Great Barrier Reef Marine Park Authority. (Series : Research publication (Great Barrier Reef Marine Park Authority) ; no. 85).

599.599



Australian Government

**Great Barrier Reef
Marine Park Authority**

Further information is available from:

Great Barrier Reef Marine Park Authority
2-68 Flinders Street
PO Box 1379
TOWNSVILLE QLD 4810
Phone: (07) 4750 0700
Fax: (07) 4772 6093
Email: info@gbmpa.gov.au

An electronic version of this document is available online in our publications area at:
www.gbrmpa.gov.au/corp_site/info_services/publications

CONTENTS

1	INTRODUCTION	1
1.1	Objectives	1
1.2	Purpose of Necropsies	1
1.3	Summary of Status and Life History of the Dugong	2
2	ELEMENTS OF A STRANDING NETWORK.....	3
2.1	The Stranding Network in Queensland, Australia	3
2.1.1	Agencies and Organisations Involved.....	3
2.1.2	Reporting Procedures	4
2.2	Stranding Database	4
3	INCIDENT RESPONSE PROCEDURES.....	5
3.1	Safety	5
3.2	Documentation.....	6
3.2.1	Record Keeping.....	6
3.2.1.1	Datasheets	6
3.2.2	Photographs.....	7
3.2.2.1	Stranding Location.....	7
3.2.2.2	Necropsy	8
3.2.3	Measurements.....	8
3.3	Initial Assessment	8
3.4	Transporting a Carcass.....	10
3.5	Compliance Investigations.....	10
3.5.1	Procedure Checklist	11
3.5.1.1	Role of the Incident Controller and Field Officer.....	11
3.5.1.2	Observations	12
3.5.1.3	Photographs	12
3.5.1.4	External Measurements.....	13
3.5.1.5	Role of the Compliance Officer	13
4	NECROPSY TECHNIQUE.....	14
4.1	Summary of Dissection Process.....	17
4.1.1	Samples	18
4.2	External Examination and Initial Incisions	19
4.3	Gastrointestinal Tract	21
4.4	Liver and Gall Bladder	24
4.5	Pericardial Cavity, Heart, Major Blood Vessels and Mammary Glands	25
4.5.1	Blood Sample	26
4.6	Respiratory System.....	27
4.7	Urinary System.....	28
4.8	Female Reproductive System	29
4.9	Male Reproductive System.....	30
4.10	Head and Neck Region	31
4.11	The Skeleton.....	32
4.11.1	Forensic Examination of Bones	33
5	SPECIMEN COLLECTION AND PRESERVATION.....	34
5.1	Fixatives and Preservatives	34
5.1.1	10% Neutral Buffered Formalin.....	34
5.1.2	Bouin's Solution	34
5.1.3	Ethyl Alcohol EtOH (100%).....	58
5.1.4	Acetic Acid.....	58

5.1.5 Dimethyl Sulfoxide (DMSO).....	58
5.1.6 Frozen Samples	58
5.2 Specimen Collection Techniques	58
5.2.1 Ingesta	58
5.2.2 Parasites.....	58
5.2.3 Genetics.....	59
5.2.4 Toxic Element and Organohalogen Analysis.....	59
5.2.5 Urine.....	60
5.2.6 Haemolysed Blood.....	60
5.2.7 Microbiology.....	60
6 TRANSPORTATION OF SPECIMENS	61
7 DETERMINATION OF CAUSES OF DEATH.....	62
7.1 Disease.....	62
7.2 Predation.....	63
7.3 Dependent Calves.....	64
7.4 Starvation.....	64
7.5 Vessel Strikes	64
7.6 Incidental Catch.....	66
7.7 Other Human-Related Causes	68
7.8 Undetermined	68
8 GLOSSARY.....	69
9 ACKNOWLEDGEMENTS	73
10 REFERENCES	74
ATTACHMENT 1 Marine Wildlife Stranding and Mortality Report	82
ATTACHMENT 2 Dugong Stranding and Necropsy Datasheet.....	83
ATTACHMENT 3 Dugong Morphometrics	90
ATTACHMENT 4 Incident Report	92
ATTACHMENT 5 Compliance Report.....	94
ATTACHMENT 6 Strandings and Carcasses: Record of Costs and Decisions .	96

TABLES

Table 1.	Suggested list of items to be used during necropsy procedures	15
Table 2.	Key roles and responsibilities at dugong necropsies in Queensland, Australia	16

FIGURES

Figure 1.	Incisions recommended for dugong necropsy from the ventral surface	35
Figure 2.	First incision of a dugong necropsy	35
Figure 3.	Cross-section of tissue layers near the ventral mid-line	36
Figure 4.	Removing the left slab of tissue layers after initial incisions	36
Figure 5.	Exposed organs <i>in situ</i> following initial incisions and removal of dermal layers ..	37
Figure 6.	Stomach and intestines of the dugong.	37
Figure 7.	Carcass with liver and intestines displaced outside the abdominal cavity.....	38
Figure 8.	Pleural cavity showing location of major internal organs	38
Figure 9.	Opening the stomach of a dugong.	39
Figure 10.	Ventral view of the dugong heart	39
Figure 11.	Marks on dugongs from entanglement in net and line.....	40
Figure 12.	Knife wound on right side of abdomen	40
Figure 13.	Marks on dugong from spear wound	41
Figure 14.	Propeller wounds from boat strike.....	41
Figure 15.	Tusk marks on dugongs	42
Figure 16.	Infectious dermatitis on tail	42
Figure 17.	Dugong wounded by stingray	43
Figure 18.	Enlarged mesenteric lymph nodes	43
Figure 19.	Fish hook and line in dugong intestine following ingestion of fishing gear.....	44
Figure 20.	Parasites in dugong.....	44
Figure 21.	Lung with bronchopneumonia.....	45
Figure 22.	Trematode parasites in bronchiole of dugong.....	45
Figure 23.	Dorsal surface of the dugong ovary.....	46
Figure 24.	The right testis and epididymis of a male dugong	47
Figure 25.	Ventral view of the reproductive tract of the male dugong	47
Figure 26.	Lateral view of the dugong head.....	48
Figure 27.	Lateral view of the dugong skeleton.....	49
Figure 28.	Haematoma in thoracic wall from fractured ribs of dugong hit by vessel.....	49
Figure 29.	Anthropogenic cuts to dugongs	49
Figure 30.	Recommended sites for collecting tissue samples	50
Figure 31.	Initial examination of abdominal cavity	51
Figure 32.	Shark bites to dugongs.....	52
Figure 33.	Dugong calf showing signs of malnutrition.....	52
Figure 34.	Adult dugongs showing signs of malnutrition	53
Figure 35.	Body creases on ventral side of dugong.	54
Figure 36.	Vessel strike (case 1)	54
Figure 37.	Vessel strike (case 2)	55
Figure 38.	Numerous markings on the back and sides of the body.....	56
Figure 39.	Dugong suspected of being entangled in a net.	56
Figure 40.	Attempts to conceal dugong carcasses.....	57

1 INTRODUCTION

Data and specimens collected from dugong carcasses and live stranded individuals provide vital information for research and management agencies. The ability to assign a cause of death (natural and/or human induced) to a carcass assists managers to identify major threats to a population in certain areas and to evaluate and adapt management measures. Data collected from dugong carcasses have contributed to research in areas such as life history (Marsh 1980, 1999, Marsh *et al.* 1984a, b, c, Marsh *et al.* 2001); feeding biology (Lawler & Andre 2001, Marsh *et al.* 1982, Preen 1995); investigating the stock structure/genetics of dugongs (McDonald 2006, Tikel 1998); contaminants studies (Gaus *et al.* 2001a, b, Gaus *et al.* 2004, Haynes *et al.* 1999, Haynes *et al.* 2005, Haynes & Schaffelke 2004, Vetter *et al.* 2001); heavy metal analyses (Denton *et al.* 1980, Haynes & Kwan 2001); parasitology (Blair 1981a); and the effects of habitat change. This manual has been adapted from the 'Manual of Procedures for the Salvage and Necropsy of Carcasses of the West Indian Manatee (*Trichechus manatus*)' in Florida, U.S.A. (Bonde *et al.* 1983).

1.1 Objectives

This manual provides a detailed guide for dugong (*Dugong dugon*) carcass handling and necropsy procedures. It is intended to be used as a resource and training guide for anyone involved in dugong incidents including management officers, biologists, parks and wildlife field staff, and veterinarians and pathologists who may lack dugong expertise. Because of the wide range of professionals this book is targeting, information and the use of technical terms is extensive. Section 8.0 provides definitions of various terms used which are italicised throughout the text.

Dugong stranding and *necropsy* procedures in place along the east coast of Queensland, Australia are provided as examples throughout the text; however, this book is intended to be used as a resource guide by those who respond to stranded dugongs throughout their range. Throughout this manual, ideal dugong carcass handling and *necropsy* practices and procedures are described. Procedures may need to be modified in actual events depending on factors such as the location, available equipment and personnel, freshness of carcass and type of investigation (e.g. compliance). Limited information is provided in this manual on managing live dugong stranding incidents. The Queensland Parks and Wildlife Service and the Great Barrier Reef Marine Park Authority (1999) have provided information, adapted from Geraci and Lounsbury (1993), detailing options available in responding to stranded live dugongs. In recent years, Sea World (Gold Coast, Queensland, Australia) have successfully raised two dugong calves (Blanshard 2006 and see Limpus *et al.* 2002, Greenland & Limpus 2006).

1.2 Purpose of Necropsies

There is little information on the causes of morbidity and mortality in marine mammals that utilise inshore and near offshore habitats. In addition to providing biological information, *necropsy* (or *post-mortem*) examinations provide opportunities to investigate signs of natural and human-induced causes of death. For example, while diseases manifest in any species as either primary or secondary events, a finding of increased secondary diseases within a species could warrant an investigation of a possible common environmental determinant (B. Hill *pers. comm.* 2000). The main objectives of dugong stranding and *necropsy* procedures described here are (in descending order of priority):

- To gather the best possible information to identify cause of death
- To collect other information relevant to management agencies implementing conservation initiatives for the recovery and conservation of dugong populations
- To collect basic biological information.

It should be appreciated that evidence collected during dugong stranding and subsequent *necropsy* evaluations may be used in a court of law. Therefore, it is imperative that these incidents be documented as required for compliance procedures (refer Section 3.5). Standardised written and photographic documentation are the most effective means of collecting the appropriate data (see Section 3.2).

1.3 Summary of Status and Life History of the Dugong

The dugong occupies a large range that spans some 40 countries and includes tropical and subtropical coastal and island waters from east Africa to Vanuatu. A significant proportion of the world's dugongs are found in northern Australian waters, where most of the modern dugong research has been conducted. In Australia, the dugong's range extends from Moreton Bay in the east across the north coast to Shark Bay in the west (Marsh & Lefebvre 1994).

Australia is obligated to conserve dugongs under several international conventions and national conservation acts. The dugong is listed as 'Vulnerable to Extinction' in *The World Conservation Union Red Data Book of Threatened Species* (International Union for the Conservation of Nature 2006). In Australia at the national level, the dugong is included as a 'Listed Migratory Species' under the Commonwealth *Environment Protection and Biodiversity Conservation Act 1999* (EPBC Act), in view of its listing in Appendix II of the *Bonn Convention* (Convention on the Conservation of Migratory Species of Wild Animals) and is also a 'Listed Marine Species' under the EPBC Act. The dugong is listed as 'Vulnerable' under Queensland's *Nature Conservation Act 1992*, as 'Protected' under the Northern Territory's *Territory Parks and Wildlife Conservation Act* and New South Wales' *National Parks and Wildlife Act*, and as 'Specially Protected' under Western Australia's *Wildlife Conservation Act 1950*. One of the World Heritage values of the Great Barrier Reef Region is that it provides major feeding grounds for large populations of dugongs (Great Barrier Reef Marine Park Authority [GBRMPA] 1981).

Dugongs can live for about 70 years. In northern Australia dugong females less than 2.00 m long have almost certainly not born a calf (non-parous), whereas those larger than 2.50 m are likely to have born young (parous) (Jillian Grayson unpublished, Kwan 2002, Marsh *et al.* 1984c). Nulliparous females with active ovaries have been recorded at lengths of between 2.28 and 2.50 m long (Kwan 2002, Marsh *et al.* 1984c). The smallest female with a placental scar was 2.27 m long (Kwan 2002). Dugongs breed very slowly and females usually start having young when they are about six to 17 years old (Kwan 2002). Pregnancy lasts about 13 months and dugongs only have one calf at a time. Calves will stay with their mothers for 18 months or more. Female dugongs usually wait at least three years before they breed again (Marsh 1995). Population simulations indicate that even with the most optimistic combinations of life-history parameters (e.g. low natural mortality and no human-induced mortality), a dugong population is unlikely to increase more than five per cent per year (Marsh 1999).

In northern Australia, dugong males less than 1.9 m long are almost certainly immature, whereas those larger than 2.5 m are likely to be mature (Kwan 2002, Marsh *et al.* 1984c).

2 ELEMENTS OF A STRANDING NETWORK

The gathering of good information from a live stranding or carcass incident requires an organised systematic response including early detection and reporting followed by rapid effective action (e.g. efficient search, recovery and transport techniques). Ideally a stranding network should include:

- A mechanism or system for allowing quick reporting of live stranded, sick, injured or dead animals, such as a telephone “hotline”
- An emergency response team to respond to reports of stranded live or dead animals
- Organised and standardised data collection and reporting procedures
- Logistic support and equipment for retrieval and transport of live animals or carcasses (when appropriate)
- A facility for medical treatment and rehabilitation in the case of live strandings
- A facility for the effective *necropsy* of dead animals by trained personnel
- A centralised and institutionalised facility for the permanent storage of data, photographs and specimen material (e.g. state or national museums).

The establishment of an incident control management team to oversee the operation (including searches, salvage, *necropsy*, disposal and debriefs) will assist in the co-ordination of an incident. When a *necropsy* is warranted, it is imperative that follow-up pathology and other testing by trained personnel is arranged for each incident, and that biological and anecdotal information is collected according to a standardised protocol to allow for detection of any trends in mortality patterns (see Section 3).

The overall objectives of a stranding network that has dugongs as at least one of its focal animals should be:

- To enable the wider community to report, effectively and rapidly, live strandings and mortalities
- To ensure that an appropriate response is made to all reported carcasses and live strandings
- To maximise the number of live stranded and dead animals recovered so that the causes of mortality, strandings and injuries are identified
- To ensure timely reporting of live strandings and mortalities to all relevant parties, including the public
- To enable long-term scientific studies which provide information to improve the conservation, management and biological understanding
- To increase public awareness.

2.1 The Stranding Network in Queensland, Australia

The following is an example of the components of a stranding network in operation along the east coast of Queensland, Australia. This network encompasses a variety of government agencies (Australian, Queensland, regional offices), the public, various boating associations and private organisations. The focus of the network includes dugongs, whales, dolphins and marine turtles.

2.1.1 Agencies and Organisations Involved

The overall coordination of dugong stranding and *necropsy* procedures is provided from the Queensland Environmental Protection Agency (EPA - State agency) office in Brisbane. However, the actual planning and operation of the stranding network is a regional responsibility. With a few exceptions, such as situations where personal safety may be put at risk, EPA’s

Queensland Parks and Wildlife Service (QPWS) staff in district offices examine and/or record all reported sick, injured or dead dugongs with the primary purpose of determining the cause of death and the presence, nature and extent of any disease or injury.

Reports of dugong and other marine wildlife incidents are provided mainly by the general public through a well-advertised State-wide marine stranding telephone hotline. Reports are also provided by numerous other organisations and agencies. These include Air Sea Rescue, Coastwatch, Surf Lifesavers Australia, Queensland Seafood Industry Association, Sunfish, Queensland Government Department of Primary Industries and Fisheries (DPI&F), and local government councils. With the appropriate authorisation, staff of these agencies are able to assist in carcass recovery. The DPI&F plays a vital role in carcass reporting due to its responsibility for managing shark nets and drumlines (baited hooks and line attached to anchored buoys) set for bather protection in Queensland and its expertise and time spent patrolling the inshore waters of the Queensland coast.

The Queensland stranding network currently operates with the assistance of several external bodies that respond to incidents. Live marine animal strandings from throughout southern and central Queensland are reported to Sea World (Gold Coast) and Underwater World (Sunshine Coast) who, with authorisation from QPWS, often respond to the strandings directly. In addition, Sea World provides staff and logistical support (including a vessel and helicopter) to QPWS for some live stranding incidents. Underwater World also assists QPWS staff in responding to and retrieving stranded live animals. In the Townsville area, the Queensland Government DPI&F Tropical and Aquatic Animal Health Laboratory and the James Cook University School of Veterinary and Biomedical Sciences provide expert technical assistance with necropsies and pathology. Reef HQ Aquarium (the National Education Centre for the Great Barrier Reef) provides a rehabilitation and reporting facility. The Water Police also assist in recovering dugong carcasses, and biologists from James Cook University and the Great Barrier Reef Marine Park Authority (GBRMPA) assist with necropsies when possible. The Queensland Boating and Fisheries Patrol (QBFP), State Emergency Service, Surf Lifesavers Australia, and volunteers from the Australian Whale Conservation Society, local councils and the general public also provide invaluable assistance at strandings.

2.1.2 Reporting Procedures

Reports of dugong carcasses are transmitted to key Queensland and Australian Government offices on an internal email listserver to facilitate co-ordinated responses and rapid sharing of information. A public email listserver is also used to inform interested persons and organisations of confirmed dugong live stranding and carcass incidents, and to provide information on causes of death when available. Joint Queensland and Australian Government news releases are issued as required to highlight issues to the public.

2.2 Stranding Database

Data from each incident should be collected and reported according to a standardised protocol, and then incorporated into a State-wide (or equivalent) database to allow for analyses and detection of trends. In Queensland, stranding information is incorporated into a stranding database managed and owned by EPA. The data are entered into a searchable, relational database of stranded marine wildlife incidents. A second database is maintained with additional information relating to pathological analyses. Queensland EPA produces annual reports that summarise stranding data. These reports can be downloaded from the Environmental Protection Agency website (www.epa.qld.gov.au).

3 INCIDENT RESPONSE PROCEDURES

There are several stages involved in responding to a dugong live stranding or carcass incident:

- Receiving the initial report
- Locating and identifying the live stranding or carcass
- Assessing the condition of the animal
- Deciding on appropriate action (release, retrieval, *necropsy*)
- Data collection and reporting.

For reports involving dead animals (carcass reports), specific decisions required include:

- Whether a compliance investigation is warranted
- The condition of the carcass
- The appropriate extent of the *necropsy* to be conducted
- Whether to conduct the *necropsy* on site or at another suitable location or facility
- How to transport the carcass (if needed)
- How to dispose of the carcass after *necropsy*.

3.1 Safety

Contact with sick, injured or dead dugongs can pose a risk to people. These risks include injuries sustained from a live animal (e.g. animal thrashing or rolling), contraction of diseases, being cut or injured during the handling and examination of the carcass, or being adversely affected by chemicals used to preserve tissues. Appropriate precautions should be taken during all stages of handling a live or dead dugong.

The risk of humans contracting a zoonotic disease (a disease that can potentially be passed on to humans) from a dead animal is always present, especially when the cause of death is unknown (Bryden *et al.* 1998). Therefore, anyone performing necropsies on dead animals should be well aware of the risks of exposing themselves to disease. It is essential that all people present wear protective clothing (gloves, boots, facemask etc.) to avoid bodily contact with any fluids from the animal (see Section 7.1). Use of disinfectant soaps after *necropsy*, or following exposure should be a routine procedure.

Anyone involved with *necropsy* sampling should also be aware of the risks associated with preservation materials (see Section 5). Some preservatives are carcinogenic; others toxic and flammable. Chemicals should always be used in a well-ventilated area and care should be taken to ensure containers are tightly capped.

Once a carcass has been opened it is impossible to contain all the body fluids and tissue. For sanitary reasons, on-site *necropsy* should not be a regular practice and should only be done if the site is far from recreational areas, and the general public can be kept well back from the *necropsy*. When transporting a dead animal (or a diseased live one) ensure any fluids or material are not allowed to drip or be aerosolised while in transit. This will avoid contaminating pedestrians or other motorists. Where possible, ensure the transport vehicle separates the air breathed by the driver and passengers from the carcass. Following the *necropsy*, waste tissue should be contained and immediately incinerated or buried, in compliance with local standards and ordinances, in a location where human and wildlife contact with the remains will be minimal. The work area and equipment should be scrubbed down with disinfectant detergents. Thoroughly wash and sterilise clothing as soon as possible after the *necropsy*. If available, it is preferable to use disposable items (e.g. disposable overalls) to reduce cross-contamination during laundry processes.

3.2 Documentation

It is imperative that proper documentation is made at each stage of an incident, especially if it is considered a compliance investigation (see Section 3.5). Data and specimens collected over time from the retrieval and subsequent *necropsy* of dugong carcasses need to be obtained in a standardised, systematic way to allow the records to be comparable and suitable for detailed analyses. Determining the cause of death relies on the collection of relevant information from sick, injured or dead dugongs through a stranding network. Between 1999 and 2005, the proportion of reported dugong carcasses in Queensland for which a cause of death could be assigned ranged from 56% to 70% (Limpus *et al.* 1999, Haines & Limpus 2000, 2001, Limpus *et al.* 2002, Greenland *et al.* 2003, Greenland & Limpus 2004, 2006). These percentages may not increase significantly with increasing expertise or time, as evidenced by the manatee salvage and *necropsy* programme run in the United States, which operates a more comprehensive programme in a cooler climate, but can not assign a cause of death to 38 to 69% of their cases (U.S. Marine Mammal Commission 1998). However, those carcasses for which a cause of death can be determined provide useful insights into potential impacts on the animals.

3.2.1 Record Keeping

It is important to standardise the methods of measuring carcasses, recording data and collecting specimens to facilitate comparisons over time and among different investigators. Accurate record keeping is accomplished through the consistent use of standardised data collection protocols and forms. Several types of forms can be used to report on different phases of the incident. These forms are described below and examples are provided in Attachments 1-3 (note: forms provided in this book are in use by research and management organisations in Queensland, Australia, at dugong live stranding and carcass incidents and necropsies) and also Attachments 4 and 5 for compliance incidents. Each carcass should be assigned a unique identification number to facilitate record keeping and analysis. It is important to record as much information as possible and take photographs, however the objective is to ‘record’ and not to ‘interpret’. Preconceived ideas can affect later findings, particularly when environmental or weather conditions are difficult to work in, the *necropsy* is rushed or the carcass is not very fresh.

3.2.1.1 Datasheets

In Queensland, the **Marine Wildlife Stranding and Mortality Report** (Attachment 1) is used to record information at the stranding site before the carcass is moved to a *necropsy* facility or necropsied on site. It is vital to conduct an initial assessment at this stage prior to any transport (see Sections 3.3 and 3.5). It is important to include several photographs at this stage (see Sections 3.2.2 and 3.5).

The **Dugong Stranding and Necropsy Data Sheet** (Attachment 2) is used to record information during the *necropsy*. This sheet includes a suggested list of specimens to be collected and space for the names of observers, the specimen number, sex, locality, date, time and cause of death in addition to the place, date and time of the carcass examination. An external description including details of skin colour, scars, ectoparasites (e.g. barnacles), injuries and any other abnormalities should also be included and accompanied with supporting photographs. Any external markings can be recorded in detail on the **Dugong External Examination: Markings Data Sheet** section of the **Dugong Stranding and Necropsy Datasheet** (Attachment 2). Included on this data sheet are spaces listing the samples taken, the method of preservation and the destination or intended recipient for each sample.

The **Evaluation of Human Interaction** section of the **Dugong Stranding and Necropsy Data Sheet** (Attachment 2) should be filled out when human interaction is suspected as a primary or contributing cause of death.

A **list of dugong morphometrics with diagrammatic instructions** is provided in Attachment 3, however completing this form should be secondary to collecting samples needed to determine the cause of death.

Compliance investigation datasheets including the **GBRMPA Incident Report** (Attachments 4) and the **QPWS Compliance Report** (Attachment 5) may also need to be completed if illegal activity is suspected to be involved with the incident.

In the Great Barrier Reef World Heritage Area the costs of responses to reported strandings are recorded for annual reporting of the Day-to-Day Management Programme (Attachment 6). A record of key decisions is also kept by officers in case decisions are questioned later. Such decisions include the fate of live animals, the use of expensive resources and whether to respond or not to animals with a high public profile.

3.2.2 Photographs

Multiple photographs of the site and external and internal features are necessary for documentation of each dugong live stranding or carcass incident. Photographs should be taken of dorsal, ventral, and both *lateral* aspects of each carcass, including dorsal and ventral aspects of the tail fluke. Additional detailed photographs should be taken of any unusual marks, scrapes, scars, wounds, skin lesions, or natural external features. A ruler or scale of known size should be present in every photograph. Programming the date correctly for the photos is essential. Use wide-angle for overall specimen photographs and macro function is ideal for close-ups. Extra batteries for camera, and extra film for non-digital cameras, should always be carried. If an appropriate camera is not available, use whatever is available or make additional notes and sketches. Each photo should be referenced with the specimen number, sex, species, date, location, and a brief description of the subject depicted. Photos should be backed up on suitable long-term storage media, and if possible a hard copy photo printed, labelled and stored on file. If compliance is a possible issue, care should be taken with handling and storage of photographs to ensure a chain of custody as the photographs are evidence.

3.2.2.1 Stranding Location

The following photographs should be taken as a matter of standard practice during carcass retrieval:

- Location
- Carcass *in situ* plus surrounding scene (from a distance while approaching)
- Any evidence of human activity near the stranding
- A short series of photographs as the retrievers move towards the carcass
- Carcass posture in the water or on the shore where found - if possible, wash off sand etc. to improve photo definition (important for subsequent investigation of possible pathology)
- All persons present at the scene
- Close-ups of any unusual marks, scrapes, scars, wounds or natural features of the animal
- Overall dorsal, ventral, and *lateral* aspects. This may be the only opportunity to thoroughly examine and photograph the back of the entire carcass if the dugong is in the water and thus can be easily rolled. External photographs taken on site are also generally superior because the carcass is in better condition than it will be by the time it reaches the *necropsy* facility
- Close-ups of head/neck (both sides), flippers (dorsal and ventral views), tail (dorsal and ventral views) and tail stock

- Actions taken to move/remove animal from location, with particular attention to any resulting damage to, or marks on, the animal.

3.2.2.2 Necropsy

If time is limited, the priority is to take photographs only where there is a suspicion of unusual circumstances or abnormalities. However, it is ideal to take all photographs suggested in each incident in order to facilitate subsequent re-examination and comparisons between cases.

- External views before incisions
- External abnormalities, old and new scars
- Dermis layers after first incisions
- All organs *in situ* after first incisions
- Gastrointestinal tract including stomach, small intestine, large intestine, caecum, spleen, pancreas
- Transverse colon (when exposed)
- Liver, gall bladder
- Dorsal and ventral surfaces of the lung and any unusual features
- Heart
- Urinary tract including kidneys
- Entire reproductive tract (male or female - including each ovary)
- Foetus (if present)
- Brain.

3.2.3 Measurements

A series of standardised measurements should be recorded for all carcasses. The minimum measurements required are body length, tail fluke width, genital opening to anus distance and teat length (if female) (see page 1 of Attachment 2). There are several additional measurements that can be taken if specific morphometric data from a carcass are desired (e.g. for stock studies). These measurements are outlined in Attachment 3 (also see Heinsohn 1981). Straight-line measurements (such as body length or tail fluke width) should not be taken over the body contours but along the side of the animal. Measurements subject to distortion (especially girths) are only accurate if taken from fresh (see Section 3.3) carcasses in which bloating has not occurred, and should not be taken on badly decomposed specimens.

Scar measurements should be recorded on the **Dugong External Examination: Markings Data Sheet** (Attachment 2). Sketches can be made on the data sheet in appropriate places and measurements of scars can be recorded.

3.3 Initial Assessment

Detailed data should be recorded at the recovery site for each dead or live dugong examined. The officer in charge (or equivalent) should take notes as per the data sheets (Attachments 1 and 2) and include information on the animal's condition and the general characteristics of the area in which it was found. If possible, note any ongoing human activities in local waters (i.e. boat usage, fishing activities) and how regularly dugongs are seen in the area (daily, seldom, seasonally). If the original reporting source is present, ask the exact location of the animal when first seen (use a map and include latitude and longitude details or a Global Positioning System [GPS] fix if possible) and how it was originally positioned. A detailed description of any external features of the dugong is important.

Injuries should be photographed, measured (if possible), and shown on diagrams; all attached ropes, nets and other apparatus should be photographed and described *in situ* and collected for

evidence in a possible compliance action, but not removed from the dugong (unless alive). Supporting photographs should also be taken (Sections 3.2.2 and 3.5).

Carcass condition should be described on the data sheet during the initial assessment. This refers to the state of decomposition and is influenced by factors such as ambient temperature, *post-mortem* interval and body size. It is important that a qualified person assess the condition of the carcass. The assessment of carcass condition guides the decision as to whether or not a *necropsy* should be conducted, the types of samples to be taken and the subsequent pathology tests to be done. For example, bacteriology and virology (for disease diagnosis) can only be done on fresh (Categories 1-3) carcasses, while heavy metal, pesticide and DNA analyses can be done on samples collected from fairly decomposed animals. Six types of descriptions to code a carcass are used on the datasheets provided (based on categories outlined in Geraci & Lounsbury 1993, 2005):

- 1: Live when first reported but subsequently died
- 2: Carcass in good condition (fresh/edible)
- 3: Carcass fair (decomposed but organs intact)
- 4: Carcass poor (advanced decomposition)
- 5: Mummified carcass (skin holding bones)
- 6: Disarticulated bones (no soft tissue remaining).

Categories 1-2 (Fresh):

- Little or no bloating due to general tissue decomposition
- Skin not sloughed
- Flippers not stiffened vertically
- Internally all organs intact with material generally suitable for histopathology.

Category 3 (Moderately Decomposed):

- Slight bloating
- Some skin sloughing or stiffening of flippers
- All internal organs including the liver show integrity, although autolysis and decomposition may render the tissue matrix unsuitable for standard histopathology
- Brain tissue may be liquefied later in this stage.

Category 4 (Badly Decomposed)

- Usually bloated
- Missing patches of skin, with flippers stiffened vertically
- Internal organs, particularly the liver, show loss of integrity or complete disintegration.
- In some carcasses bloating may not be evident due to very advanced decomposition or release of gas through wounds.

Categories 5-6 (Dried carcasses or bones)

- Advanced to the point where little remains of the carcass other than the skeleton or hide.

External examinations (see Section 4.2) should be conducted on all carcasses. Carcasses in the 1, 2 and 3 categories (as per the stranding data sheet, Attachments 1 and 2) should be necropsied in detail. If possible, these carcasses should be transported to a suitable facility for *necropsy*. After the *necropsy* has been completed the animal should be buried at a designated location. The location of burial should be noted on the data sheet (Attachment 1) to enable recovery if required. Carcasses in the 4, 5 and 6 categories should be examined to the extent possible. An internal examination should always be conducted on intact carcasses because carcasses that appear decomposed externally can be in relatively good condition internally. Internal examination of all carcasses can also rule out some causes of death (e.g. ingestion of marine debris, stingray barbs).

3.4 Transporting a Carcass

If a carcass is to be transported to a *necropsy* facility, this should occur as soon as possible (preferably within 24 hours). The estimated time of arrival should be given to all parties involved. If possible, a carcass should be chilled during transport by placing it on ice within a body bag or suitable waterproof cover (e.g. a tarpaulin). A rolled plastic tube may also be suitable, as it can be cut to length, the body slid into the tube and a knot tied at each end; ice can then be placed around the tube, held in with a second tube of plastic. However, this may not be possible if time is limited. It is important to carefully document any marks or other damage to the carcass caused by handling and transport. To enable such damage to be identified, the carcass should be photographed before and after transport. Any damage caused by handling and transport must be documented, preferably by photographs, and recorded on the datasheets. The carcass should be shaded from the sun before and during transport to minimise tissue decomposition. Loading and transport should be as gentle and efficient as possible to minimise any damage to the carcass which may obscure evidence indicating cause of death.

Equipment needed to transport a carcass should include a truck and trailer equipped with a power winch fitted with a front mounted tow bar. A fully equipped vehicle should carry harnesses, mobile phone, pager, water testing kits, pathological sample kits and a complete list of contact names and telephone numbers for most marine incidents.

A *necropsy* may have to be performed on site if an area is inaccessible by boat, if collecting the carcass either manually or by using lifting machinery is not suitable, or if the carcass is so badly decomposed as to make transport impossible.

3.5 Compliance Investigations

Investigation for potential compliance action is one of the objectives of a marine animal stranding response. Determining cause of death and whether human interference has occurred before or after death is important for deciding if compliance investigations are warranted. The collection of evidence can become an important part of the *necropsy* process. Where there is a conflict of interest between various objectives of a *necropsy*, then compliance issues should take precedence.

Compliance issues regarding marine wildlife may be covered under several sets of legislation, e.g. in Queensland, Australia, the following legislation is relevant: Commonwealth offences under the *Great Barrier Reef Marine Park Act 1975*, *Environment Protection and Biodiversity Conservation Act 1999*, or State offences under the *Marine Parks Act 2004*, *Nature Conservation Act 1992*, or *Fisheries Act 1994*.

Compliance incidents may include direct impacts on a dugong, such as illegal hunting (i.e. hunting by non-Traditional Owners) or unlawful killing (e.g. deliberately killing an animal entangled in a net). Dugongs may also have been killed as a result of other activities, such as illegal netting or speeding boats in areas with a statutory speed limit. In these situations, an injured or dead animal provides potential evidence of an offence.

Additional illegal activities may include: deliberately injuring an animal; interfering with a dead animal to prevent detection of the carcass, e.g. slitting belly and adding weights or tying up to mangroves; collecting material from a dead animal; selling meat obtained by legal (or illegal) hunting; and not reporting animals entangled in legally set fishing gear.

Not all human interaction with a live dugong or a carcass is illegal. Traditional hunting when conducted by some Traditional Owners is legal in Australia. Dugongs may die accidentally in

legally set gill/mesh nets, and nets set for bather protection. On occasion, members of the public or other agencies may retrieve carcasses and associated handling or transport may have made marks on these dugong carcasses. Such factors must be taken into consideration when determining cause of death and whether there is a compliance incident.

Officers with specific training generally conduct compliance investigations. For example, in Queensland, investigations are generally conducted under the guidance of a Compliance Investigator from the relevant government agency, such as the QPWS Senior Ranger. In the Great Barrier Reef World Heritage Area, investigations occur under the *Commonwealth Compliance Management and Investigation Procedures*. In State managed areas, investigations occur under a series of documents relating to *Investigations Processes and Procedures*. Compliance Officers should be informed if an illegal activity is suspected and their advice or direction(s) taken. Necropsies can provide vital evidence in the investigation and for the preparation of a Brief of Evidence. Evidence in compliance cases may include:

- The carcass
- Biological samples
- Other physical evidence (e.g. ropes, nets, bullets)
- Photographs.

The standard chain-of-custody process must be implemented for all such evidence if it is suspected that an offence has been committed. The importance of maintaining a chain-of-custody cannot be over-emphasised. The assistance of Compliance Officers at the stranding site and *necropsy* should be encouraged.

In some circumstances a compliance action may be undertaken before a *necropsy*. For example, the discovery of a carcass in a campsite or an empty vehicle may lead to discreet surveillance of the carcass to see who returns for it. Compliance action may delay, and therefore compromise, the *necropsy*. Appropriate response to such incidents should be discussed with the Compliance Officer, and the best outcome for compliance determined and followed.

3.5.1 Procedure Checklist

3.5.1.1 Role of the Incident Controller and Field Officer

Responses to dead dugongs may be coordinated by a government agency using an Incident Control System. This will have an Incident Controller and possibly one or more Field Operations Officers. Field Officers may also undertake compliance evidence collection or there may be separate Compliance Officers. Below is an example from the Great Barrier Reef World Heritage Area of procedures that should be conducted by the Incident Controller or the person in charge of responding to a report of a dead or injured dugong. They should:

- Determine from initial notification, subsequent contact with the person who reported the incident or on-site assessment by staff, if a compliance incident is probable, possible or unlikely. Until a *necropsy* is conducted, many cases will fall into the category of ‘possible’.
- Notify possible or probable compliance incidents to a QPWS Senior Ranger (Compliance) or to the Day-to-Day Management Coordination Unit (in the Great Barrier Reef Marine Park) using standard notification procedures.
- If it is possible that a suspect will return to a carcass, before retrieving or *necropsy* of the animal, seek advice from a QPWS Senior Ranger (Compliance). Compliance action would take priority over an immediate *necropsy*.

- Collect observations, photographs, and external measurements on site as these may be used to support the compliance actions and provide important biological data. If compliance issues are possible or probable, ensure staff make very detailed observations and take photos.
- Ensure evidence that is collected for compliance is handled using chain-of-custody procedures. Physical evidence may include: bullets or harpoons in the animal; nets and ropes; weights or buoys; other nearby dead marine life; evidence from nearby campsites or human activity; and paint marks on the carcass. All evidence must be packaged, sealed, stored and passed on to others using chain-of-custody procedures. Compliance Officers can advise on exact protocols.
- Do not allow an animal in the possession of staff to be claimed by others if there is a possibility of human interference, as it is potential evidence. If necessary, explain that further investigation or *necropsy*/diagnostic work is needed on the carcass.
- If possible, provide resources to support compliance actions, e.g. boats. To handle potential compliance issues, ensure that a QPWS Officer attends necropsies with possible or probable human interference, including those necropsies undertaken by other institutions or agencies.
- Ensure that Compliance Officers receive copies of stranding forms and *necropsy* results.
- Ensure the safety of field staff, including those undertaking compliance investigations and *necropsy* activities, by coordinating activities and ensuring that compliance needs do not conflict with safety issues e.g. infection risks.
- Complete Compliance Incident Forms (Attachments 4 and 5).

3.5.1.2 Observations

- Treat all stranded dugongs with possible or probable human interference as potential evidence. Indicators of interference may include knife marks, rope marks, net marks, and bruising. Natural marks may include scars from the tusks of other dugongs, shark teeth marks, scratches and grazes from the substrate and grazes to the animals caused after death as the animal is moved by currents or waves. Other marks, but not necessarily illegal marks, may be caused by boat propellers, keels or outboard skegs. See Sections 4 and 7 for descriptions and figures illustrating these marks.
- Ensure observations are made of the scene before the animal is moved, especially evidence of human activity (e.g. footprints, tyre tracks, boat marks, cigarette butts, rubbish) and other dead or live marine life in the vicinity.

3.5.1.3 Photographs

- Marks on the animal should be photographed before the animal is moved. This will differentiate marks made prior to the stranding from any new ones made during handling and transport. Marks caused by bruising should not be confused with discolouration caused by blood that has drained to lower parts of the body.
- Ensure photographs are taken of the scene before the animal is moved, especially evidence of human activity (e.g. footprints, tyre tracks, boat marks, cigarette butts, rubbish) and other dead or live marine life in the vicinity.

- Photographs may be taken using film or digitally. Note that the negatives and the digital chip are considered the evidence; any prints from these are considered secondary evidence which may be presented with a written statement.

3.5.1.4 External Measurements

- Ensure as detailed measurements as possible are recorded from animals with signs of possible human interference. This includes measurements of the animals (e.g. length, width) and details of any marks (e.g. cuts, rope marks, paint smears). The length, depth and distance between propeller cuts can assist with the identification of the size and speed of the boat that caused the marks.

3.5.1.5 Role of the Compliance Officer

- Upon notification of a possible or probable case involving compliance issues, determine what information is required from the stranding site, animal or the surrounding area and whether the site should be managed as part of a compliance operation, e.g. a stakeout.
- Advise the Incident Controller about what information and evidence needs to be collected and how it should be handled.
- Ensure investigation processes are conducted under the direction of the *Commonwealth Compliance Management and Investigation Procedures* or in accordance with *State Investigations Processes and Procedures*.
- Sample and evidence collection, storage and transport must be undertaken with regard to safety issues, including infection risks (refer Section 3.1).

4 NECROPSY TECHNIQUE

Performing an effective *necropsy* requires consistent procedures, keeping detailed notes and photographic records, proper equipment, proper labelling of each sample and experience. This section provides guidelines for *post-mortem* examination of all major organ systems in a dugong carcass. Use of these guidelines, when appropriate, should result in a thorough *necropsy*. Other sections provide information to aid in keeping records (Sections 3.2, 3.3 and 3.5), preserving material (Section 5), and classifying the cause of death (Section 7). Table 1 provides a list of equipment necessary for a thorough *necropsy*. Table 2 provides an example of the key roles and responsibilities that may be required to conduct and record a *necropsy* effectively.

The *necropsy* should be performed in an area that has restricted public access, is sheltered from rain and direct sun, and is screened from flying insects. Access to running water, as well as electricity for refrigerators, freezers, bone saws, and other equipment, is also important. Efforts should be made to contain fluids and tissue waste and to keep the work area as clean as possible. In compliance with local workplace health and safety regulations (see Section 3.1), all personnel handling dead animals should wear adequate protective clothing including surgical gloves, face mask, overalls (to cover all body surfaces) and rubber boots (Table 1). Disinfectants should be used on tools and work surfaces and care taken not to expose eyes, nose, mouth, and skin to contamination.

It is recognised that it may not be possible to adhere to the following *necropsy* instructions and guidelines in all situations. This text aims to provide guidelines for a detailed *necropsy* by a qualified professional (e.g. veterinary pathologist) in a well-equipped facility. The extent of an actual *necropsy* will depend on location, carcass condition and the availability and experience of personnel, equipment and other resources. Each *necropsy* should be adapted to the situation; however, **the overriding objective during a *necropsy* should be to determine the cause of death.** At each stage, tissues should be sampled as soon as possible after they are exposed. Samples to be collected for microbiology, histopathology and toxicology examinations should be given first priority to minimise any chances of further contamination. Collection of other biological information (including organ weights and morphometrics) should be secondary to collecting samples needed to determine the cause of death. It should be noted that the time since death and presence/absence of disease/dehydration might influence the weight of organs. Lists of samples to be collected at a *necropsy* are summarised in Section 4.1.1 and are highlighted at the beginning of each *necropsy* section (from Sections 4.2-4.10).

Table 1. Suggested list of items to be used during necropsy procedures.

Use	Item
Clothing and Hygiene	<ul style="list-style-type: none"> • First aid kit • Rubber boots • Heavy rubber and plastic sterile gloves • Coveralls or disposable overalls, butcher's aprons or smocks • Hand soap, sunscreen • Buckets, brushes • Detergent/disinfectant solution, paper towels • Surgical mask or chemical-style particle masks • Container for used needles and blades • Dedicated storage bin (e.g. nally bin) for storage and transport of equipment • Label 'Animal Waste Products'
Documentation	<ul style="list-style-type: none"> • Camera (wide angle capable zoom and macro function) - make sure digital card is inside • Extra batteries for camera, flash and any other equipment • Data sheets (use standardised ones such as in this manual) • Clipboard for datasheets • Notebook • Soft pencils • Permanent black marker pen • Waterproof paper and pens • Masking tape or other suitable labelling material • Waterproof labels for placing in jars with preserved tissue
Dissection	<ul style="list-style-type: none"> • Measuring tape and ruler or scale for photos • Large knives, sharpening stone • Stainless steel knives for collecting samples for toxicology • Bone saw • Hacksaw • Forceps • Scalpel handle, blades and remover • Assorted scissors (very sharp) • String • <i>Haemostats</i> • Tackle box or similar for storing dissection equipment • Small gas burner for sterilising equipment used in microbiological sampling
Specimen collection	<ul style="list-style-type: none"> • Balances/scales • Plastic containers/jars/vials • Plastic bags: click seal/medium sized (for organs)/large bag (for head) • Preservatives as required (i.e. formalin, alcohol, DMSO, Bouin's) • Syringes for blood and fluid sampling • Transfer pipettes • Water containers for dilution of formalin (if not already pre-mixed) • Cooler or esky and freezer blocks to transport specimens to freezer

Table 2. Key roles and responsibilities at dugong necropsies in Queensland, Australia.

One person can fulfil more than one role, providing the roles are compatible (e.g. “wet” roles and “dry” roles should not be done by the same person).

Role	Necropsy Manager	Photographer	Record Keeper	Veterinarian/Biologist(s)	Necropsy Assistant	Sample Collector
Duties	<p>Oversee entire procedure to ensure:</p> <ul style="list-style-type: none"> • Pre-briefing of all participants of roles, responsibilities, procedures • Proper procedures are followed, including external examination, focus on determining cause of death, collection of required samples, completion of forms, adequate photographic documentation, etc. • Occupational Health and Safety requirements met • Maintenance of chain of evidence • Proper storage, dissemination and transport of samples • Subsequent exchange of materials (e.g. data sheets, necropsy reports, samples, photographs) as required • Feedback – dissemination of results to participants 	<p>Take photos of carcass and procedure including:</p> <ul style="list-style-type: none"> • Photos required for compliance investigations (see Section 3.5.1.3) • Full body photos showing overall body condition and state of decomposition • Close-ups of head/face, flippers, tail and peduncle to show presence/absence of marks, including those useful for identification (see Section 3.2.2) • Photos of major organs (stomach, lungs, liver, kidney, heart, others as judged useful) • Photos of anything considered unusual or pathological • Ensure record is kept of photos taken • Make arrangements with Necropsy Manager for provision of images etc. • May need to resolve copyright issues in advance 	<p>Ensure necropsy form filled out properly including:</p> <ul style="list-style-type: none"> • Date, time, location, names, affiliations and roles of persons present • Relevant measurements • Preliminary necropsy findings as dictated by Veterinarian or Biologist • Ensure sample collection form filled out properly including: <ul style="list-style-type: none"> • Samples collected • Who has them • Ensure all forms given to Necropsy Manager or Incident Controller, as appropriate 	<ul style="list-style-type: none"> • Conduct necropsy procedure in accordance with direction from Necropsy Manager • Provide best preliminary assessment of cause of death (natural, human-related, unknown) • Subsequently provide necropsy report to Necropsy Manager • In agreement with Necropsy Manager, arrange for any pathology/histology/ bacteriology tests, and any follow-up (e.g. pathology) reports 	<ul style="list-style-type: none"> • Assist with procedure in accordance with direction from Veterinarian/ Biologist 	<ul style="list-style-type: none"> • Assist with collection of samples in accordance with protocol and direction from Necropsy Manager and Veterinarian/ Biologist • Ensure all required samples are properly collected and stored (e.g. in formalin or frozen) • Ensure all samples are properly labelled • In agreement with Necropsy Manager, arrange for proper storage and transport of samples
Requirements	<ul style="list-style-type: none"> • Government staff • Thorough knowledge of carcass handling and necropsy procedures and requirements • Biological knowledge an asset 	<ul style="list-style-type: none"> • Reasonable photographic skills • Familiarity with necropsy procedures and requirements 	<ul style="list-style-type: none"> • Familiarity with datasheets • Familiarity with relevant terminology useful • Familiarity with necropsy procedures and requirements 	<ul style="list-style-type: none"> • Appropriate veterinary and/or biological qualifications (formal or informal) • Familiarity with necropsy procedures and requirements 	<ul style="list-style-type: none"> • General familiarity with necropsy procedures and requirements useful • Basic knowledge of biology and anatomy helpful 	<ul style="list-style-type: none"> • Familiarity with necropsy procedures and requirements, especially as relates to required samples • Familiarity with anatomy helpful
Compatible roles	Record Keeper or Photographer or Necropsy Assistant. Could also act as Sample Collector, but this is not ideal	Record Keeper or Necropsy Manager	Photographer or Necropsy Manager	None, unless more than one Veterinarian/Biologist present, then Necropsy Assistant or Sample Collector	Necropsy Manager or Sample Collector. May not be necessary if both a veterinarian and a biologist are participating	Preferably none, possibly Necropsy Assistant

4.1 Summary of Dissection Process

It is essential to conduct a thorough external examination before making any incisions (see Section 4.2). **All internal organs should be examined *in situ* prior to removal, then removed and examined further, with samples taken as appropriate.**

- Place animal on dorsal side (i.e. upside down) so ventral side is uppermost.
- Make a ventral mid-line incision through dermal layers (moving to the left or right of the genital opening) (Incision A, Figs. 1 and 2, Fig. 3). **Be extremely careful to prevent a sudden, unexpected release of gas and fluids.** (Section 4.2)
- The second incision should extend from the sternum laterally to a point just ventral to the *distal* tips of the right ribs. Follow the line of the rib cage caudally, rejoining incision A just *cranial* to the anus (Incision B, Fig. 1). Remove the entire right slab. (Section 4.2)
- Remove a mirror image on the other side (Fig. 4). (Section 4.2)
- Survey exposed surfaces, observing organs and noting any abnormalities. (Fig. 5)
- Remove the entire gastrointestinal tract (stomach and intestines) from the abdominal cavity and examine (Figs. 6, 7 and 9). (Section 4.3)
- Remove liver and gall bladder. (Section 4.4)
- Make an incision along the ventral midline from the sternum to the chin (Incision C, Fig. 1) and from the chin postero-laterally to each *axilla*, and from each *axilla* caudally to the open abdominal cavity (Incision D, Fig. 1). (Section 4.5)
- Survey exposed surfaces, observing organs, noting any abnormalities. (Fig. 8)
- Remove heart; examine externally and internally (Fig. 10). (Section 4.5)
- Remove each hemidiaphragm. (Section 4.6)
- Remove and further examine lungs (Fig. 8). (Section 4.6)
- Remove and further examine both kidneys (Fig. 8). (Section 4.7)
- Examine urinary tract. Dissection of the urinary tract may be reserved until after dissection and removal of the reproductive tract.
- Remove and further examine male or female reproductive tracts. (Sections 4.8 and 4.9)
- Examine head and neck region. (Section 4.10)
- Remove and examine thyroid gland (Fig. 8). (Section 4.10)
- Remove and examine trachea, hyoid bones and tongue. (Section 4.10)
- Remove brain (ideally using a large bone saw or circular saw). (Section 4.10).

Sections 4.2 through 4.11 present a more detailed description of a thorough dugong *necropsy*. All instruments, collecting jars, labels and preservatives should be on hand before making the first incision.

4.1.1 Samples

Samples are collected to conduct virology, bacteriology, environmental contaminants analyses, histopathology, genetics and dietary studies. See detailed instructions for sample collection and preservation (Section 5). Priorities for sampling should include but may not be limited to the following.

Sample	Analysis Required	Collection and Size	Fixation and Preservation
<ul style="list-style-type: none"> Lung, liver, heart and any abnormalities or lesions 	Bacteriology and virology	Aseptically-collected pieces (0.5cm x 0.5cm)	Chilled on ice (4°C)
<ul style="list-style-type: none"> Blubber, muscle, liver, kidney, milk, brain 	Toxic Element and Organohalogen Analysis (Section 5.2.4)	300g of each; as much milk as possible Collect with sterile stainless steel instruments	Frozen (-10°C)
<ul style="list-style-type: none"> All organs (liver, lung, heart, kidney, pancreas, spleen, gastrointestinal tract) Brain (sliced) 	Histopathology	2cm x 2cm x 0.5cm sections One section of stomach and five other sections of the intestinal tract equally spaced between the stomach and anus	10% neutral buffered formalin (or 10% seawater formalin if buffer is unavailable)
<ul style="list-style-type: none"> Stomach contents Faeces 	Dietary Studies (Section 5.2.1) Genetic studies Hormone studies	A handful of stomach contents and faeces	10% neutral buffered formalin Faeces can be chilled
<ul style="list-style-type: none"> Nematodes, flukes, trematodes 	Parasitology (Section 5.2.2)	From the nasal passage, stomach, intestines, caecum, lungs	80% EtOH or 5% formalin
<ul style="list-style-type: none"> Skin and/or muscle 	Genetics (Section 5.2.3)	1 cm x 0.5 cm (size of a fingernail)	80% EtOH or 20% DMSO
<ul style="list-style-type: none"> Female reproductive tract (Section 4.8) Male reproductive tract (Section 4.9) 	Life History Life History	Whole ovary, embryos or foetus, if present, or entire tract Testis, Epididymis or entire tract	10% neutral buffered formalin or Bouin's for 24 hours then transferred to 70% EtOH
<ul style="list-style-type: none"> Tusks (Section 4.10) Eyes 	Age Determination Life History	Collect both tusks Collect one eye	Dried Formalin (slit corner of eye to aid fixation)
<ul style="list-style-type: none"> Blood (Section 4.5) 	Toxic element (if botulism is suspected) and Biochemical assays	20-30ml from the left ventricle of the heart	Frozen (-20°C)

In general most sections for preservatives should be small (e.g. 2 cm x 2 cm). If larger samples are taken, it is important to slice them to facilitate penetration of preservative (where used).

4.2 External Examination and Initial Incisions

Measurements	Samples	Photographs
<ul style="list-style-type: none"> • Body length • Length of teats • Genital opening to anus • Tail fluke width • Blubber thickness <p>(See Attachment 2)</p>	<ul style="list-style-type: none"> • Seagrass from mouth (if present) • One eye • Milk from the teat • Skin • Blubber from outermost layer • Muscle • Nasal flukes • Any abnormalities 	<ul style="list-style-type: none"> • Organs <i>in situ</i> (after first incision) • Wounds, scars • Any abnormalities (external and internal)

The carcass will usually be presented on its back (dorsal recumbency) and preliminary examination of the dorsal surfaces should have taken place in the field before transport to the *necropsy* facility (as noted in Section 3.3). The **ventral and lateral aspects should be examined externally** with comments made on the presence, absence, location, and appearance of abnormalities (e.g. wounds, scars, colouration, barnacles, abrasions, lesions, abscesses, deformities, *emaciation* and bloating).

Any injuries should be examined to determine whether they occurred *ante-mortem* (before death) or *post-mortem* (after death). *Ante-mortem* injuries tend to be associated with reddening, *haemorrhage*, *fibrin* and perhaps *pus*. *Post-mortem* injuries show no signs of *trauma* to internal organs or musculature. Any lesions should be sampled and placed in 10% neutral buffered formalin. Particular attention should be taken to document the presence or absence of marks indicating possible entanglement in a net or line, bullet wounds, knife wounds, spear wounds, propeller strike or other marks associated with human-related activities (see Sections 3.5, 7.6, 7.7, respectively and Figs. 11 - 14). Fresh wounds that occurred before death are open, usually with recent bleeding. Recent wounds show signs of healing. Healing and healed scars may be completely covered by white scar tissue. However, there can also be pigment infiltration in older scars. Each wound should be sketched and documented photographically (see Section 3.2.2.2), including a scale of measurement. Barnacles present on young dugongs should be excised and preserved in 10% neutral buffered formalin as this can assist with age determination.

The presence of numerous scars, scratches and parallel markings on the skin of the back and sides of the body are normal and are characteristic of dugongs because they rub their backs against various types of substrate and from social interactions. Similarly, scars seen on many adults are often tusk wounds resulting from interactions in mating herds or in situations where dependent calves are orphaned or separated from their mother and have been approached by, or approach, other adults (see Fig. 15). Such marks are not (necessarily) indicative of entanglement in nets or ropes. Furthermore, if a dugong carcass is left to decay in the sun, the skin will crack in a mosaic-type pattern that may resemble net entanglement marks (Fig. 11).

Carefully examine the epidermis for focal lesions, sloughing, or patches of wrinkling (see Fig. 16 which shows “infectious dermatitis”). Take transport swabs of any infected areas (see Section 5.2.7). Avoid contact with suppurative lesions and abscesses (see Section 3.1); *pathogens* infective to humans may be present (see Section 7.1). Note presence or absence of large uneven swellings, asymmetry in body contours, or abnormal stiffness or curvature to the *axial skeleton*.

Examine the **head** for evidence of *trauma*. Inspect the mouth and lips for the presence of foreign objects, vegetation (i.e. seagrass, collect if present), *inflammation*, or lesions. If lesions are present, preserve a sample in 10% neutral buffered formalin for consideration during pathology. Note if the nostrils are free of obstruction, note the nature of any nasal discharge, and

collect nasal flukes (*Cochleotrema indicum*) in 10% formalin (see Section 5.2.2). Examine the eyes and preserve one in 10% formalin if not badly decomposed. Eyes can be collected as an alternative age determination technique. The *external auditory meatus* should be located for examination and as a reference point if morphometrics are required (Heinsohn 1981, Attachment 3). On some specimens the meatus may be difficult to locate. It is found at about the same distance *caudal* to the eye as the eye is from the tip of the snout. A slice through the dermis at the meatus will reveal a 1-2 mm diameter canal filled with a black waxy paste. Note if the mandible may be moved with ease or if it is stiff. Leave a more detailed examination of the head and neck for a later stage in the *necropsy* (see Section 4.10).

Examine **each flipper** for freedom of movement, inflammatory lesions, healed wounds or other abnormalities. Measure the lengths of both **teats in females**; palpate each teat working up towards the nipple, and note the presence or absence of milk, *pus*, blood, or other material and take samples if present. Note if both teats are of approximately equal size, or if there is any apparent shrinkage or swelling. Cut the gland to check for the presence of milk. If available, collect a sample of milk and freeze for histology and toxicology.

Examine the umbilicus for abnormalities or infections, particularly in calves. Examine the urogenital aperture for discharges or abnormalities. In recently *parturient* or near-term pregnant females the vaginal canal is enlarged and supple, and the examiner's protected forearm can pass through to the uterus. Females in late pregnancy will also show a bulge with a prominent curve *cranial* to the urogenital opening, which may exude mucus. Note the texture and characteristics of vaginal fluids, and collect samples to later check for sperm under a microscope if recent copulation is suspected. Note if semen is exuding from the external genitalia of males. Examine the anus for blockage, and note the presence or absence of faeces or other discharges, describing texture, colour and consistency. Photograph any abnormalities of the tail fluke, including a reference scale.

Carefully obtain the **measurement data** detailed in Section 3.2.3 and in Attachment 2. These include body length, lengths of teats, genital-opening-to-anus distance and fluke width.

Using a knife, begin the **first incision** (Incision A, Fig. 1; Fig. 2) making a mid-line incision through the skin, blubber and muscle (Fig. 3) to the anus (move to the right of the genital aperture) without penetrating the abdominal cavity. (Throughout the text of this manual right refers to the animal's right, left to the animal's left.). **When cutting through the dermis and blubber layers, be extremely careful to prevent a sudden release of gas and fluids** from the abdominal cavity and the digestive tract. Bloated large intestines are capable of sudden explosion during this stage, or subsequently, and cautious management of any such distended sections should be a priority. Once the length of the incision has been made, cautiously make a small cut in the *parietal peritoneum* at the mid-abdomen using bandage scissors (blunt point directed internally), gradually lengthening the cut as the internal pressure is reduced. The *parietal peritoneum* can then be cut the length of incision A (Fig. 1), taking care not to nick underlying organs. Make a second large incision with a knife (Incision B, Fig. 1) from the sternum laterally to a point just ventral to the *distal* tips of the right ribs. Follow the line of the rib cage caudally, rejoining incision A just *cranial* to the genital aperture. Remove the entire right slab and put it to the side. **Remove a mirror-image left slab** (Fig. 4) by cutting down the midline just to the left of the genital aperture to a point *cranial* to the anus, and by making a *lateral* cut from the sternum to a point just ventral to the *distal* tips of the left ribs, proceeding caudally as in Figure 1. The genitalia should remain with the carcass. Be careful not to disturb the underlying organs during removal of these slabs. Look for any subdermal haemorrhaging and take samples if present. Take a sample of any haematomas (if present) and preserve in 10% neutral buffered formalin to allow for ageing of the wound(s). Fresh haematomas (four days old or less) are unorganised while older haematomas show developing *fibrin* structure and tissue organisation.

Photograph all exposed organs *in situ* (Figs. 4 and 5), including a reference scale (ruler or other known scale). Note the presence of any foreign objects (e.g. stingray barb, Fig. 17) or abnormalities in any of the major organs. Even if organs appear normal, photographic documentation is essential for future reference in supporting diagnoses, particularly should legally sensitive issues arise. Take measurements of the exposed dermis and thickness of the outer and inner blubber layers at the mid-ventral and mid-*lateral* layer cake-like surfaces from the left slab (Fig. 3). Describe the quantity, colour and texture of the blubber. Blubber appearance and thickness can be an indicator of body condition and general health. Collect a sample of the outer blubber and outer muscle layers for toxicology analysis following instructions detailed in Section 5.2. Collect samples for genetic analysis (see Section 5.2). Remark on the general appearance of the abdominal cavity. Note the presence of fluids, if any, and their colours and consistencies. Remark on peculiar odours, the presence or absence of gas and *ingesta*, displacement of organs, ruptures, adhesions and/or *haemorrhage*. Examine the gastrointestinal mesenteries for discolouration or *haemorrhage*, and mesenteric lymph nodes for size and colour. Take transport swabs (if appropriate) and collect tissue samples for histopathology.

4.3 Gastrointestinal Tract

Anatomical Notes	Samples	Photographs
<ul style="list-style-type: none"> The large intestine is up to 25m long in an adult, more than twice as long as the small intestine (Fig. 6) The spleen is generally dark coloured and small The stomach is a simple sac, a large muscular <i>dilatation</i> of the alimentary canal between the oesophagus and the small intestine (Fig. 6 and 7) The presence of nematodes in the stomach and cardiac gland is normal, but a rough estimate of the number present should be noted and photographed 	<ul style="list-style-type: none"> Stomach contents and nematodes Section of stomach and 5 sections along the intestines equally spaced between the stomach and anus Section of caecum and parasites Adrenal gland Spleen Pancreas (if carcass is fresh) Intestinal contents (including faeces) Lymph node(s) Any abnormalities 	<ul style="list-style-type: none"> Gastrointestinal tract <i>in situ</i> and spread out on table Any abnormalities

The gastrointestinal tract and associated structures of the digestive system are removed for examination following *in situ* inspection of the exposed serosal surfaces and mesenteries for *haemorrhage*, cysts, enlarged lymph nodes, tears, abscesses or other lesions. Examine the different parts of the gastrointestinal tract and the mucosal surface for the presence of any abnormalities (e.g. discolourations, haemorrhages, cysts, lesions, *fibrin* strands and adhesions, obstructions, *stenosis*, *inflation*, ulcers, foreign objects, sediment etc.).

After initial incisions, the stomach is somewhat obscured by the liver lobes but when these are gently pulled aside it can be seen that the adult stomach, when distended with *ingesta*, bulges to fill the *anterior* body cavity. The spleen is situated to the left of the median plane, adjacent to the dorsal stomach wall near its region of maximum dilation (Fig. 8). The cardiac gland of the stomach, which is not initially obvious externally, can be seen after the removal of the lesser omentum as a definite protuberance of the left dorsal stomach wall (Fig. 8).

Begin to **remove the gastrointestinal tract** by locating the junction of the descending colon and the rectum. Free this segment by cutting the mesentery (mesocolon), and tie the rectum off

with string in two places a few centimetres apart, just dorsal to the urinary bladder. Examine the mesentery for enlarged lymph nodes (see Fig. 18), which indicate that the dugong is fighting disease or infection. Sever the descending colon between the tied strings and start to cut the mesocolon cranially to begin removal of the entire tract. The diaphragm is on an almost horizontal plane, and each half is referred to as a hemidiaphragm (Fig. 8). The descending mesocolon is attached to the left hemidiaphragm, near the left kidney. The mesocolon should be cut and the colour, texture, and quantity of fat described for the transverse colon and adjoining mesenteries. Tie a string at the centre of the transverse colon to mark its location for future reference.

The coiled ascending colon is attached to the *parietal peritoneum* at the vertebral column. Continue dissections to free the ascending colon. The caecum marks the junction of the large and small intestines (Fig. 6). It is located to the left of the vertebral column. Cut the peritoneum joining the dorsal surface of the caecum to the vertebral column and hemidiaphragm while lifting the caecum. Continue to apply tension and remove the loops of the ileum and jejunum. At this point the *coeliac* and *cranial* mesenteric arteries are severed. The aorta and *caudal* (*inferior*) vena cava are left attached to the hemidiaphragm.

Complete the removal of the gastrointestinal tract by cutting between the duodenum and hemidiaphragm until the pylorus of the stomach is reached. Do not cut the hemidiaphragm. Then stop and move cranially to where the oesophagus enters the stomach. Sever the oesophagus about 5 cm *cranial* to the stomach and continue to cut between the stomach and hemidiaphragm, dissecting through the lesser omentum, hepatic artery, and the bile duct. Clamp the bile duct with a *haemostat* before severing. Cut the bile duct *caudal* to the *haemostat*. The entire gastrointestinal tract may be removed from the abdominal cavity once the stomach attachments are freed. Place the tract on a flat, clean surface for later detailed examination.

After the gastrointestinal tract has been removed but prior to detailed examination, the examiner should inspect the peritoneal lining and the abdominal cavity. Note any abnormalities (areas of *oedema*, adhesions, abscesses, growths, ruptures of the diaphragm or body wall, or other peculiarities). If not contaminated by foreign material, note the amount (by removal with a graduated container) and characteristics (colour, consistency, presence of *fibrin* strands, etc.) of fluids. If clotted blood is present, measure the amount – small amounts can be a normal *post-mortem* development.

Locate the **adrenal glands** (Fig. 8). These are small glands found along each *medial* edge of the vertebral column *cranial* to the kidneys. They are best located by palpation of the region. If the adrenal glands cannot be located they may have been removed inadvertently with the gastrointestinal tract. Once the adrenals are located and removed, they should be examined for cysts or swellings and sliced like bread at no greater than 5-mm thickness for examination and preservation.

The gastrointestinal tract should be placed on a large clean working area so it can be spread out for examination. Detailed examination of the gastrointestinal tract can be left until last in order to avoid any possible cross contamination to the general work area, particularly when necropsies are being carried out under less than ideal conditions. Begin by cutting the jejunum and ileum free of the mesentery and carefully examine all serosal surfaces for haemorrhages. Clamp off any areas inadvertently nicked during removal. Once the serosal surfaces have been examined and described, the spleen and pancreas should be collected and the *lumen* and *mucosa* of the stomach examined.

Photograph, measure, and weigh the **spleen** (Fig. 8). Note if the spleen is in one piece or fragmented; if fragments whether they are of accessory spleens or old ruptures are discernible. Comment on the overall appearance, size, presence of fatty growths, *polyps*, and texture of the

organ. Thinly slice the spleen and note the nature of fluids that might ooze from it. Preserve a 5mm section of spleen in 10% neutral buffered formalin.

The **pancreas** (Fig. 8) is a large, pale, relatively diffuse glandular organ found dorsal to where the duodenal ampulla narrows. The single pancreatic duct opens into the narrow end of the duodenal ampulla *distal* to the opening of the bile duct. The pancreas is subject to rapid decomposition. In fresh carcasses (Categories 1-3) it should be removed, photographed, measured, weighed in its entirety, examined for abnormalities and a 0.5 cm section taken and preserved in 10% neutral buffered formalin.

Open the stomach by making an incision about 15 cm long through its ventral surface (Fig. 9). Note if the stomach contains gas or if peculiar odours are present. When making initial incisions, be careful to prevent a sudden release of gas and digesta from the stomach and intestines. Look for foreign objects or *impactions*, or for swallowed blood near the gastro-oesophageal junction. Note the consistency, colour, quantity and odour of stomach contents, mucus, or fluids. Note the presence or absence of sand, mud, or other sediment and macro-invertebrates. If abundant, estimate or measure the amount of these substances present and collect all or some fraction of the sediment, estimating the proportion of the total present that has been preserved. Examine contents for parasites and, if present, estimate degree of infection (light, moderate, heavy, very heavy). If unsure what the quantity represents, take a photo. The nematode *Paradujardinia halicoris* is common in the stomach, especially in the cardiac gland (see below). Collect a sample of nematodes (see Section 5.2.2). Collect a sample of stomach contents in the centre of the food mass, from near the junction of the oesophagus and place in 10% neutral buffered formalin. Remove the remaining stomach contents and record their weight if required.

Examine the mucosal surface of the stomach for abnormalities. Note if the muscular wall of the stomach appears normal in thickness or if it is thickened, *oedematous* or reddened (this will require experienced personnel to judge). There is considerable but consistent variation in the thickness of the muscle coat in different regions of the main sac (Marsh *et al.* 1977). The cardiac gland occurs as a glandular mass in the submucosal layer of the left dorsal wall of the main sac. Cut through the cardiac gland and examine for abnormalities. Photograph the stomach and collect tissue samples and samples of any abnormalities in 10% neutral buffered formalin.

Examine the intestines (Fig. 6). Note any abnormalities. Make an incision about 10 cm long on the ventral surface of the duodenum. Contents are typically watery throughout the small intestine beyond the *proximal* duodenum and care should be taken to avoid inadvertent spillage. Examine contents and make notations on the presence and characteristics of vegetation, parasites, or foreign objects (e.g. fishing gear, see Fig. 19). Save the small intestine contents if a total gastrointestinal tract contents weight is required. Collect nematodes as previously described. Remove contents and carefully examine the *mucosa* and *serosa* for any abnormalities (reddening, cysts, ulcerations, abscesses, haemorrhages, or other lesions – e.g. parasitic abscesses containing *Faredifex clavata* see Fig. 20 and Blair 1981a). Locate the duodenal villi and probe the exit of the bile duct for *patency*.

Continue cutting through the jejunum (middle portion of the small intestine) and ileum (*posterior* on lower third of small intestine ending at the caecum), examining and remarking upon the mucosal surfaces and contents. Examine the lymph nodes in this region. Note the size, shape, and colour. Preserve a thinly sliced section in 10% neutral buffered formalin.

Make an incision ventrally along the length of the **caecum** (Fig. 6). *Ingesta* are normally firmer than those found in the small intestine and finer in consistency than those found in the stomach. Collect *ingesta* from the centre of the food mass and parasite samples. Preserve any parasites

seen in the caecum in 10% neutral buffered formalin (the trematode *Indosolenorchis hirudinaceus* has been found to occur in the caecum and the first portion of the large intestine).

The remainder of the **large intestine (colon)** should be examined by opening the organ along its entire length with scissors. If possible, weigh the entire gastrointestinal tract contents when the tract is full and contents are normal in appearance and consistency. These weights are useful indicators of the mass of food dugongs ingest. Distinguish between *ingesta* and *meconium* in calves. *Meconium* is a dark green rubbery, mucilaginous material in the intestinal tract of full-term foetuses and neonates. Take transport swabs if *enteritis* is suspected. Collect tissue samples for histopathology in 10% neutral buffered formalin. Collect parasites, noting location in intestines, and give an estimate of the degree of infection (light, moderate, heavy, very heavy), proportion collected, and approximate total present. Collect a sample of *ingesta* in 10% neutral buffered formalin from the mid-region of the large intestine.

4.4 Liver and Gall Bladder

Anatomical Notes	Samples	Photographs
<ul style="list-style-type: none"> Liver - four lobes can be distinguished: right, left, quadrate, and caudate The liver (Fig. 5) and gall bladder are situated in the <i>cranial</i> quadrant of the abdominal cavity, just dorsal and <i>cranial</i> to the stomach 	<ul style="list-style-type: none"> 300 g of liver (from the <i>caudal</i> tip of the right lobe for toxicology analysis) Sections of liver for histology, virology, bacteriology Any abnormalities 	<ul style="list-style-type: none"> Liver, <i>in situ</i> and removed Gall bladder, <i>in situ</i> and removed Any abnormalities

Remove the liver and gall bladder by cutting at the cranially situated connection between the *cranial* border of the liver and the diaphragm, where it is fused with the pericardium, severing the *cranial* ligaments of the liver. Continue the dissection caudally, cutting the ligaments between the liver and diaphragm. At the *caudal* border of the liver, sever the portal vein. Remove the entire liver and gall bladder. Avoid tainting the surfaces if samples are to be taken for contaminants analysis.

Examine the **gall bladder**. Note if it is swollen or abnormally distended. Remove the *haemostat* and determine if the bile duct is *patent* (allows free flow of bile). Note the quantity, colour, clarity and consistency of the bile. Cut along the bile duct. Search for obstructions if the bile was not free flowing and examine the *mucosa* of the bile duct and the gall bladder for any abnormalities (reddening, cysts, unusual thickness, stones, and parasites). Describe the colour and lustre of the *mucosa*.

Examine the surface of the **liver**. Note the colour, degree of rounding of the edges, presence or absence of pigmentation and any abnormalities (discolouration, *tubercles*, cysts, abscesses, spots (*foci*), *nodules*, *fibrosis* or scarring). Remove a sample from the *caudal* tip of the right lobe for toxicology analyses (see Section 5.2.4). Make transverse cuts through remaining portions of the liver to examine the internal structure. On the cut surface, determine if the tissue within the membrane bows outward from the plane of the cut (indication of a swollen liver). Describe any exuding fluids. Examine for parasites and estimate the degree of infection present. Preserve a small slice of liver tissue in 10% formalin. The sample should be taken from a location away from major bile ducts, areas of bile spillage, or bile stained areas of tissue.

4.5 Pericardial Cavity, Heart, Major Blood Vessels and Mammary Glands

Anatomical Notes	Samples	Photographs
<ul style="list-style-type: none"> Heart - midline structure with a double ventricular apex, a double subvalvular conus and a dorsal left atrium (Fig. 10) Lies in a vertical plane at right angles to the dorsal lungs Heart is flat and more broad than long 	<ul style="list-style-type: none"> Section of heart from right and left ventricles Whole heart if <i>congenital</i> abnormality is suspected Blood (20 ml) Pericardial fluid for bacteriology, virology Any abnormalities 	<ul style="list-style-type: none"> Heart <i>in situ</i> Any abnormalities

The pericardial cavity houses the thymus, heart, and associated vessels and lies dorsal to the sternum in the *cranial* portion of the thorax. It is lined by a firm, *fibrous* parietal pericardium and a thin visceral pericardium (epicardium) that covers the myocardium and base of the great vessels. The pleural cavities lie on either side of the vertebral column, in part encircled by the fixed ribs and in part by the much more extensive component of the thorax that lies dorsal to the abdominal cavity. Dorsally, the bronchi and oesophagus separate the pericardium and pleura, and the great vessels are separated laterally by the diaphragm (Rowlatt & Marsh 1985).

To reach the **pericardial cavity** incisions are made along the ventral midline from the xiphoid process of the sternum to the chin (Incision C, Fig. 1), from the chin postero-laterally to each *axilla*, and from each *axilla* caudally to the open abdominal cavity (Incision D, Fig. 1). This creates two slabs of tissue. Remove the skin over each area and examine the underlying musculature for signs of *trauma*. Examine the mammary gland tissue in females (Fig. 8) for lactation, cysts, *haemorrhage*, *inflammation*, or other abnormalities. Note the presence and nature of any fluids present when cut (blood, milk, *pus*), the colour of the underlying mammary tissue, and the presence or absence of *fibrous* tissue, lumps or abscesses. Remove the superficial musculature ventral to the sternum, cut the cartilaginous tissue around the sternum, and lift it free. Examine the **thymus**, located along the *cranial* wall of the pericardial cavity.

Examine the pericardial membranes for any lesions (e.g. *haemorrhage*, *fibrin* deposition or cachexia – see below). Determine if fluid is present in the pericardial sac, and note its colour, consistency, clarity, and amount. Take a sample of the fluid for microbiological culture. Photograph the heart *in situ*. Examine the fat overlying the ventral surface and in the interventricular groove. Describe the amount, colour, and texture of the fat. Note any abnormalities in the position or appearance of the heart, including the relative size of the right and left ventricles and the profile of the ventral border. Note if any *congenital* anomalies are apparent on external examination.

Begin the **removal of the heart** by cutting the pericardium down to the diaphragm, and then cut the right hemidiaphragm *lateral* to the right ventricle (Fig. 10). Cut the right pulmonary artery and vein, and then the *caudal* vena cava, as *distal* to the heart as possible. Cranially, locate the major branches of the aortic arch. These are, from right to left, the brachiocephalic trunk, left common carotid and left subclavian arteries. Cut the right common carotid and right subclavian arteries approximately 5 cm *distal* to their common junction with the brachiocephalic trunk. Cut the left common carotid approximately 5 cm *distal* to its junction with the aorta. Isolate the left subclavian from as much of the surrounding connective tissue as possible and then cut. Once the major arteries are free, cut the left hemidiaphragm *lateral* to the left ventricle as deeply as possible, severing the left pulmonary artery and vein. From the right side cut between the dorsal surface of the heart and the right bronchus, cutting the aorta, which passes dorsal to the left bronchus, as far distally as possible. Remove the heart.

Examine the heart externally. Note if the muscular wall of the heart is firm or flabby, if either of the ventricles show abnormally rounded bulging (*dilatation*), or if there is any evidence of *hypertrophy*. Examine the external surface for the presence of scars, abscesses, *haemorrhage*, or other unusual features. Note the presence of any clear vesicular gelatinous material adhering to the internal lining of the heart (this is also occasionally visible on the exterior of the heart). The presence of this material is a condition called *cachexia* or serous atrophy of the pericardial fat ('water fat'), and is an indicator of severe starvation in dugongs (an internal examination of the heart will also reveal this condition).

Examine the heart internally by cutting through the ventral surface of the right atrium to the right ventricle. A sample of blood (minimum 20 ml) from the heart should be frozen for toxicology, contaminants analysis, and if botulism is suspected. Examine the endocardium, chordae tendineae, and papillary muscles for *inflammation*, scars, tears, *haemorrhage*, *plaque*, or other abnormalities. Examine the dorsal and ventral cusps and the smaller *medial* and *lateral* cusps of the right atrioventricular valve for *inflammation*, thickness, hardening, growths, or other abnormalities. Continue the incision from the right ventricle through the pulmonary trunk, examining the three semilunar cusps of the pulmonary valve. Turn the heart over and from the dorsal aspect make a new incision from the left atrium to the left ventricle, examining the left atrioventricular valve and interior as on the right side. Make a third incision in the dorsal side of the heart from the left ventricle through the ascending aorta. Examine the three semilunar cusps of the aortic orifice for growths, hardness, wear, holes, and other features. Examine the wall of the aorta and the coronary arteries for *plaque* build-up, *emboli* or *thrombi*, noting colour, size, thickness, and texture. Note if the interventricular and interatrial septa are complete. Examine the heart for evidence of *coarctation* or *aneurysms*. Note if blood is present in the left ventricle, and whether it is clotted. However, large clots present within the heart may also be a *post-mortem* development.

Note the colour of blood and the sheen or lustre of the internal lining of the heart. Note the presence or absence of *chicken-fat clots*, or if there is no evidence of clotting. *Post-mortem* clots can be distinguished from thrombi in that they are uniform in colour, smooth and shiny, uniform in texture, and unattached but moulded to the vessel in which they are formed. *Ante-mortem* thrombi are often a layered mixture of red and grey, *friable*, dull, roughened, stringy, and attached to the walls of blood vessels.

The heart should also be examined for evidence of *congenital* anomalies, particularly in young animals. Examine the ductus arteriosus between the pulmonary artery and the aorta with a probe to determine if it is *patent* or has closed, as is normal in larger, older animals, remaining as the ligamentum arteriosum. Examine the pulmonary artery for *stenosis* or constriction. Take tissue samples for histology including samples of any suspected abnormalities.

Major blood vessels should be inspected routinely during examination of the organ systems they supply. In calves, particular attention should be paid to the umbilical vessels for *necrosis* or abscesses.

4.5.1 Blood Sample

Whenever possible collect 20 ml of blood in a sterile tube for hormonal and other biochemical assays. Blood will usually have to be obtained with a syringe from the left ventricle as soon as possible after death. Allow it to clot in a cool place for several hours (if you are working on a beach, placing the tube at an angle in the sand in a shady place is fine). Remove the serum with a Pasteur pipette. If possible, centrifuge the serum (keep the supernatant) before freezing. It should keep indefinitely at -20°C.

With a fresh (Categories 1-3) carcass, blood samples can provide valuable data on blood chemistry, haematology and pathology.

4.6 Respiratory System

Anatomical Notes	Samples	Photographs
<ul style="list-style-type: none"> Lungs are located in the pleural cavity (Fig. 8) Lungs are long, wide and thin 	<ul style="list-style-type: none"> Lung, for histology, virology and bacteriology Parasites or trematodes Diaphragm Any abnormalities 	<ul style="list-style-type: none"> Lungs, <i>in situ</i> and removed Any abnormalities

Dugongs have far more *fibrous* tissue in their lungs than terrestrial animals. As a result, a normal dugong lung may not collapse as convincingly and will feel firmer than may be expected. Lungs not yet collapsed in the carcass are a sign of recent death (D2 or D1).

Each lung is a single, undivided lobe and is located in the dorsal part of the thoracic cavity. The lungs are separated from the abdominal cavity on either side of the vertebral column by the right and left muscular hemidiaphragms (Fig. 8). Pleural cavities extend from the first to the sixteenth thoracic vertebrae.

Examine each **hemidiaphragm** for tears. Carefully cut and remove each hemidiaphragm beginning at the *cranial* and *lateral* edges and ending down the midline, first ensuring that no fluid remains in the abdominal cavity to run into the pleural cavities. Note the amount, colour, and consistency of fluid in each pleural cavity. Note if *pus* or *fibrin* is present. Obtain a transport sample if appropriate.

Examine the **lungs *in situ*** for adhesions or punctures by passing the hand completely around the lungs. Begin removal of each lung by severing the primary bronchus and carefully cutting through the pulmonary ligament along most of the length of the lung between its *medial* edge and the vertebral column. Remove each lung and place on a flat surface for further examination. As occurs in cetaceans (whales and dolphins) (Hare & Mead 1987), dugongs do not have a breathing reflex so they do not inhale water when they pass out; drowning in dugongs is usually a matter of asphyxiation (the condition of being deprived of oxygen) and is often referred to as “dry” drowning. “Dry” drowning is generally not evident at *necropsy* or histological examination (see Section 7.6 and 7.7).

Describe the external appearance of the lungs (colour, lustre, consistency and texture), and examine the pleural surfaces for any abnormalities (e.g. *fibrinous inflammation*, *verrucous* growths, discoloured patches, abscesses, adhesions, cysts, *spicules*) or any other unusual features. Poke the lung with a finger and describe the response of the tissue: note if it remains depressed or retains its shape, if it is well rounded, or if it collapses. Examine the lungs for areas of *hepatisation*, in which the tissue has about the same degree of firmness as liver. A hepatised lung is incompressible, and when cut with a knife a watery fluid will run out. A collapsed lung (atelectasis) is similar to liver in consistency but will be depressed and shrunken rather than swollen, and no fluid can be squeezed from its cut surface. If the lung tissue seems distended and firm in consistency, cut through a lobe and squeeze the edges; if a watery fluid emerges, perhaps a little tinged with blood, the lung is oedematous; if the fluid is definitely bloody the lung is congested; if there are drops of *pus* it is pneumonic (see Fig. 21 showing bronchopneumonia – caseous nodules). Photograph unusual features.

Using scissors, open the bronchi from the ventral surface working towards the *caudal* end of the lung. Cut the ramifications of the bronchioles as far as possible and note the presence and quantity of mucus, blood, froth, *ingesta* (through terminal *aspiration*), obstructions, *fibrin*, reddening or *pus*. Occasionally nasal flukes (*Cochleotrema indicum*) may be present; if so, note their numbers and position, and collect (Section 5.2.2). Other parasites may be present in

bronchioles (e.g. see Fig. 22). Take transport swab and tissues samples for histopathology when appropriate. Obtain weights of each lung if required. Photograph any unusual features.

Returning to the body cavity, examine the parietal pleura for any abnormalities. Examine ventral surfaces of the ribs for evidence of *fractures* or exostoses (bony outgrowths) and intercostal (between rib) spaces for haemorrhaging.

4.7 Urinary System

Anatomical Notes	Samples	Photographs
<ul style="list-style-type: none"> Kidneys are located in the <i>caudal</i> quadrant of the abdominal cavity, attached to the ventral surface of each hemidiaphragm (Fig. 8) 	<ul style="list-style-type: none"> Kidney (300 g from <i>caudal</i> tip of right kidney for contaminants analysis) Section of kidney for histology Urine Any abnormalities 	<ul style="list-style-type: none"> Kidney, <i>in situ</i> and removed Any abnormalities

The dugong kidney is an elongated, fusiform gland with narrow, rounded poles thicker dorsoventrally then mediolaterally. The surface is smooth and covered with a thick but strong *fibrous* renal capsule (Fig. 8).

Note the relative size, shape, and position of each **kidney**. Make an incision along the length of each renal capsule, exposing the outer surface of the kidney. Photograph and describe the presence (if any), amount, colouration, and consistency of fat overlying each kidney. Locate each ureter and clamp with a *haemostat* and sever cranially. Remove both kidneys and remove each encapsulating renal membrane and adhering tissue. Obtain weights if required. Remove a sample from the *caudal* tip of the right kidney for contaminants analysis (see Section 5.2.4). Examine the remaining kidney, making transverse slices. Describe the colour and presence or absence of necrotic areas. Examine each kidney internally, and note the definition between the cortex and medulla, the presence or absence of cysts or abscesses, and the nature of any fluids. Collect tissue samples in 10% neutral buffered formalin for histology.

When working on the reproductive system (Sections 4.8 and 4.9), follow the ureter to the urinary bladder and note the degree of bladder distension (dissection of the urinary tract needs to be reserved until during or after dissection and removal of the reproductive tract). Carefully puncture the bladder with a sterile syringe and collect a urine sample. Measure the amount of urine present, and its consistency, clarity, and colouration. Freeze urine samples not intended for culture, particularly if starvation or *emaciation* is suspected and *ketone* determinations are desired. Samples may also be frozen for *osmolality* studies. Examine the ureter, urinary bladder, and urethra for any abnormalities (obstructions, *inflammation* of the *mucosa*, cysts, stones, tumours, thickenings, folds, or haemorrhages).

4.8 Female Reproductive System

Anatomical Notes	Samples	Photographs
<ul style="list-style-type: none"> Each ovary lies in a peritoneal pouch hidden in the dorsal abdominal wall <i>posterior</i> to the kidney and <i>lateral</i> to the ureter (Fig. 8) Graafian follicles and corpora lutea may be seen on the dorsal surface of the ovaries (Fig. 23) 	<ul style="list-style-type: none"> Ovary or entire reproductive tract (if desired) Small embryo in uterus (if present) Large foetus from uterus with placenta and membranes attached (if present) Any abnormalities 	<ul style="list-style-type: none"> Entire reproductive tract <i>in situ</i> Embryo or foetus (if present) Any abnormalities

The female reproductive system is located in the *caudal* quadrant of the abdominal cavity (Fig. 8). **To locate the ovaries**, trace the uterine horns to the abdominal wall or feel along the dorsal abdominal wall on each side immediately *caudal* to the kidneys. The ovaries of the dugong are flattened ovoid organs and may be difficult to find, especially in young dugongs. A single ovary in an adult female is about 10 cm long and 7 cm wide. The ovaries are attached to the *parietal peritoneum*, ventro-*lateral* to the kidneys, and ventro-*lateral* to the hemidiaphragms. The dorso-*lateral* aspect of each ovary shares a common wall with the peritoneum (see Marsh 1981).

Examine and photograph the entire reproductive tract *in situ* and describe any abnormalities (*haemorrhages*, *inflammation*, or abscesses). The germinal epithelium of the ovary is covered by a complete bursa (Fig. 23a), which forms the dorsal wall of the pouch and is connected dorsally to the *caudal* end of the almost horizontal diaphragm by a strong peritoneal fold. Cut the bursa membrane encapsulating the ovaries and dissect each entire ovary free but leave the uterine horn attached. Great care should be taken to remove the entire *cranial* pole of the ovary. Each ovary should be left attached to the corresponding oviduct and uterine horn.

Inspect and photograph each ovary and note the size, shape, colour, presence, and quantity of ovarian follicles (Fig. 23b), corpora lutea (Fig. 23c), and corpora albicantia (note: this can be done after the *necropsy* is completed). Ovarian follicles are about 1 cm in diameter, blister-shaped with clear or translucent jelly-like contents. Corpora lutea are similar, but filled with solid, creamy coloured glandular tissue. The dugong has a large and variable number of corpora lutea associated with each pregnancy. Corpora albicantia are smaller, brown and irregularly shaped and can be seen and counted in sliced ovaries. The number of corpora albicantia generally increases with age. Remove and weigh each ovary and measure its greatest length and width. Tie a string around the right ovary as a marker. Fix the ovary intact (i.e. without slicing it) in 10% neutral buffered formalin (or 10% seawater formalin).

Examine the uterine horns and associated *fascia* for deposits of fat. Describe the amount, consistency, and colour. Photograph the fat-laden areas. Tie a string around the right horn of the uterus. Dissect free both uterine horns up to the body of the uterus. Slice longitudinally along each horn into the *lumen* and examine the endometrium for *haemorrhage*, *placental scars*, or banding. If the animal is pregnant, preserve small embryos undisturbed in the carefully injected uterus with 10% neutral buffered formalin. It is important to retain the apposition of the foetal and maternal parts of the placenta as completely as possible. Larger foetuses with the placenta and membranes attached should be removed from the uterus, carefully photographed, measured, and injected with and preserved in formalin or frozen.

Check the uterus and vagina for mucus or seminal fluid. Make a smear on a glass slide if seminal fluid is suspected. Note any anomalies and preserve in 10% neutral buffered formalin.

If the entire female reproductive tract is to be collected, dissect around the urogenital aperture, deep into the constrictor vulvae muscle to the abdominal cavity. Collect the vestigial pelvic bones on each side of the urogenital opening, lying deep to the cutaneus trunci muscle. Dissect free and remove the entire vagina, urinary bladder, uterus, uterine horns, and ovaries.

If the entire tract cannot be preserved intact, separate it between the uterus and vagina at the *fornix* of the vagina, just *proximal* to the cervix.

Fixatives should be injected into the uterine and vaginal cavities and the whole tract immersed in 10% neutral buffered formalin (or 10% seawater formalin) for several weeks. It is best to fix the tract in a container about 30 cm deep and large enough for it to be stretched out horizontally. The tract will tend to float and should either be weighted or covered with paper towelling soaked in the buffered formalin solution.

4.9 Male Reproductive System

Anatomical Notes	Samples	Photographs
<ul style="list-style-type: none"> • Testes are permanently situated in the abdomen (testiconda) • Each testis lies <i>caudal</i> and slightly <i>lateral</i> to the corresponding kidney 	<ul style="list-style-type: none"> • Slice of testis • Slice of epididymis • Entire reproductive tract if required • Any abnormalities 	<ul style="list-style-type: none"> • Reproductive tract <i>in situ</i> • Any abnormalities

The male reproductive system (see Marsh & Glover 1981) (Figs. 5, 12 and 13) is located in the *caudal* section of the abdominal cavity. The **testes** are attached to the peritoneum overlying the *ventro-lateral* surface of the kidney. In immature animals the size of the testes appears to increase with body length. The size of the testes in an adult dugong depends on whether they are reproductively active (i.e. producing spermatozoa).

Examine each **testis** (Fig. 12). Locate the head of the epididymis and follow it to the seminal vesicles by way of the ductus deferens. The epididymis runs along the *lateral* edge of each testis. Spermatozoa are stored in the *caudal* end of the epididymis. The seminal vesicles are bilateral and located on the dorsal aspect of the urinary bladder (the urinary bladder is just *cranial* to the anus and located at the *proximal* end of the body of the penis). Examine and photograph the entire reproductive tract *in situ* and describe any abnormalities (haemorrhages, *inflammation*, or abscesses). Note the colour and quantity of fat deposits on the ductus deferens.

Cut the membranes surrounding the right and left testes. Dissect free each testis with the epididymis and ductus deferens attached. Free the right and left ductus deferens to the base of the seminal vesicles. Remove the entire reproductive tract, severing ventral to the urinary bladder. Measure the greatest length and width of each seminal *vesicle* and examine internally. Separate testes from epididymides with scissors (tie a string around the right testis for reference) and take weights and measurements (greatest length x width) of each testis within its capsule. It is also useful to weigh each epididymis and the seminal vesicles. A 5 mm cube of tissue for histology should be cut from the centre of one testis (suggest standardising on right testis) and a similar cube from the corresponding epididymis at level 1 or 2 (Fig. 13). Both should be fixed by immersion in Bouin's solution for at least 24 hours and stored in 70% ethanol until required for routine histological processing.

If the entire male reproductive tract is required, dissect around the bulbocavernosus muscle, freeing the entire penis, urinary bladder, and seminal vesicles with testes, epididymides, and ductus deferens attached. Remove and save the right and left vestigial pelvic bones on each side of the bulbocavernosus muscle at the base of the penis. Examine, photograph, and fix by

injection with and immersion in 10% neutral buffered formalin. Slit each testis before immersing to allow proper penetration of formalin.

If the entire tract cannot be collected, separate it between the root of the penis and the urinary bladder, preserving the testes and epididymides with the seminal vesicles and urinary bladder attached in 10% neutral buffered formalin, after slicing several times to allow proper penetration of formalin.

4.10 Head and Neck Region

Anatomical Notes	Samples	Photographs
<ul style="list-style-type: none"> The permanent <i>posterior</i> incisors form tusks which later erupt in males and occasionally in females Dentinal growth layer groups in the tusks can be counted to estimate age (Marsh 1980) The position of the skull is deceiving as it is set further back in the head than expected (Fig. 26a) 	<ul style="list-style-type: none"> Whole brain (if possible, if not then a section) Slice of lymph node Thyroid Tusks Any abnormalities 	<ul style="list-style-type: none"> Brain <i>in situ</i> Any abnormalities

Remove the ventral skin mass from the pectoral area up to the chin. Examine the underlying muscle for any abnormalities (e.g. *trauma*, *haemorrhage*, abscesses, cysts). Cut free and remove the muscles (right and left sphincter colli profundus muscles), which run parallel to the long axis of the body, ventral to the trachea at the median. Note the large parotid salivary glands just *lateral* to each muscle. Slice through and examine the parotid salivary glands. Note their colour, size, and shape, and examine for abnormalities. Examine the lymph nodes in this region, noting size, shape and colour. Preserve a thinly sliced sample in 10% neutral buffered formalin. Take a transport swab if required.

Just dorsal to the sphincter colli profundus muscles are the right and left sternohyoideus muscles. Dissect and remove the neck muscles, avoiding damage to the underlying **thyroid**. The thyroid is a bi-lobed gland usually joined by a thin isthmus, lying on both sides of the trachea just *posterior* to the larynx. Its colour may vary and it is very variable in size. Remove the thyroid (Fig. 8), examine and describe, weigh, slice and preserve in 10% neutral buffered formalin.

Slice open the **trachea** and examine the *lumen* for parasites, obstructions, mucus, froth, blood, foreign matter or other abnormalities. Note if the *mucosa* shows any reddening. Remove the trachea and examine the oesophagus (dorsal to the trachea) internally for any abnormalities (e.g. obstructions, irritation, *inflammation* or other unusual features). Remove the **hyoid bones** and examine the base of the oral cavity. The middle ear chambers are each exposed by slicing through the membrane between the basioccipital bone and tympanoperiotic bone. Examine the middle ear chambers for fluid or solid material, noting the colour, quantity, and clarity of contents.

The head can be removed from the neck by cutting between the occipital condyles and the atlas (located at the level of the humero-scapular joint). Cut through the overlying dorsal musculature and skin to remove the entire head.

Examine the dorsal aspect of the head and the lips. Make sagittal slices through each nostril and examine the nasal cavities for parasites, fluids, other material, or foreign objects. Remove the skin from the dorsal and *lateral* aspects of the head, examining the underlying tissue for signs of *trauma*, *haemorrhage*, or splintered bone. Open the mouth and count the number of erupted

teeth on each tooth row. Erupted teeth and **tusks** can later be removed from the skull after the head has been buried as a means of removing the flesh (see Section 4.11.1). Tusks to be retained for age determination can be removed using a small abrasive disc in a hand-held flexible drive (see Marsh 1980).

The **brain** can be removed by making a series of cuts on the dorsal and *caudal* aspects of the skull using an electric or hack saw. A small hatchet can also be used in field situations. An alternative technique used to remove the brain in the field involves making a single transverse cut through the head with a bone saw. Although this technique is commonly used on terrestrial mammals, appropriate landmarks have not yet been identified for marine mammals. The bone is dense and the job is tedious and physically demanding; caution should be taken not to damage the underlying tissue. Carefully pry the cut section of skull away from the cranium. Gently remove the brain, cutting major *cranial* nerves as it is lifted out; carefully remove the small pituitary gland, which is located on the mid-ventral surface, intact with the entire brain. Describe the colour of the brain and the presence or absence of surface lesions or *oedema*. Weigh the entire brain. Examine the *cranial* cavity for fluid, *haemorrhage*, or discolouration. If toxic chemicals are suspected as a cause of death but histology is still required, make a sagittal cut dividing the brain in two symmetric halves, freezing one-half and preserving the second half entire in 10% neutral buffered formalin. Otherwise preserve the brain entire in 10% neutral buffered formalin.

4.11 The Skeleton

The skeleton (described by Husar 1978, Fig. 27) is composed of extremely dense bone. *Cranial* characters are: enlarged and sharply down-turned premaxilla, nasal basin on the top of the skull extending posteriorly beyond the *anterior* margin of the orbits, nasal bones absent, zygomatic arches thick and deep, brain case small. Molariform cheek teeth (up to six per side in each jaw) are replaced from the rear by newly erupting teeth. The *anterior*-most teeth are resorbed and lost in old dugongs. Cheek teeth (Fig. 26) increase in size from front to rear except for the last, which is grooved laterally. They are subterete in cross section. The inner pair of upper incisors are resorbed early; the outer pair (tusks) protrudes into the mouth. Eight prominent alveoli (four per jaw) which may contain vestigial teeth are located in the *anterior* face of the mandible. Vertebrae number 59-62 (7 cervical, 17-19 thoracic, 4 lumbar, 3 sacral, 28-29 *caudal*).

If a closer examination of the skeleton is required, remove the right and left flippers by cutting between the head of the humerus and the glenoid fossa of the scapula. Remove as much flesh as possible and carefully slice the skin from the rest of the flipper. Remove the scapula. Trim away as much soft tissue as possible from the sides, carefully examining for *trauma*, *haemorrhage*, abscesses, or other abnormalities. Continue flensing the dorsal skin and musculature. On large specimens the *axial skeleton* can be cut in halves or thirds for ease of handling. The vertebral column is best severed by cutting from the ventral aspect with a sharp knife. Cut between the dorsally situated articular processes of the vertebrae at a direction angled towards the fluke while applying pressure by draping one section of the body over the end of the worktable or trailer.

Broken or disarticulated bones and ribs should be noted and photographed. Describe which bones are broken, numbering ribs consecutively from *cranial* to *caudal*. Describe any bony overgrowth if the wound is not recent. Note whether *fractures* occurred before or after death (this can only be determined by a pathologist or by experienced personnel). If the *fracture* is a recent, acute break note its location (tip or *distal*, middle, or *proximal* third in the case of ribs) and whether it is a hairline crack, simple break, or comminuted (shattered in pieces) *fracture*. Describe the edges and angles of the breaks. Examine any associated *haematoma* to determine the age of the *fracture* and take a sample for histological examination.

If the skull or skeleton is required (note that the skull at least should be retained for ageing), the carcass should be wrapped in shade cloth, to ensure small/fine bones are not lost, and buried in compliance with local authority (council) requirements. An alternative method used with manatees in Florida involves placing the skeleton in large drums with small drain holes at the bottom. Mandibles are disarticulated from the cranium and set next to the skull, dorsal side up. Flippers are placed flat on the bottom and far enough apart so that carpal bones and digits of separate limbs do not intermingle as the remaining flesh disintegrates. Label the skull and the outside of each barrel with a tag marked with the correct field number of the specimen. The drum is then covered with a securely fastened hardware cloth or chicken wire lid. Care should be taken to prevent smaller bones from being lost or separated from the specimen.

4.11.1 Forensic Examination of Bones

Bones should be examined for evidence of *fractures* and knife cuts (see Sections 3.5, 7.6, 7.7 and Figs. 28, 29), and the skull should be retained for age determination. Because sirenian bone is very dense, marks made by a sharp knife are very characteristic and can be indicative of entanglement or poaching activities. The marks made on the surface of the bone by a sharp knife are usually narrow and shallow. If soft tissue is present, opened edges likely will be cut evenly. Edges of soft tissue torn due to internal gas pressure, predation, and other *post-mortem* changes, are usually irregular. When poaching is suspected, the examiner should look for straight-line cuts through the surrounding soft tissues and periosteum, and narrow, generally shallow, cuts on the underlying bone. As with all forms of acute *trauma*, *ante-mortem haemorrhage* should be noted if present, and photographs taken. *Ante-mortem* injuries tend to be associated with reddening, *haemorrhage*, *fibrin* and perhaps *pus*. *Post-mortem* injuries show no signs of *trauma* to internal organs or musculature. The fractured bone and associated tissues should be retained for subsequent histological examination.

5 SPECIMEN COLLECTION AND PRESERVATION

This section outlines the use of fixatives and preservatives used in *necropsy* procedures and some specialised collection techniques. Tissue samples should be routinely collected from all organ systems for histopathology if a carcass is fresh (Categories 1-3). Particular attention should be given to collecting and examining samples from areas with gross lesions. Histological samples should include the interface between normal and diseased tissue. Neutral buffered formalin (10% neutral buffered seawater is a substitute if the regular buffer is unavailable) is a suitable fixative for general purposes; other solutions may be required for more specialised collection techniques and analyses as discussed in Section 5.2. Crushing, stretching, scraping, or otherwise damaging specimens should be avoided. All samples should be secured in durable, leak-proof containers with appropriate tags as well as internal and external labels. Any chemicals should be used with caution to avoid human health problems.

5.1 Fixatives and Preservatives

5.1.1. 10% Neutral Buffered Formalin

The most widely used fixative for wet tissue samples is 10% neutral buffered formalin. For histopathology, samples should be collected from relatively fresh (Categories 1-3) carcasses and cut into small pieces (2 cm x 2 cm x 0.5 cm) and placed in at least 10 volumes of formalin per volume of sample. Larger samples and entire organs may also be preserved in formalin, but these should be cut adequately or infused with formalin using a needle and syringe to ensure maximum penetration of formalin into tissue. Do not collect large samples that can not be adequately fixed. Fixation should be complete in one to two weeks. Samples must be checked routinely during storage to avoid loss of fluid. Note that freezing of formalin-fixed samples may destroy the sample.

10% neutral buffered formalin can be prepared as follows:

Formalin (37% Formaldehyde)	100 ml
Distilled or tap water	900 ml
Disodium hydrogen phosphate $\text{Na}_2 \text{HPO}_4 \cdot 2\text{H}_2\text{O}$	6.5 g
Sodium dihydrogen phosphate $\text{Na}_2 \text{H}_2\text{PO}_4 \cdot 2\text{H}_2\text{O}$	4.5 g

Note: Formalin should not be handled without gloves or inhaled. Always use in a well-ventilated area and ensure containers are tightly capped (see Section 3.1).

5.1.2 Bouin's Solution

Used for preserving gonad samples. Fixation occurs in less than 24 hours. Samples fixed in Bouin's fluid should be transferred to 10% neutral buffered formalin or 70% ethanol (ethyl alcohol) after 24 hours. Bouin's fluid can be prepared as follows:

Saturated aqueous picric acid	750 ml
Formalin	250 ml
Glacial Acetic Acid	50 ml

Note: Dry picric acid is explosive. Use extreme care with storage and handling (see Section 3.1).

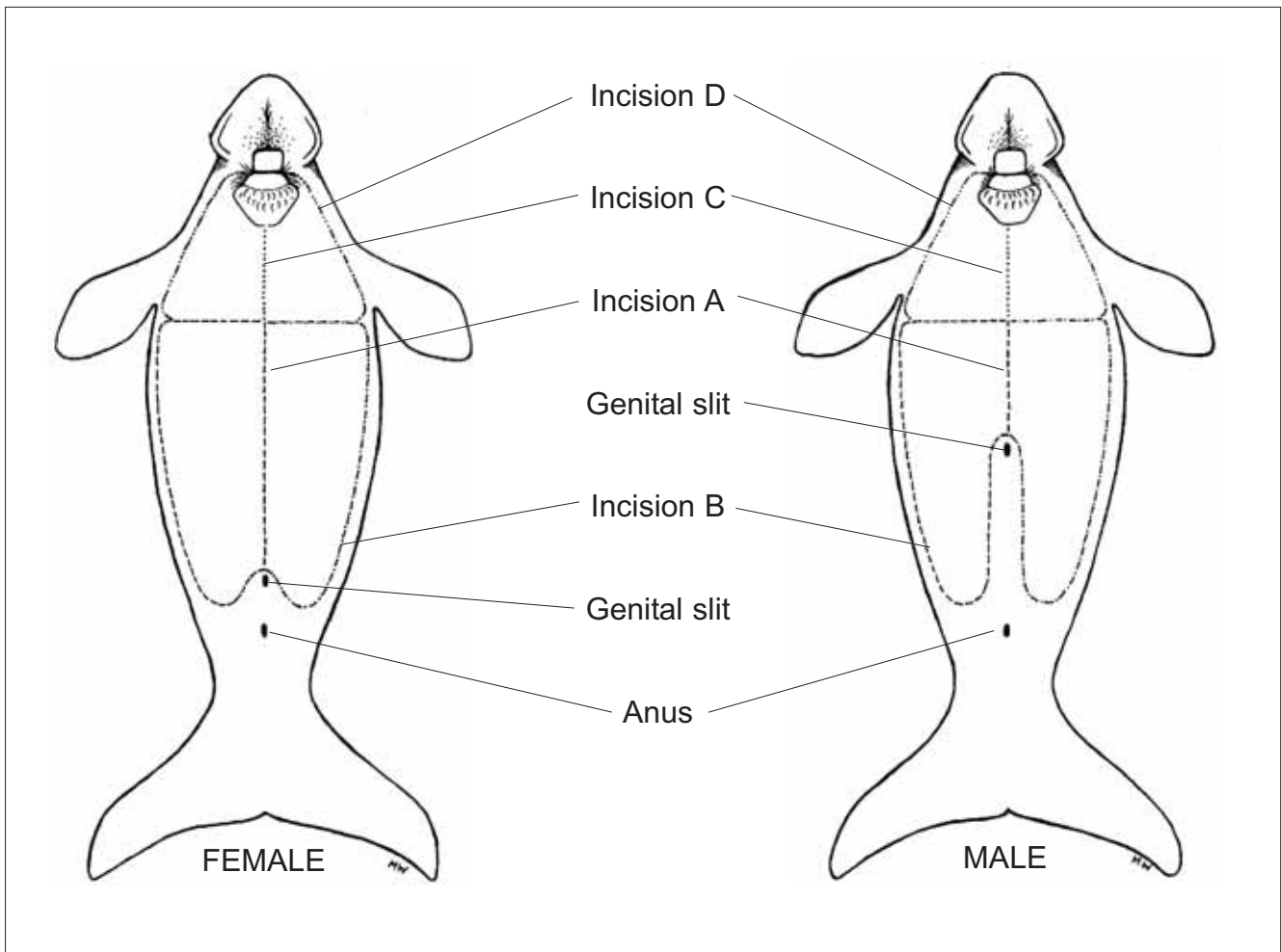


Figure 1. Incisions recommended for dugong necropsy from the ventral surface. *Illustrated by Melina Wales.*

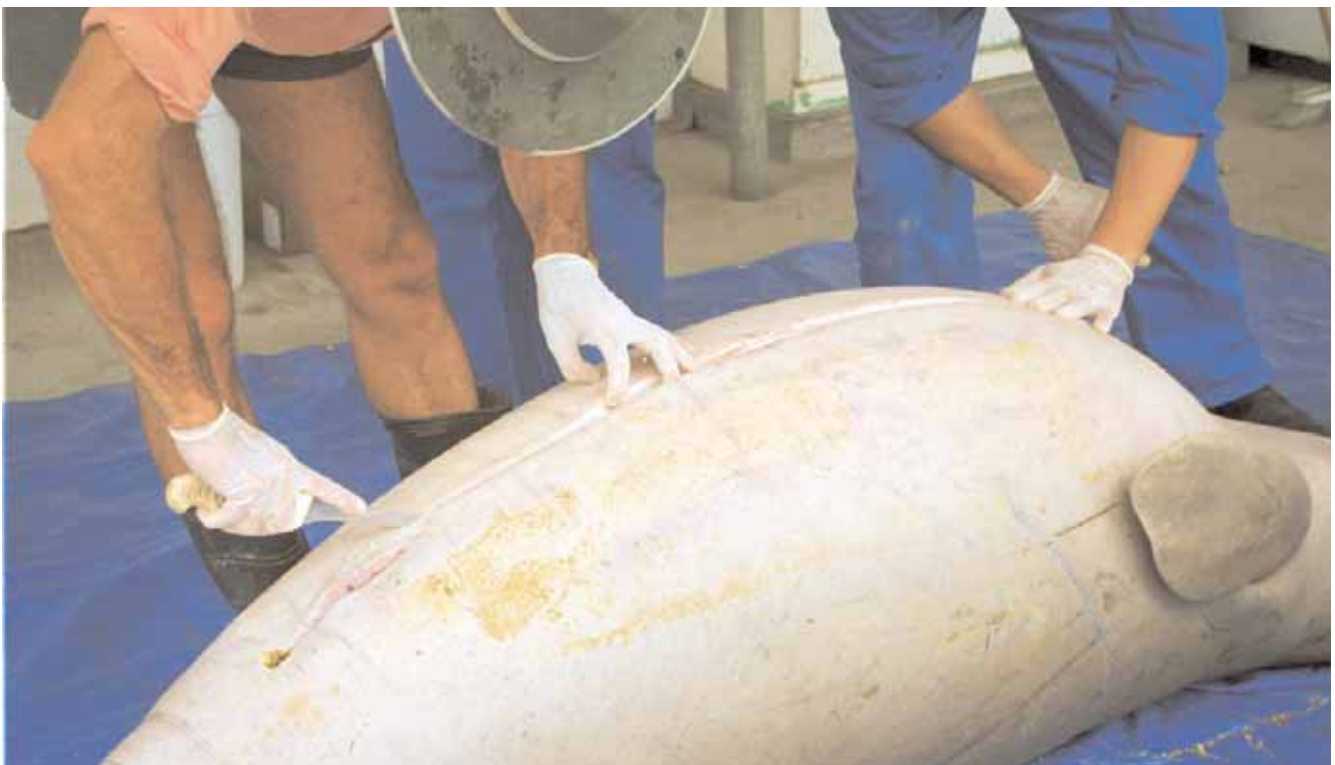

Figure 2. First incision of a dugong necropsy. *Photo courtesy of QPWS.*

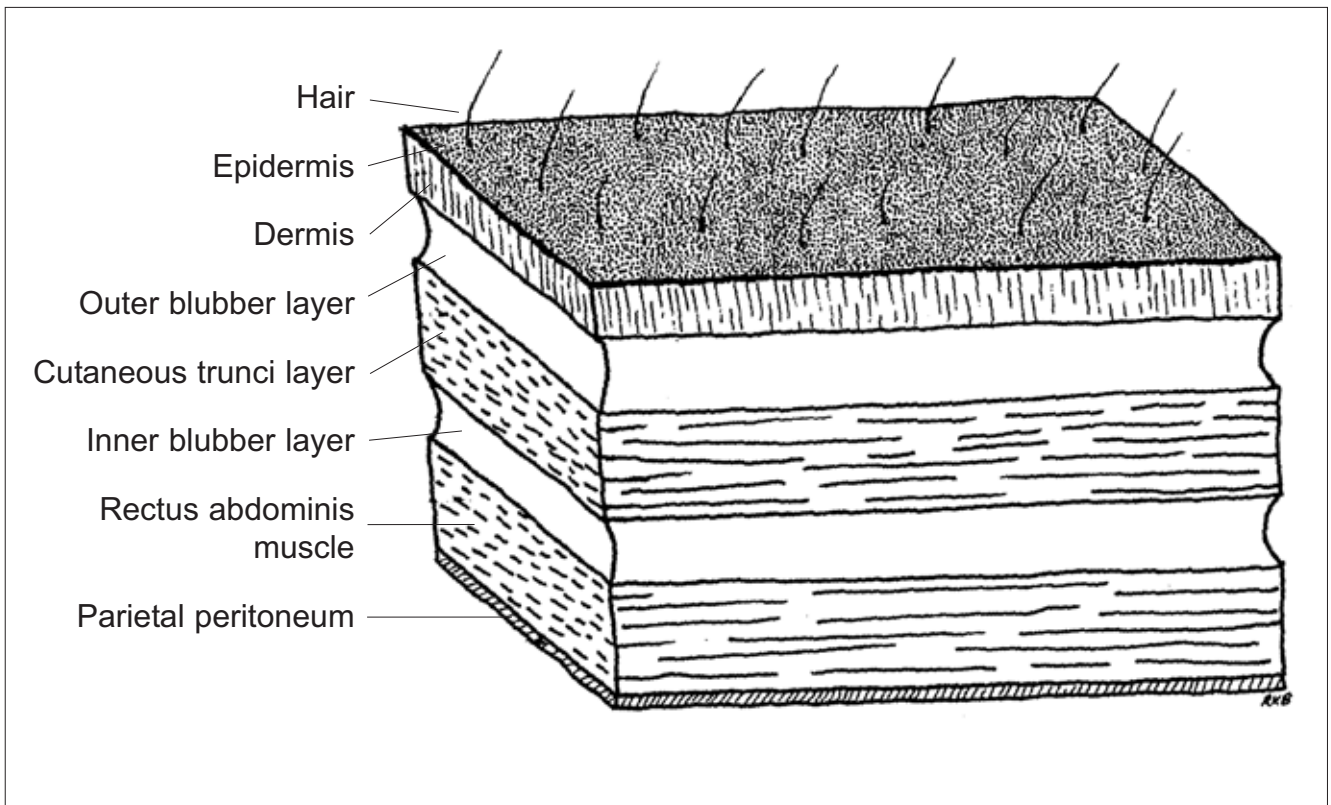


Figure 3. Cross-section of tissue layers near the ventral mid-line. *Reprinted from Bonde et al. (1983) with permission from the authors.*

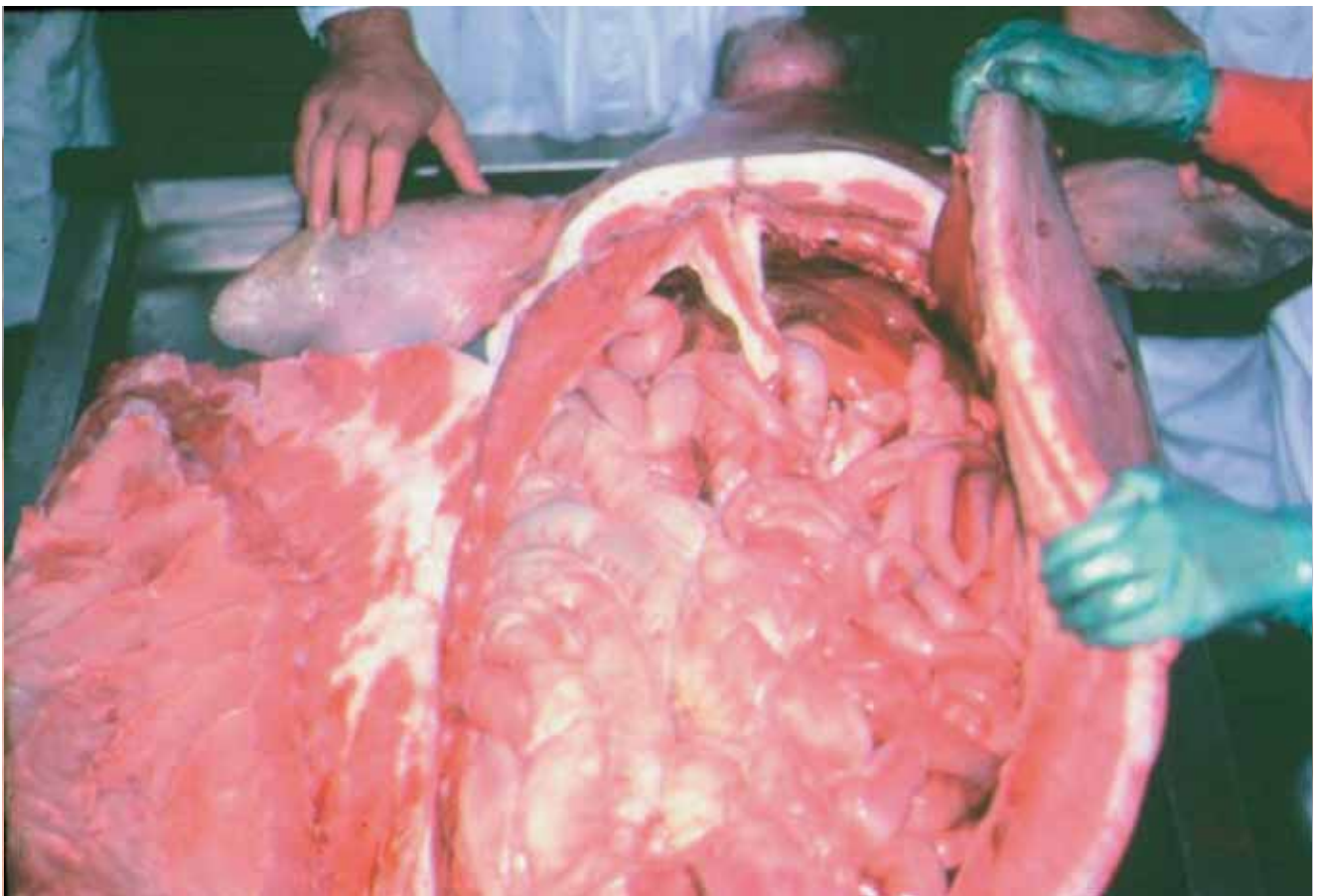


Figure 4. Removing the left slab of tissue layers after initial incisions. The right slab has already been removed and the gastrointestinal tract is exposed. *Photo courtesy of Helene Marsh.*

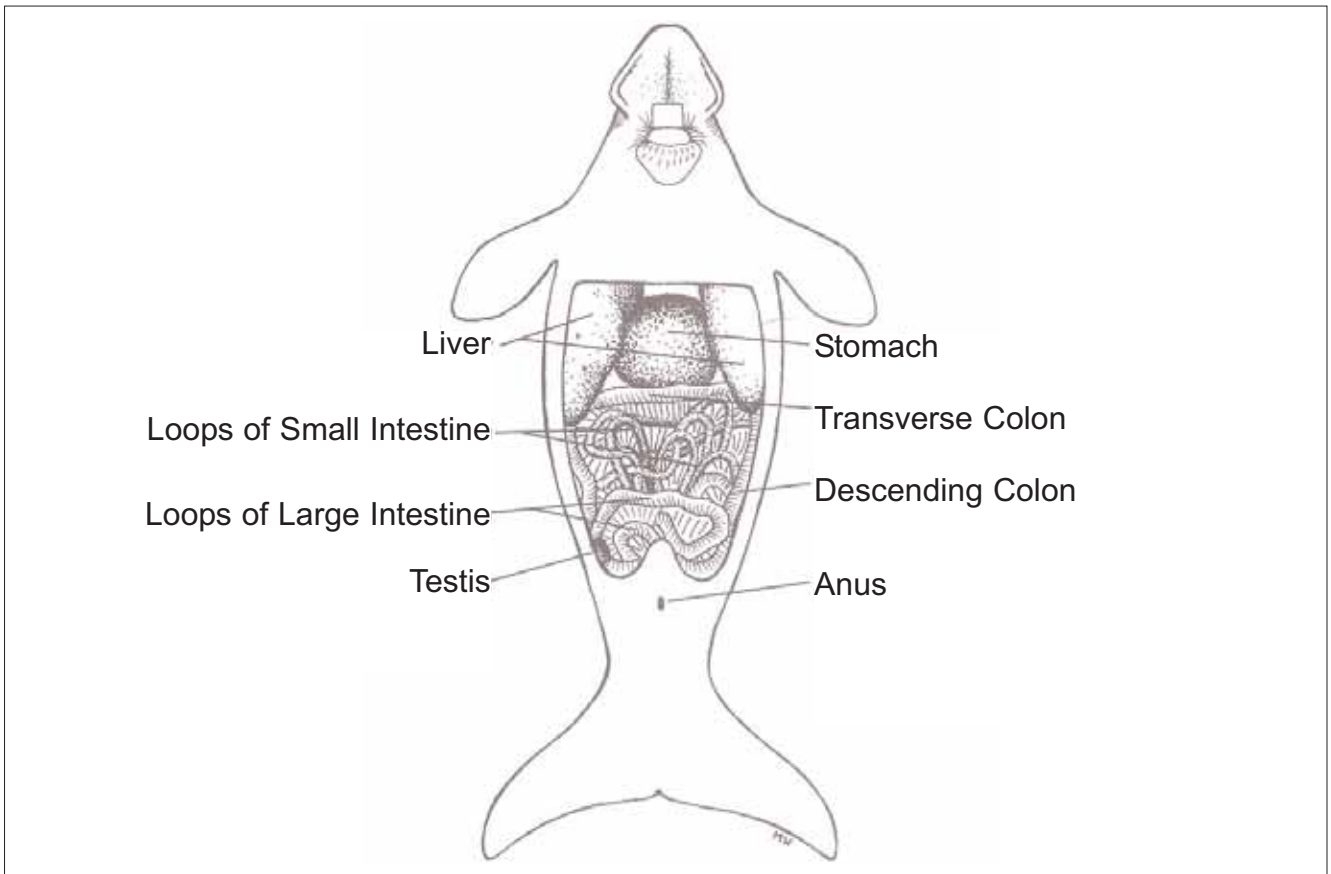


Figure 5. Exposed organs *in situ* following initial incisions and removal of dermal layers. *Illustrated by Melina Wales.*

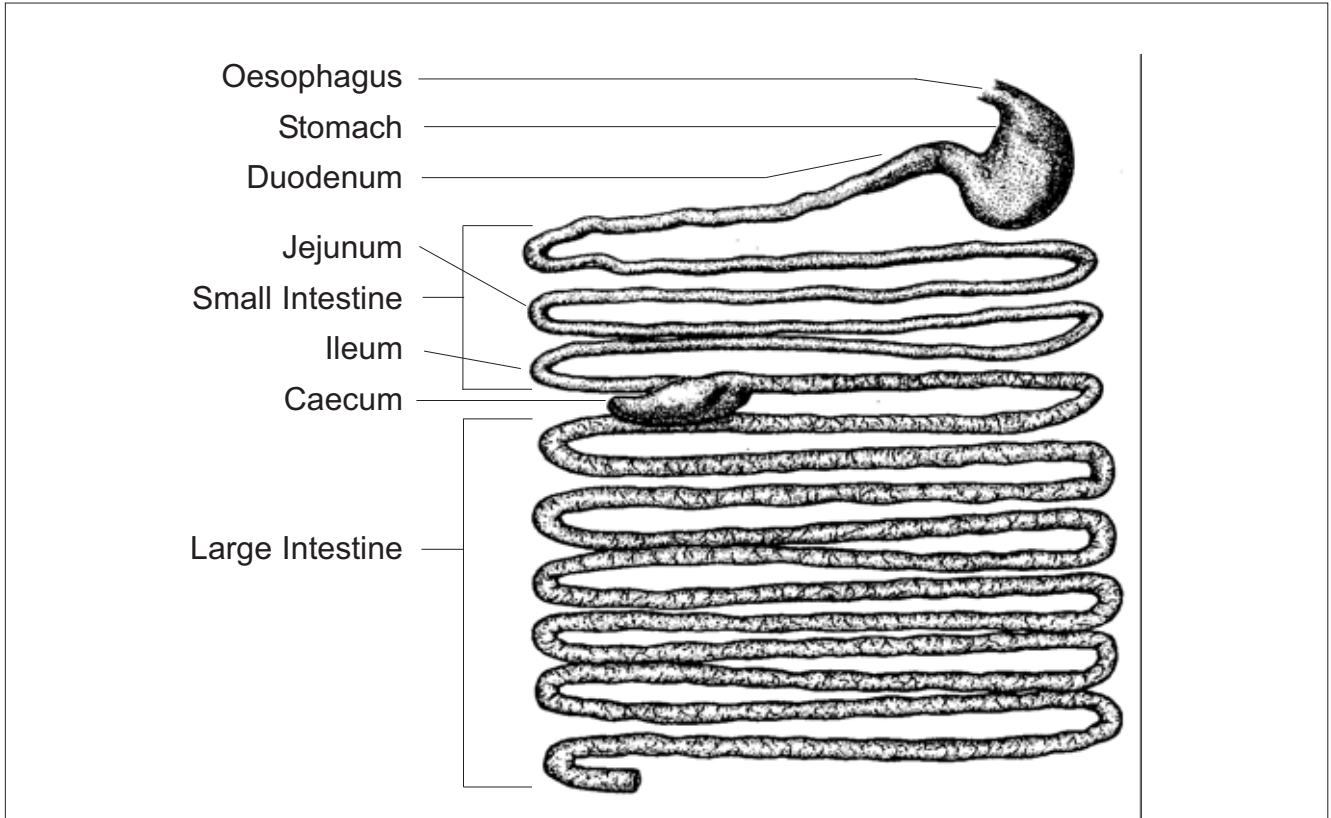


Figure 6. Stomach and intestines of the dugong. *Illustrated by Bozena Jantulik and reprinted from Bryden et al. (1998) with permission of Allen and Unwin Pty. Ltd., St. Leonards, New South Wales, Australia.*

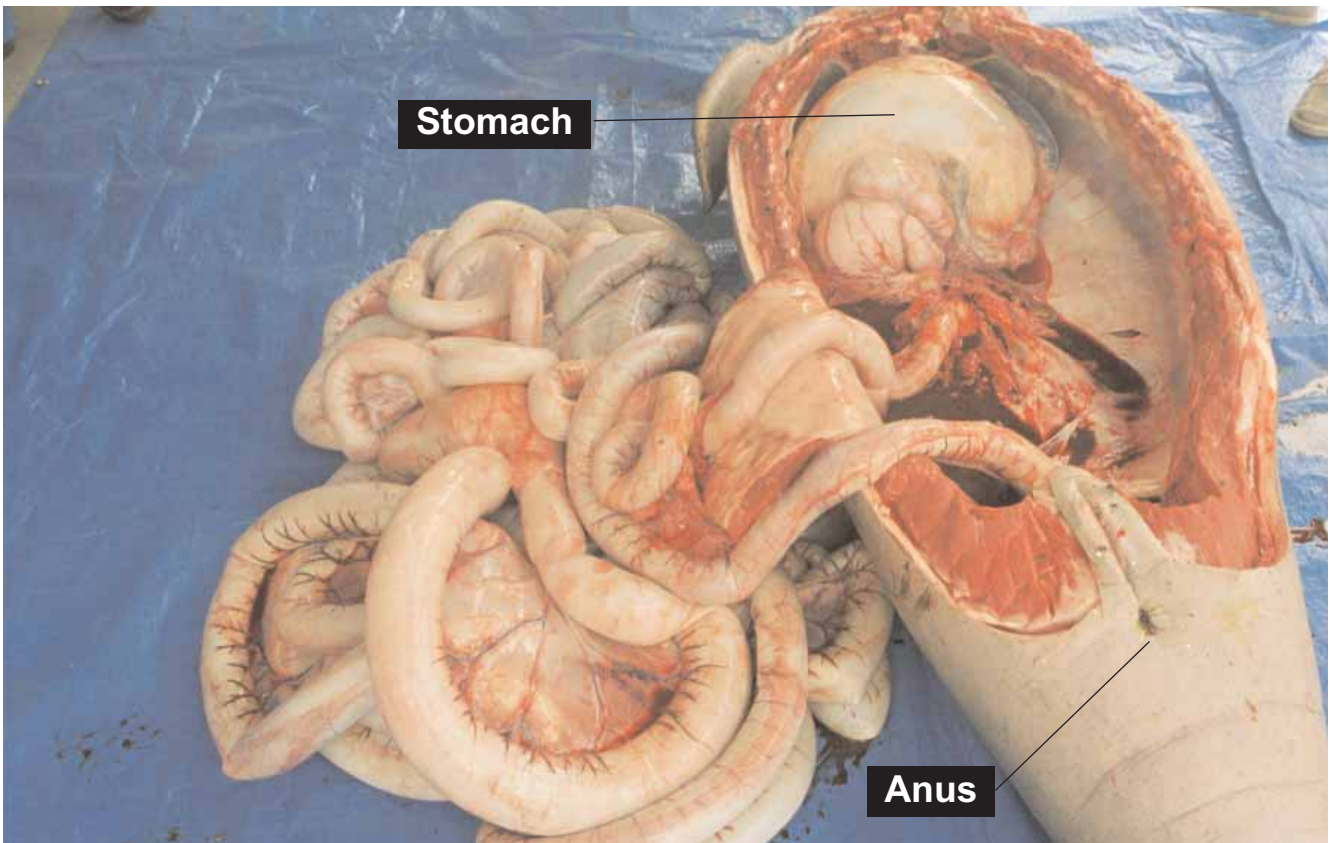


Figure 7. Carcass with liver and intestines displaced outside the abdominal cavity (stomach should be removed along with intestines). *Photo courtesy of QPWS.*

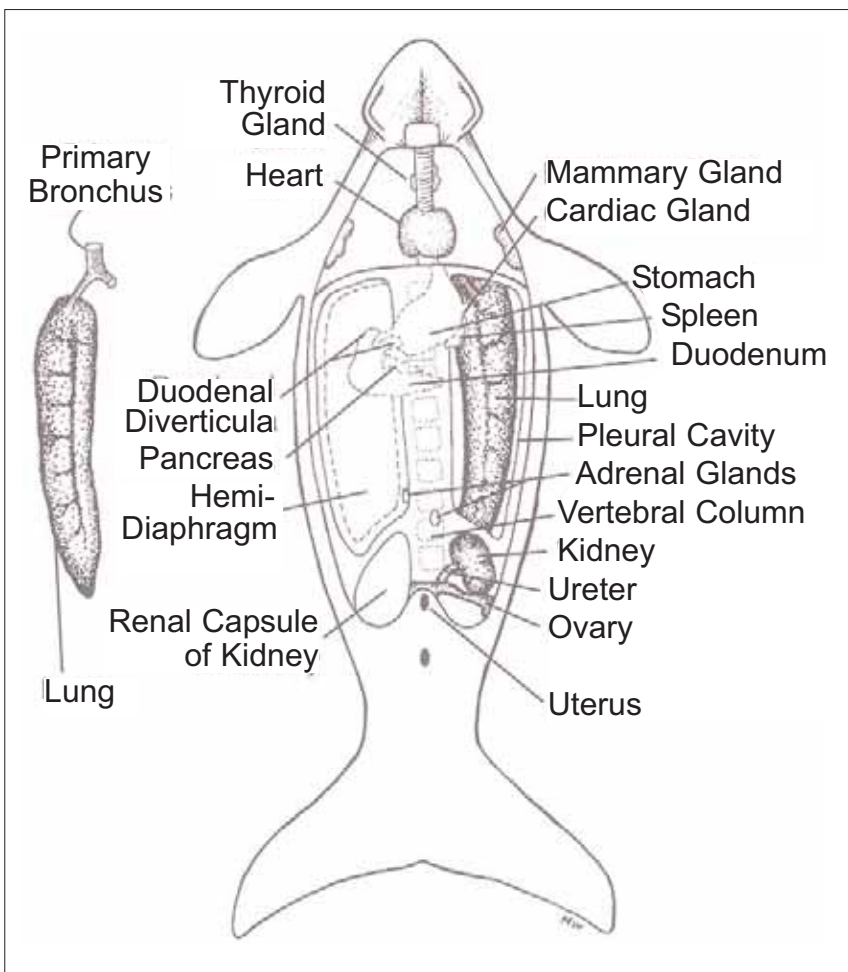


Figure 8. Pleural cavity showing location of major internal organs after removal of liver, stomach and intestines. Approximate locations of organs are indicated but are not representative of size. General locations of stomach and duodenum are shown, but by this point in the necropsy these organs should have been removed. Note kidney in particular is longer and thinner than in this figure. *Illustrated by Melina Wales.*

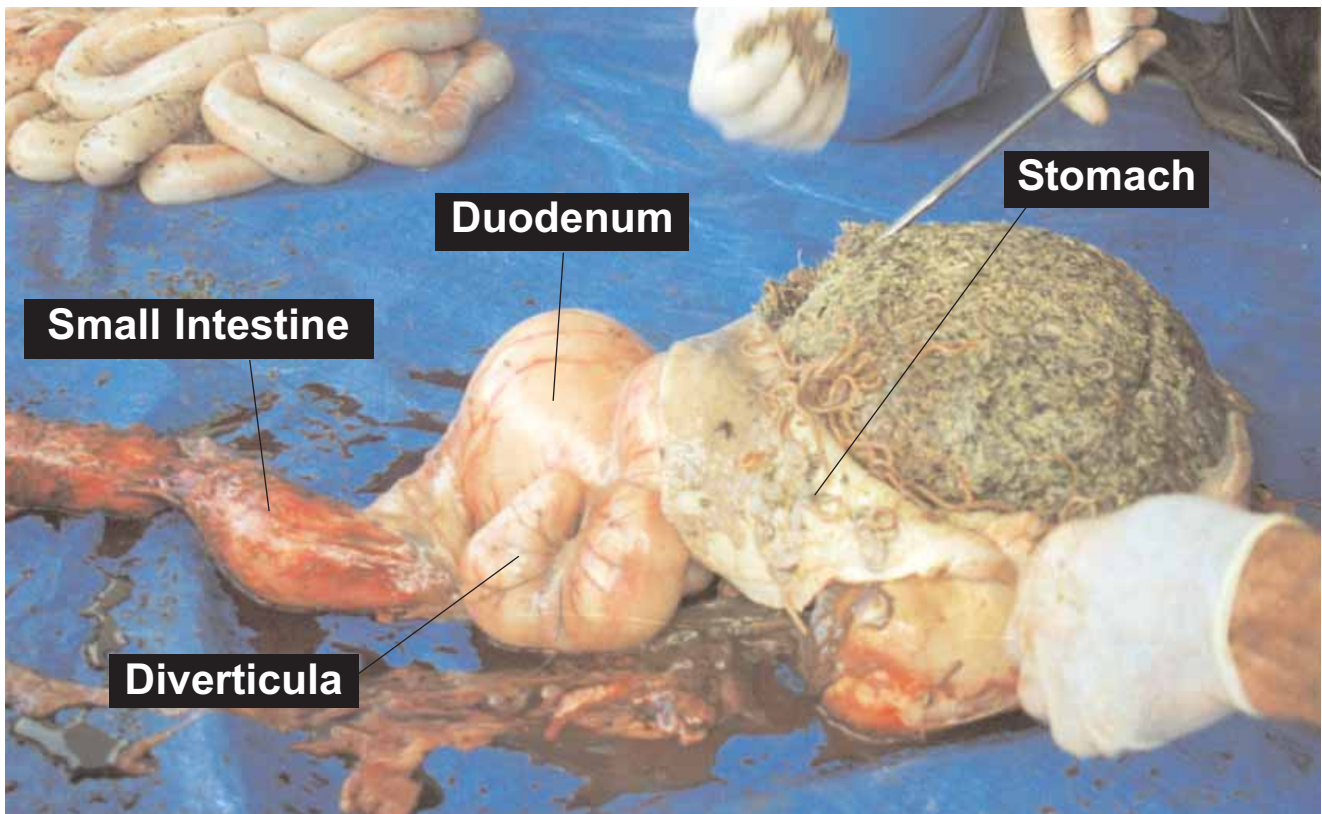


Figure 9. Opening the stomach of a dugong. The presence of nematode worms is normal in dugong stomachs. *Photo courtesy of QPWS.*

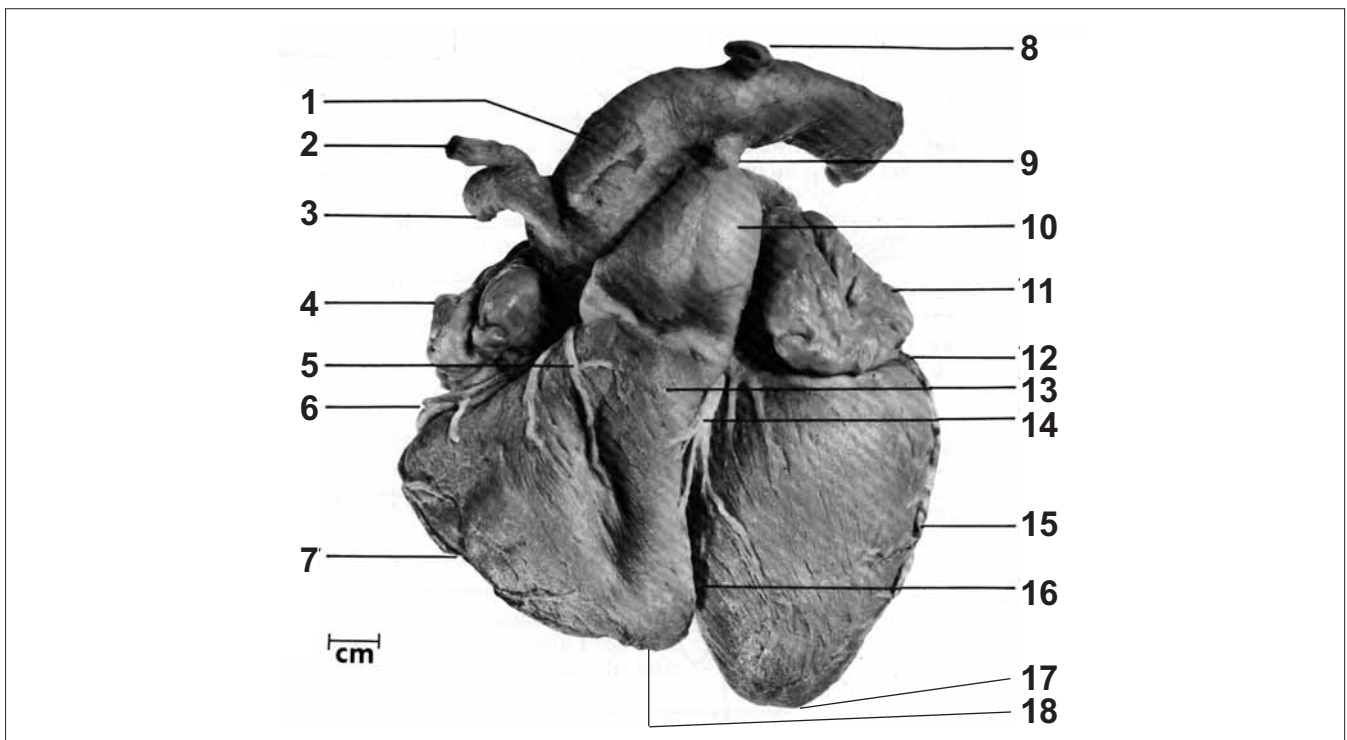


Figure 10. Ventral view of the dugong heart after removal of epicardium, fat, veins and nerves: 1. Left carotid artery, 2. Right carotid artery, 3. Right subclavian artery, 4. Right arterial appendage, 5. Conal branch of the right coronary artery, 6. Right coronary artery, 7. Right marginal artery, 8. Left subclavian artery, 9. Ligamentum arteriosum, 10. Pulmonary trunk, 11. Left atrial appendage, 12. Left circumflex artery, 13. Conus arteriosus, 14. Ventral interventricular artery, 15. Left marginal artery, 16. Interventricular sulcus, 17. Left ventricular apex, 18. Interventricular groove. *Reprinted from Rowlatt and Marsh (1985) with permission of Wiley-Liss, Inc., a subsidiary of John Wiley and Sons, Inc.*

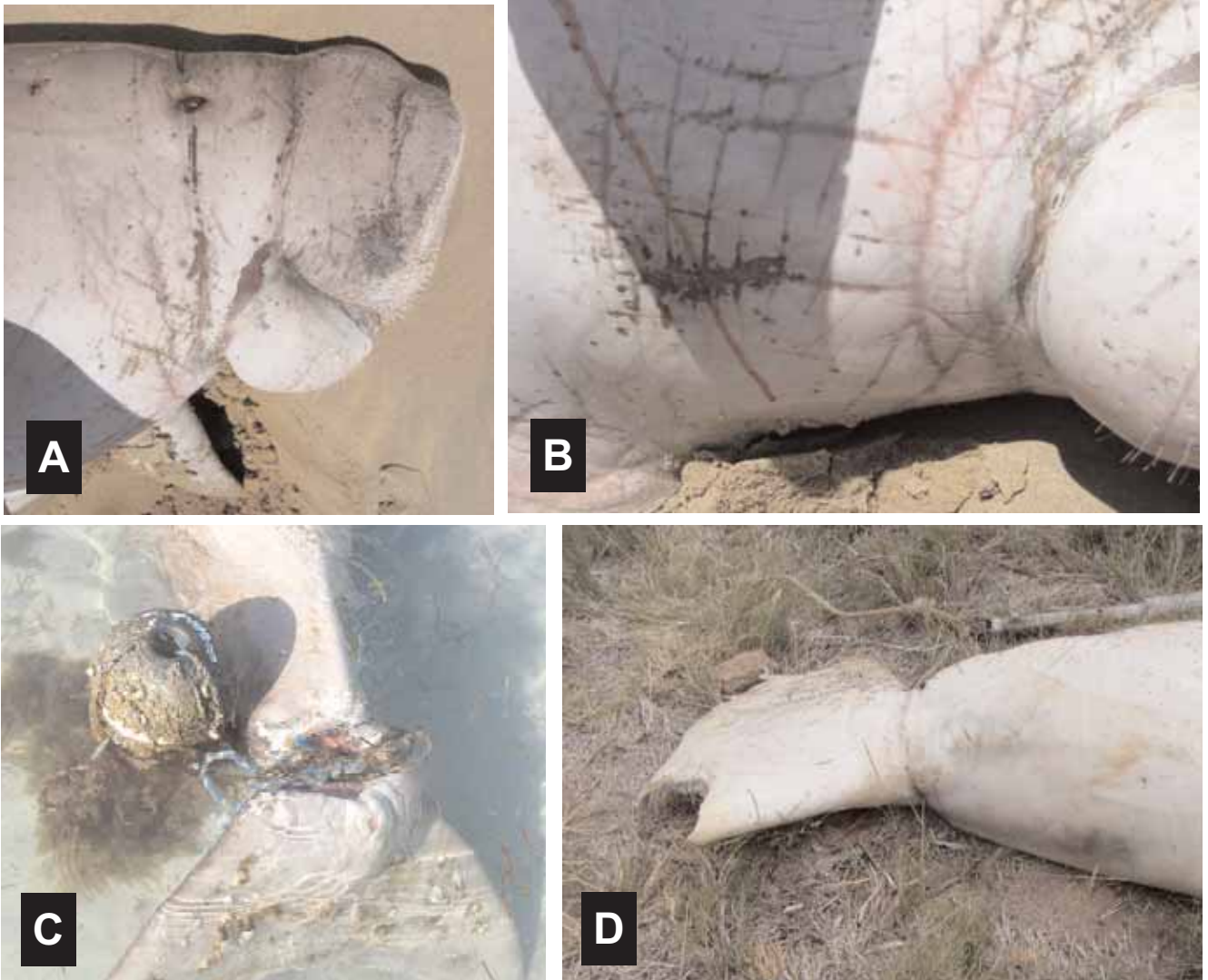

Figure 11. Marks on dugongs from entanglement in net and line: **a)** marks from net in head and neck region, **b)** marks from net around neck/chest area, **c)** peduncle entangled in rope and buoy, **d)** indentation from rope entangled around peduncle (note: shark bite on tail). *Photos courtesy of QPWS, (a, b W1528 cse numbers from EPA Stranding Reports).* See also Figure 39.



Figure 12. Knife wound on right side of abdomen, with insert showing close-up of wound that has serrations on edge (note: this dugong was also pregnant). *Photos courtesy of QPWS, (W1559).*

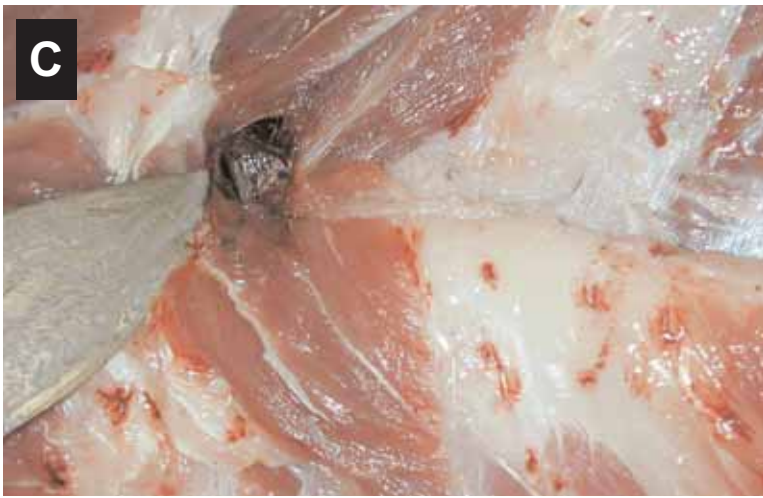
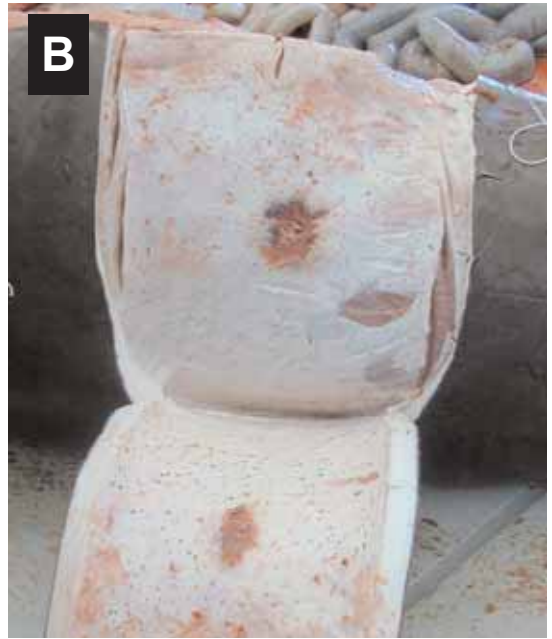
Figure 13. Marks on dugong from spear wound: **a)** spear wound to skin (note: the spear was removed so radiating cuts may have been made after the animal was already dead), **b)** the underside of the wound in (a) showing damage from spear, **c)** spear head embedded in and protruding from the intercostal muscles within the chest. *Photos courtesy of QPWS, (Q492096).*

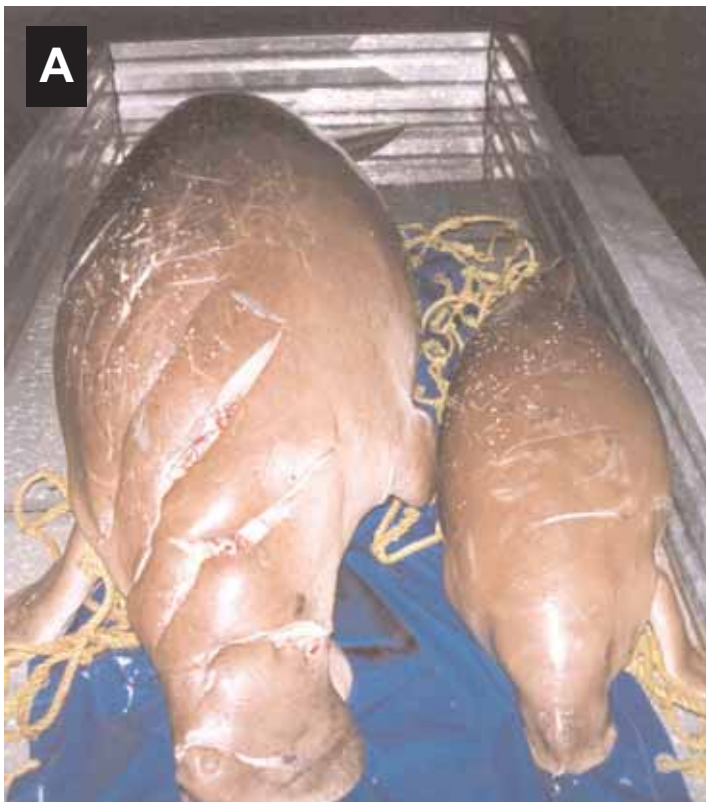


Figure 14. Propeller wounds from boat strike: **a)** cow had propeller damage and smashed skull and calf had propeller damage and compound fracture of ribs, **b)** propeller wounds on dorsal side. *Photos courtesy of QPWS, (W1570, W1571, Q0492477).*



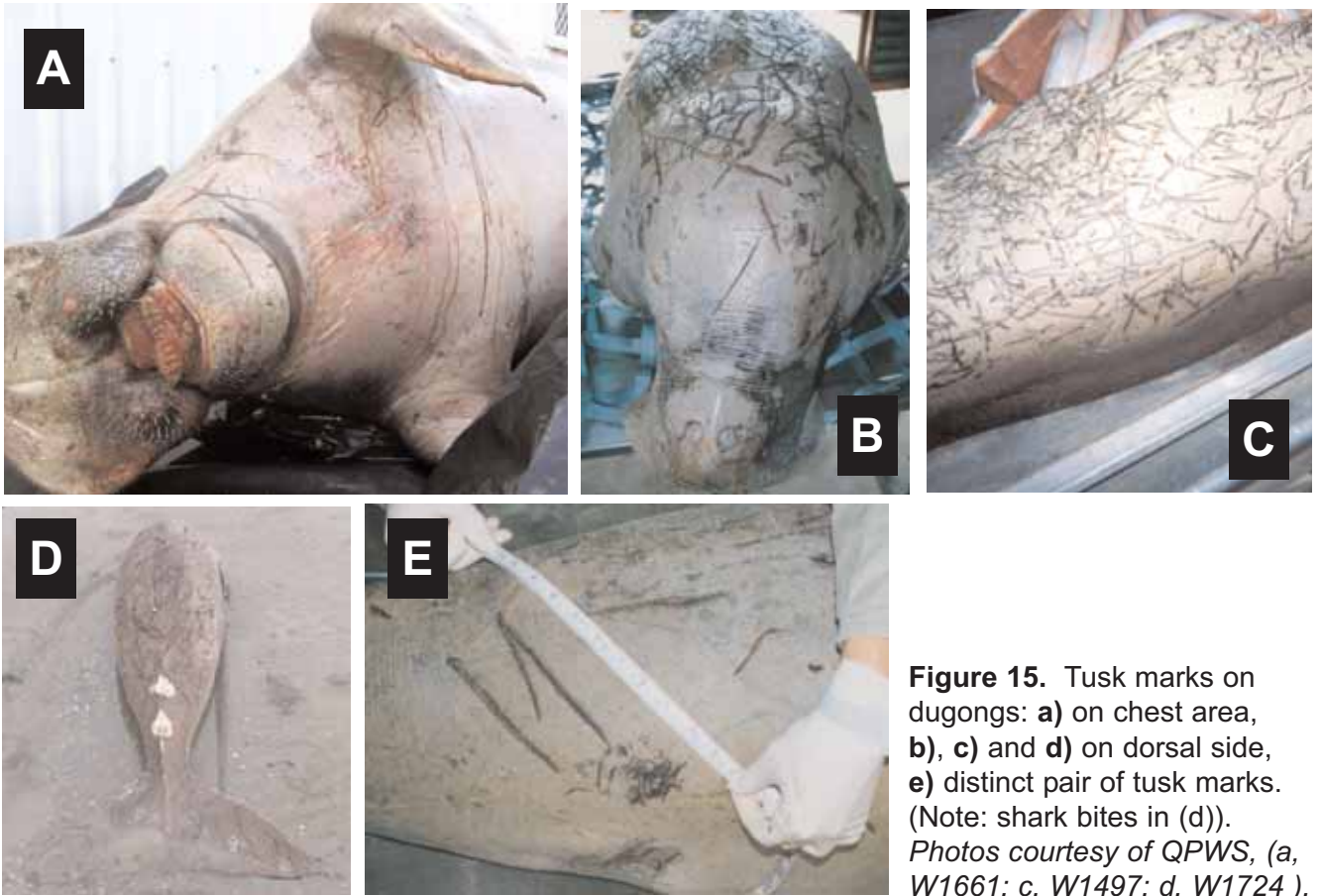


Figure 15. Tusk marks on dugongs: **a)** on chest area, **b), c)** and **d)** on dorsal side, **e)** distinct pair of tusk marks. (Note: shark bites in (d)). Photos courtesy of QPWS, (a, W1661; c, W1497; d, W1724).

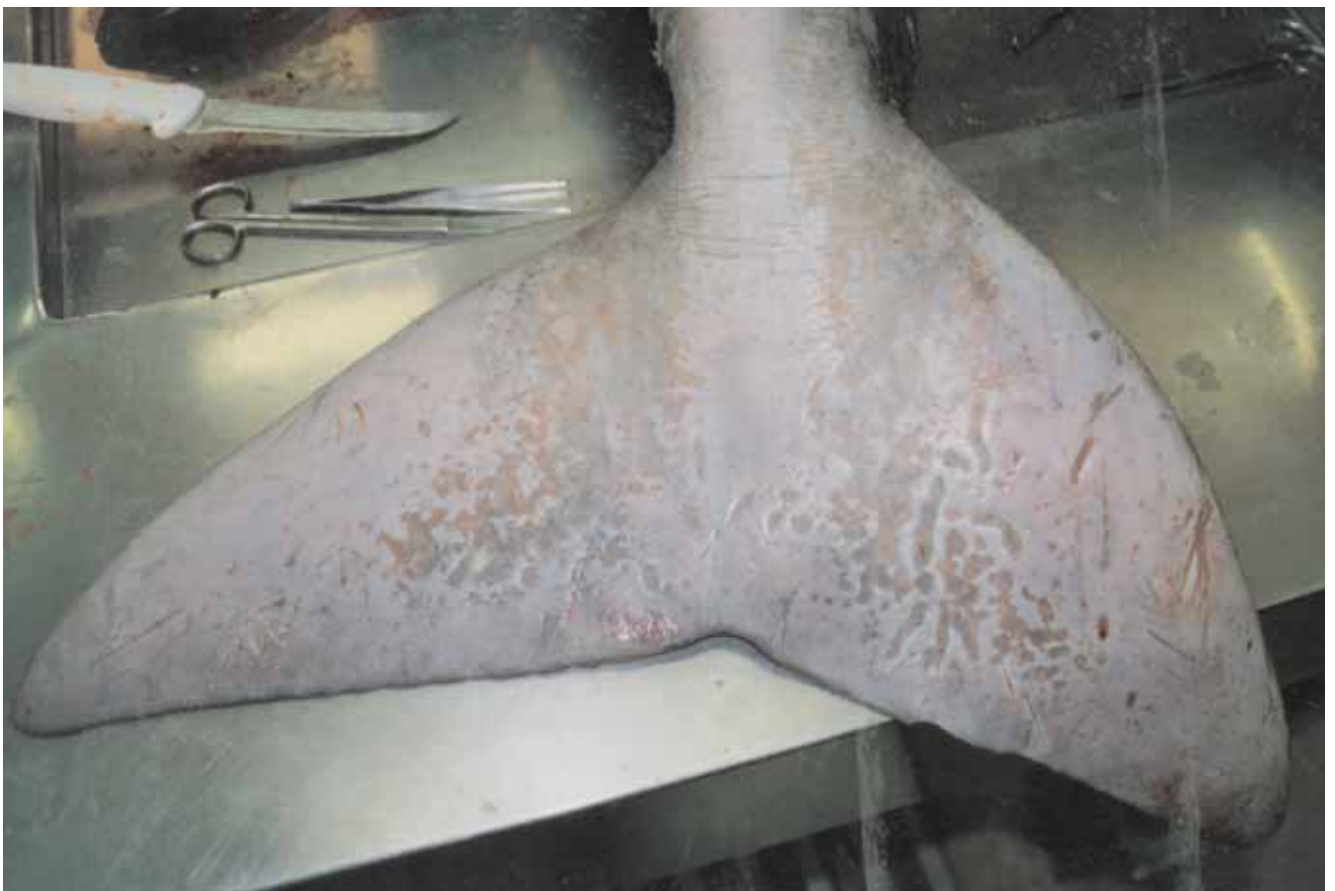

Figure 16. Infectious dermatitis on tail. Necropsy by Dr Rachel Bowater, Department of Primary Industries and Fisheries; photo courtesy of QPWS.

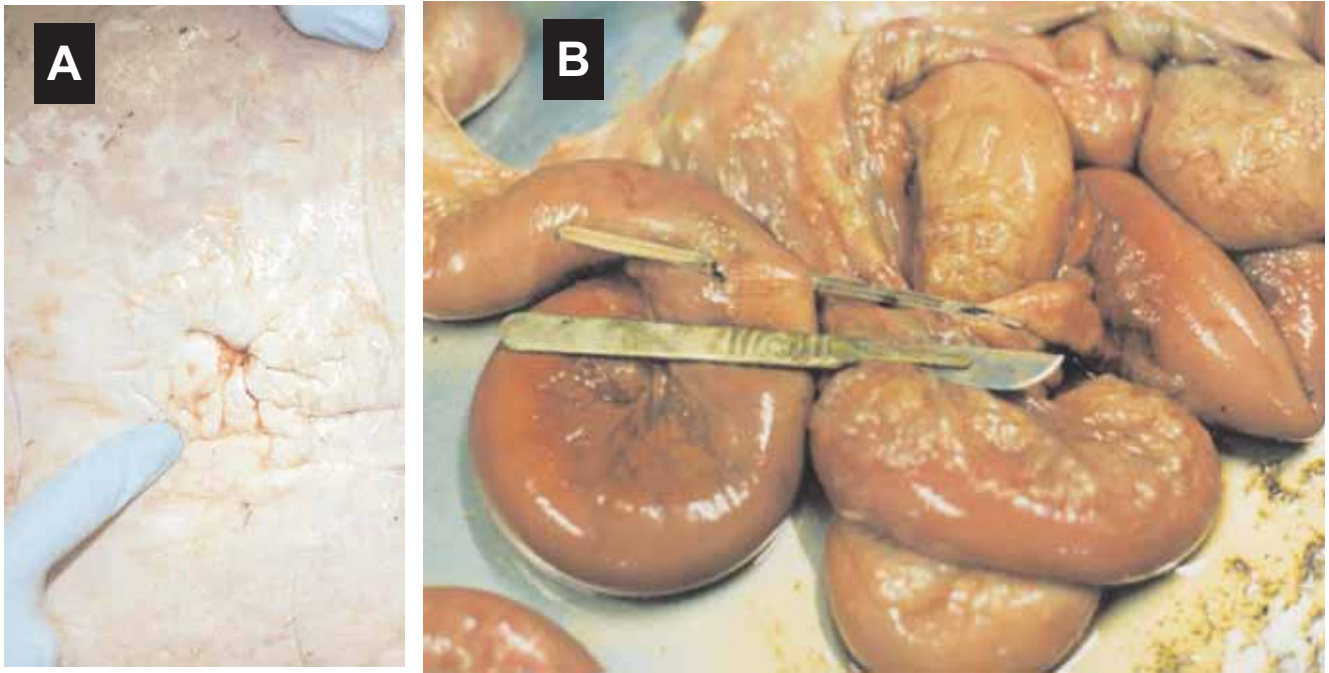


Figure 17. Dugong wounded by stingray: **a)** entry point of stingray barb, **b)** stingray barb perforating intestine (note: this dugong developed peritonitis). Necropsy by Dr Rachel Bowater, Department of Primary Industries and Fisheries; photo courtesy of and © The State of Queensland, DPI&F/QPWS and GBRMPA.

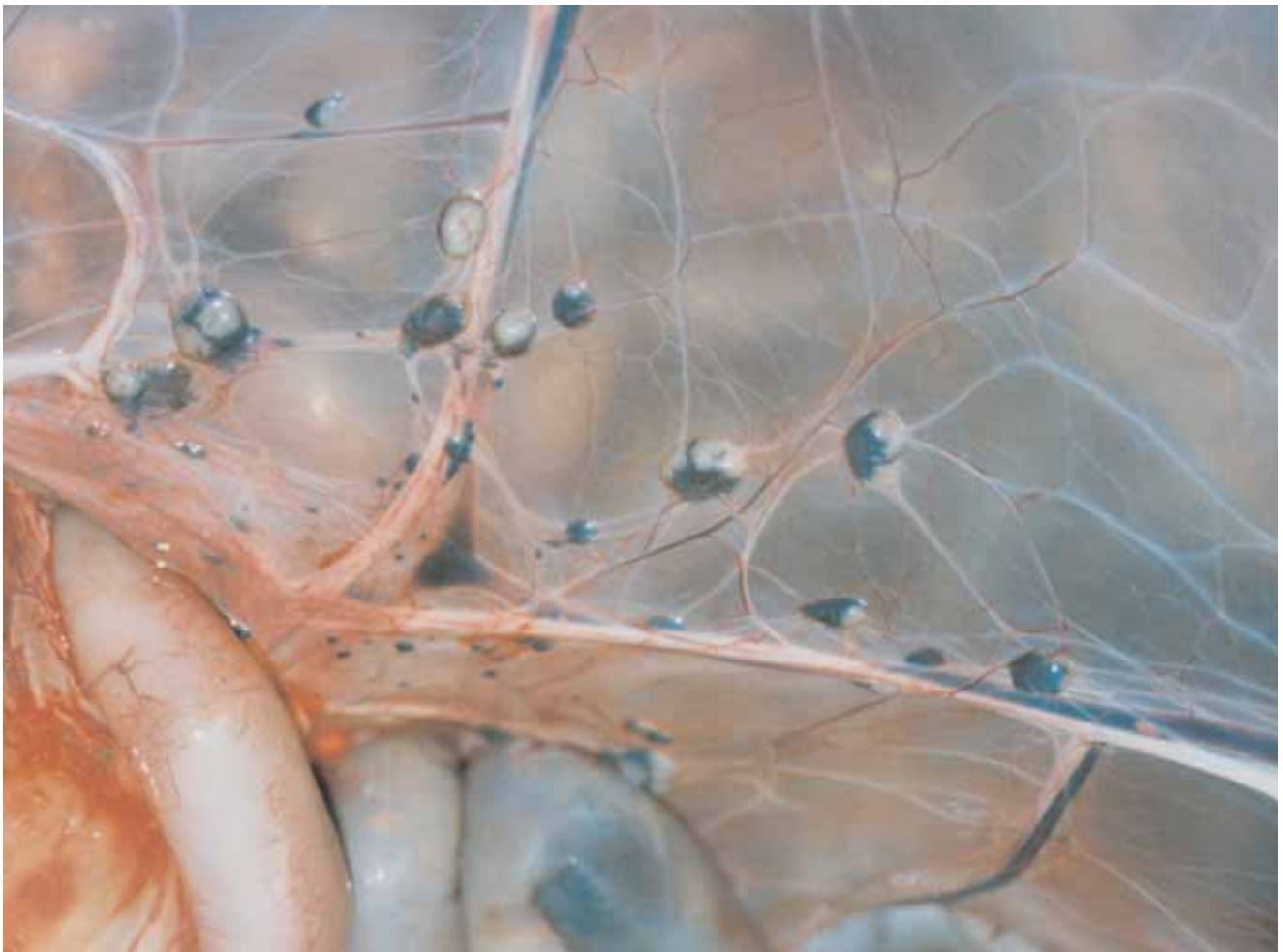

Figure 18. Enlarged mesenteric lymph nodes. Photo courtesy of QPWS.

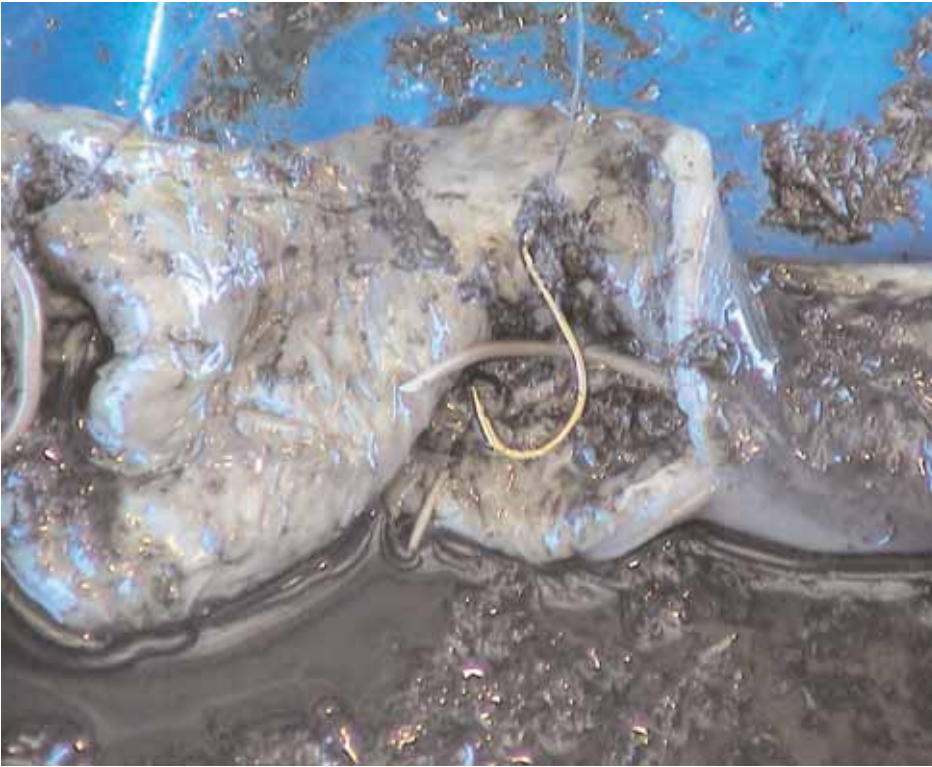

Figure 19. Fish hook and line in dugong intestine following ingestion of fishing gear. *Photo courtesy QPWS, (W1482).*

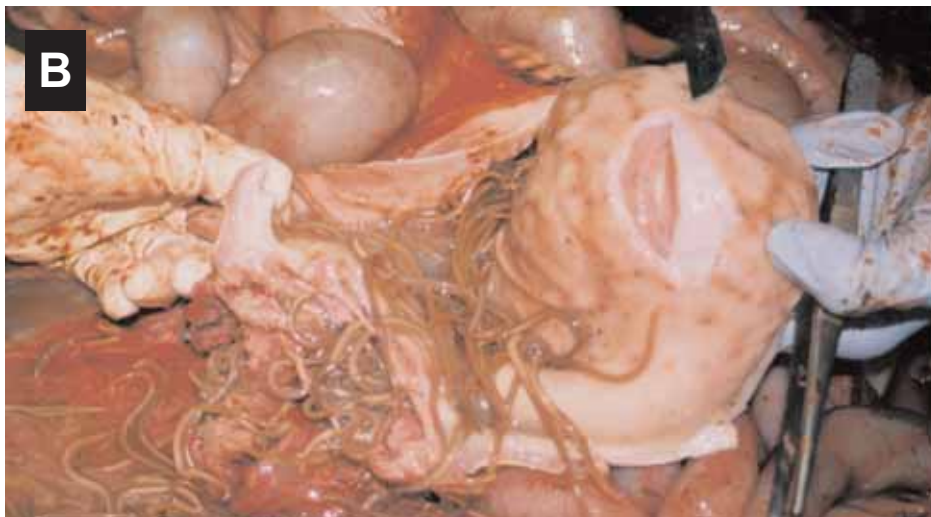
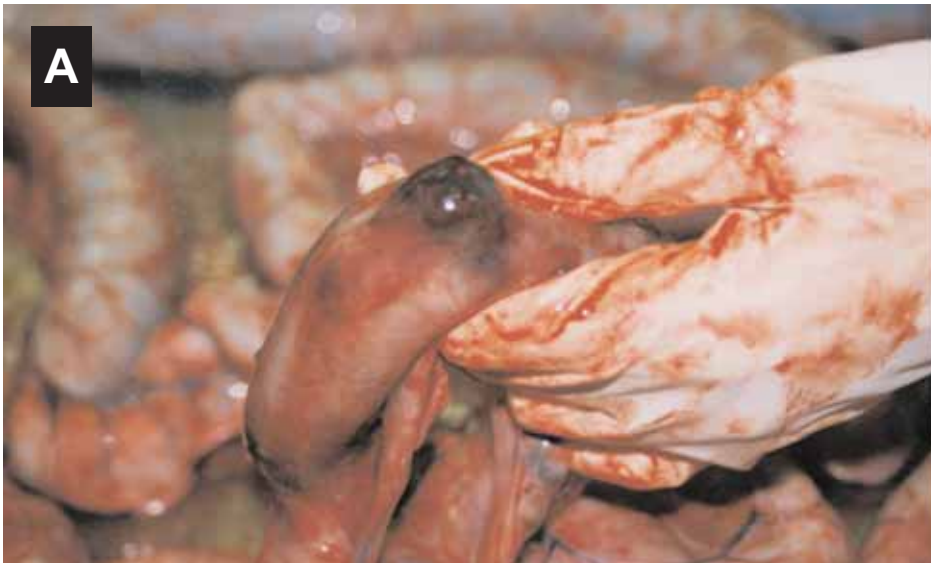
Figure 20. Parasites in dugong: **a)** abscess of intestine containing *Faredifex clavata* (note: can rupture intestine leading to peritonitis), **b)** ascarid worms. *Necropsies by Dr Rachel Bowater, Department of Primary Industries and Fisheries; photo courtesy of QPWS.*

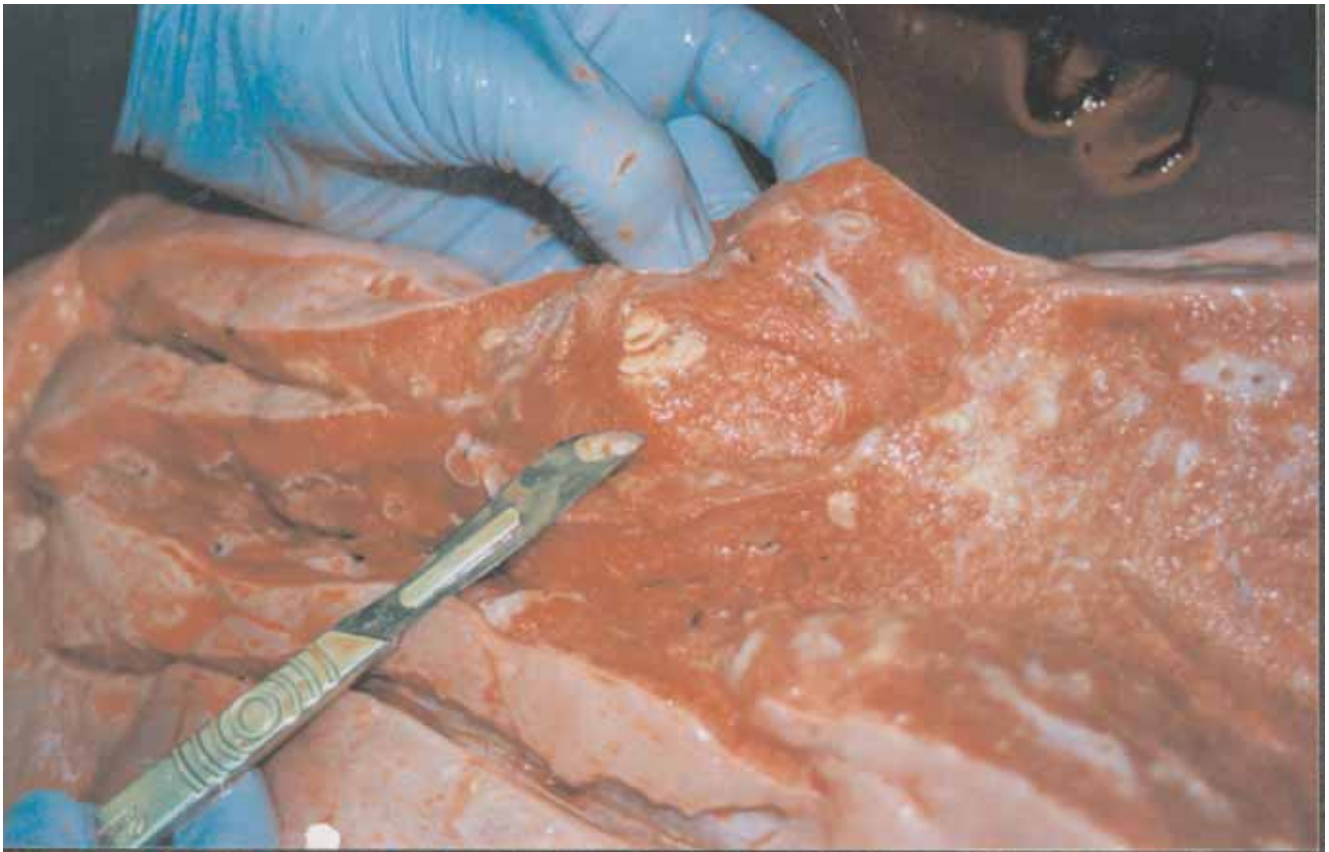

Figure 21. Lung with bronchopneumonia (note: lung abscesses ranging in size from 1 to 10 mm in diameter containing purulent exudate). Necropsy by Dr Rachel Bowater, Department of Primary Industries and Fisheries; photo courtesy of and © DPI&F.

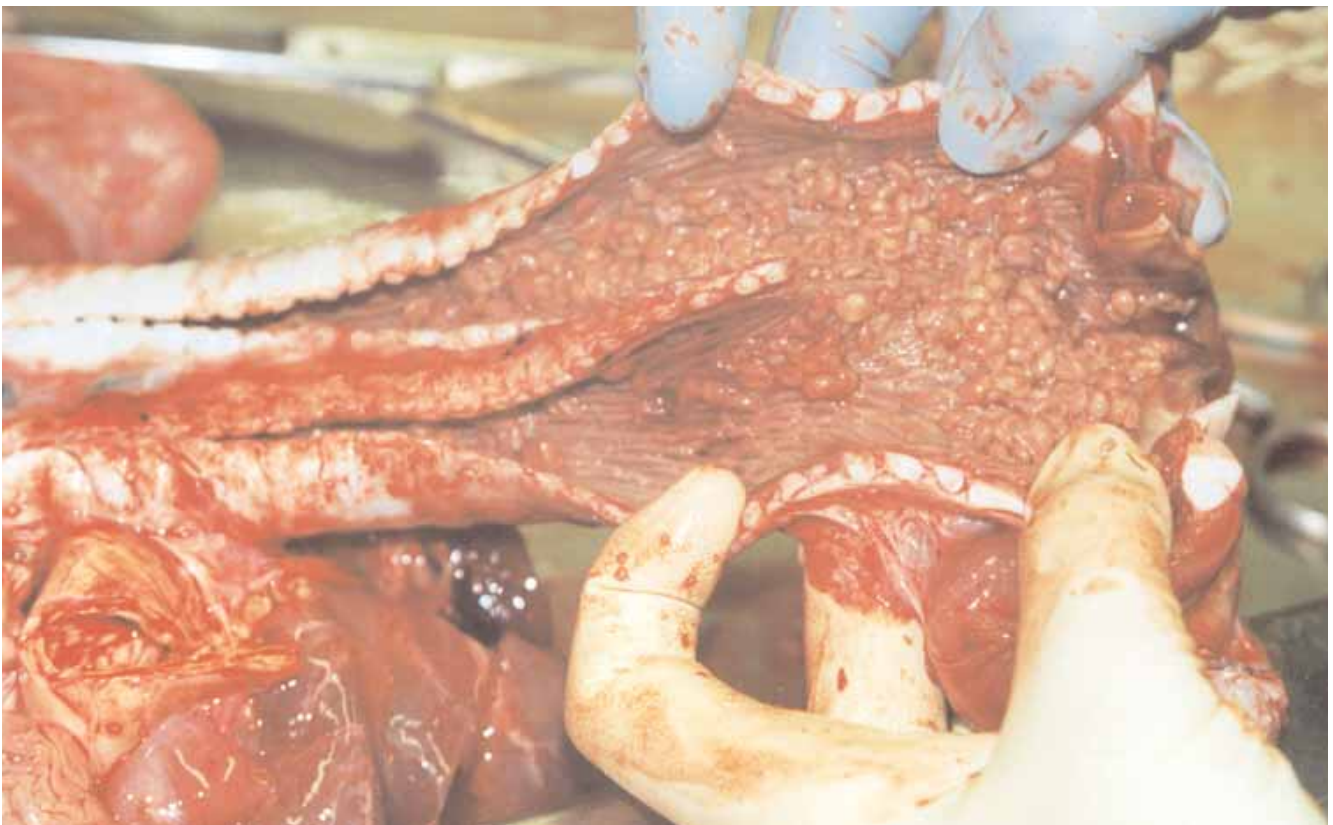

Figure 22. Trematode parasites in bronchiole of dugong. Necropsy by Dr Rachel Bowater, Department of Primary Industries and Fisheries; photo courtesy of QPWS.

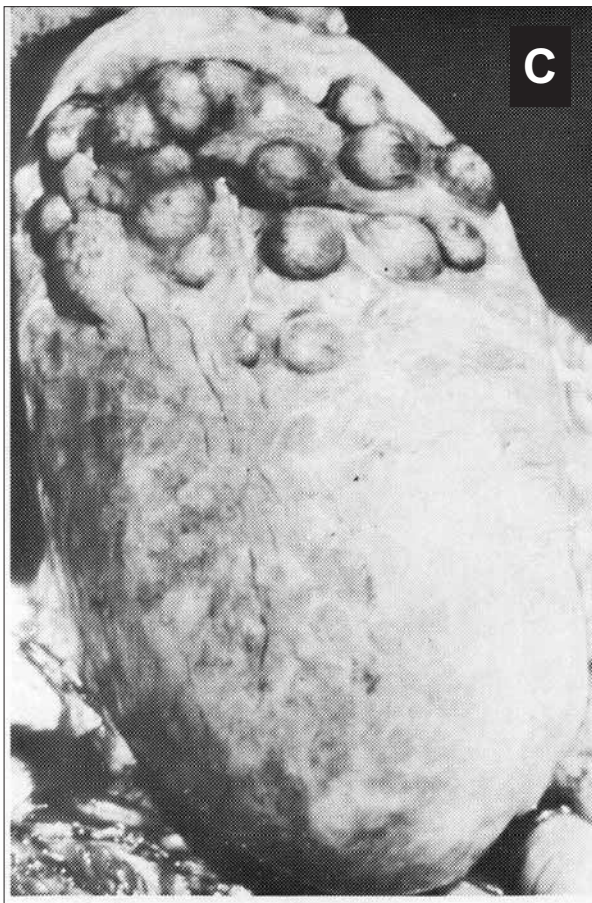
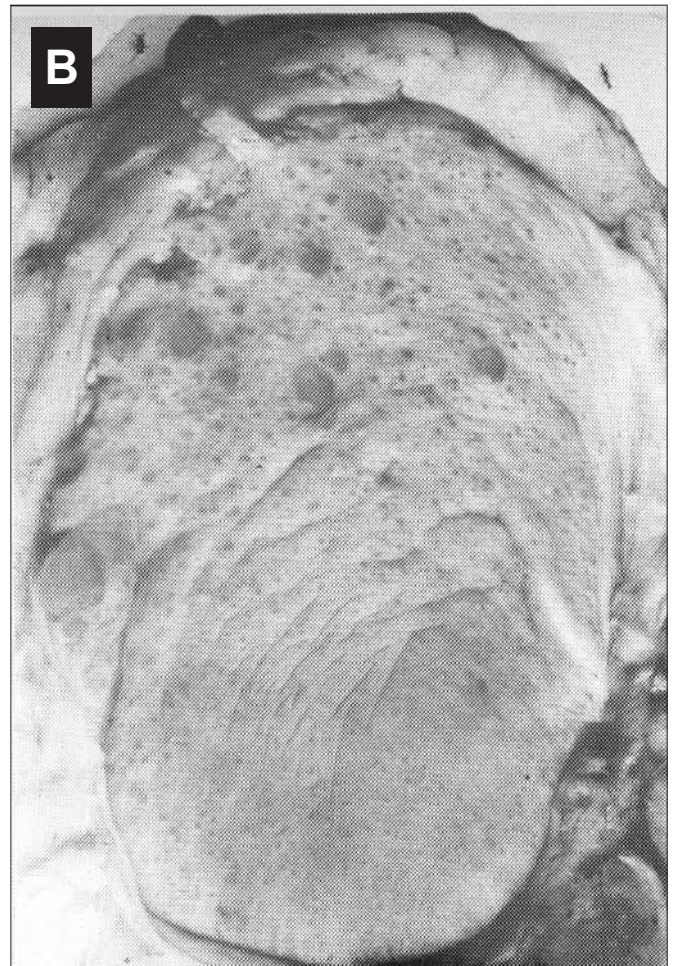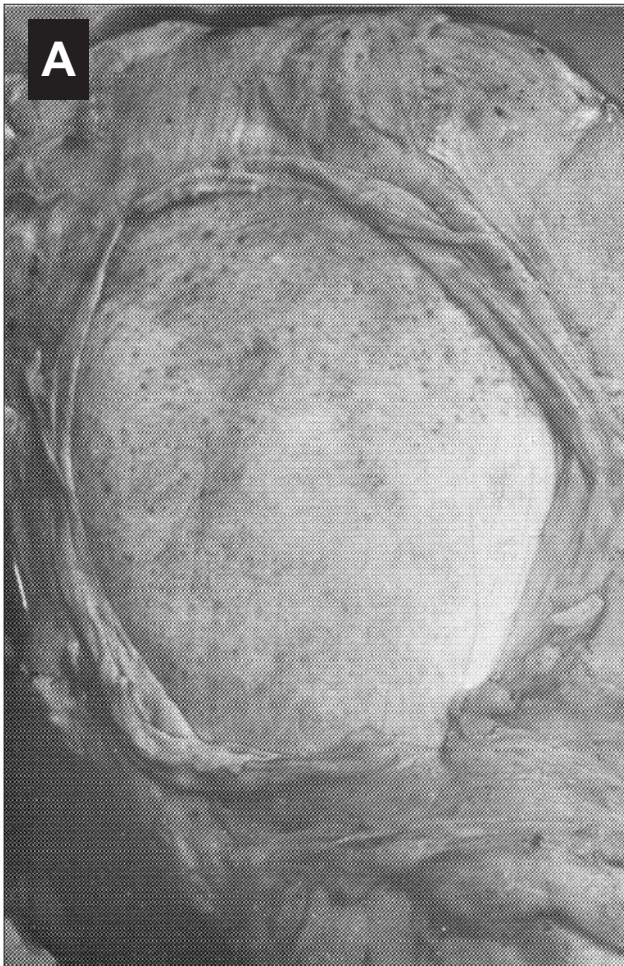


Figure 23. Dorsal surface of the dugong ovary: **a)** left ovary of a mature female with bursa opened and partly removed, **b)** the right ovary of the same animal as (a) showing several large follicles, **c)** the right ovary of a dugong pregnant with a foetus. Numerous highly vascular corpora lutea can be seen. *Photos courtesy of Helene Marsh.*

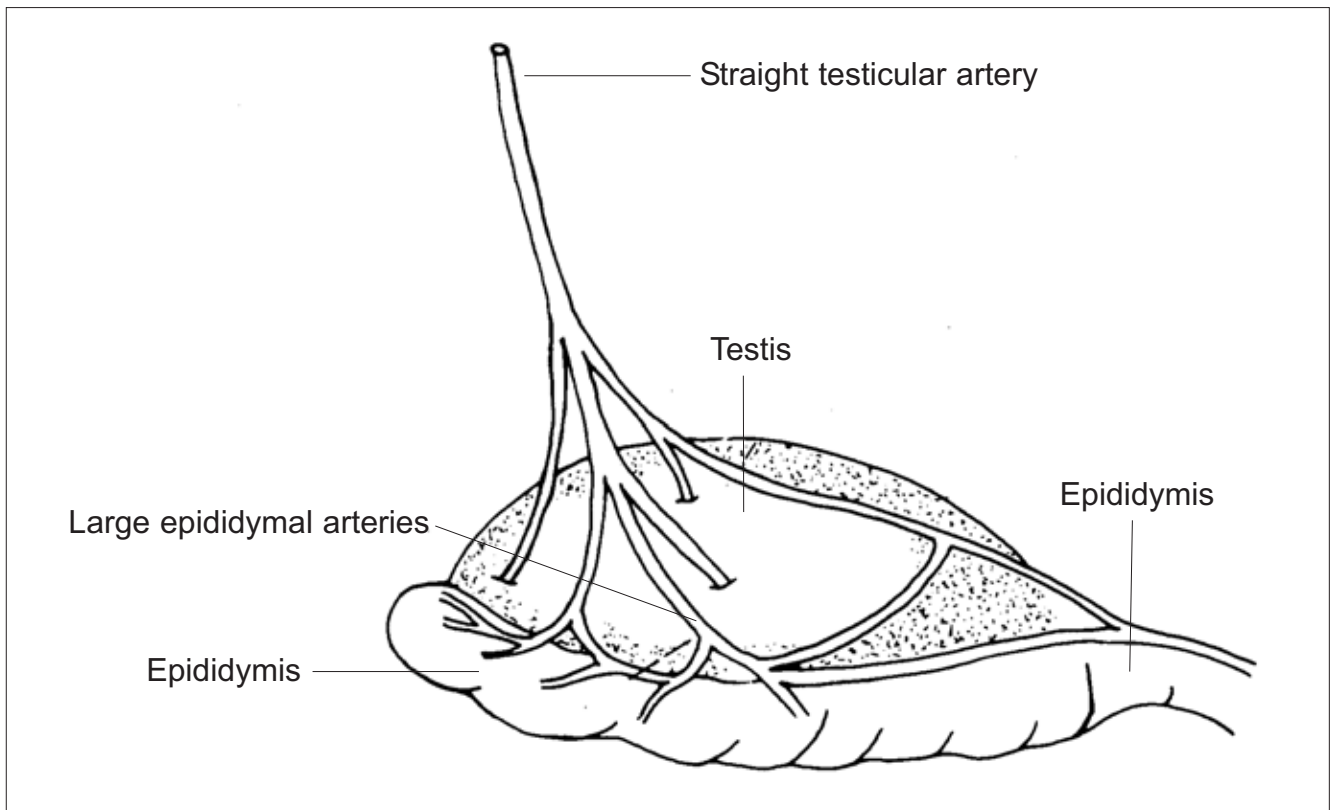


Figure 24. The right testis and epididymis of a male dugong (Marsh and Glover 1981). *Courtesy of Helene Marsh.*

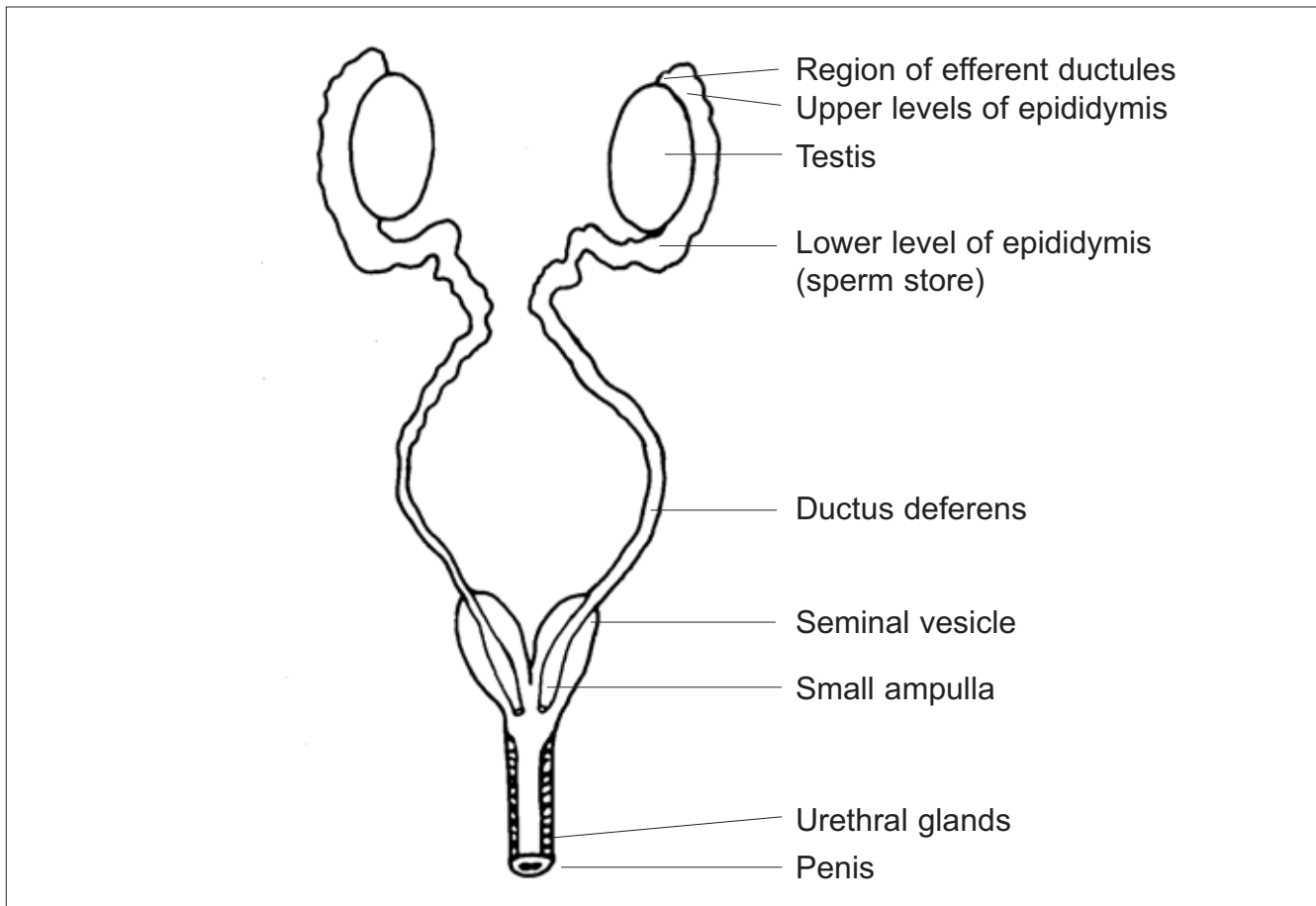


Figure 25. Ventral view of the reproductive tract of the male dugong (Marsh and Glover 1981). *Courtesy of Helene Marsh.*

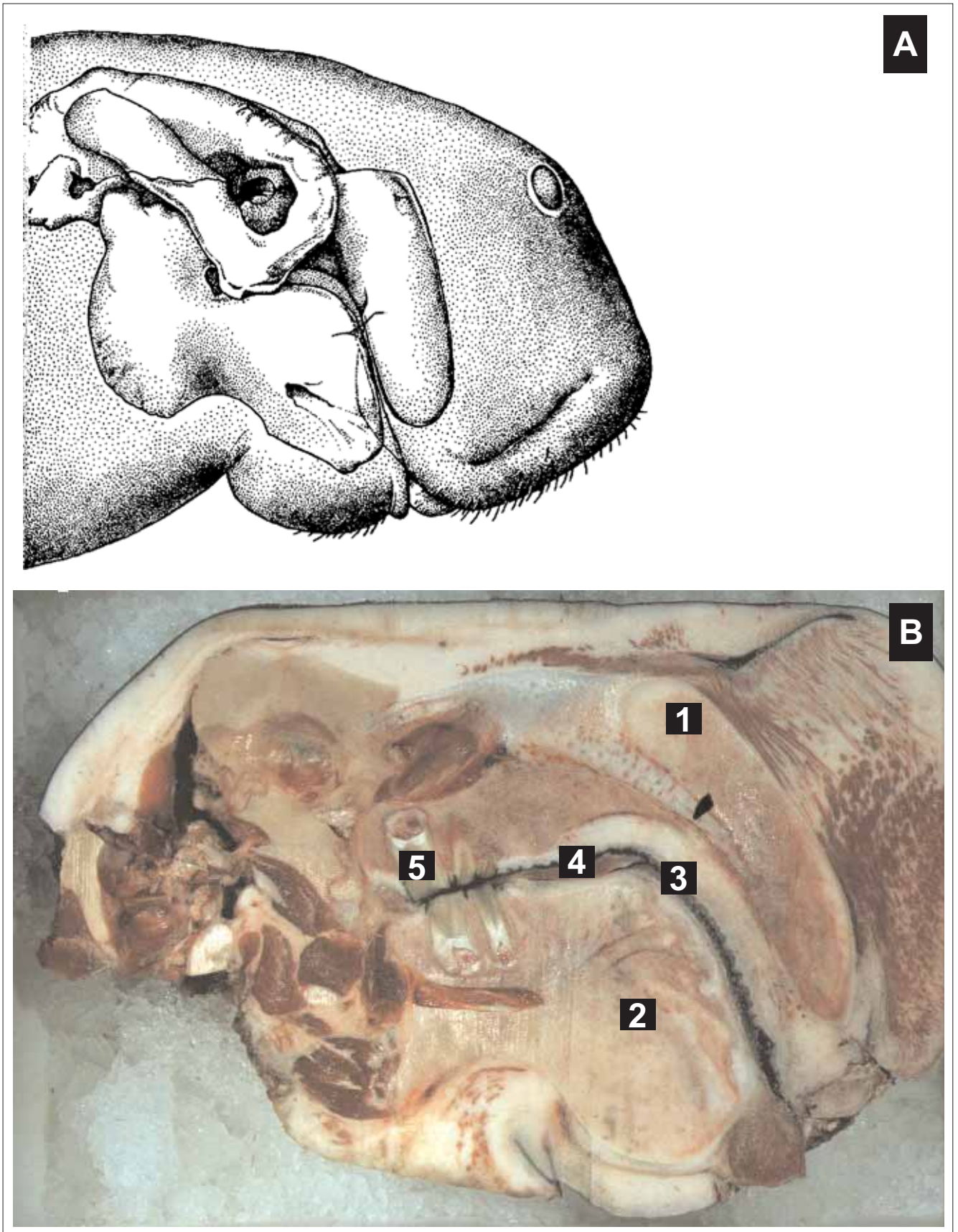


Figure 26. Lateral view of the dugong head showing: **a)** the position of the skull in the head, and **b)** a longitudinal midsection of the head. **1.** Premaxilla, **2.** Mandible, **3.** Hornyplates, **4.** Tongue, and **5.** Cheek Teeth. **a)** Illustrated by Bozena Jantulik and reprinted from Bryden *et al.* (1998) with permission of Allen and Unwin Pty. Ltd., St. Leonards, New South Wales, Australia. **b)** Photo courtesy of Helene Marsh.

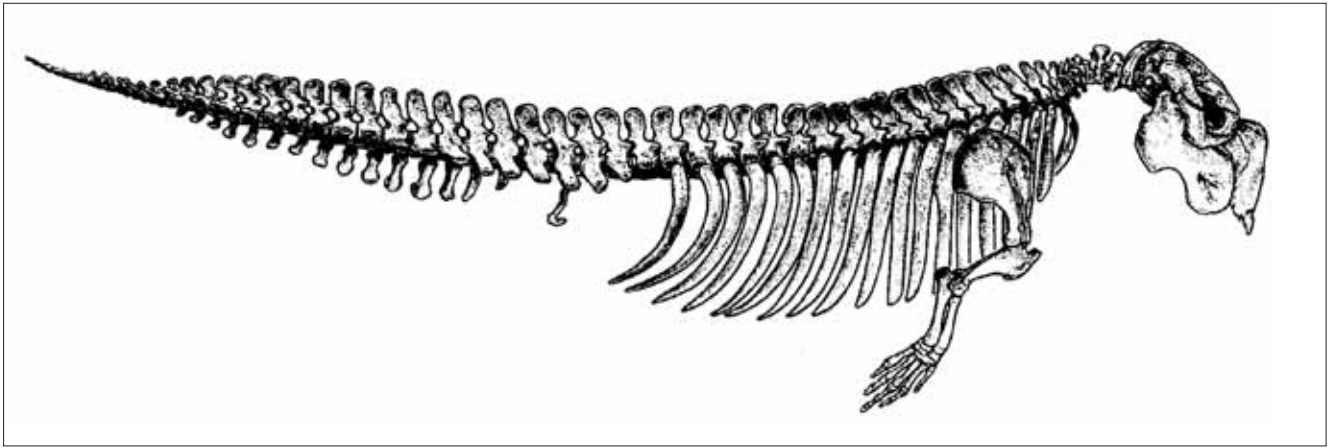


Figure 27. Lateral view of the dugong skeleton. *Illustrated by Bozena Jantulik and reprinted from Bryden et al. (1998) with permission of Allen and Unwin Pty. Ltd., St. Leonards, New South Wales, Australia.*

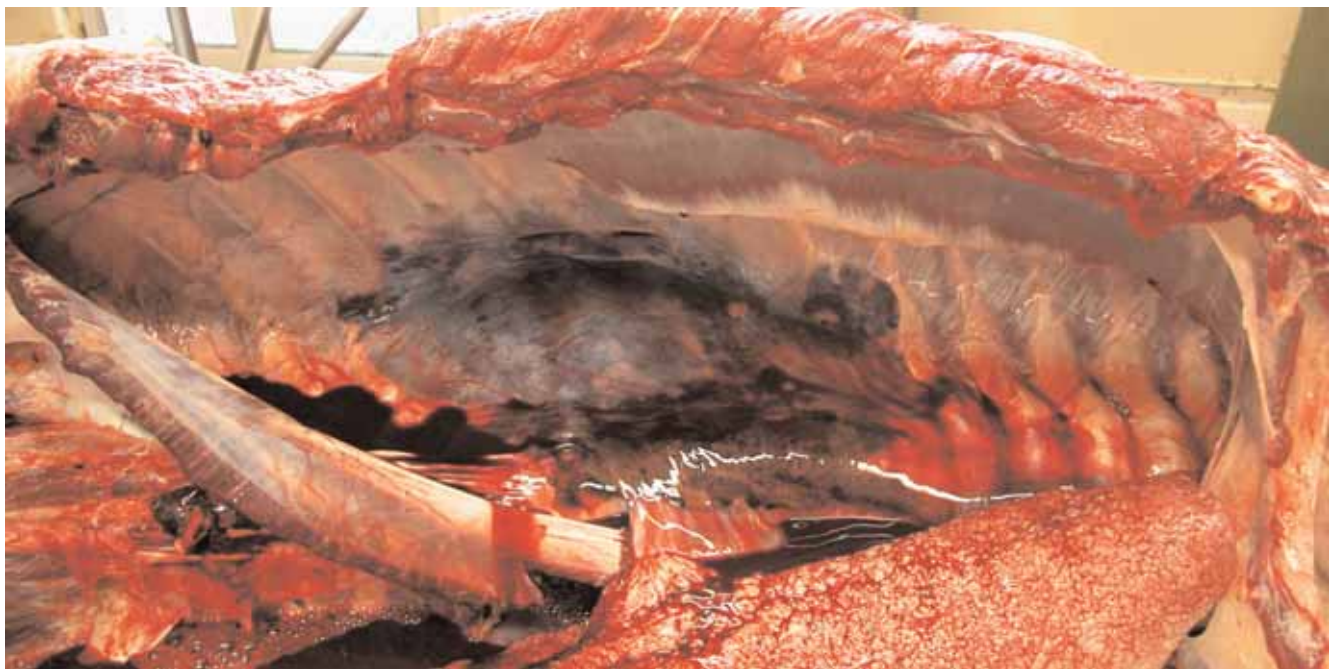


Figure 28. Haematoma in thoracic wall from fractured ribs of dugong hit by vessel (see also Figure 37 of same carcass). *Photo courtesy of QPWS, (Q0492414).*




Figure 29. Anthropogenic cuts to dugongs: **a)** tail cut off, **b)** head cut off. These cuts are straight (note: contrast to shark bites in Figure 32). *Photos courtesy of QPWS, (a, W1764).*

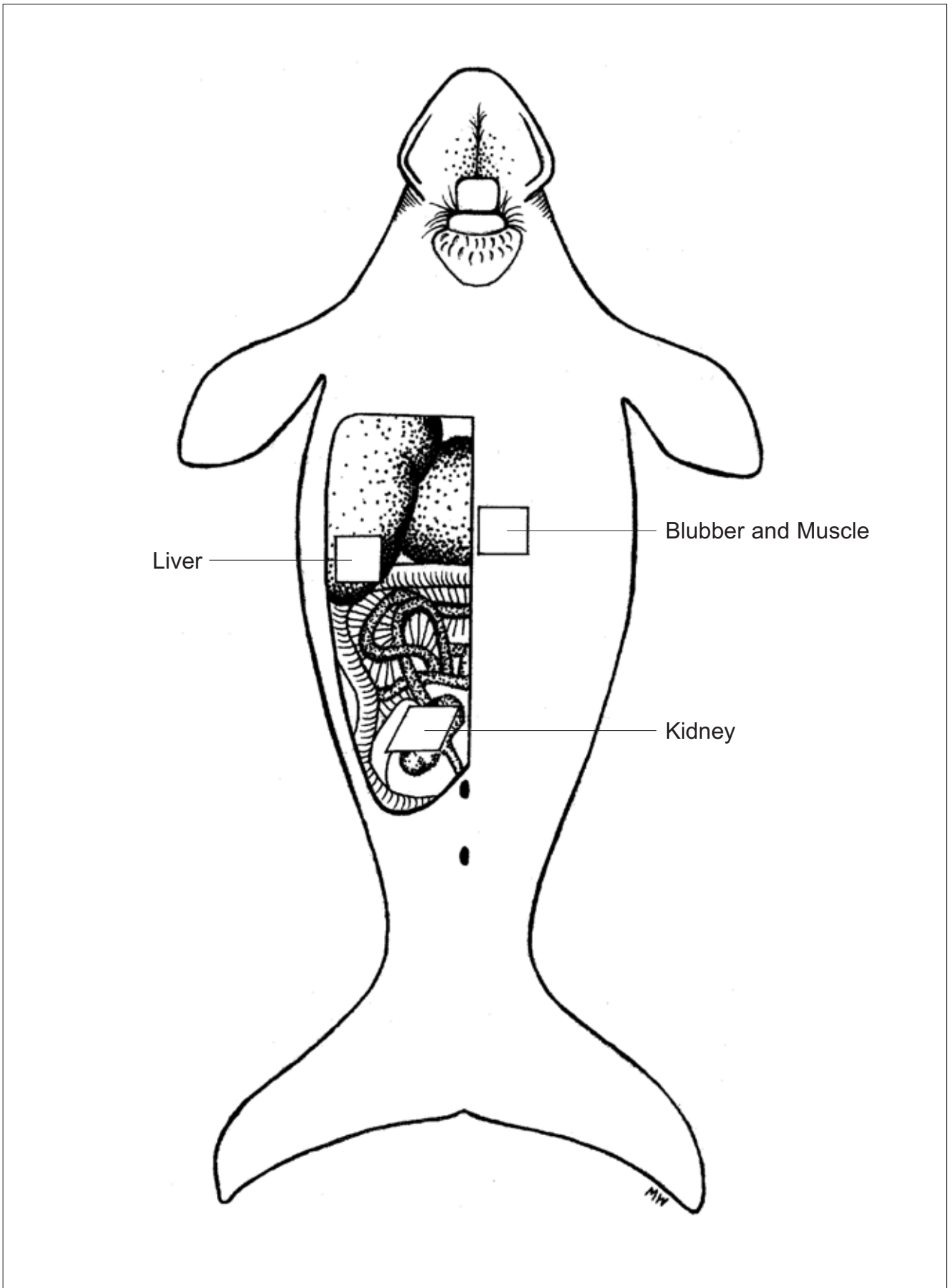


Figure 30. Recommended sites for collecting tissue samples from liver, kidney, blubber and muscle for contaminants analysis. *Illustrated by Melina Wales.*

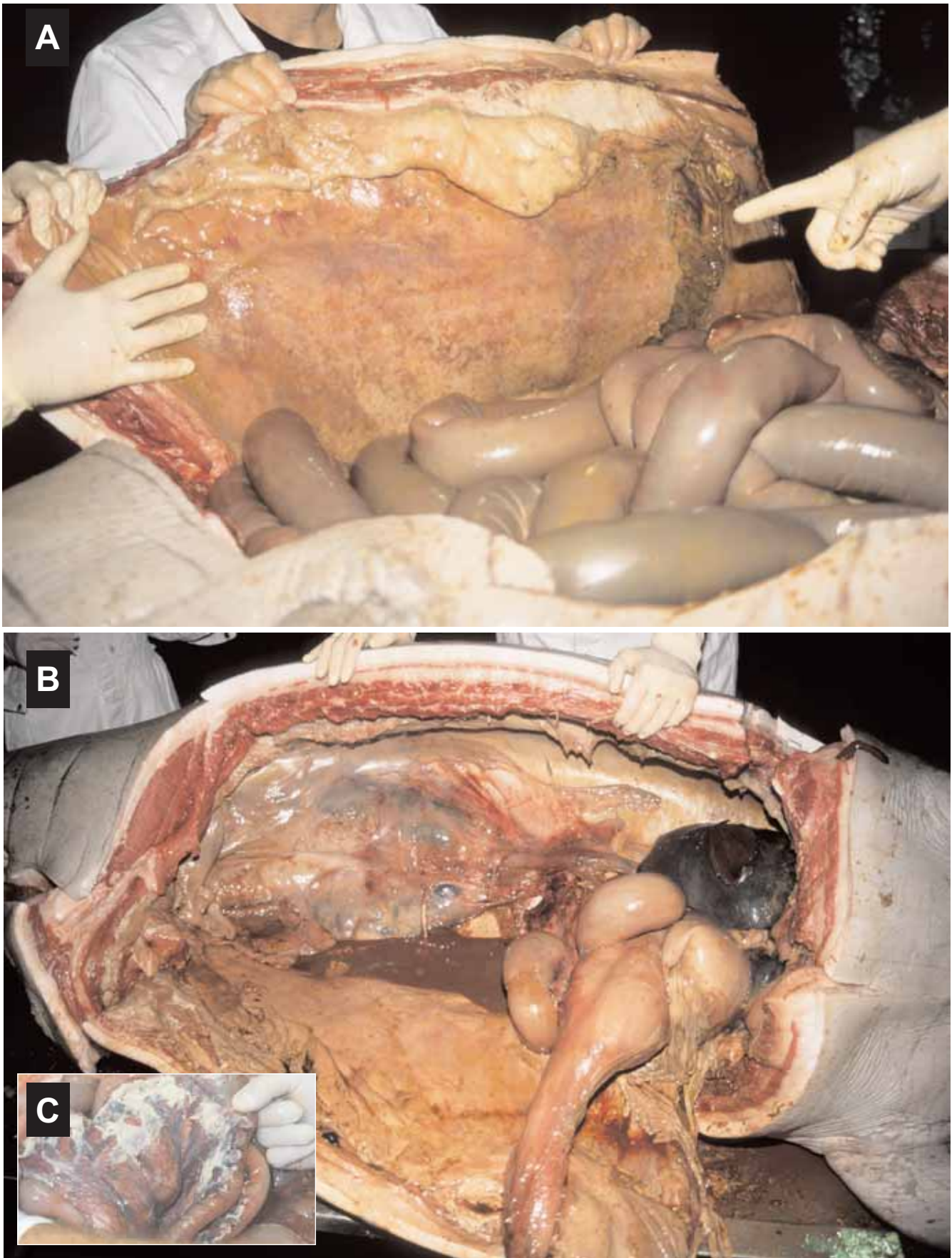


Figure 31. a) Initial examination of abdominal cavity. Note presence of fibrinous adhesions to the parietal surface of the abdominal cavity. **b)** and **c)** Note peritoneal fluid below kidneys and fibrinous adhesions to the stomach and intestines. *Necropsy by Dr Rachel Bowater, Department of Primary Industries and Fisheries; photos courtesy of and © DPI&F and QPWS.*

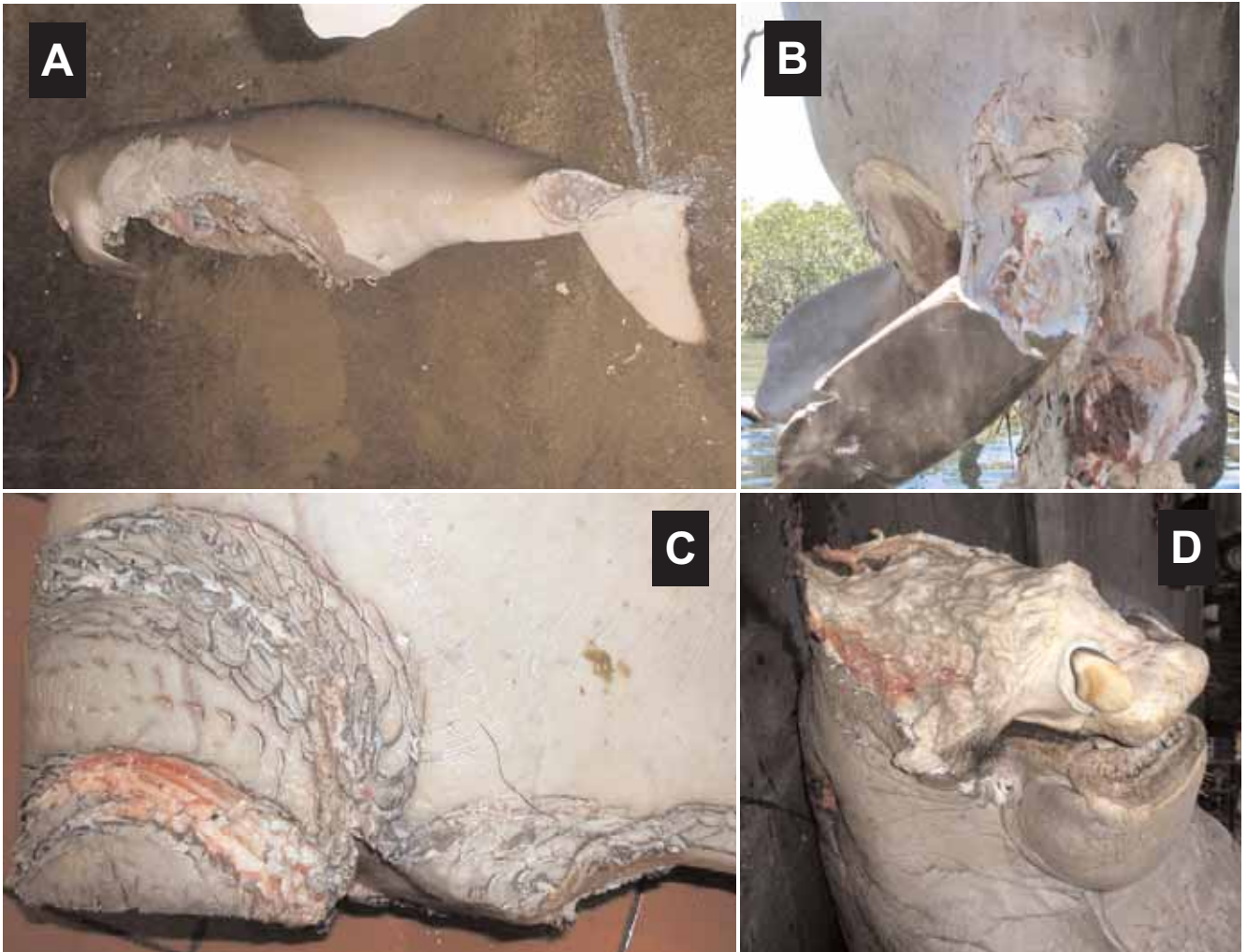


Figure 32. Shark bites to dugongs: **a)** bite marks on abdomen and peduncle, **b)** numerous bites, **c)** close-up of bite marks, **d)** bites to head (note: sharks often target the head and tail).
Photos courtesy QPWS, (a, W1507; b, W1767; c, W1692).



Figure 33. Dugong calf showing signs of malnutrition, including thin body.
Photo courtesy of QPWS.

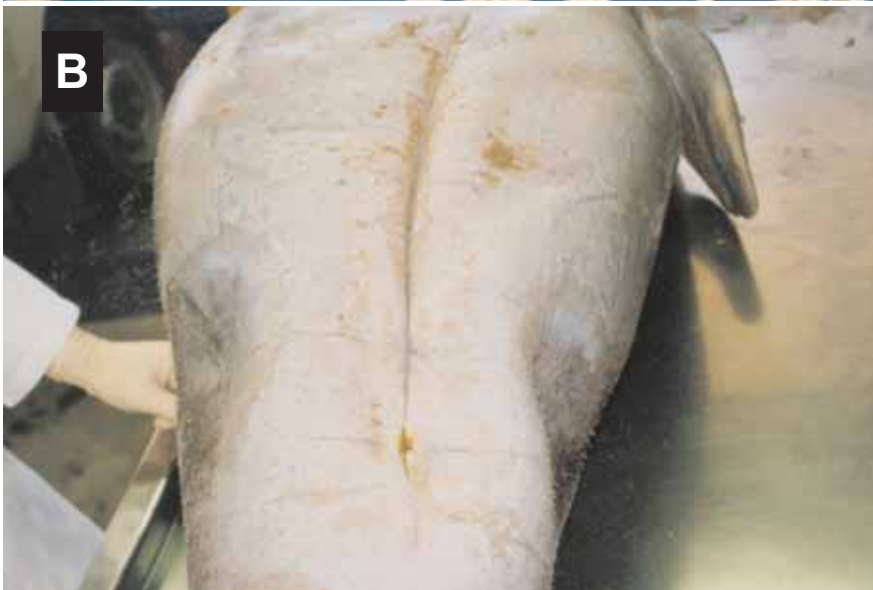
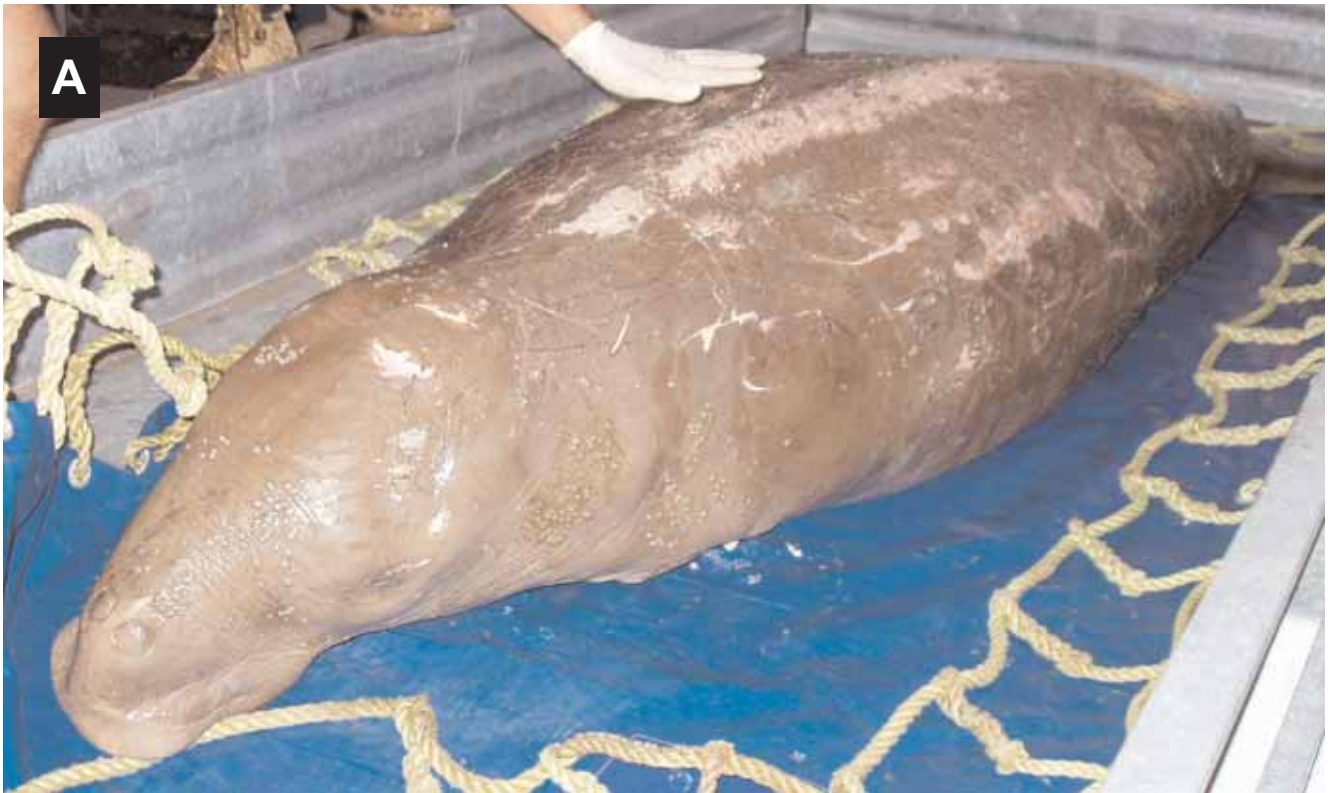
Figure 34. Adult dugongs showing signs of malnutrition: **a)** with neck becoming visible and prominent backbone (note: diagnosis was chronic interstitial nephritis and multiple bacterial emboli), **b)** caving in and blackening of abdomen (note: the darkened surface of the skin often with fissuring is due to bacteria, and can be described as “generalised raised grey irregular verruciform plaques with some focal lesions being ulcerated”), **c)** blackening around peduncle. *Photos courtesy QPWS, (a, W1569).*



Figure 35. Body creases on ventral side of dugong. *Photo courtesy of QPWS.*

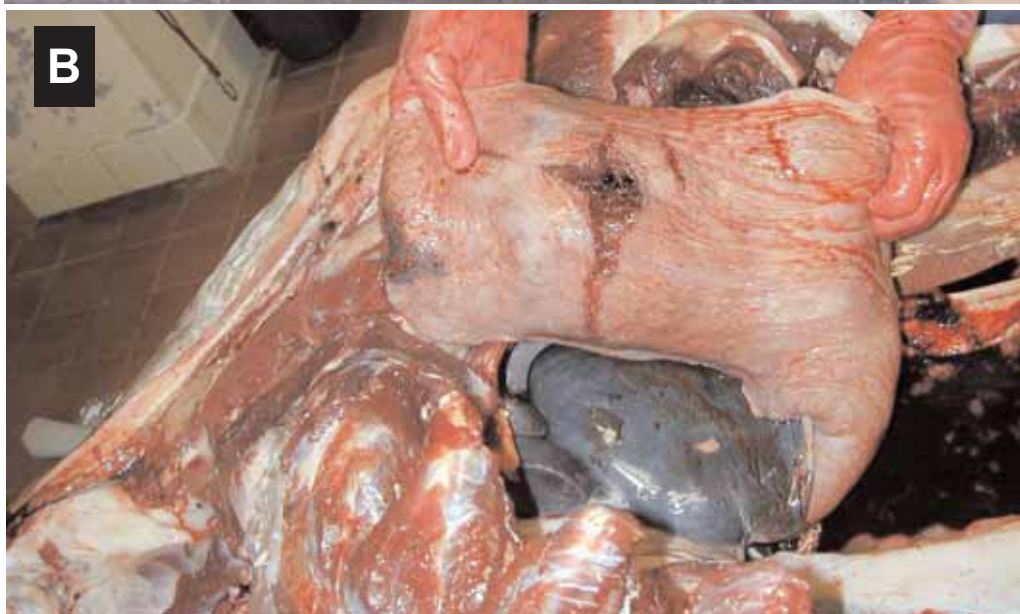

Figure 36. Vessel strike (case 1): **a)** propeller wounds on dugong struck by 20 metre water taxi with 1 metre draft travelling at 18-20 knots, **b)** resulting lung trauma in same animal. *Photos courtesy of QPWS, (Q0492412).*




Figure 37. Vessel strike (case 2): **a**) and **b**) propeller wounds on dugong struck by 18-20 metre ferry with 1-1.2 metre draft travelling at 20-22 knots in water of between 1.3-1.7 metre depth at low tide, **c**) and **d**) lung lacerations/collapsed lung, **e**) haematoma. (Note: all from same carcass, and see also Figure 28). *Photos courtesy of QPWS, (Q0492414).*



Figure 38. Numerous markings on the back and sides of the body are common. Note wounds are old and healed. *Photo courtesy of QPWS.*

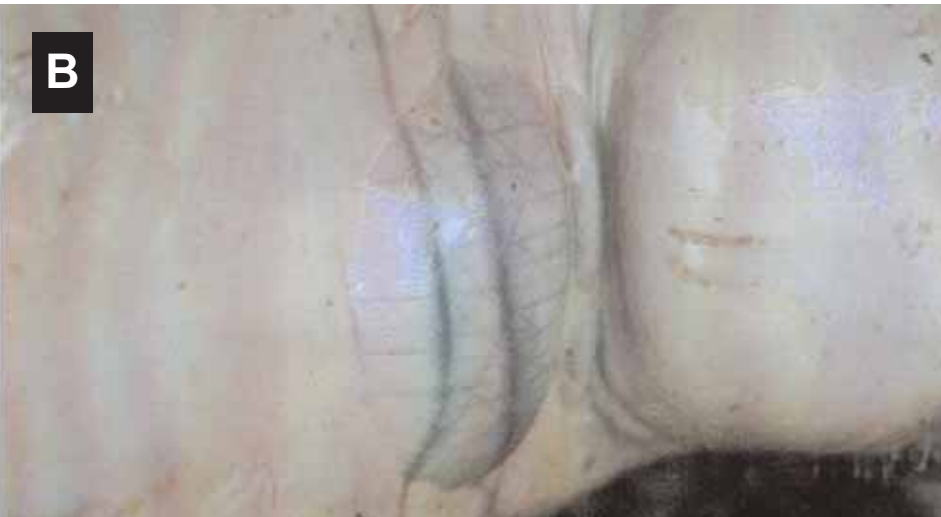

Figure 39. Dugong suspected of being entangled in a net: **a)** markings on the neck of a dugong carcass possibly indicating entanglement in a net, **b)** close up of markings showing detail and an underlying haematoma (indicated by bulge). *Photos courtesy of QPWS.* See also Figure 11.




Figure 40. Attempts to conceal dugong carcasses: **a)** abdomen was cut open and carcass weighted/anchored, **b)** and **c)** carcass cut open and weight attached to flipper. *Photos courtesy QPWS, (a, W1432; b & c, W1401).*

5.1.3 Ethyl Alcohol EtOH (100%)

Used for preserving nematodes. Formalin (5%) may also be used but is less satisfactory than alcohol.

5.1.4 Acetic Acid

Used for killing certain parasites (see Section 5.2.2).

5.1.5 Dimethyl Sulfoxide (DMSO)

Used to preserve tissue for genetic analyses. Tissue should be preserved immediately in tubes containing 20% DMSO in saturated NaCl solution.

A note on DMSO: DMSO is to be used with caution as it is toxic and mildly flammable. It does not require declaration for transport on aircraft, as it is not toxic or flammable enough to require a United Nations chemical code. However, it is hazardous to your health and penetrates skin readily into the subdermal tissue, also carrying any other chemicals on the skin into the body. If DMSO comes in contact with your skin it should be immediately washed off with soap and water (see Section 3.1).

5.1.6 Frozen Samples

Samples collected for genetic, contaminants and pesticide analyses should be frozen as soon as possible.

5.2 Specimen Collection Techniques

5.2.1 Ingesta

Stomach contents collected for dietary studies can be preserved in 10% neutral buffered or seawater formalin or in 80% EtOH. About 100 ml of material should be collected from the mouth (if present) and from each region of the digestive tract (including stomach, duodenum, mid-small intestine, caecum, and mid-large intestine) and diluted with an equal volume of preservative. Do not freeze *ingesta* samples – the freezing of seagrass and algal fragments will burst the cell walls and turn the sample mushy, making seagrass identification much more difficult.

5.2.2 Parasites

Parasites need to be killed then relaxed and preserved. Nematodes are best killed by dropping them into glacial acetic acid for one minute, then transferring them to 80% alcohol for storage. Nematodes tend to straighten out when placed in acetic acid, thus making them easier to work with. If acetic acid is not available they may be killed with hot 80% alcohol and then stored in 70 to 80% alcohol. Formalin (5%) may be used for the preservation of nematodes, but is less satisfactory than alcohol. Flukes need more careful treatment. All flukes may be killed and relaxed using hot (80°C) water. Larger worms should then be placed on a piece of moist filter paper in a petri dish. This is to render them as flat as possible without compressing them, and is best done with the aid of a dissecting microscope and a pair of needles to move the worms. Another piece of filter paper may then be placed on top of the worms and 10% formalin added, drop-by-drop, until the filter paper is damp. They become sufficiently fixed after about one hour, and can then be removed to a vial of 10% formalin without causing them to curl up again. See Blair (1981a) for a description of parasites found in dugongs.

5.2.3 Genetics

The most favoured tissue for genetic analysis from a fresh (Categories 1-3) carcass is gonad, liver or muscle (see Rainey 1981). If the carcass is not fresh, skin (the grey epidermal layer) and/or muscle is the most favoured. Collect a 1 cm x 0.5 cm sample and preserve either frozen (including blood samples), in 80% EtOH, 20% DMSO in saturated NaCl solution or dried (e.g. salted meat). Tissue preserved in formalin makes genetic work near impossible.

If a skin biopsy is to be taken from a live animal, it may be surgically removed from the trailing edge of the tail fluke using a sterile scalpel blade or a sterilised leather punch. Only a small amount of tissue is needed. The epidermis of the skin (grey in colour) contains the most DNA. The epidermis (only about 1 – 2 mm thick) may be scraped off using a sterile scalpel. The white, *fibrous* layer immediately beneath the skin (hyperdermis) is NOT suitable. Once the skin biopsy is obtained, the tissue should be immediately placed into the preservation solution.

An alternative material for DNA extraction is dugong faecal samples (Tikel *et al.* 1996). Collect faeces as they are eliminated from a live dugong, or from the distal colon of a freshly-dead dugong (Lanyon *et al.* 2005), or floating on top of the water surface. Care must be taken to prevent contamination of samples. Preserve faecal samples immediately either frozen (preferably at -80°C), in 80% EtOH, 0.01M Phosphate Buffered Saline (NaCl 0.138 M; KCl 0.0027 M) or 20% DMSO in saturated NaCl solution, and store at -20°C until analysed (Parsons *et al.* 1999).

5.2.4 Toxic Element and Organohalogen Analysis

Liver, kidney, muscle and blubber tissue samples should be taken as soon as possible. Brain should be sampled if organochlorine pesticide poisoning is suspected. Use a clean stainless steel knife to obtain samples. If possible, wash the knife, then rinse in distilled water and then in ethanol between sampling different tissues. Acetone and hexane rinses are preferred for collection of samples for organohalogen analyses; rinses with dilute nitric acid are preferred for samples collected for elemental analysis. Ensure as far as is practical that samples are not in contact with aerosols from insect repellent, tobacco smoke, exhaust fumes, petrol fumes, hand soap, etc. Samples should be placed individually in glass jars that have been pre-rinsed with acetone, hexane, and dilute nitric acid. If these are not available, samples may be securely wrapped individually in plastic bags or containers such that in the laboratory they can be trimmed and subsampled to provide specimens that have not directly contacted plastic surfaces (see Denton *et al.* 1980, Geraci & Lounsbury 1993). Samples should be frozen as soon as possible after collecting. Label each sample with date, location and tissue type. Make a note of any unusual field conditions (e.g. recent chemical spills, runoff) that may have an impact on subsequent pollutant levels. Samples that should be collected are detailed below.

Samples	Area Sampled	Quantity
Blubber (Fig. 30)	From the outer-most layer of blubber (under the white fibrous skin layer) just to one side of the mid-ventral line	300g (15cm square, grapefruit size sample)
Liver (Fig. 30)	From the <i>caudal</i> tip of the right lobe of the liver	300g
Muscle (Fig. 30)	Collected just to the right of the mid-ventral line (i.e. immediately under the blubber samples)	300g
Kidney (Fig. 30)	From the <i>caudal</i> end of the right kidney	300g
Milk*	From the teat	As much as possible
Brain**	Half of sagittally cut brain	As much as possible

*Milk may contain organochlorines that can be passed on to juvenile dugongs.

**If organochlorine pesticides are suspected as a cause of mortality, concentrations in brains must be determined. If cholinesterase-inhibiting pesticides are suspected, brain cholinesterase levels should be determined in comparison with controls, and *ingesta* analysed for cholinesterase-inhibiting pesticides. Note that one-half of the brain should be frozen and the other half preserved in 10% neutral buffered formalin (Section 4.10).

5.2.5 Urine

Urine can be collected from the urinary bladder of relatively fresh (Categories 1-3) carcasses with a sterile syringe. If the bladder is not distended it may be desirable to slit it to remove the urine with a syringe. Urine can be refrigerated but it should be submitted for culturing or clinical pathology as soon as possible after collecting. Samples can otherwise be frozen for later determination of *osmolality* and other urine values.

5.2.6 Haemolysed Blood

Haemolysed blood from very fresh carcasses (Categories 1-3) can be collected from the heart and stored frozen.

5.2.7 Microbiology

Sampling for microbiological testing may only be possible when a qualified professional (e.g. veterinarian, pathologist and/or trained microbiology technician) is conducting the *necropsy* and when the tissues are in suitable condition (usually Categories 1-3). Transport swabs should be removed from their sterile wrapping, brushed against the *lesion* or fluid requiring sampling, and replaced in the media tube as swiftly as possible to avoid contamination. The tube should then be labelled, chilled, and submitted to a microbiology laboratory within 72 hours. Separate swabs should be taken from areas where the presence of *pathogens* is suspected. Specimens may also be collected using rat-toothed forceps and scissors (from sterile packets) and placed in sterile plastic vials on ice. Sampling of the pleural surface of the lungs, bronchi, stomach *mucosa*, perineal fluid, fluid in the pericardial sac, brain surfaces, abscesses, or infected areas is recommended for relatively fresh (Categories 1-3) carcasses.

6 TRANSPORTATION OF SPECIMENS

All samples to be transported should be packaged in heavy-duty containers and should comply with the appropriate local protocol. It is important that all agencies involved in sending preserved samples are aware of the local regulations. Specimens sent in bottles should be sealed with tape and enclosed in sealed plastic bags. Specimens can also be sent wrapped; place tissues in paper towels moistened with 10% formalin and then place wrapped sample in a sealed bottle or in two sealed plastic bags (see Webb 1998). Place samples in a strong insulated container or cardboard box. Addresses on the transport box should be clearly marked. The inside of the container should contain a duplicate address and information specifying the material enclosed and nature of the shipment. Enclose a copy of the data sheet to provide pertinent information on the carcass.

Frozen samples must be shipped in very sturdy ice chests that will not break in transit. Use ice bricks to ensure samples stay cold. For long shipments, a substantial quantity of dry ice should be included. Three kilograms of dry ice lasts approximately 72 hours. Arrangements must be made with the receiver prior to shipping so that someone will be present to promptly handle the package and properly deal with the contents at the destination. Courier service and airfreight are acceptable. In the latter case, choose flights with a minimum number of connections, preferably at cooler times of the day. Inform the recipient by telephone of the identification number at the time of shipping in case the shipment is lost and requires tracing. In Australia, dry ice is considered a dangerous good and requires shipment in a specific foam container and accompanying paperwork filled out by a Dangerous Goods Officer. Therefore, prior to sending specimens in dry ice, the sender needs to liaise with a Dangerous Goods Officer in order to obtain instructions on packaging and paperwork.

International shipment of samples must comply with the local requirements of the Convention on International Trade in Endangered Species of Wild Fauna and Flora (CITES). In Australia, the *Environment Protection and Biodiversity Conservation Amendment (Wildlife Protection) Act 2001* is the legislative basis for conservation-orientated controls on the export and import of wildlife and wildlife products. Controls under this Act apply to transactions undertaken by museums, zoos, scientific institutions, commercial organisations, tourists, migrants and the general public. The Act controls the export of most Australian native animals and plants and fulfils Australia's legislative requirements as a signatory to CITES.

7 DETERMINATION OF CAUSES OF DEATH

Careful observations of stranded marine mammals can document evidence of natural mortality, such as disease and predation, as well as human-induced *trauma*, such as entanglement in fishing gear, vessel collisions, bullet wounds and knife marks. It is important to determine if injuries occurred before or after death (see section 4.2).

7.1 Disease

Dugongs, like other marine mammals, are susceptible to a wide range of diseases, some of them infectious, non-infectious, or *idiopathic*. Diseases documented in dugongs in northern, central and southern Queensland in Australia include parasitic diseases toxoplasmosis and cryptosporidiosis, *pneumonia*, pancreatitis, enteritis, peritonitis, salmonellosis, septicaemia starvation, and *trauma* from stingray barb penetration, vessel strike, shooting, propeller strike, and drowning (Campbell & Ladds 1981, Elliot *et al.* 1981, Hill *et al.* 1997, Marsh *et al.* 2000).

Two systemic parasitic diseases have been identified in wild dugongs, cryptosporidiosis and toxoplasmosis. Cryptosporidiosis was diagnosed in a dugong that displayed *anorexia*, lethargy and slow aimless swimming over three days, prior to dying (Hill *et al.* 1997). The parasite was identified as *Cryptosporidium parvum*, a small apicomplexan protozoan present in the small intestine of the dugong. *Cryptosporidium parvum* is the same species that infects humans (Morgan *et al.* 2000). It was speculated that human sewage may have been responsible for the source of infection (Bruce Hill, *pers comm.*). Toxoplasmosis has been identified in a wild dugong necropsied in south-east Queensland (Roger Kelly, *pers. comm.*). Parasites were observed in the brain and some internal organs of the dugong. Toxoplasmosis is caused by the protozoan parasite *Toxoplasma gondii*. *Toxoplasma gondii* infects a range of terrestrial and marine animals and the definitive host is the domestic cat (Bowater *et al.* 2003, Dubey & Beattie 1988). *Toxoplasma gondii* has also been described infecting Indo-Pacific humpback dolphins *Sousa chinensis* from Townsville, Queensland that inhabit similar inshore areas to dugongs (Bowater *et al.* 2003).

Wild dugongs support a wide range of parasites that inhabit various external body parts and internal organs. At least 19 species of trematodes and one species of nematode have been described from dugongs (Blair 1979, 1980, 1981a, 1981b, Bryden *et al.* 1998, Campbell & Ladds 1981, Cruz & Fernand 1954). External parasites include barnacles and copepods (Campbell & Ladds 1981). Most internal parasites are commensal organisms, however some have been associated with disease. A dugong found swimming aimlessly in shallow waters off the beaches of Townsville in 1999 died of verminous bronchopneumonia. Numerous trematodes, *Cochleotrema indicum* were present in the bronchi and bronchioles. Another dugong died from bacterial peritonitis, after an intestinal abscess ruptured. There were multiple mural abscesses of the small intestine containing the trematodes *Faredifex clavata*.

Dugongs may be susceptible to diseases documented in other sirenians and marine mammals, such as leptospirosis, lobomycosis, cryptococcosis, blastomycosis, caliciviruses, morbillivirus, papillomavirus, mycobacteriosis, tuberculosis, hepatitis, cold stress syndrome and brevetoxicosis (Bossart *et al.* 1998, 2002a, b, 2004, Bryden *et al.* 1998, Greenland *et al.* 2003, Morgan *et al.* 2000, Sato *et al.* 2003, Smith *et al.* 1978).

Necropsy of dead dugongs should only be done by qualified veterinarians or associated staff fully trained in *necropsy* procedures. The risk of contracting a zoonotic disease from contact with an infected animal should always be considered during *necropsy*. Proper clothing and safety precautions should always be followed at all times during a *necropsy*. Instruments, surfaces, and clothing etc. should be properly disinfected, autoclaved or discarded after the

necropsy is completed. The carcass should be disposed of according to local council and environmental and health regulations. See also Section 3.1 on safety.

Diagnosis of disease in dugongs requires examination of the sick animal by a qualified veterinarian. *Necropsy* of dead dugongs, to determine the cause of death, should ideally be done by a qualified veterinary pathologist. However field staff familiar with *necropsy* procedures can conduct necropsies, contact the nearest veterinary laboratory and send samples of organs and tissues to a veterinary pathologist at a veterinary pathology laboratory for testing, to help determine the cause of death. A range of tests can be conducted at the veterinary pathology laboratory including microbiology, histology, virology, parasitology and serology.

The following is an example of a dugong diagnosed as dying from a bacterial peritonitis infection:

A subadult male dugong, estimated to be about eight to nine years old and which measured 235 cm in length was reported floating offshore of Cardwell in northern Queensland, Australia. The carcass was in reasonably fresh condition, estimated to have been dead less than 24 hours. The Queensland Parks and Wildlife Service recovered the carcass, which was transported to James Cook University for a *necropsy* by a Department of Primary Industries and Fisheries veterinarian.

External examination

An examination of the external surfaces of the carcass did not reveal any unusual markings or indications of disease but bloody fluid was draining from both nares (a common post-mortem observation in dugongs). There was a light to moderate covering of barnacles on the dorsal surface of the animal. There was no evidence of shark bites; the head, body, both flippers and the tail were intact.

Internal examination (Figure 31)

When the carcass was opened for internal examination, a substantial subcutaneous fat layer was present. The abdominal cavity was full of a copious amount of peritoneal fluid (*ascites*) that was red/green in colour and of a foul odour. A large amount of *fibrin* was adhered to the viscera, especially to a small section of the small intestine, holding it to the *parietal peritoneum* of the dorsal aspect of the abdominal cavity. Faecal material in the large intestine was hardened indicating the animal may have been dehydrated prior to death.

The stomach was full of seagrass and a few nematodes *Paradujardinia halicoris* were in the cardiac gland of the stomach. A large amount of blood was present in the pericardial sac (*haemopericardium*) and pleural cavities (*haemothorax*). An area of *haemorrhage* was noted at the points of attachment of the spleen to the visceral surface of the stomach.

Tissue samples and swabs from major organs, peritoneal, pericardial and pleural effusions were taken for histology, virology, and bacteriology.

Cause of Death

Bacterial peritonitis with haemorrhagic septicaemia, as evidenced from *post-mortem*, histological examination and bacterial isolation. The bacterial peritonitis and haemorrhagic septicaemia were caused by a toxin producing bacterium, *Clostridium sporogenes*, isolated from organs and tissues. The bacteria is presumed to have entered the abdominal cavity via an intestinal perforation, caused by the penetration of an unidentified helminth parasite, from post-mortem and histological examination.

7.2 Predation

There is little information on non-human predation on dugongs. Dugongs have been preyed upon by killer whales and sharks in Shark Bay in Western Australia (Bryden *et al.* 1998, Heithaus *et al.* 2001). Dugongs with large scars are occasionally sighted, indicating they have

experienced and survived attacks by large sharks. There are accounts of shark attacks on dugong calves in northern Australia and dugong remains are commonly found in the stomachs of tiger sharks in Shark Bay (N. Gales, *pers comm.* 1999). Observers in aircraft have photographed dugongs in the jaws of crocodiles off Cape York Peninsula on at least two occasions, however, it was not known whether the dugongs died before or after the attack (Bryden *et al.* 1998). Sharks often bite at the head or tail of a dugong, unless they are very large sharks that are able to encircle the entire abdomen. Shark bites (Fig. 32) should not be confused with wounds caused by humans whereby the head or tail can be marked by a knife or other instrument, or entirely cut off to remove an entangled dugong from a net (see Fig. 29).

7.3 Dependent Calves

Calves which die at or soon after birth can be distinguished by: (1) the presence of *meconium* in the digestive tract (but no milk or vegetation), (2) an unhealed (a non-involuted) umbilicus, and clotted blood in the umbilical artery, and (3) horny plates in the mouth unstained by seagrass. Morphological abnormalities or birth defects, such as deformities of the heart, may contribute to an early death. Signs of starvation (see below) or *anorexia* are sometimes encountered in small calves (see Fig. 33).

Separated dependent calves may survive for some time before death. For example, a dependent stage calf (1.16 m) found shortly after death with extreme emaciation, some barnacles attached and no sign of the umbilical cord, had stomach and intestines full of chewed seagrass (personal observation David Savage and Dr Steve Johnson). Also faecal formation appeared normal although assimilation of nutrients from seagrass would seem improbable. Even calves larger than this one would have difficulty extracting suitable nutrition from seagrass without the benefit of their mother's milk.

7.4 Starvation

Carcasses with *emaciation* often have prominent dorsal processes of the cervical, thoracic and caudal vertebrae, and the bones of the skull may be prominent. Fat deposits are generally reduced in starving animals, and fat undergoes *serous atrophy*, leaving a clear or gel-like appearance to remaining fat deposits. Often a starving dugong will have darkened skin on various parts of the body (see Fig. 34). This should not be confused with damage caused by anthropogenic impact (e.g. rope marks, see Fig. 11). The most prominent serous atrophy occurs in the heart. Clear vesicular gelatinous material can adhere to the internal lining of the heart, and is occasionally visible on the exterior surface, indicating a condition called *cachexia* ('water fat'). This is an indication of severe starvation in dugongs (an internal examination of the heart will reveal this condition). The gastrointestinal tract may be empty or contain unusual material including algae, dead seagrass rhizomes and anoxic sediment. The gall bladder may be distended with bright yellow bile, indicating the animal has not eaten for some time. Animals in this condition may also have other systemic infections.

7.5 Vessel Strikes

Between 1996 and 2005, 36 dugongs were reported as having been struck by vessels in Queensland waters (Limpus *et al.* 1999, Haines & Limpus 2000, 2001, Limpus *et al.* 2002, Greenland *et al.* 2003, Greenland & Limpus 2004, 2006) (see Fig. 14). Vessel strikes are a major cause of mortality for Florida manatees, for example 713 (24%) of 2940 dead manatees between 1993 and 2003 were killed by watercraft-induced trauma (Ackerman *et al.* 1995, Lightsey *et al.* 2006, Laist & Shaw 2006). The rise of vessel traffic in the dugong's range is increasing the likelihood of vessel strikes. Areas of particular risk occur where there are extensive shallow areas of seagrass used by regionally important populations of dugongs close

to recreational or commercial boating facilities, and therefore subject to large amounts of boat traffic (e.g. Moreton Bay, near Brisbane and Missionary Bay, near Cardwell, Queensland).

It is important to measure propeller marks to gain an understanding of the size of vessels more likely to strike a dugong (see Rommel *et al.* 2007). Note that 'body creases' (Fig. 35), which vary amongst individual specimens, should not be confused with propeller marks (see Fig. 14). In some instances, tusk marks (see Fig. 15) may look similar to propeller marks.

Death from collisions with vessels is often sudden. Fresh, open propeller wounds or skeg marks provide obvious external clues to vessel strike (see Fig. 14a). Dugongs can be killed by impact alone or from crushing between the hull of the vessel and the substrate, leaving no propeller marks. External features providing clues to this type of incident include extensive scrape marks and asymmetry or twists along the main axis of the body. The superficial muscle layers, particularly on the top of the head and the back, should be examined, because there may be signs of massive *trauma*, such as bruising or *haemorrhage*. Sites of trauma are usually well-demarcated with blood-tinged patterns, and can be distinguished from autolysis in all but the most badly decomposed carcasses. Broken bones, particularly recent *fractures* of ribs or shattered scapulae, may also be observed (see Fig. 28). Broken ribs or vertebrae in dugongs caused by boat strikes have been reported in Queensland (Limpus *et al.* 2002) and in Shark Bay (N. Gales, *pers comm.* 1999). Massive *trauma* to internal organs may also be seen and large amounts of coagulated blood are sometimes found in the body cavities if major blood vessels are ruptured. Broken bones may perforate lungs or major blood vessels, the heart may *rupture*, and the kidneys may appear paler, softer, and larger than normal from loss of blood. Pulmonary *haemorrhage* may occur, causing the lungs to be heavy and saturated with blood (see Fig. 36 which shows massive trauma to lung), with an absence of frothy fluid in the bronchi. Pathology associated with vessel collision may include torn muscles or ligaments, bone fracture, *haemorrhage*, *anuria*, *petechial haemorrhages* of various organs and tissues, *ascites*, *haematoma*, *haemothorax* and *haemopericardium*.

External propeller wounds can be minor and superficial but also associated with massive internal *trauma* as described above. Boat propellers can cause severe wounds that penetrate the skin, underlying muscle layers and abdominal cavity causing serious internal organ damage. The possibility of a propeller cut occurring *post-mortem* can be determined using several clues. *Post-mortem* propeller cuts show no signs of *haemorrhage* or bruising of internal organs or musculature. If the wound is cut through with a knife and examined in cross-section and shows reddening around the edges, presence of *fibrin*, *pus*, or scar tissue, it was inflicted *ante-mortem*. The location of the propeller wound also provides a clue. Dead dugongs usually float with the ventral aspect exposed, and *ante-mortem* wounds on this aspect are rare. Wounds responsible for death are usually located on the dorsal aspects. Floating dead dugongs are probably also more easily seen and avoided by boat pilots than live animals. In Florida manatees, propeller scars and wounds have been reported on their lateral aspects, suggesting that the sides of the propeller can contact the animal (Rommel *et al.* 2007). *Post-mortem* propeller cuts have very rarely been encountered in Florida manatees (Bonde *et al.* 1983).

Dugongs struck by vessels may be healthy or sick at the time of strike. Dugongs surviving a boat-induced injury may already be chronically debilitated or go on to develop other infections. Even a dugong with only minor, externally healed propeller wounds may have more advanced acute or more chronic disease processes occurring. It is therefore important to do both an external and an internal examination of a carcass to look for evidence of disease. For example, there may be large *purulent* internal abscesses, signs of septicaemia, organ adhesions, or other signs of infection. Chronic *osteolytic* lesions from broken ribs can also lead to massive internal infections and subsequent death.

In a study of vessel strikes to Florida manatees, mortality may be a direct result of sharp and blunt-force trauma or from chronic effects resulting from either force (Lightsey *et al.* 2006). In

most of these cases, the cause of death could be determined by gross *necropsy* findings alone, even in the case of decayed carcasses because many watercraft-induced lesions are diagnostic and persist through autolysis. Common conditions in Florida manatees resulting from vessel strike include skin lesions, torn muscles, fractured and luxated bones, lacerated internal organs, hemothorax, pneumothorax, pyothorax, hydrothorax, abdominal hemorrhage and ascites, and pyoperitoneum (Lightsey *et al.* 2006).

The following examples are dugong carcasses that were positively identified as having died from boat strike injuries (Limpus *et al.* 2002):

1. Marine Park rangers witnessed a dugong being struck by a water taxi in Moreton Bay, Queensland, Australia. The body had 11 large deep propeller cuts into the thoracic and abdominal cavity, trauma to left lung and left kidney (Fig. 36).
2. An adult dugong was reported floating in a creek in Moreton Bay, Queensland, Australia. The necropsy revealed that the dugong had suffered fractured ribs and spine, punctured lungs and paralysis behind the mid body (Figs. 28 and 37).

7.6 Incidental Catch

Accidental entanglement in mesh nets set by fishers is an identified source of dugong mortality (Heinsohn *et al.* 1976). Shark nets set for bather protection can also entangle and kill dugongs (Gribble *et al.* 1998, Marsh *et al.* 2001, 2005). The ability to identify incidental catch as a cause of death in stranded dugongs is important because it provides information that may indicate a problem in a certain area. Specific marks on dugongs resulting from interactions with fishing gear have not been well documented, but can be differentiated from normal markings. As mentioned previously, the presence of numerous scars, scratches or parallel marks on the skin of the back and sides of the body are normal and are characteristic of dugongs (Fig. 38). These marks result from rubbing their backs against various types of substrate and from social interactions. For example, parallel scars on adult dugongs are likely tusk wounds resulting from interactions in mating herds (see Fig. 15). Parallel scarring may also be seen on orphaned infants from interactions with adult male dugongs (see Fig. 15). These tusk marks must not be confused with net entanglement marks (Fig. 11). As noted previously, if a dugong carcass is left to decay in the sun, the skin will crack in a mosaic type pattern that may resemble net entanglement marks (Fig. 11).

On cetacean carcasses, marks caused by monofilament nets, can be small thin cuts 1-2 cm deep in the epidermis (Hare & Mead 1987). Netting may also leave impressions instead of, or in addition to, cuts, particularly around the neck or snout. These can sometimes be seen in relatively decomposed carcasses. Read and Murray (1998) describe various types of netting marks on small cetaceans as a result of entanglement in fishing gear, which may assist examiners in identifying similar patterns in dugongs. As evidence of entanglement of small cetaceans, Read and Murray (1998) consider the presence of unhealed, narrow, linear lacerations or indentations in the epidermis, most commonly around the head, dorsal fin, flukes and flippers, to be diagnostic. As a result, in undertaking an external examination, these areas should be closely inspected for net marks. Examples of dugong carcasses with markings considered indicative of net entanglement are shown in Figs. 11 and 39.

Net marks may be obvious and extensive if the animal thrashes in the net or becomes more entangled during a release operation. Alternatively, net marks may be quite subtle and limited. There is some evidence that dugongs may be prone to capture stress syndrome. Elevated levels of serum potassium (a physiological manifestation of capture stress) were found in dugongs that had been chased and harpooned by Indigenous hunters (Marsh & Anderson 1983). Furthermore, as noted previously, dugongs suffocate, rather than drown by taking in water (B. Hill & R.

Kelly *pers comm.* 1999). As a result, dugongs that become entangled may die quickly, without struggling extensively and may not exhibit any external markings indicative of entanglement. For example, in April 1998 at Port Douglas, Queensland, Australia, a dugong was entangled in a commercial gill net whilst in attendance by the fisherman. The dugong was released from the net by the fisherman and towed ashore but subsequently died as a result of the entanglement. A *necropsy* undertaken by QPWS staff identified no external markings indicative of the net entanglement.

An incidental catch diagnosis may be dependent on the collection of detailed circumstantial evidence at the stranding site and the absence of any other signs found during *necropsy* that indicate an alternative cause of death (e.g. disease, boat strike).

The following is an example of a dugong carcass that was diagnosed as having died from entanglement:

An adult male dugong, estimated to have been dead for two to three days and which measured 260 cm in length, was reported floating offshore of Midge Point in northern Queensland, Australia. The Queensland Parks and Wildlife Service recovered the carcass, which was transported to a veterinary clinic for *necropsy* by a qualified veterinarian.

External examination (Figure 39)

The carcass was severely bloated, the penis having been extruded from the prepuce from the internal pressure (bloat).

Three or four bruise lines, 2 mm wide and 150 mm-200 mm long, were noted on the ventral surface of the neck. Deep bruising was observed around the base of the pectoral fins, especially on their ventral surface. Early lifting of the skin over the bruise lines on the neck had occurred.

Subcutaneous emphysema with mild deep bruising of the musculature at the base of the pectoral fins were noted. Possible bruising of the tail – patches of blood stained/bruised tissue near the centre of tail were collected for histology.

Internal examination

Severe autolysis of the liver, of the right side of heart and of the kidneys had occurred. The liver and kidney had liquefied and darkened; however, the testis had liquefied but not darkened. The stomach was full of seagrass and a few nematode worms were present. The lungs had moderate *emphysema* (small gas filled pockets).

Samples were taken for histopathology. There were no signs of disease or infection within the animal.

Cause of Death

The bruising around the neck and pectorals is consistent with trauma caused by entanglement with some type of rope. The air embolisms on the tissue surface of the right lung were consistent with suffocation/drowning.

Given these findings, and the lack of any other obvious causes of death, this animal was judged to have died from trauma caused by entanglement leading to suffocation. The excessive degenerative change of the liver, kidney and heart may be the result of a struggle at the time of death, raising the animal's internal body temperature while depleting the intracellular energy reserves.

There is also evidence that there has been human intervention to 'conceal' dugong carcasses that have most likely been entangled. Efforts to conceal usually involved slitting open the abdominal cavity of the carcass to assist with sinking it and attaching weights (see Fig. 40) or the removal of the head or tail to disentangle the dugong (see Fig. 29).

7.7 Other Human-Related Causes

Diagnosis of “dry” drowning (which may be a result of entanglement, see Section 7.6) is made by excluding other significant lesions, and is presumptive at best because drowning in dugongs leaves little or no tell-tale morphological signs, and the tissues will look essentially normal (Anita Gordon, *pers. comm.* 2006).

Bullet wounds leave small entry holes on the external surface, which must be searched for carefully during *necropsy*. Knife wounds typically leave a straight cut (Fig. 12). Shotgun pellets or other foreign objects resulting from non-lethal wounding may be encountered during *necropsy* when removing the skin or flesh, for example, in the snout/head region. Radiography of areas with suspicious or unusual lesions will help locate foreign objects. If bullets are found, they should be collected as evidence for compliance investigations (see Section 3.5). The carcass should also be carefully examined for spear wounds (see Fig. 13). Any suspected human-related marks should be described, measured and photographed.

There is increasing evidence of dugongs ingesting fishing gear, which has resulted in their death (see Fig. 19). Careful internal examination of the entire gastrointestinal tract is required. Figure 19 shows a dugong that ingested a fishing line and hook, that eventually perforated the intestinal wall, resulting in peritonitis and death.

Dugongs that have been killed for meat usually have large pieces of flesh missing from the carcass, often from the abdomen.

Acute or chronic exposure to pollution is another potential cause of death or poor health in dugongs. Studies have found elevated concentrations of some contaminants in dugongs along the Queensland coast (e.g. Haynes *et al.* 1999, 2005, McLachlan *et al.* 2001, Vetter *et al.* 2000). While knowledge of resultant health and physiological effects on dugongs is very limited, a risk assessment found a high potential for adverse health effects from specific organochlorine pollutants (e.g. dioxins, Gaus *et al.* 2004). Exposure to toxicants may also result in a lowered immune response and other secondary health effects. If exposure to contaminants is suspected, samples should be taken and analysed (see Section 4.1.1 and 4.10). Poor water quality and pollution, particularly with herbicides may also cause significant seagrass loss leading to starvation in dugongs (Haynes *et al.* 2000, Müller *et al.* 2000) (see Section 7.4).

Underwater explosions are difficult to diagnose from a cause-of-death standpoint because the *trauma* inflicted could merely be enough to cause the animal to lose consciousness. However, more severe injuries may include massive trauma and internal injury.

7.8 Undetermined

Cases can be classified as undetermined if no cause of death is apparent following *necropsy* and subsequent histopathology.

8 GLOSSARY¹

Abscess - a localised collection of *pus* in a cavity formed by disintegration of tissues.

Adhesion - the stable joining of parts to one another, usually abnormally.

Aneurysm - a sac formed by localised dilation of a blood vessel.

Anorexia - loss of appetite for food.

Anterior - in front of (toward the head end of the body).

Ante-mortem - before death.

Anuria - absence of urine in bladder indicating possible suppression of urine formation by the kidney.

Ascites - abnormal accumulation of serous (oedematous) fluid within the peritoneal cavity, characterized by distension of the abdominal cavity.

Aspiration - the act of inhaling. In 'terminal aspiration' smooth muscle relaxing post-mortem allows contents of gut to return into the oesophagus.

Atrophy - a wasting away, causing a reduction in size.

Axial Skeleton - the skeleton of the head and trunk.

Axilla - the armpit, in dugongs the area between the flipper and the thoracic wall.

Cachexia - profound and marked state of constitutional disorder; general ill health and malnutrition. (General appearance is clear gelatinous material adhering to the internal lining of the heart.)

Caudal - pertaining to or towards the tail.

Chicken-fat clot - a clot that develops after death, largely devoid of red blood cells. Common in animals with anaemia or with increased blood sedimentation rate. In dugongs, appears as a greyish-yellow clot.

Coarctation - stricture or narrowing.

Coeliac - pertaining to the abdomen.

Congenital - present at or existing from the time of birth.

Cranial - pertaining to or towards the head.

Cyst - a closed bladder-like sac formed in animal tissue, usually containing fluid or a semi-solid material.

Dilatation - a condition of being expanded or stretched beyond normal dimensions.

¹ Definitions adapted from *The American Heritage Dictionary of the English Language* (W. Morris, ed. 1976. Houghton Mifflin Company, Boston, Mass. 1550 pp.), *Dorland's Pocket Medical Dictionary* (J.P. Friel, ed. 1977. 22nd ed. W.B. Saunders Company, Philadelphia, Penn. 741 pp.); *Veterinary Pathology* (Smith, H.A., T.C. Jones, and R.D. Hunt. 1972. 4th ed. Lea and Febiger, Philadelphia, Penn. 1521 pp.); and *Baillière's Comprehensive Veterinary Dictionary* (D.C. Blood and V. P. Studdert. 1988. Baillière's Tindall, Sydney, NSW, Australia. 1123pp).

Distal - remote; farther from any point of reference.

Dyspnoea - laboured or difficult breathing.

Emaciation - excessively thin, wasted condition of the body.

Embolus (plural *Emboli*) - undissolved material carried by the blood flow and impacted in some part of the blood *vascular* system as *thrombi* or fragments of thrombi, tissue fragments, clumps of bacteria, protozoan parasites, fat globules or gas bubbles.

Emphysema - a pathological accumulation of air in tissues.

Enteritis - *inflammation* of the intestine.

External auditory meatus - external opening of the ear.

Fascia - a sheet or band of *fibrous* tissue.

Fibrin - a dull white stringy material formed by the coagulation of fibrinogen.

Fibrinous - pertaining to or of the nature of *fibrin*.

Fibrosis - a formation of *fibrous* tissue.

Fibrous - composed of or containing fibres.

Foci - small discrete points or areas.

Fornix - an archlike structure or space.

Fracture - the breaking of a part, especially a bone.

Friable - easily pulverised or crumbled.

Haemopericardium - an effusion of blood in the pericardial cavity, caused by rupture of the atrium, a coronary artery or perforation of the ventricle, usually manifested by sudden death.

Haemothorax - collection of blood in the pleural cavity that can cause the collapse of the lung or *dyspnoea*.

Haemorrhage - the escape of blood from a ruptured vessel; bleeding.

Haematoma - a bruise or collection of blood in a tissue, organ or space.

Haemostat - an instrument or agent used to compress or trap bleeding of blood vessels to stop *haemorrhage*.

Hepatisation - transformation into a firm mass, liver-like in texture.

Hypertrophy - increase or enlargement of an organ or part, due to an increase in the size of its constituent cells.

Idiopathic - occurring without known cause.

Impaction - being wedged in firmly.

Inferior - situated below, or directed downward.

Inflammation - a localised protective tissue response elicited by injury or destruction of tissues, which serves to destroy, dilute, or wall off both the injurious agent and the injured tissue.

Inflation - distension or the act of distending, with air, gas or fluid.

Ingesta - material taken into the body by the mouth.

Ketone - any compound containing the carbonyl group, CO, and having hydrocarbon groups attached to the carbonyl carbon.

Lateral - denoting a position farther from the *medial* plane or midline; side.

Lesion - a pathologic or traumatic discontinuity of tissue.

Lumen - a cavity or channel within a tube or organ.

Meconium - dark green mucilaginous material in the intestine of the foetus.

Medial - situated towards the midline.

Mucosa - mucus-producing membrane; this includes the tissue lining the *lumen* of the gastrointestinal tract and the urinary bladder.

Necropsy - examination of a body after death.

Necrosis - death of individual cells or groups of cells.

Nodules - a small node that is solid and can be detected by touch.

Oedema - an abnormal accumulation of fluid in a body cavity or in the intercellular spaces of a tissue or organ, usually leading to swelling.

Oedematous - characterised or pertaining to *oedema*.

Osmolality - the concentration of a solution in terms of osmoles of solutes per kilogram of solvent.

Osteolytic - dissolution of bone.

Parietal peritoneum - a *serous* membrane lining the walls of the visceral cavity.

Parturient - giving birth or pertaining to birth.

Patent - open, unobstructed, or not closed.

Patency - state of being open, i.e. not being blocked or obstructed.

Pathogen - any disease-producing agent or microorganism.

Peduncle - the narrow area between the body and the tail of the dugong.

Peritoneum - the *serous* membrane lining the walls of the abdominal and pelvic cavities (*parietal peritoneum*) and investing contained viscera (*visceral peritoneum*), the two layers enclosing a potential space, the *peritoneal cavity*.

Peritonitis - inflammation of the peritoneum.

Petechia (plural *Petechiae*) - a minute red spot due to the escape of a small amount of blood.

Placental scars - conspicuous purple bands in the uterine endometrium.

Plaque - a small, flat, rounded formation or area, as a deposit of *fibrous* matter in the wall of a blood vessel or localised patch of skin disease.

Pneumonia - *inflammation* of the lungs with exudate and consolidation.

Polyp - a growth or mass protruding from a mucous membrane.

Posterior - directed towards or situated at the back.

Post-mortem - performed or occurring after death.

Proximal - nearest to the point of reference.

Purulent - containing or forming *pus*.

Pus - a protein-rich liquid *inflammation* product made up of cells (leukocytes), a thin fluid (liquor puris) and cellular debris.

Rupture - tearing of tissue.

Serosa - serum-producing membrane; outermost surface or wall of the gastrointestinal tract.

Serous - pertaining to or resembling serum; usually a watery fluid.

Spicule - a sharp needle-like body.

Stenosis - narrowing or contraction of a body passage or opening.

Subcutaneous emphysema - air or gas in the subcutaneous tissues. The lesion is characteristically soft, mobile with swelling that crackles like stiff paper when palpated.

Thrombus (plural *Thrombi*) - a *fibrinous* clot which forms in and obstructs a blood vessel, or which forms in one of the heart's chambers.

Trauma - a wound or injury.

Tubercle - small rounded projection or small firm nodule or swelling.

Tumour - swelling; a new growth of tissue.

Ulcer - a local defect produced by sloughing of necrotic inflammatory tissue.

Vascular - pertaining to blood supply.

Verrucous - rough, warty.

Vesicle - a small bladder or sac containing fluid; a small blister.

9 ACKNOWLEDGEMENTS

Many people have assisted in the preparation of the first and/or second editions of this manual. We would like to thank the many reviewers including those from the Queensland Parks and Wildlife Service (Ian Bell, Grahame Byron, Dr. Sandy Clague, Dr. Don Cook, Artie Jacobson, Dr. Jeff Miller, John Olds, Paul O'Neill, Dave Orgill, Dr. Mark Read, David Savage, Michael Short, Cathy Skippington, Kirsten Wortel); the Great Barrier Reef Marine Park Authority (Ken Anthony, David Haynes, James Sheppard, Tony Stokes); the Queensland Government Department of Primary Industries and Fisheries veterinarians (Dr. Bruce Hill, Dr. Steve Johnson, Dr. John Norton); Veterinarians (Dr. Tim Annand, Dr. David Jaimson); the Commonwealth Scientific and Industrial Research Organisation (Hamish Malcolm, now with New South Wales Marine Parks Authority); the University of Queensland (Dr. Caroline Gaus - National Research Centre for Environmental Toxicology, Dr. Roger Kelly - School of Veterinary Science, Dr. Janet Lanyon - Department of Zoology); the Department of Conservation and Land Management in Western Australia (Dr. Nick Gales); Seaworld (Dr. Wendy Blanshard) and James Cook University (Dr. George Heinsohn, Adrian McMahon). Jenny Greenland (Environmental Protection Agency), David Savage (Queensland Parks and Wildlife Service), and Artie Jacobson (formerly Queensland Parks and Wildlife Service, Airlie Beach) assisted with the compilation of photographs. The first edition of this publication was funded by the Great Barrier Reef Marine Park Authority, James Cook University and the Co-operative Research Centre (CRC) for the Reef Research. Natural Heritage Trust funding from the Day-to-Day Management Coordination Unit of the GBRMPA contributed to production of the second edition.

10 REFERENCES

- Ackerman, B. B., Wright, S. D., Bonde, R. K., Odell, D. K. & Banowetz, D. J. 1995. 'Trends and patterns in mortality of manatees in Florida, 1974-1992', pp. 223-258 in *Population Biology of the Florida Manatee (Trichechus manatus latirostris)*, T. J. O'Shea, B. B. Ackerman, and H. F. Percival (eds.) National Biological Service, Information and Technology Report 1. 289 pp.
- Blair, D. 1979. 'A new family of Monostome flukes (Platyhelminths, Digenea) from the Dugong, *Dugong dugon* (Müller)'. *Annales de Parasitologie* 54(5), 519-526.
- Blair, D. 1980. '*Indosolenorchis hirudinaceus* Cruzs, 1951 (Platyhelminths, Digenea) from the Dugong, *Dugong dugon* (Müller) (Mammalia; Sirenia)'. *Annales de Parasitologie* 55(5), 511-525.
- Blair, D. 1981a. 'Helminth parasites of the dugong, their collection and preservation', pp. 275-285 in *The Dugong: Proceedings of a seminar/workshop held at James Cook University 8-13 May 1979*. H. Marsh (ed.) James Cook University, Townsville, Queensland, Australia.
- Blair, D. 1981b. 'The Monostome flukes (Digenea: families Opisthotrematidae Poche and Rhabdiopoeidae Poche) Parasitic in Sirenians (Mammalia: Sirenia)'. *Australian Journal of Zoology Supplementary Series* 81, 1-54.
- Blanshard, W. 2006. 'Update of Captive Dugong in Australia'. *Sirennews*, Newsletter of the IUCN/SSC Sirenia Specialist Group No. 45, April 2006.
- Bonde, R. K., O'Shea, T. J. & Beck, C. A. 1983. *Manual of Procedures for the Salvage and Necropsy of Carcasses of the West Indian Manatee (Trichechus manatus)*. National Technical Information Service, Springfield, VA. Doc. No. PB83-255273, 175 pp.
- Bossart, G. D., Baden, D. G., Ewing, R. Y., Roberts, B. & Wright, S. D. 1988. 'Brevetoxicosis in manatees (*Trichechus manatus latirostris*) from the 1996 epizootic: gross, histologic and immunohistochemical features'. *Toxicologic Pathology* 26, 276-282.
- Bossart, G. D., Ewing, R. Y., Lowe, M., Sweat, M., Decker, S. J., Walsh, C. J., Ghim, S. -J. & Jenson, A. B. 2002a. 'Viral papillomatosis in Florida manatees (*Trichechus manatus latirostris*)'. *Experimental and Molecular Pathology* 72, 37-48.
- Bossart, G. D., Meisner, R. A., Rommel, S. A., Ghim, S.-J. & Jenson, A. B. 2002b. 'Pathological features of the Florida manatee cold stress syndrome'. *Aquatic Mammals* 29(1), 9-17.
- Bossart, G. D., Meisner, R. A., Rommel, S. A., Lightsey, J. D., Varela, R. A. & Defran, R. H. 2004. 'Pathologic findings in Florida manatees'. *Aquatic Mammals* 30(3), 434-440.
- Bowater, R. O., Norton, J., Johnson, S., Hill, B., O'Donoghue, P. & Prior, H. 2003. 'Toxoplasmosis in Indo-Pacific humpbacked dolphins (*Sousa chinensis*), from Queensland'. *Australian Veterinary Journal* 81(10), 627-632.
- Bryden, M., Marsh, H. & Shaughnessy, P. 1998. *Dugongs, Whales, Dolphins and Seals. A Guide to the Sea Mammals of Australasia*. Allen & Unwin: St. Leonards NSW.
- Campbell, R.S.F. & Ladds, P.W. 1981. 'Diseases of the dugong in north-eastern Australia: a preliminary report'. pp. 176-181 in *The Dugong: Proceedings of a seminar/workshop held at*

- James Cook University 8-13 May 1979. H. Marsh (ed.) James Cook University, Townsville, Queensland, Australia.
- Crusz, H & Fernand, V. S. F. 1954. 'The trematode parasites of the dugong with descriptions of two new monostomes and histopathological changes in the host'. *Journal of Parasitology* 40, 499-507.
- Denton, G. R., Marsh, H., Heinsohn, G. E. & Burdon-Jones, C. 1980. 'The unusual metal status of the dugong (*Dugong dugon*)'. *Marine Biology* 57, 201-219.
- Dubey, J. P & Beattie, C. P. 1988. *Toxoplasmosis of animals and man*. CRC Press, Boca Raton, Florida, pp 1-215.
- Elliot, H., Thomas, A., Ladds, P. N. & Heinsohn, G. E. 1981. 'A fatal case of salmonellosis in a dugong'. *Journal of Wildlife Diseases* 17, 203-208.
- Gaus, C., Brunskill, G. J., Weber, R., Pöpke, O. & Müller, J. F. 2001a. 'Historical PCDD inputs and their source implications from dated sediment cores in Queensland (Australia)'. *Environmental Science and Technology* 35, 4597-4603.
- Gaus, C., Pöpke, O., Dennison, N., Haynes, D., Shaw, G. R., Connell, D. W. & Müller, J. F. 2001b. 'Evidence for the presence of a widespread PCDD source in coastal sediments and soils from Queensland, Australia'. *Chemosphere* 43(4-7), 549-558.
- Gaus, C., O'Donohue, M., Connell, D., Müller, J., Haynes, D. & Papke, O. 2004. 'Exposure and potential risks of dioxins to the marine mammal dugong'. *Organohalogen Compounds* 66, 1559-1566.
- GBRMPA. 1981. *Nomination of the Great Barrier Reef by the Commonwealth of Australia for inclusion in the World Heritage List*. Unpublished report to the World Heritage Committee, UNESCO. 14pp.
- Geraci, J. R. & Lounsbury, V. J. 1993. *Marine Mammals Ashore: A Field Guide for Strandings*. Texas A&M University Sea Grant College Program: Texas. TAMU-SG-93-601. 305pp. (Updated in 1998 and available on CD-ROM from the National Aquarium, 501 E. Pratt St., Baltimore, MD 21202, USA.).
- Geraci, J. R. & V. J. Lounsbury. 2005. *Marine Mammals Ashore: A Field Guide for Strandings*. Second Edition. National Aquarium in Baltimore, Maryland, USA. 372pp.
- Greenland, J. A. & Limpus, C. J. 2004. *Marine wildlife stranding and mortality database annual report 2004 I. Dugong, Conservation technical and data report*, Volume 2004, Number 1, Environmental Protection Agency, Queensland, Australia. 27pp.
- Greenland, J. A. & Limpus, C. J. 2006. *Marine wildlife stranding and mortality database annual report 2005, I. Dugong, Conservation technical and data report*, Volume 2005, Number 1, Environmental Protection Agency, Queensland, Australia. 29pp.
- Greenland, J. A., Limpus, C. J. & Currie, C. J. 2003. *Marine wildlife stranding and mortality database annual report 2003 I. Dugong*, Environmental Protection Agency, Queensland, Australia. 36pp.

- Gribble, N. A., McPherson, G. & Lane, B. 1998. 'Effect of the Queensland Shark Control Program on non-target species: whale, dugong, turtle and dolphin: a review'. *Marine and Freshwater Research* 49, 645-651
- Haines, J. A. & Limpus, C. J. 2000. *Marine Wildlife Stranding and Mortality Database Annual Report 2000, I. Dugong*. Research Coordination Unit, Parks and Wildlife Strategy Division, Queensland Parks and Wildlife Service, Queensland, Australia. 21pp.
- Haines, J. A. & Limpus, C. J. 2001. *Marine Wildlife Stranding and Mortality Database Annual Report 2001, I. Dugong*. Conservation technical and data report Volume 2001, Number 1. Conservation Sciences Unit, Forestry and Wildlife Division, Environmental Protection Agency, Queensland, Australia. 21pp.
- Hare, M. P. & Mead, J. G. 1987. *Handbook for determination of adverse human-marine mammal interactions from necropsies*. Marine Mammal Program, National Museum of Natural History, Smithsonian Institution, Washington, D.C. NWAFC Processed Report 87-06. 35pp.
- Haynes, D., Müller, J. & McLauchlan, M. S. 1999. 'Polychlorinated dibenzo-*p*-dioxins and dibenzofurans in Great Barrier Reef (Australia) dugongs (*Dugong dugon*)'. *Chemosphere* 38, 255-262.
- Haynes, D., Müller, J. & Carter, S. 2000. 'Pesticide and herbicide residues in sediments and seagrasses from the Great Barrier Reef World Heritage Area and Queensland coast'. *Marine Pollution Bulletin* 41, 279-281.
- Haynes, D. & Kwan, D. 2001. *Trace Metal Concentrations in the Torres Strait Environment and Traditional Seafood Species, 1997- 2000*. Torres Strait Regional Authority, Thursday Island, Queensland, Australia.
- Haynes, D. & Schaffelke, B. (eds). 2004. *Catchment to reef: water quality issues in the Great Barrier Reef Region, 9-11 March 2004, Conference abstracts*, CRC Reef Research Centre, Townsville.
- Haynes, D., Carter, S., Gaus, C., Müller, J. & Dennison, W. 2005. 'Organochlorine and heavy metal concentrations in blubber and liver tissue collected from Queensland (Australia) dugong (*Dugong dugon*)'. *Marine Pollution Bulletin* 51, 361-369.
- Heinsohn, G. E. 1981. 'Methods of taking measurements, other data and specimen material from dugong carcasses', pp. 228-238 in *The Dugong: Proceedings of a seminar/workshop held at James Cook University 8-13 May 1979*. H. Marsh (ed.) James Cook University, Townsville, Queensland, Australia.
- Heinsohn, G. E., Marsh, H. & Spain, A. V. 1976. 'Extreme risk of mortality to dugongs (Mammalia: Sirenia) from netting operations'. *Australian Journal of Wildlife Research* 3, 117-121.
- Heithaus, M. R. 2001. 'The biology of tiger sharks (*Galeocerdo cuvier*) in Shark Bay, Western Australia: sex ratio, size distribution, diet, and seasonal changes in catch rates'. *Environmental Biology of Fishes* 61, 2536.
- Hill, B. D., Fraser, I. R. & Prior, H. C. 1997. 'Cryptosporidium infection in a dugong (*Dugong dugon*)'. *Australian Veterinary Journal* 75(9), 670-671.
- Husar, S. 1978. '*Dugong dugon*'. *Mammalian Species* 88, 1-7.

- International Union for the Conservation of Nature. 2006. *IUCN Red List of Threatened Animals*. J. Baillie and B. Groombridge (eds.) IUCN, Gland, Switzerland.
- Kwan, D. 2002. *Towards a sustainable indigenous fishery for dugongs in Torres Strait: a contribution of empirical data and process*, PhD Thesis, School of Tropical Environment Studies and Geography, James Cook University, Townsville.
- Laist, D. W. & Shaw, C. 2006. 'Preliminary evidence that boat speed restrictions reduce deaths of Florida manatees'. *Marine Mammal Science* 22(2), 472-479.
- Lanyon, J. M., Smith, K. M. & Carrick, F. N. 2005. 'Reproductive steroids are detectable in the faeces of dugongs'. *Australian Zoologist* 33(2), 247- 250.
- Lawler, I., & Andre, J. 2001. *Analysis of stomach contents of dugongs stranded in the Central Region of the GBR Marine Park: May-August 2000*. 7pp. (Available from www.gbrrmpa.gov.au/corp_site/info_services/library/resources/documents/stomach_contents_report_2001_03.pdf).
- Lightsey, J. D., Rommel, S. A., Costidis, A. M. & Pitchford, T. D. 2006. 'Methods used during gross necropsy to determine watercraft-related mortality in the Florida manatee (*Trichechus manatus latirostris*)'. *Journal of Zoo and Wildlife Medicine* 37(3), 262-275.
- Limpus, C. J., Haines, J. A. & Flakus, S. 1999. *Marine wildlife stranding and mortality database annual report, 1999, I. Dugong*. Research Coordination Unit, Planning and Research Division, Queensland Parks and Wildlife Service, Queensland, Australia. 30pp
- Limpus, C. J., Currie, K. J. & Haines, J. 2002. *Marine wildlife stranding and mortality database annual report 2002, I. Dugong*. Conservation technical and data report Volume 2002, Number 1, Environmental Protection Agency, Queensland, Australia. 51pp.
- Marsh, H. 1980. Age determination of the dugong, *Dugong dugon* (Muller), in Northern Australia and its biological implications. *Report of the International Whaling Commission (Special Issue)* 3, 181-201.
- Marsh, H. 1981. 'Preliminary description of the reproductive organs of the female dugong and suggested methods of specimen collection as part of a carcass salvage program'. pp. 248-260 in *The Dugong: Proceedings of a seminar/workshop held at James Cook University 8-13 May 1979*. H. Marsh (ed.) James Cook University, Townsville, Queensland, Australia.
- Marsh, H. 1995. 'The life history, pattern of breeding and population dynamics of the dugong'. pp. 75-83 in *Population Biology of the Florida Manatee*. T. J. O'Shea, B. B. Ackerman and H. F. Percival (eds). U. S. Department of the Interior. National Biological Service. Information and Technology Report 1, Washington, D. C.
- Marsh, H. 1999. 'Reproduction in sirenians'. pp. 243-256 in *Marine Mammals*. J. E. Reynolds, III and S. A. Rommel (eds.) Smithsonian Institution Press, Washington D.C.
- Marsh, H. & Anderson, P. K. 1983. 'Probable susceptibility of dugongs to capture stress'. *Biological Conservation* 25, 1-3.
- Marsh, H. & Glover, T. D. 1981. 'A preliminary description of the reproductive organs of the male dugong and suggested methods of specimen collection', pp. 261-274 in *The Dugong: Proceedings of a seminar/workshop held at James Cook University 8-13 May 1979*. H. Marsh (ed.) James Cook University, Townsville, Queensland, Australia.

- Marsh, H. & Lefebvre, L.W. 1994. 'Sirenian status and conservation efforts'. *Aquatic Mammals* 20, 155-170.
- Marsh, H., Heinsohn, G. E. & Spain, A. V. 1977. 'The stomach and duodenal diverticula of the Dugong (*Dugong dugon*)'. pp. 271-295 in *Functional Anatomy of Marine Mammals* R. J. Harrison (ed.). Academic Press, London.
- Marsh, H., Channells, P. W., Heinsohn, G. E. & Morissey, J. 1982. 'Analysis of stomach contents of dugongs from Queensland'. *Australian Wildlife Research* 9, 55-67.
- Marsh, H., Eros, C., & Webb, R. O. 2000. 'Dugongs in health and disease', pp. 301-317 in *Marine Wildlife*. The Fabian Fay Course for Veterinarians. Proceedings 335, 4-8 September 2000. Post Graduate Foundation in Veterinary Science (ed), University of Sydney, New South Wales, Australia.
- Marsh, H., Heinsohn, G. E. & Channells, P. W. 1984a. 'Changes in the ovaries and uterus of the dugong, *Dugong dugon* (Sirenia: Dugongidae) with age and reproductive activity'. *Australian Journal of Zoology* 32, 743-766.
- Marsh, H., Heinsohn, G. E. & Glover, T. D. 1984b. 'Changes in the male reproductive organs of the dugong, *Dugong dugon* (Sirenia: Dugongidae) with age and reproductive activity'. *Australian Journal of Zoology* 32, 721-742.
- Marsh, H., Heinsohn, G. E. & Marsh, L. M. 1984c. 'Breeding cycle, life history and population dynamics of the dugong, *Dugong dugon* (Sirenia: Dugongidae)'. *Australian Journal of Zoology* 32, 767-785.
- Marsh, H., De'ath, G., Gribble, N. & Lane, B. 2001. *Shark control records hindcast serious decline in dugong numbers off the urban coast of Queensland*, Great Barrier Reef Marine Park Authority Research Publication Series No. 70, Great Barrier Reef Marine Park Authority, Townsville.
- Marsh, H., De'ath, G. Gribble, N. & Lane, B. 2005. 'Historical marine population estimates: Triggers or targets for conservation? The dugong case study'. *Ecological Applications* 15, 481-492.
- McDonald, B. 2006. *Population genetics of dugongs*. PhD Thesis, James Cook University, School of Tropical Biology, James Cook University, Townsville.
- McLachlan M.S., Haynes, D. & Müller, J.F. 2001. 'PCDDs in the water/sediment-seagrass-dugong (*Dugong dugon*) food chain on the Great Barrier Reef (Australia)'. *Environmental Pollution* 113(2), 129-134.
- Morgan, U. M., Xiao, L., Hill, B. D., O'Donoghue, P., Limor, J., Lal, A. & Thompson, C. A. 2000. 'Detection of the *Cryptosporidium parvum* "Human" Genotype in a Dugong (*Dugong dugon*)'. *Journal of Parasitology* 86(6), 1352-1354.
- Müller, J. F., Duquesne, S., Ng, J., Shaw, G., Krrishnamohan, K., Manonmanii, K., Hodge, M. & Eaglesham, G. K. 2000. 'Pesticides in sediments from Queensland irrigation channels and drains'. *Marine Pollution Bulletin* 41, 294-301.
- Parsons, K. M., Dallas, J. F., Claridge, D. E., Durban, J. W., Balcomb, K. C., Thompson, P. M. & Noble, L. R. 1999. 'Amplifying dolphin mitochondrial DNA from faecal plumes'. *Molecular Ecology* 8(10), 1766-1768.

- Preen, A. R. 1995. Diet of dugongs: are they omnivores? *Journal of Mammalogy* 76, 163-171.
- Queensland Parks and Wildlife Service & Great Barrier Reef Marine Park Authority. 1999. *A review of Queensland's dugong stranding and carcass response procedures*. QPWS, Brisbane, Queensland, Australia. 33 pages + Attachments.
- Rainey, W. E. 1981. 'Procedure for collection of dugong tissues for electrophoresis'. pp. 240-247 in *The Dugong: Proceedings of a seminar/workshop held at James Cook University, 8-13 May 1979*, H. Marsh (ed.) James Cook University, Townsville, Queensland, Australia.
- Read, A. J. & Murray, K. T. 1998. *Gross evidence of human-induced mortality in small cetaceans*. NOAA Technical Memorandum NMFS-OPR 15. 21pp. Silver Spring, Maryland.
- Rommel, S. A., Costidis, A. M., Pitchford, T. D., Lightsey, J. D., Snyder, R. H. & Haubold, E. M. 2007. 'Forensic methods for characterizing watercraft from watercraft-induced wounds on the Florida manatee (*Trichechus manatus latirostris*)'. *Marine Mammal Science* 23(1), 110-132.
- Rowlatt, U. & Marsh, H. 1985. 'The heart of the dugong (*Dugong dugon*) and the West Indian Manatee (*Trichechus manatus*) (Sirenia)'. *Journal of Morphology* 186, 95-105.
- Sato, T., Shibuya, H., Ohba, S., Nojiri, T. & Wataru, S. 2003. 'Mycobacteriosis in two captive Florida manatees (*Trichechus manatus latirostris*)'. *Journal of Zoo & Wildlife Medicine* 34(2), 184-188.
- Smith, A. W., Vedrus, N. A., Akers, T. G. & Gilmartin, W. E. 1978. 'Hazards of disease transfer from marine mammals to land mammals: review and recent findings'. *Journal of the American Veterinary Medical Association* 173(9), 1131-1133.
- Tikel, D. 1998. *Using a Genetic Approach to Optimise Dugong (Dugong dugon) Conservation Management*. PhD Thesis. James Cook University, Townsville, Queensland, Australia. 277 pp.
- Tikel, D., Blair, D. & Marsh, H. D. 1996. 'Marine mammal faeces as a source of DNA'. *Molecular Ecology* 5, 456-457.
- U.S. Marine Mammal Commission. 1998. *Annual report to Congress 1997*. Marine Mammal Commission, Bethesda, Maryland.
- Vetter, W., Scholz, E., Luckas, B., Gaus, C., Müller, J. & Haynes, D. 2000. 'Anthropogenic and natural persistent, bioaccumulative organohalogen compounds in dugongs (*Dugong dugon*) and a bottlenose dolphin (*Tursiops truncatus*) from Australia'. *Organohalogen Compounds* 46, 310-313.
- Vetter, W., Garson, J. J., Fahey, S. J., Cameron, G. M., Gaus, C. & Müller, J. F. 2001. 'Anthropogenic and Natural Organohalogen Compounds in Blubber of Dolphins and Dugongs (*Dugong dugon*) from Northeastern Australia'. *Archives of Environmental Contamination and Toxicology*. 41(2), 221-231
- Webb, R. O. 1998. *Cultured Aquatic Animals. Preparation for Veterinary Laboratory Examination* (Second Edition). Queensland Department of Primary Industries, Oonoonba Veterinary Laboratory, Townsville, Queensland, Australia.

ATTACHMENTS

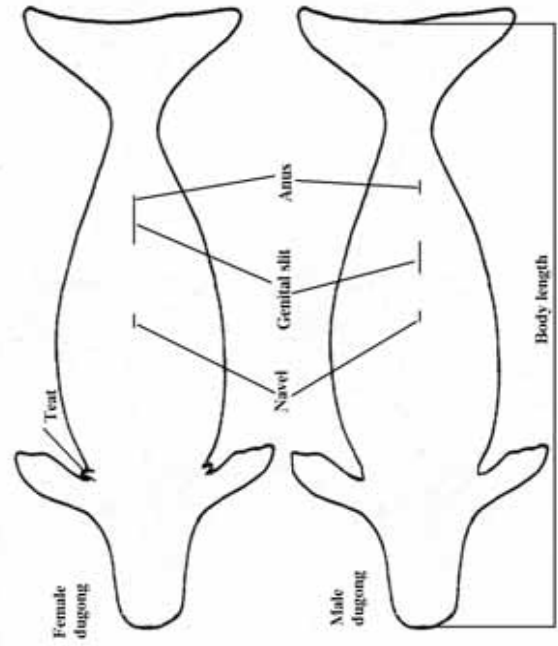
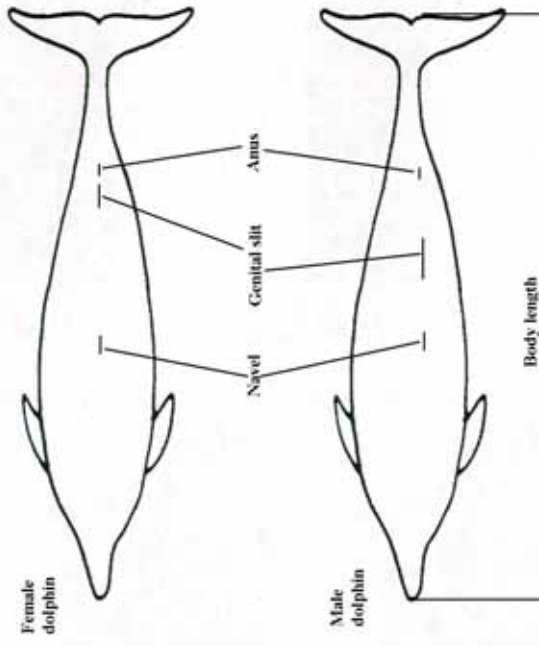
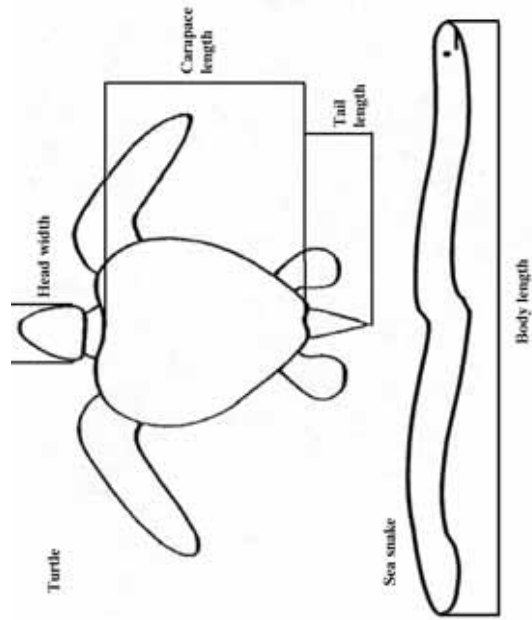
Reporting of marine reptile, bird and mammal mortality in Queensland

Instructions for completing the datasheet

- A. Date: records as day/month/year
- B. Identify the species using the identification keys.
- C. Where possible, identify sex (See key for mammals) and maturity
- D. Record any tag number. Tags may be attached to the rear edge of either front flipper of turtles.
- E. Location: be precise but use more than one line if necessary, e.g. Stradbroke Island 5km south of Pt Lookout. If a precise locality cannot be described either supply a map showing site or give latitude and longitude.
- F. Record the health/condition of the animal: dead or alive, e.g. swims in circles, continues to strand, rotting carcass, dry bones etc. Additional data will guide further action.
- G. Notes can cover topics such as damage, cause of death etc. Be as brief or as full as considered necessary.
- H. Record where animals are sent, whether carcasses are buried etc.
- I. Measurements:

Turtles – three measurements (cm) only are required which permit assessment of sex and maturity (see diagram). One measurement only required for other species (See diagrams).

- *Carapace length*: measured along the midline with a flexible tape from the skin/shell junction at the front, to the rear edge of the carapace.
- *Tail length*: measured as the distance the tail extends beyond the carapace (+ve) or is short of the rear carapace edge (-ve)
- *Head width*: measured with a straight rule at the maximum width behind the eyes.



S A M P L E

ATTACHMENT 2. Dugong Stranding and Necropsy Datasheet

Specimen No.

Specimen No (QPWS Tag #)..... Collectors of Carcass

Stranding Location (incl. latitude and longitude -GPS fix).....

Date of Examination Location..... Time

Vetrinarian..... Registering Officer in Charge.....

Additional Examiners Present.....

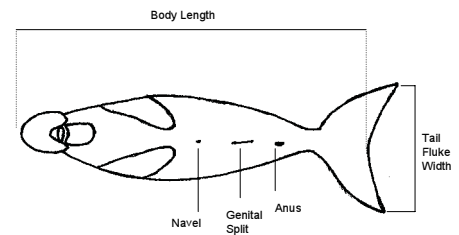
Est. time since death Sex: Male/Female Tusks present: YES/NO

PRELIMINARY DIAGNOSIS (Notes on the Cause of Death):

EXTERNAL EXAMINATION (comments on skin, eyes, nostrils, flippers, tail flukes, general physical condition , injuries, attached ropes, nets etc. – **draw any injuries and/or scars on Markings Datasheet**)

CARCASS CONDITION: (circle one)

- Alive Dead:
- 1: Live but subsequently died
 - 2: Carcass in good condition (fresh/edible)
 - 3: Carcass fair (decomposed but organs intact, bloated)
 - 4: Carcass poor (advanced decomposition, bloated)
 - 5: Mummified carcass (skin holding bones)
 - 6: Disarticulated bones (no soft tissue remaining)



MEASUREMENTS:

Take directly along body surface except for body length. For body length measure along a straight line i.e., along beach not along animal.

Body Length (Distance along the axis of the body from the anterior top of the snout to the apex of the median notch in the tail fluke m	Collect milk if expressible from nipple and freeze Is female lactating? (cut mammary gland and preserve as instructed) YES/NO
Tail Fluke Width (maximum posterior - tip to tip).....cm	Foetus Present? YES/NO
Genital Opening to Anus Distance (Distance between the centres of the genital and anal openings to tip of teat)	Length of Foetus (measure as for body length) Sex of Foetus
Teat Lengths (Perpendicular lengths of both teats from thorax – point to point) Left..... cm Right.....cm	Approx. age of animal

IF FOETUS PRESENT FILL IN SEPARATE SHEET (ASSIGN OWN NUMBER). TAKE BODY LENGTH, SEX. PRESERVE FOETUS IF LESS THAN 15 CM LONG.

SAMPLE

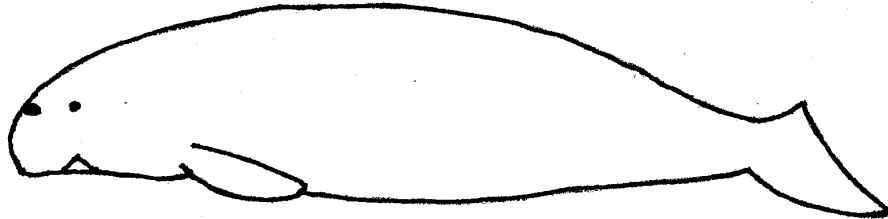
Specimen No.

Dugong External Examination: Markings Datasheet


Sketch all visible markings (i.e., scars, injuries, tusk marks etc.) on the silhouettes provided. Supplement drawings with photographs whenever possible.

- Note the condition of any scars (i.e.,: **Fresh** (open), **Recent**, but healing, **Healing** (white), **Healed**).
- If appropriate, take measurements of any markings/scars and mark on the silhouettes (i.e., Length of marking, Width, Depth at deepest point, Distances between any scars).


Left




Right



Ventral



Dorsal



SAMPLE

Specimen No.

INTERNAL EXAMINATION

Specimen No. (QPWS Tag #)..... Date of Necropsy..... Time

- **Include notes on any additional samples taken in addition to those on the Sample Checklist Form (e.g., swabs, sterile tissue sample).**
- **Tick any photos taken.**

ABDOMINAL

__ Photo taken

.....
STOMACH

__ Photo taken

.....
DUODENUM

__ Photo taken

.....
JEJUNUM & ILEUM

__ Photo taken

.....
CAECUM

__ Photo taken

.....
COLON

__ Photo taken

LIVER

__ Photo taken

.....
GALL BLADDER

__ Photo taken

REPRODUCTIVE TRACT

__ Photo taken

SAMPLE

Specimen No.

KIDNEYS

__ Photo taken

.....
URINARY BLADDER

__ Photo taken

HEART

__ Photo taken

RESPIRATORY SYSTEM

__ Photo taken

.....
LUNGS

__ Photo taken

HEAD AND NECK REGIONS (AND BRAIN)

__ Photo taken

SKELETON

__ Photo taken

OTHER

DIAGNOSIS

CAUSE OF DEATH

By (sign and print name):

SAMPLE

Specimen No.

EVALUATION OF HUMAN INTERACTION

Specimen No. (QPWS Tag #)..... Date of Necropsy..... Time

Preliminary Assessment

Human Interaction is (tick one): ___ possible
 ___ fairly certain
 ___ certain

Take photographs, histological samples and measurements of any suspect markings both within and between if multiple marks exist. Record markings and measurements on silhouettes on back of this sheet.

Y = Yes, N = No, CBD = Could not be determined, NE = Not examined

External Examination

1. **Net or Line Marks:** Indicate Y / N / CBD / NE for each area and carefully describe marks.

Head ___ L. Flipper ___ R. Flipper ___ Peduncle ___ Other ___

Photos taken?

2. **Fishing Gear or other debris present on animal** (nets, ropes, lines, wire). Carefully describe:

Photos taken?

3. **Gear Retained:** YES/NO Describe:

4. **Penetrating Wounds:** Y / N / CBD / NE Photos taken?

5. **Mutilations:** Body slit or otherwise mutilated? Y / N / CBD / NE. Describe:

6. **Evidence of Hemorrhaging/Bruising:** Y / N / CBD / NE. Describe extent and area:

Internal Examination

1. **Sub-Dermal Hemorrhaging:** Y / N / CBD / NE. Describe extent and area: Photos taken?

2. **Broken Bones:** Y / N / CBD / NE. Describe: Photos taken?

3. **Lungs and Bronchi contents:** AIR / FLUID / FROTH / CBD / NE.
Describe appearance of lungs (heavy, consolidated, etc.) and contents of respiratory tract:

SAMPLE

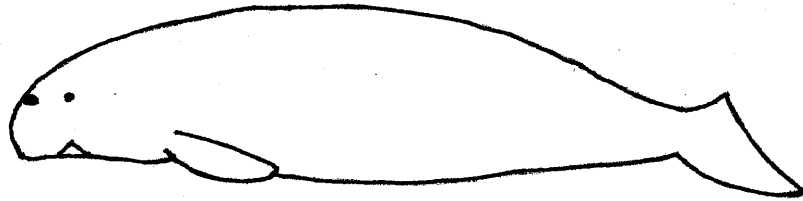
Specimen No.

4. **Histopathology Samples Retained:** YES / NO. List all samples taken.


*CBD = Can not be determined

*NE = Not Examined


Left View




Right View



Ventral View



Dorsal View



DUGONG NECROPSY SAMPLES

DATE: _____

Specimen ID# _____

Samples	Sample Size	Sample Taken for	Formalin	Chilled	Frozen	Bouins	Sample Taken Yes/No	To be sent to: (insert name & address)	Date Sent	Who Sent Samples
Skin & blubber/fat	2cm x 2cm	histopathology	X							
Skin	finger nail size	genetics			X*					
Blubber/Fat	300g	heavy metal / toxicology			X					
Muscle	2cm x 2cm	histopathology	X							
Muscle	300g	heavy metal / toxicology			X					
Gastrointestinal Tract (six samples, see below)										
Stomach	2cm x 2cm	histopathology	X							
5 other sections equally spaced b/w stomach & anus	2cm x 2cm	histopathology	X							
Stomach contents	handful	histopathology		X						
Faeces	handful	histopathology		X						
Liver	2cm x 2cm	histopathology	X							
Liver	300g	heavy metal / toxicology			X					
Heart	2cm x 2cm	histopathology	X							
Blood	15ml	Biochemical analysis		X						
Kidney	2cm x 2cm	histopathology	X							
Kidney	300g	heavy metal / toxicology			X					
Lung	2cm x 2cm	histopathology	X							
Milk	as much as possible	histopathology			X					
Milk	as much as possible	heavy metal / toxicology			X					
Whole brain (or section)	2cm x 2cm	histopathology	X							
Eyes	one or both	histopathology	X							
Teeth (& tusks)		age determination		X						
Reproductive Organs (Testes or ovary)	2cm x 2cm	histopathology				X				
Skull		morphology			X					

*could also be preserved in DMSO

Additional Comments _____

SAMPLE

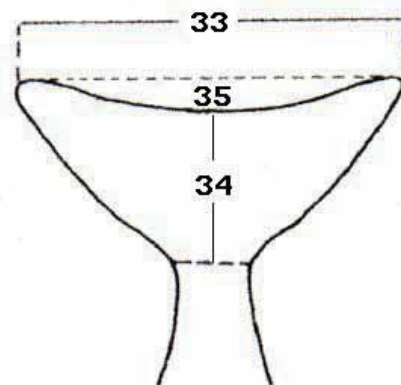
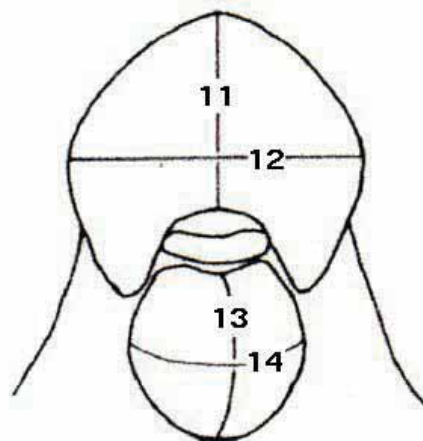
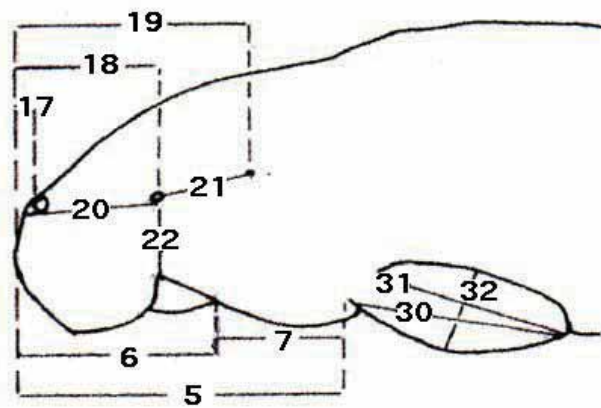
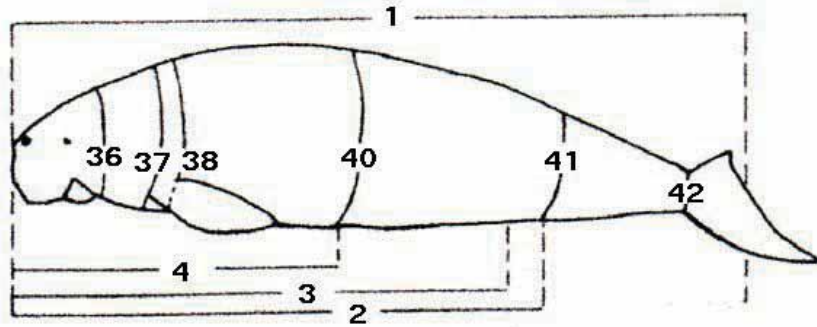
ATTACHMENT 3. Dugong Morphometrics

Standardised measurements from Heinsohn 1981 with diagrammatic instructions

No	Measurements	Left or Single	Right	Unit
1	Total body length			
2	Snout to centre of anal opening			
3	Snout to centre of genital opening			
4	Snout to centre of umbilicus			
5	Head plus neck length			
6	Head length			
7	Neck length			
8	Genital opening length			
9	Anal opening length			
10	Teat length: from thorax to teat			
11	Snout length			
12	Snout width			
13	Chin length			
14	Chin width			
15	Distance separating centres of tusks			
16	Tusks length (from gum to tip)			
17	Snout to nostrils			
18	Snout to eyes			
19	Snout to external auditory meatus			
20	Eye to nostril			
21	Eye to external auditory meatus			
22	Eye to gape			
23	Gape length			
24	Eye height			
25	Eye length			
26	Nostril height			
27	Nostril width			
28	Total nostril width			
29	External auditory meatus diameter			
30	Anterior flipper length			
31	Posterior flipper length			
32	Flipper width			
33	Fluke width			
34	Fluke length			
35	Fluke notch depth			
36	Anterior neck girth			
37	Posterior neck girth			
38	Axillary girth			
39	Maximum girth			
40	Umbilicus girth			
41	Anal girth			
42	Tail stock girth			
43	Dorsal skin thickness			
44	Lateral skin thickness			
45	Ventral skin thickness			
46	Total body weight			

SAMPLE

Dugong Morphometrics (con't)



SAMPLE

ATTACHMENT 4. Incident Report

GBRMPA INCIDENT REPORT



This form is to help you report suspected breaches of legislation applicable to the Great Barrier Reef Marine Park. These breaches could have been either identified or witnessed by you or reported by a member of the public. **If you witness a suspected breach of the law you are advised NOT to approach any suspected persons and you should NOT request information from them.** Please forward the completed form and associated documentation (if any) to the DDM Compliance Group (details on back of form).

Report Date	<input type="text"/>	Reference	<input type="text"/>
		Case Officer	<input type="text"/>

Incident details

Record additional information overleaf, attach additional sheets if necessary

Please describe details of the incident overleaf (attach additional sheets if necessary)

Incident Date	<input type="text"/>	Time: between	<input type="text"/>	am/pm	and	<input type="text"/>	am/pm
Location of incident	<input type="text"/>						
QPWS District	<input type="text"/>	Lat. ¹	<input type="text"/>	Long.	<input type="text"/>		
GBRMP Section	<input type="text"/>	Datum	<input type="text"/>				

Informant details (Reporting Officer recorded overleaf)

Record additional information overleaf, attach additional sheets if necessary

Last Name	<input type="text"/>	Phone	() <input type="text"/>	Mobile	<input type="text"/>
Other Names	<input type="text"/>	E-mail	<input type="text"/>		
Address	<input type="text"/>				
	<input type="text"/>				
City	<input type="text"/>	PCode	<input type="text"/>	Confidential?	<input type="checkbox"/>

Offence details (if known)

Legislation	<input type="text"/>	Section	<input type="text"/>
Managing Agency	<input type="text"/>		
QPWS District	<input type="text"/>	Region	<input type="text"/>
Case Type	<input type="text"/>		

Offender details

Record additional offenders/information overleaf, attach additional sheets if necessary

Business Name	<input type="text"/>				
Last Name	<input type="text"/>	Phone	() <input type="text"/>	Mobile	<input type="text"/>
Other Names	<input type="text"/>	E-mail	<input type="text"/>		
Address	<input type="text"/>		Occupation	<input type="text"/>	
	<input type="text"/>				
City	<input type="text"/>	PCode	<input type="text"/>		
Additional Information	<input type="text"/>				
	<input type="text"/>				

Vehicle details

Record details of additional vehicles/information overleaf, attach additional sheets if necessary

Vessel/Vehicle type	<input type="text"/>	Name	<input type="text"/>		
Make / model	<input type="text"/>	Rego no.	<input type="text"/>	Colour	<input type="text"/>
Additional Information	<input type="text"/>				
	<input type="text"/>				

S A M P L E

ATTACHMENT 5. Compliance Report

Compliance report

CR No.

Date	Region	District	Program	Office/establishment		
Time and date reported (by informant)			How reported (by phone-in person etc)			
At hours on / /						
I N F O R M A N T	Informant: Surname		Given name/s		Occupation	
	Address				Agency/Category (QBFP-Com Op etc)	
				Phone contact (incl. mobiles etc)		
I N C I D E N T D E T A I L S	Time and date of incident					
	At approx. hours on / / OR Between / / and / /					
	Location of incident (in full)					
	Incident (short title)			Statute	Section	
	Conservation Plan/Zoning Plan/Plan of Management (if applicable)			Protected area details *		
	GBRMP Section		State marine park		Property Seized	
Map reference or GPS		Marine park zone	Gazetteer no.	Seizure notice served (attach photocopy) Y <input type="checkbox"/> N <input type="checkbox"/>	Seizure notice no.	
W I L D L I F E	Class		Number	Scientific name		
	Common name		Implant no.		DNA sample Yes <input type="checkbox"/> No <input type="checkbox"/>	
	Tag/ring no.		Conservation value/Rehabilitation costs * \$			
A L L E G E D O F F E N D E R	Family/Business/Company name			Given name/s		
	Address			Other names including nickname/alias		
	Date of birth	Place of birth	Occupation	User group	Phone contact	
	Sex F <input type="checkbox"/> M <input type="checkbox"/>	Age	Height	Build	Complexion	Eyes
	Clothing		Extraction	Noticeable scars/tattoos/peculiarities		
	Identification details		Licence/Permit type)	Number	Issued by	Expiry date / /
V E H I C L E E T C	Vehicle	Registration no.	Expiry date / /	State	Year	Make/model
	Colour	Type of vehicle/vessel/aircraft		Size	Trim	Symbols
	User type	Vessel name		Other features		
For juveniles: Provide parent/guardian/next of kin details				Relationship	Phone contact	
Surname		Given name/s		Address		

* Note : Where space provided is insufficient attach separate schedule

S A M P L E

ATTACHMENT 6. Strandings and Carcasses: Record of Costs and Decisions

Incident Controller: _____
 Date/Time of Report: _____ Species: _____ Location: _____
 How was report received? Hotline () Phone to QPWS () Agency () Other ()

Record of Costs

NB Refer to tables of staff and boat costs/hour based on Marine Park business plan figures

Staff (name/level/agency)	Time	Overtime	Costs/hr normal	Costs/hr overtime	Total \$

Boat and aircraft used (boat name)	Time	Costs/hour	Total \$

Vehicles (type)	Km	Costs/km	Total \$

Vet fees	\$
Materials	\$
Photographic	\$
Freight/postage	\$
Other costs	\$

Total cost of incident	\$
------------------------	----

Search

Was search undertaken? Yes () No () Date/Time of search _____
 Decision based on: (eg reliability and age of report, location, safety issues, weather, availability
 of people/equipment) _____

Legal/Enforcement

Was it an enforcement issue? Yes () No ()
 Was enforcement advice obtained - on-site? () by phone? () Name/s _____
 What was advice? _____

What course of action was taken? _____

Decision based on: (eg advice, safety, weather, location) _____

SAMPLE

Dead Carcass Retrieval

Was carcass retrieved? Yes () No () Date & time of decision: _____

Decision based on: (eg location, logistics required and available, safety issues, conditions of carcass)

Necropsy/Post mortem

QPWS officer in charge of post mortem: _____ Date/time: _____

Who conducted post mortem? Veterinarian () Qualified staff () Biologist ()

Name/s: _____ Location: _____

Decision based on: (eg availability of suitable vet, time) _____

Were sampling varieties varied? Yes () No () Why? _____

Notification/media

Were media or agency staff notified beyond list server? Yes () No ()

If yes, decision based on: _____

Disposal

Where was carcass disposed of? _____

Decision based on: _____

Can it be subsequently retrieved? Yes () No ()

Signature: _____ Date: _____