


Iron Oxide Nanoparticles as MRI Contrast Agents in CNS Imaging; perfusion assessment of brain tumor therapy using ferumoxytol

Thesis of doctoral (Ph.D.) dissertation

Csanád Várallyay M.D.

Semmelweis University
School of Doctoral Studies, Clinical Medicine



Supervisor: Prof. Kálmán Hüttl M.D., Ph.D.

Official Reviewers: Tibor Kovács M.D., Ph.D.
János Martos M.D., Ph.D.

Head of the Final Examination Committee:
Prof. Judit Fidy M.D., Ph.D., D.Sc.

Members of the Final Examination Committee:
Prof. Imre Szirmai M.D., Ph.D., D.Sc.
Péter Barsi M.D., Ph.D.

Budapest
2012

List of abbreviations:

BEV: animals, treated with bevacizumab (45mg/kg)
CNS: central nervous system
CTR: control group, animals receiving saline only
DEX 12: animals treated with dexamethasone (12mg/kg/day)
DEX 2: animals treated with dexamethasone (2mg/kg/day)
DSC: dynamic susceptibility contrast
GBCA: gadolinium based contrast agent
GBM: glioblastoma
IF: impact factor
MR(I): magnetic resonance (imaging)
MRA: magnetic resonance angiography
PWI: perfusion weighted imaging
rCBV: relative cerebral blood volume
rMTT: relative mean transit time
ROI: region of interest
T: tesla
T1w: T1-weighted
TOF: time of flight
TTP: time to peak
USPIO: ultrasmall superparamagnetic iron oxide
VEGF: vascular endothelial growth factor

1 INTRODUCTION

High-grade gliomas such as glioblastoma (GBM), anaplastic astrocytoma, and anaplastic oligodendroglioma are commonly treated with radiation therapy with concomitant temozolomide chemotherapy, followed by adjuvant temozolomide. In addition, at recurrence, as a second line therapy patients may receive anti-angiogenic therapy such as bevacizumab (Avastin®), a monoclonal antibody against vascular endothelial growth factor (VEGF). Tumor response is generally determined using the Macdonald treatment response criteria, which is based on post-contrast tumor enhancement on T1-weighted (T1w) magnetic resonance (MR) images. Decreases in tumor vascular permeability and normalization of existing tumor vasculature after bevacizumab treatment can be interpreted as decreased tumor volume and apparent tumor response; however, tumor progression as non-enhancing or infiltrative disease can occur in bevacizumab-treated patients. Bevacizumab-induced pseudoresponse, also referred to as pseudoregression, makes radiographic responses challenging to interpret. Similarly, increasing tumor vascular permeability during and after radiotherapy can result in an increasing contrast enhancement, without an increase of the underlying tumor mass, this called pseudoprogression. Both pseudo-phenomena confuse the assessment of outcome of brain tumors in clinical practice and in clinical trials. To overcome these issues, alternative endpoints and response criteria are needed.

My PhD thesis deals with an MR contrast agent, an ultrasmall superparamagnetic iron oxide (USPIO) compound, called ferumoxytol and its application in high grade primary malignant brain tumors. The ultimate goal of these research projects is a “better” detection of brain malignancies, including improved specificity and sensitivity, and the evaluation of early therapeutic changes, overcoming the above mentioned issues with therapy assessment, and thus to help find the optimal therapeutic options. Besides anatomical imaging, the main interest of my research is dynamic MR imaging, especially the dynamic susceptibility contrast (DSC) perfusion weighted imaging (PWI), by taking advantage of two important properties of ferumoxytol, such as: no substantial extravasation during the first pass, and a strong T2* shortening effect.

In this writing two studies, one clinical and one preclinical, will be detailed in this unusual order. The clinical part is mainly concentrating on anatomical imaging, whereas the preclinical part uses more advanced imaging techniques, and aims to detect early therapeutic changes during antiangiogenic therapy. Therefore the clinical part will be discussed first.

2 OBJECTIVES

2.1 Clinical studies:

Ferumxylol has not been used before as an imaging agent in the central nervous system (CNS) in patients. The clinical objective of my work was to investigate the potential for this USPIO as an MR contrast agent in CNS malignancies:

1. Evaluation of enhancement time course in patients, and comparison with standard gadolinium based contrast agent (GBCA) enhancement on T1w scans.
2. Assessing the utility of ferumoxylol in various MR imaging techniques, including time of flight (TOF) MR angiography (MRA) and PWI, using the DSC technique.
3. Comparison of MR imaging using ferumoxylol at various magnetic field strengths.

2.2 Preclinical studies:

The preclinical studies were carried out on a 12 tesla experimental MR system with the following objectives:

4. To develop a study protocol, including an intracranial tumor model in rats, and serial dynamic MR imaging on 12T using a standardized bolus injection of ferumoxylol and GBCA.
5. Comparison of DSC imaging using ferumoxylol vs. GBCA.
6. Detection of early therapeutic changes of the antiangiogenic drug, bevacizumab, using a dual agent MR imaging method (ferumoxylol for perfusion assessment and GBCA for permeability estimation)

3 METHODS

3.1 Clinical studies

Twelve patients with malignant brain tumors underwent serial magnetic resonance imaging multiple times up to 72 hours after ferumoxytol injection at both 1.5 and 3T. The enhancement time course of this long circulating agent (plasma half life 14-21h) was determined at each magnetic field strength. Ferumoxytol enhancement was also compared with a baseline GBCA enhanced scan. Perfusion parametric maps, TOF MRA and quantitative T1-measurement were compared for the two agents. Region of interest (ROI) based analysis was performed for relative cerebral blood volume (rCBV), relative mean transit time (rMTT) and changes in T1 values in the enhancing tumor and in the surrounding area.

3.2 Preclinical Studies

Athymic rats with intracerebral U87 human glioma were used to test dynamic MR imaging at 12T. To compare ferumoxytol and gadodiamide in DSC imaging, two animals underwent DSC imaging with gadodiamide and one day later with ferumoxytol. In the tumoral ROI Time-Intensity curves were analyzed and rCBV was estimated and compared between the two agents. In the second half of the study we used serial dynamic contrast-enhanced MRI to assess early vascular responses to antiangiogenic versus steroid therapy. Tumor bearing rats (n=17) underwent DSC perfusion MRI with ferumoxytol, followed by T1w dynamic contrast enhanced (DCE) MRI using gadodiamide to measure vascular permeability. Rats were

imaged before and after 24, 48, and 72h of treatment with the antiangiogenic agent bevacizumab, the corticosteroid dexamethasone (in two different doses) or saline as controls, thus resulting four treatment groups. Treatment groups: BEV: bevacizumab (45mg/kg) n=5; DEX-2: dexamethasone (2mg/kg per day) n=4, DEX-12: dexamethasone (12mg/kg per day) n=5; and CTR: control n=3. rCBV values of the tumors were calculated using the DSC perfusion series on a ROI basis. DCE scans were processed by defining the time to peak (TTP) enhancement in the tumor. Changes in rCBV and TTP enhancement were statistically analyzed throughout the study using repeated measurements of two-way analysis of variance with Tukey's post hoc statistical test. $P < 0.05$ was considered significant.

4 RESULTS AND DISCUSSION

4.1 Clinical Studies

Using ferumoxytol, contrast enhancement was detectable in all the studied patients at all magnetic field strengths, even with a low field intraoperative 0.15-T magnet. Maximal ferumoxytol enhancement intensity was detected at 24 to 28 hours after administration, and the enhancing volume subsequently expanded with time into a non-gadolinium-enhancing, surrounding T2-hyperintense region. The enhancement appeared to be more intense at 1.5T than on 3T. In most cases ferumoxytol enhancement was less intense than GBCA enhancement. Differences in enhancement patterns of ferumoxytol vs. GBCA agents could be also explained with slightly different mechanism of extravasation, and also the uptake of ferumoxytol by inflammatory cells within and around the tumor mass may play an important role. DSC studies were assessed with both agents. In tumors with high vascular permeability, the early vascular leakage of GBCA overestimated the rCBV. This was only found with gadolinium but not with ferumoxytol. Nevertheless there was no significant difference in rCBV or rMTT values between the two agents when comparing in the entire study population. TOF MRA post contrast administration depicted more blood vessels with either contrast agents, without visible extravasation when ferumoxytol was used. T1 values in GBCA enhancing tumor regions did not show significant changes post ferumoxytol injection confirming that ferumoxytol stays intravascular early after contrast agent administration. These results confirmed that ferumoxytol stays

intravascular in the early phase, which could be exploited to assess the micro and macro vasculature.

4.2 Preclinical Studies

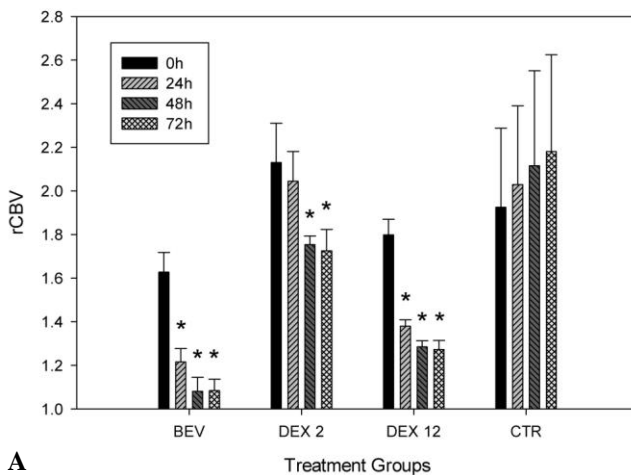
The U87 tumor model was found to be a suitable intracranial model to test DSC perfusion measurement. Contrast agent extravasation was seen rapidly after gadodiamide resulting a substantial underestimation of rCBV in this tumor model. This was not found with ferumoxytol. The dual agent imaging method could be successfully applied with only a minimal confounding effect, alone the arterial input function could not be measured due to high concentration intravascular iron oxide particles. The ferumoxytol bolus was suitable for rCBV measurement, followed by gadodiamide injection, in which the dynamics of parenchymal enhancement could be used to test the vascular permeability expressed as TTP enhancement.

Evaluating early therapeutic response, both of these measures showed significant early changes (Figure 1): In the BEV group, the initial rCBV (1.628 ± 0.091) (means \pm s.e.m.) decreased significantly in all 24, 48, and 72h time points to 1.214 ± 0.061 , 1.082 ± 0.064 , and 1.084 ± 0.052 , respectively (Figure 1A). In the DEX 2 group, the initial rCBV of 2.130 ± 0.180 showed significant decrease in the 48 and 72 h time points (1.755 ± 0.040 and 1.725 ± 0.098 , respectively). In the DEX 12 group, the initial 1.800 ± 0.072 rCBV value decreased significantly at all time points, to 1.380 ± 0.029 at 24 h, 1.286 ± 0.028 at 48 h, and 1.272 ± 0.041 at 72 h. In the CTR group, there was no significant change found from the initial 1.927 ± 0.363 rCBV value.

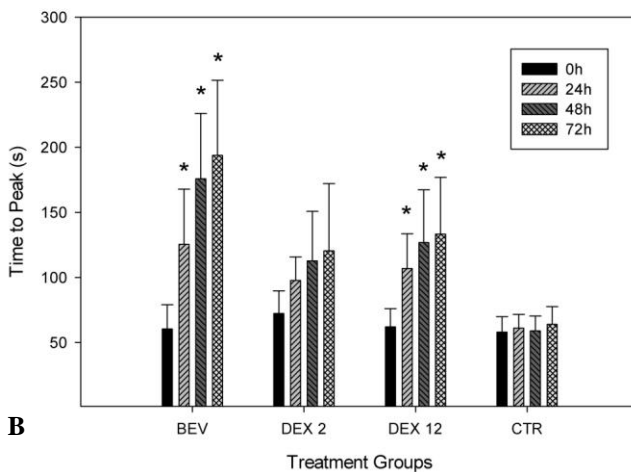
Comparing the treatment groups the normalized rCBV in BEV and DEX 12 groups appeared to be significantly decreased compared with the CTR and DEX 2 groups in all the three post treatment time points. The difference between the BEV and DEX 12 groups was not significant. The DEX 2 group became significantly different from the CTR group at the 48 and 72 h time points.

Changes in vascular permeability were following (Figure 1B): In the BEV group, the initial TTP of 60 ± 19 s increased significantly in all 24, 48, and 72 h post treatment time points to 125 ± 42 s, 176 ± 50 s, and 194 ± 58 s, respectively). Similarly, in the DEX 12 group, the initial 62 ± 14 secs increased to 107 ± 27 s, 127 ± 41 s, and 133 ± 44 s, respectively. The baseline TTP of 72 ± 17 s in the DEX 2 group and the 58 ± 12 s in the control group has not shown significant changes throughout the study.

After normalizing the TTP data to the pretreatment value in each treatment group, there was no significant difference between the groups 24 h after the start of treatment. At the 48 h time point in the BEV treatment group, the TTP increased significantly to 3.023 ± 0.58 compared with the CTR (1.071 ± 0.05) and also compared with the DEX 2 TTP (1.517 ± 0.25), but it was not significantly different from DEX 12 (1.907 ± 0.16 , $P = 0.051$). At 72 h post-treatment time point, the normalized TTP in the BEV group increased to 3.313 ± 0.59 , and was found to be significantly higher than that in all the three other groups (CTR: 1.110 ± 0.06 , DEX 2: 1.581 ± 0.37 , and DEX 12: 2.064 ± 0.34). There were no other significant differences between groups.



A



B

Figure 1 Early rCBV (A) and TTP (B) changes after treatment.

* indicates significance ($p < 0.05$)

5 CONCLUSIONS

Ferumoxytol, a bolus injectable USPIO may serve as a complimentary MR contrast agent to improve localization, characterization, and follow-up in CNS malignancies. Using DSC perfusion, it will be invaluable in the future for monitoring therapeutic responses to antiangiogenic chemotherapies. Ferumoxytol, in particular, is an exciting and powerful tool that is approved by the United States Food and Drug Administration and can be used to study a variety of CNS pathologies. We conclude that dynamic perfusion MRI measurement with ferumoxytol USPIO to assess cerebral blood volume, along with dynamic gadodiamide-enhanced MR to assess vascular permeability in the same imaging session is feasible, and holds promise in more accurately detecting therapeutic responses to antiangiogenic therapy. In our preclinical study a dramatic rCBV and permeability decrease was observed as early as 24h post treatment. These findings were similar, but more pronounced compared to high doses of corticosteroids.

This work is a step forward in tumor treatment response assessment using advanced dynamic MR imaging techniques, which may complement the currently used, mainly contrast enhancement based response criteria. These results may help solving diagnostic problems of pseudoresponse and pseudoprogression, which is one of our most relevant future directions.

6 NEW SCIENTIFIC RESULTS

6.1 Clinical studies

1. Ferumoxytol can be used as an MR contrast agent in CNS malignancies. Enhancement intensity peaks around 24 hours after intravenous administration. In most cases enhancement on T1w scans is somewhat less intense than at GBCA.
2. In early time points ferumoxytol remains intravascular, and the vasculature can be depicted by TOF MRA, without confounding effect of contrast extravasation. The bolus injectable ferumoxytol is suitable for DSC perfusion measurement.
3. Unlike GBCA, ferumoxytol enhancement on T1w scans shows a higher intensity at lower magnetic field strength.

6.2 Preclinical studies

4. Dual agent imaging with ferumoxytol followed by GBCA can be beneficial to evaluate the contrast agent leakage and also the rCBV with minimal confounding effect in the same imaging session.
5. The U87 tumor model is highly permeable for GBCA, but not for ferumoxytol. Using USPIO, the misinterpretation of rCBV derived from contrast agent extravasation can be prevented.
6. Bevacizumab treatment causes a rapid decrease in both tumor rCBV and also blood brain barrier permeability. This effect is similar to a high dose corticosteroid treatment.

7 Publications related to the thesis

1. Neuwelt EA, Varallyay CG, Manninger S, Solymosi D, Haluska M, Hunt MA, Nesbit G, Stevens A, Jerosch-Herold M, Jacobs PM, Hoffman JM. The potential of ferumoxytol nanoparticle magnetic resonance imaging, perfusion, and angiography in central nervous system malignancy: a pilot study. *Neurosurgery* **60**:(4) pp. 601-611. (2007) IF: 3.007
2. Varallyay CG, Muldoon LL, Gahramanov S, Wu YJ, Goodman JA, Li X, Pike MM, Neuwelt EA. Dynamic MRI using iron oxide nanoparticles to assess early vascular effects of antiangiogenic versus corticosteroid treatment in a glioma model. *J Cereb Blood Flow Metab* **29**:(4) pp. 853-860. (2009) IF: 5.457
3. Weinstein JS, Varallyay CG, Dosa E, Gahramanov S, Hamilton B, Rooney WD, Muldoon LL, Neuwelt EA. Superparamagnetic iron oxide nanoparticles: diagnostic magnetic resonance imaging and potential therapeutic applications in neurooncology and central nervous system inflammatory pathologies, a review. *J Cereb Blood Flow Metab* **30**:(1) pp. 15-35. (2010) IF: 4.522
4. Neuwelt EA, Hamilton BE, Varallyay CG, Rooney WR, Edelman RD, Jacobs PM, Watnick SG. Ultrasmall superparamagnetic iron oxides (USPIOs): a future alternative magnetic resonance (MR) contrast agent for patients at risk for nephrogenic systemic fibrosis (NSF)? *Kidney Int* **75**:(5) pp. 465-474. (2009) IF: 6.193
5. Gahramanov S, Raslan AM, Muldoon LL, Hamilton BE, Rooney WD, Varallyay CG, Njus JM, Haluska M, Neuwelt EA. Potential for differentiation of pseudoprogression from true tumor progression with dynamic susceptibility-weighted contrast-enhanced magnetic resonance imaging using ferumoxytol vs. gadoteridol: a pilot study. *Int J Radiat Oncol Biol Phys* **79**:(2) pp. 514-523. (2011) IF: 4.503*

8 Further Scientific Publications

1. Doolittle ND, Jahnke K, Belanger R, Ryan DA, Nance RW Jr, Lacy CA, Tyson RM, Haluska M, Hedrick NA, Varallyay C, Neuwelt EA. Potential of chemo-immunotherapy and radioimmunotherapy in relapsed primary central nervous system (CNS) lymphoma. *Leuk Lymphoma* **48**:(9) pp. 1712-1720. (2007) IF: 1.512
2. Várallyay Cs, Balázs Gy, Lénárd Zs, Bérczi V, Belics Z, Bajzik G, Wragg P, Hüttl, Kálmán, Jolesz, Ferenc A. MR imaging follow up after MR-guided focused ultrasound surgery for uterine leiomyomas.: Early and mid term results. *Interventional Medicine & Applied Science* **1**:(1) pp. 46-51. (2009)
3. Berczi V, Molnar AA, Apor A, Kovacs V, Ruzics C, Varallyay C, Huttli K, Monos E, Nadasy GL. Non-invasive assessment of human large vein diameter, capacity, distensibility and ellipticity in situ: dependence on anatomical location, age, body position and pressure. *Eur J Appl Physiol* **95**:(4) pp. 283-289. (2005) IF: 1.619
4. Li X, Rooney WD, Varallyay CG, Gahramanov S, Muldoon LL, Goodman JA, Tagge IJ, Selzer AH, Pike MM, Neuwelt EA, Springer CS Jr. Dynamic-contrast-enhanced-MRI with extravasating contrast reagent: rat cerebral glioma blood volume determination. *J Magn Reson* **206**:(2) pp. 190-199. (2010) IF: 2.333
5. Wu YJ, Muldoon LL, Varallyay C, Markwardt S, Jones RE, Neuwelt EA. In vivo leukocyte labeling with intravenous ferumoxides/protamine sulfate complex and in vitro characterization for cellular magnetic resonance imaging. *Am J Physiol Cell Physiol* **293**:(5) pp. C1698-C1708. (2007) IF: 4.230

6. Jahnke K, Muldoon LL, Varallyay CG, Lewin SJ, Brown RD, Kraemer DF, Soussain C, Neuwelt EA. Efficacy and MRI of rituximab and methotrexate treatment in a nude rat model of CNS lymphoma. *Neuro Oncol* **11**:(5) pp. 503-513. (2009) IF: 4.984
7. Jahnke K, Muldoon LL, Varallyay CG, Lewin SJ, Kraemer DF, Neuwelt EA. Bevacizumab and carboplatin increase survival and asymptomatic tumor volume in a glioma model. *Neuro Oncol* **11**:(2) pp. 142-150. (2009) IF: 4.984
8. Wu YJ, Muldoon LL, Dickey DT, Lewin SJ, Varallyay CG, Neuwelt EA. Cyclophosphamide enhances human tumor growth in nude rat xenografted tumor models. *Neoplasia* **11**:(2) pp. 187-195. (2009) IF: 5.025
9. Soussain C, Muldoon LL, Varallyay C, Jahnke K, DePaula L, Neuwelt EA. Characterization and magnetic resonance imaging of a rat model of human B-cell central nervous system lymphoma. *Clin Cancer Res* **13**:(8) pp. 2504-2511. (2007) IF: 6.250