



## White matter lesions in FTLD: distinct phenotypes characterize GRN and C9ORF72 mutations

Fatima Ameur, Olivier Colliot, Paola Caroppo, Sebastian Stroer, Didier Dormont, Alexis Brice, Carole Azuar, Bruno Dubois, Isabelle Le Ber, Anne Bertrand

### ► To cite this version:

Fatima Ameur, Olivier Colliot, Paola Caroppo, Sebastian Stroer, Didier Dormont, et al.. White matter lesions in FTLD: distinct phenotypes characterize GRN and C9ORF72 mutations. *Neurology Genetics*, American Academy of Neurology, 2016, 2 (1), 10.1212/NXG.0000000000000047. hal-01266596

HAL Id: hal-01266596

<https://hal.inria.fr/hal-01266596>

Submitted on 3 Feb 2016

HAL is a multi-disciplinary open access archive for the deposit and dissemination of scientific research documents, whether they are published or not. The documents may come from teaching and research institutions in France or abroad, or from public or private research centers.

L'archive ouverte pluridisciplinaire HAL, est destinée au dépôt et à la diffusion de documents scientifiques de niveau recherche, publiés ou non, émanant des établissements d'enseignement et de recherche français ou étrangers, des laboratoires publics ou privés.



Fatima Ameur, MD  
Olivier Colliot, PhD  
Paola Caroppo, MD, PhD  
Sebastian Ströer  
Didier Dormont, MD  
Alexis Brice, MD  
Carole Azuar, MD  
Bruno Dubois, MD  
Isabelle Le Ber, MD, PhD  
Anne Bertrand, MD, PhD

*Neurol Genet*  
2016;2:e47; doi: 10.1212/  
NXG.000000000000047

## WHITE MATTER LESIONS IN FTLD: DISTINCT PHENOTYPES CHARACTERIZE *GRN* AND *C9ORF72* MUTATIONS

### OPEN

Frontotemporal lobar degeneration (FTLD) has a high frequency of genetic forms; the 2 most common are *GRN* (progranulin) and *C9ORF72* mutations. Recently, our group reported extensive white matter (WM) lesions in 4 patients with FTLD caused by *GRN* mutation, in the absence of noteworthy cardiovascular risk factors,<sup>1</sup> in line with other studies in *GRN* mutation carriers.<sup>2,3</sup> Here we compared the characteristics of frontal WM lesions in patients with behavioral variant of FTLD (bv-FTLD) caused by *GRN* and *C9ORF72* mutations.

**Methods.** *Patients.* We retrospectively collected clinical and MRI data from 28 patients with a diagnosis of bv-FTLD based on the Rascovsky criteria,<sup>4</sup> including 11 *GRN* mutation carriers and 17 *C9ORF72* mutation carriers. One patient with multiple cardiovascular risk factors was excluded from this study; all other patients had no cardiovascular risk factors apart from sex, age, or treated and well-controlled hypertension. Age at onset was determined as the time of symptom appearance reported by the closest relative of the patient. A group of 11 age-matched healthy individuals were used as controls. Two *GRN* patients have been reported in a previous publication.<sup>1</sup> This retrospective study was approved by our institutional review board. Informed consent was obtained according to the French legislation for clinical genetic studies.

**MRI.** All patients had a brain MRI including fluid-attenuated inversion recovery (FLAIR) sequence (1.5T/3T, echo time >100 ms, slice thickness ≤5 mm). One neuroradiologist (F.A.) assessed the severity of left and right frontal atrophy using the Kipps-Davis scale for frontal atrophy.<sup>5</sup> Three neuroradiologists (F.A., S.S., and A. Bertrand) and 1 neurologist (P.C.) characterized the severity of WM lesions on FLAIR images in the left and right frontal lobes using an ad hoc 3-level visual score (figure). All readers were blinded to clinical and genetic data.

Statistical analysis was performed using GraphPad Prism 5.0 (San Diego, CA). Interrater agreements were assessed using the weighted  $\kappa$  test. Comparisons

of sex and symptoms between the 3 groups were assessed using the  $\chi^2$  test; other comparisons were assessed using the Kruskal-Wallis test and Dunn post hoc test (when comparing 3 groups) or the Mann-Whitney test (when comparing 2 groups).

**Results.** No significant difference was observed between groups regarding sex, age at onset, age at MRI, disease duration, and associated amyotrophic lateral sclerosis symptoms (table e-1 at [Neurology.org/ng](http://Neurology.org/ng)).

Interrater agreement between the 4 readers for the characterization of WM lesions was moderate to very strong ( $\kappa = 0.536$ – $0.805$ , median 0.74).

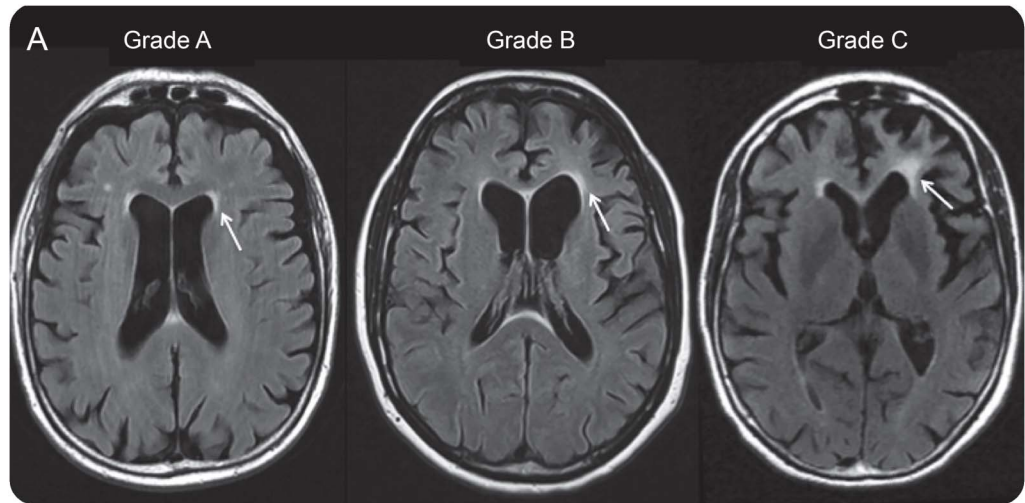
Frontal WM lesions were different between the 3 groups ( $p = 0.007$  for the right side and  $p < 0.0001$  for the left side, Kruskal-Wallis test). The grade of WM lesions was higher on both sides in the *GRN* group than in the control group and the *C9ORF72* group (Dunn post hoc test) (figure).

In *GRN* mutation carriers, the presence of grade C WM lesions on the left side was associated with a higher degree of left frontal atrophy ( $p = 0.003$ , Mann-Whitney test) but not with longer disease duration ( $p = 0.082$ , Mann-Whitney test). No significant result was observed for the right side, where WM lesions were less frequent.

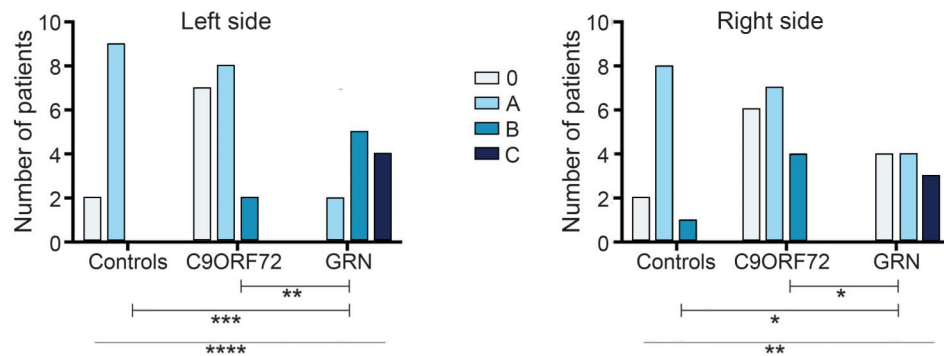
**Discussion.** Previous reports have shown that some FTLD cases with *GRN* mutation present with marked FLAIR hyperintensities in the WM.<sup>1–3,6</sup> Here we extended these findings by showing that these WM lesions are frequent: 45% (5/11) of *GRN* mutation carriers had extensive frontal WM lesions (grade C) in the absence of noteworthy cardiovascular risk factors. These WM lesions were atypical for common cerebral small vessel disease because they extended toward the subcortical WM (figure) and were associated with a higher degree of left frontal atrophy. They were not associated with longer disease duration; thus, they may be a consequence of a faster atrophy process than in the other patients. Of note, the patient excluded from the study because of cardiovascular risk factors had only grade A WM lesions in the frontal lobes.

It is interesting that both *GRN* and *C9ORF72* mutation carriers are likely to have underlying FTLD-TDP43 pathology. This suggests that gene effects can exceed lesion effects in the phenotypical expression of

Supplemental data  
at [Neurology.org/ng](http://Neurology.org/ng)



B. Grade of periventricular frontal WM lesions



(A) Grade A: minor fluid-attenuated inversion recovery (FLAIR) hyperintensities, <4 mm thick, limited to the periventricular area, no extension into the deep and subcortical white matter (WM). Grade B: moderate FLAIR hyperintensities, <6 mm thick, affecting the periventricular and deep WM, no extension into the subcortical WM. Grade C: marked FLAIR hyperintensities, >6 mm thick, affecting periventricular, deep, and subcortical WM. (B) Frontal WM lesions were significantly different between groups on the left side ( $p < 0.0001$ , Kruskal-Wallis test) and on the right side ( $p = 0.007$ , Kruskal-Wallis test). Dunn post hoc tests showed statistically significant differences between the GRN group and controls and between the GRN group and the C9ORF72 group for the left and right side.

FTLD. The progranulin protein is normally expressed not only in neurons but also in activated microglia, astrocytes, and oligodendroglia and plays a role in inflammation.<sup>7</sup> Histopathologic studies of the WM in GRN mutation carriers have reported microglial activation in the areas of abnormal WM on MRI.<sup>2</sup> These results favor the hypothesis of a specific vulnerability of the WM to granulin haploinsufficiency.

From the Service de Neuroradiologie Diagnostique et Fonctionnelle (F.A., O.C., S.S., D.D., A. Bertrand), Département de Génétique et Cytogénétique, Unité Fonctionnelle de Génétique Clinique (A. Brice), Centre de Référence des Démences Rares (C.A., B.D., I.L.B.), and Département de Neurologie (O.C., C.A., B.D., I.L.B.), AP-HP Hôpital de la Pitié-Salpêtrière, Paris, France; INSERM (O.C., P.C., D.D., A. Brice, B.D., I.L.B., A. Bertrand), ICM, Paris, France; Sorbonne Université (O.C., P.C., D.D., A. Brice, B.D., I.L.B., A. Bertrand), UPMC Univ Paris, ICM, France; CNRS (O.C., P.C., D.D., A. Brice, B.D., I.L.B., A. Bertrand), ICM, Paris, France; INRIA (O.C., D.D., A. Bertrand), Centre Paris-Rocquencourt, France; ICM (O.C., P.C., D.D., A. Brice, C.A., B.D., I.L.B., A. Bertrand), Paris, France;

Carlo Besta Institute (P.C.), Milan, Italy; and FrontLab (C.A.), INSERM, ICM, Paris, France.

Author contributions: Study concept and design: F. Ameur, A. Bertrand, O. Colliot, and I. Le Ber. Acquisition of data: F. Ameur, A. Bertrand, P. Caroppo, and I. Le Ber. Analysis and interpretation of data: F. Ameur, A. Bertrand, P. Caroppo, S. Ströer, O. Colliot, and I. Le Ber. Drafting of the manuscript: F. Ameur and A. Bertrand. Critical revision of the manuscript for important intellectual content: P. Caroppo, D. Dormont, A. Brice, I. Le Ber, O. Colliot, C. Azuar, and B. Dubois.

Study funding: This work was supported by the program "Investissements d'avenir," grant ANR-10-IAIHU-06; by the PHRC FTLD-exome, grant NCT02363062 (to I.L.B.); by the Association PSP-France (to I.L.B.); by the France Alzheimer Association, grant R12091DD (to A. Brice); by Neuromics FP7, grant E12009DD (to A. Brice); by the Roger de Spoelberch Foundation, grant R12123DD (to A. Brice); by the PHRC Predict PGRN, grant AOM08045 (to A. Brice); and by the Fondation Plan Alzheimer (to A. Brice). Dr. Paola Caroppo received a PhD Fellowship from Carlo Besta Institute, Milan, Italy.

Disclosure: Dr. Ameur reports no disclosures. Dr. Colliot has received lecture fees from Roche; has served on the editorial board of Medical Image Analysis (Elsevier); and has received research support from Agence Nationale de la Recherche and Fondation Plan Alzheimer.

Dr. Caroppo reports no disclosures. Mr. Ströer has received research support from the Société Française de Radiologie. Dr. Dormont has received travel funding from Guerbet Group France; has served on the editorial board of the American Journal of Neuroradiology; holds a patent as Co-inventor of the Neurinfarct software, which is protected by an international patent (WO 2008/000973) currently owned by Intelligence in Medical Technologies, Paris; and has been a consultant for Medtronic, France. Dr. Brice has received honoraria from Lundbeck and has received research support from “Investissements d’avenir” and the France Parkinson Association. Dr. Azuar reports no disclosures. Dr. Dubois has been a consultant for Eli Lilly and has received research support from INSERM, ANR, and PHRC. Dr. Le Ber reports no disclosures. Dr. Bertrand has received research support from IHU-a-ICM. Go to [Neurology.org/ng](http://Neurology.org/ng) for full disclosure forms. The Article Processing Charge was paid by INRIA.

This is an open access article distributed under the terms of the Creative Commons Attribution-NonCommercial-NoDerivatives License 4.0 (CC BY-NC-ND), which permits downloading and sharing the work provided it is properly cited. The work cannot be changed in any way or used commercially.

Received June 17, 2015. Accepted in final form November 19, 2015.

Correspondence to Dr. Bertrand: [anne.bertrand@aphp.fr](mailto:anne.bertrand@aphp.fr)

1. Caroppo P, Le Ber I, Camuzat A, et al. Extensive white matter involvement in patients with frontotemporal lobar

degeneration: think progranulin. *JAMA Neurol* 2014;71:1562–1566.

2. Kelley BJ, Haidar W, Boeve BF, et al. Prominent phenotypic variability associated with mutations in progranulin. *Neurobiol Aging* 2009;30:739–751.
3. Van Swieten JC, Heutink P. Mutations in progranulin (GRN) within the spectrum of clinical and pathological phenotypes of frontotemporal dementia. *Lancet Neurol* 2008;7:965–974.
4. Rascovsky K, Hodges JR, Knopman D, et al. Sensitivity of revised diagnostic criteria for the behavioural variant of frontotemporal dementia. *Brain J Neurol* 2011;134:2456–2477.
5. Kipps CM, Davies RR, Mitchell J, Kril JJ, Halliday GM, Hodges JR. Clinical significance of lobar atrophy in frontotemporal dementia: application of an MRI visual rating scale. *Dement Geriatr Cogn Disord* 2007;23:334–342.
6. Pietroboni AM, Fumagalli GG, Ghezzi L, et al. Phenotypic heterogeneity of the GRN Asp22fs mutation in a large Italian kindred. *J Alzheimers Dis* 2011;24:253–259.
7. Cenik B, Sephton CF, Kutluk Cenik B, Herz J, Yu G. Progranulin: a proteolytically processed protein at the crossroads of inflammation and neurodegeneration. *J Biol Chem* 2012;287:32298–32306.

# Neurology<sup>®</sup> Genetics

## White matter lesions in FTLN: distinct phenotypes characterize *GRN* and *C9ORF72* mutations

Fatima Aneur, Olivier Colliot, Paola Caroppo, et al.  
*Neurol Genet* 2016;2;  
DOI 10.1212/NXG.0000000000000047

This information is current as of January 28, 2016

<b>Updated Information &amp; Services</b>	including high resolution figures, can be found at: <a href="http://ng.neurology.org/content/2/1/e47.full.html">http://ng.neurology.org/content/2/1/e47.full.html</a>
<b>Supplementary Material</b>	Supplementary material can be found at: <a href="http://ng.neurology.org/content/suppl/2016/01/28/2.1.e47.DC1.html">http://ng.neurology.org/content/suppl/2016/01/28/2.1.e47.DC1.html</a>
<b>References</b>	This article cites 7 articles, 2 of which you can access for free at: <a href="http://ng.neurology.org/content/2/1/e47.full.html##ref-list-1">http://ng.neurology.org/content/2/1/e47.full.html##ref-list-1</a>
<b>Subspecialty Collections</b>	This article, along with others on similar topics, appears in the following collection(s): <b>Amyotrophic lateral sclerosis</b> <a href="http://ng.neurology.org/cgi/collection/amyotrophic_lateral_sclerosis">http://ng.neurology.org/cgi/collection/amyotrophic_lateral_sclerosis</a> <b>Frontotemporal dementia</b> <a href="http://ng.neurology.org/cgi/collection/frontotemporal_dementia">http://ng.neurology.org/cgi/collection/frontotemporal_dementia</a> <b>MRI</b> <a href="http://ng.neurology.org/cgi/collection/mri">http://ng.neurology.org/cgi/collection/mri</a>
<b>Permissions &amp; Licensing</b>	Information about reproducing this article in parts (figures, tables) or in its entirety can be found online at: <a href="http://ng.neurology.org/misc/about.xhtml#permissions">http://ng.neurology.org/misc/about.xhtml#permissions</a>
<b>Reprints</b>	Information about ordering reprints can be found online: <a href="http://ng.neurology.org/misc/addir.xhtml#reprintsus">http://ng.neurology.org/misc/addir.xhtml#reprintsus</a>

*Neurol Genet* is an official journal of the American Academy of Neurology. Published since April 2015, it is an open-access, online-only, continuous publication journal. Copyright © 2016 American Academy of Neurology. All rights reserved. Online ISSN: 2376-7839.

