

1-1-2020

Ataxia Telangiectasia- A Case Report

Pooja Pallavi
JSS AHER

Dr. Rajani H.S
JSS AHER

Follow this and additional works at: <https://rescon.jssuni.edu.in/djcm>



Part of the [Dentistry Commons](#), [Health Policy Commons](#), [Medical Education Commons](#), [Pharmacy and Pharmaceutical Sciences Commons](#), and the [Public Health Education and Promotion Commons](#)

Recommended Citation

Pallavi, Pooja and H.S, Dr. Rajani (2020) "Ataxia Telangiectasia- A Case Report," *Digital Journal of Clinical Medicine*: Vol. 2: Iss. 3, Article 8.

This Case Report is brought to you for free and open access by Research Connect. It has been accepted for inclusion in Digital Journal of Clinical Medicine by an authorized editor of Research Connect.

Ataxia Telangiectasia- A Case Report

Pooja Pallavi, Dr. Rajani.H.S , Department of Pediatrics ,JSS Medical College, JSSAHER,

Mysuru

Clinical History

18-year-old female, presented with complaints of reddish discoloration of both eyes since 12 years, Involuntary movements of hands since 11 years, Unsteady gait since 8 years, Slurring of speech since 8 years, Hair loss since 3 years,

Now brought with History of Increased frequency of micturition since 1 month

Past History-

She had h/o recurrent respiratory and skin infections in first 4 years of life. She discontinued school because of physical disability.

Menstrual History-

She attained menarche at the age of 14 years

Birth History-

Antenatal and perinatal history was normal with normal developmental milestones till 7 years of age.

Family History-

There were no similar complaints in the family.

Examination and Investigations

General:

Patient looks grossly wasted and stunted.

Height– 140cm

Weight– 34kg

BMI– 17.3

Vitals:

PR: 72bpm

BP: 110/80 Hg

RR: 14 breaths /min

SpO2: 98%

Head to Toe:

Head – Thin and sparse hairs with patchy areas of baldness.

Eyes– Telangiectasia were seen over bilateral bulbar conjunctiva (B/L congestion over bulbar conjunctiva)

Synophrys

Hyperpigmentation of skin around eyes

Acanthosis nigricans over nape of neck

Café au lait spots

Cubitus valgus

Genu valgum

Deformity on standing (Knock- Knees)

Plantar flexion of B/L feet

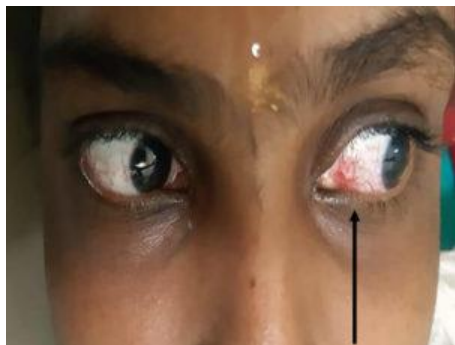Systemic Examination:

On CNS examination,

The patient was conscious oriented with hypotonia, diminished deep tendon reflexes and bilateral plantar flexor.

Cranial nerve examination was normal except for nystagmus.

Cerebellar signs like Wide-based ataxic gait, bilateral nystagmus, scanning speech, intention tremor, dysmetria, dysdiadochokinesia were seen.



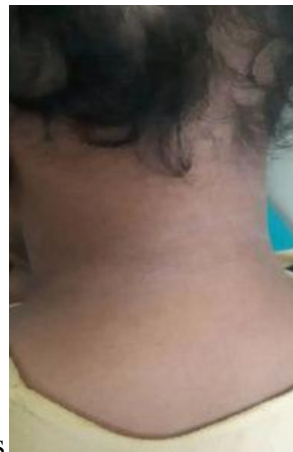
Telangiectasia



Genu



Synophrys



Acanthosis nigrans

valgum

and sparse hair



Knocked knees

Nystagmus

Unsteady gait and genu valgum

Scanning Speech

There were no signs of meningeal irritation

Spine was Normal with no kyphoscoliosis

Other systems

(CVS,RS, P/A) were unremarkable.

HbA1c– 12.6

RBS was 382 mg /dl

C peptide level was Low with 3.96ng/ml

MRI Scan

Brain– Mild cerebellar atrophy

Alpha Fetoprotein was grossly elevated with 166ng/ml

IgA level was normal with 134 .g/dl

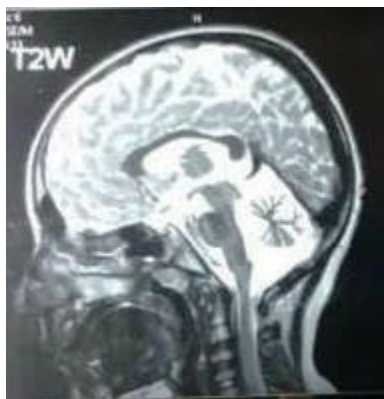IgE level was low with 7.45 IU/ml

Brain Stem Evoked Response Audiometry (BERA) showed

Sensorineural hearing loss on right side

Rest of the tests came out to be normal.

Molecular testing and cytogenetic assays could not be done.



MRI showing

mild cerebellar

atrophy

PROCEDURE: Brainstem auditory evoked response was performed on both the sides using rarefaction clicks. A total of 1000 signals were averaged at each intensity of stimulation namely at 90 dB, 50 dB and 30 dB on the left and right side respectively. The test was repeated at 2 occasions on both the sides at all intensity of stimulation to look for reproducible.

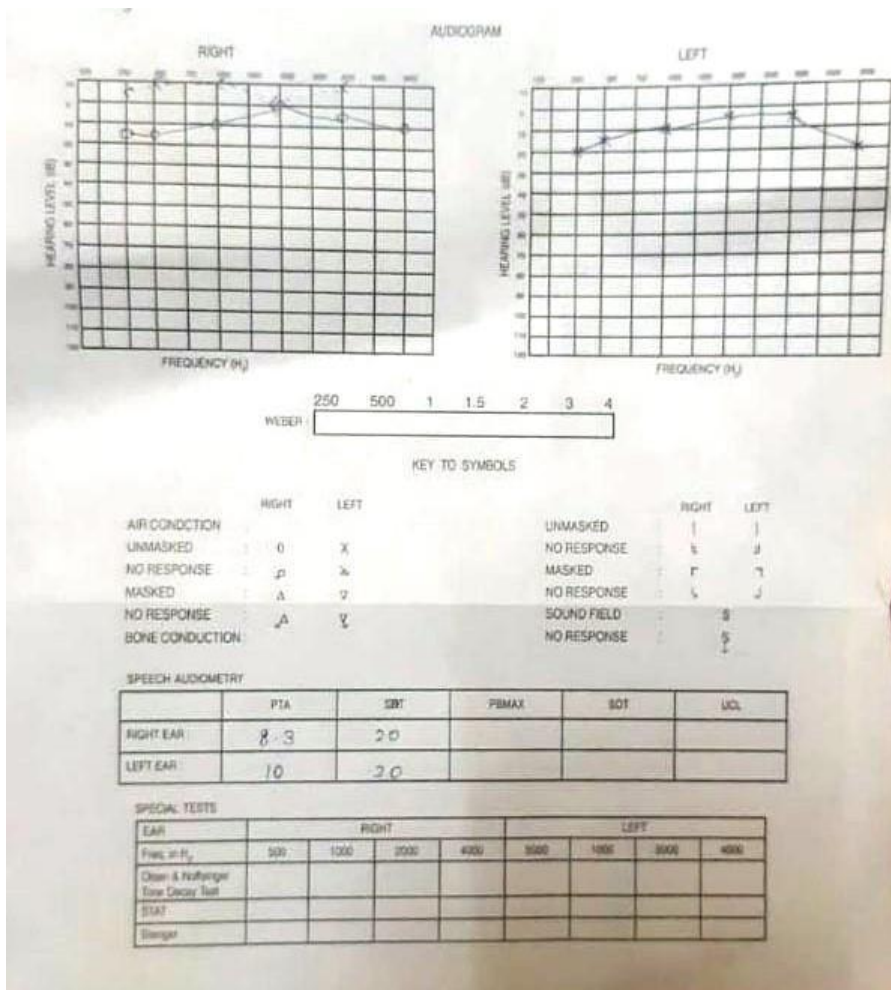
Results :

Encl: Tracings of all recordings with relevant values.

Latency of wave III to V moderately prolonged on the right side.

CONCLUSION: Findings suggest moderate right upper auditory path way dysfunction.

BERA Report with Findings



Audiological Evaluation

Final Diagnosis

ATAXIA TELANGIECTASIA

Discussion

Here we have presented a case of 18 year old female born to a consanguineous marriage with chronic progressive

ataxia with bilateral telangiectasia, grossly elevated alpha fetoprotein, decreased IgA and IgE levels and MRI findings suggestive of diagnosis of **Ataxia Telangiectasia presenting with new onset type 2 diabetes mellitus, one of the known association of A-T [1-3].**

Ataxia Telangiectasia also known as “Louis bar syndrome” is a complex disorder, characterized by progressive cerebellar ataxia, neurologic impairment, immunological abnormalities which includes immunoglobulin and antibody deficiencies and lymphopenia, ocular and cutaneous telangiectasia, risk of lymphoreticular malignancy, and increased hypersensitivity to ionizing radiation [1-3].

It is an Autosomal Recessive disorder With Incidence of 1 in 100,000 live Births [1] Males and females are equally affected [1]. It is caused due to mutation on ATM Gene on 11q22-23 involved in cell division and DNA repair [1,3].

Both humoral and cellular immunity are impaired (combined Immunodeficiency) [2,3] Other manifestations include -Recurrent sinopulmonary infections, choreo-athetoid movements Premature aging, alopecia areata. Insulin resistant Diabetes, predisposition to development of malignancy, Hyper- sensitivity to radiation, slowed growth.

There is delayed pubertal development, gonadal atrophy/dysgenesis [1-3]. Average life expectancy was reported to be approximately 25 years. Two most common cause of death are chronic lung disease and cancer [3]. There is no definitive treatment for A-T.

New advances in management includes *gene therapy and IVIG administration [3]*

Acknowledgements : None

References

1. Saleh AA. Ataxia Telangiectasia:a case report. Int J Health Sci Res. 2018;8(3):279-281
2. M Shabeer
A Nana, N Ali,B pattnaik.JMSCR,2017. June.5(6);
22915-22917 <https://dx.doi.org/10.18535/jmscr/v5i6.19>
3. Rothblum Oviatt
C., Wright, J.,Lefton-Grief, M.A.et al.Ataxia telangiectasia: a review.
Orphanet J Rare Dis 11, 159(2016).
<https://doi.org/10.1186/s13023-016-0543-7>